

Isolated Skeletal Muscle Metastasis and Hypercalcemia in Non-Small Cell Lung Carcinoma

Javid Muzamil Dandroo, Naveed Mohsin, Shabir Ahmed Rather

Department of Internal Medicine, SKIMS Soura, Srinagar, Jammu and Kashmir, India

Correspondence: Dr. Javid Muzamil Dandroo, Married Hostel, Room Number F16, SKIMS Soura, Srinagar - 190 011, Jammu and Kashmir, India. E-mail: Javidmd@gmail.com

ABSTRACT

Lung cancer is the most common malignancy throughout the world. Non-small cell lung carcinoma is the most common type and squamous cell type is the most common in India. Patients mostly present with chest related symptoms and signs. Isolated skeletal muscle metastasis (ISMM) is rarely seen. We describe a patient who presented with ISMM and hypercalcemia without any pulmonary symptoms.

Key words: Cytokeratin, isolated skeletal muscle metastasis, nonsmall cell lung carcinoma, parathyroid hormone related peptide, skeletal muscle metastasis, thyroid transcription factor

ملخص البحث:

يعتبر سرطان الرئة أكثر الأورام عالمياً، كما أن سرطان الرئة غير كبير الخلايا هو الأكثر انتشاراً. وعادة ما يشكو المرضى من آلام في الصدر وتغيرات سريرية، كما أن وجود نمو ثانوي للورم في العظام يعتبر نادراً وتبلغ نسبته (0.16% - 6%) حسب بعض الدراسات الاسترجاعية. يناقش الباحثون حالة مريض حضر إلى المستشفى وكان يعاني من ورم ثانوي في العظام مع ارتفاع في نسبة الكالسيوم وعدم وجود أعراض في الجهاز التنفسي.

INTRODUCTION

Lung cancer is the most common malignancy throughout the world and non-small cell histology always outnumber the small-cell type. Lung cancer has diverse clinical presentations and chest complaints are the most common. Lung cancer metastases to every organ with a rare involvement of isolated skeletal muscle. In one retrospective series, the prevalence of isolated skeletal muscle metastasis (ISMM) was seen in 0.16-6%. Again, paraneoplastic manifestations are commonly encountered in the presentation of lung cancer. However, hypercalcemia with ISMM as the lung cancer presentation is unique and our literature search showed that no patient has ever been reported.

CASE REPORT

A 65-year-old male of Asian origin, ex-smoker with no comorbid illness, presented with right gluteal region pain of 3 months duration. The pain was provoked by hip movement and was intermittently relieved by analgesics. This was associated with constitutional symptoms in the form of loss of appetite and loss of weight. There were no pulmonary symptoms. The patient was dehydrated with resting tachycardia pulse rate 110/min, blood pressure of 90/60 mmHg with the loss of skin turgor. The rest of systemic examination was unremarkable.

This is an open access article distributed under the terms of the Creative Commons Attribution-NonCommercial-ShareAlike 3.0 License, which allows others to remix, tweak, and build upon the work non-commercially, as long as the author is credited and the new creations are licensed under the identical terms.

For reprints contact: reprints@medknow.com

Access this article online	
Quick Response Code:	Website: www.sjmms.net
	DOI: 10.4103/1658-631X.194245

How to cite this article: Dandroo JM, Mohsin N, Rather SA. Isolated skeletal muscle metastasis and hypercalcemia in non-small cell lung carcinoma. Saudi J Med Med Sci 2017;5:62-4.

On evaluation, complete hemogram and liver function tests were normal. Renal function tests revealed serum urea of 112 mg/dl, serum creatinine of 2.87 mg/dl, serum calcium of 18.87 mg/dl and serum parathyroid hormone-related peptide was 15 pmol/L. The rest of all investigations such as serum phosphorous, uric acid, coagulogram and arterial blood gas with electrolytes were normal.

Imaging was carried-out for this patient and chest x-ray was absolutely normal. Ultrasound of the right gluteal region revealed heterogeneous, predominantly hypoechoic mass in relation to the right iliopsoas muscle which appeared to breach the cortex of the underlying iliac bone. Bone scan was normal with the exception of increased tracer uptake of the right iliac bone at the site of involvement. Contrast computed tomography (CT) of the chest and abdomen revealed left hilar mass [Figure 1] and contrast CT of the right hip showed mixed attenuating mass arising from the right iliac muscle involving the right iliac fossa of the

pelvic bone and there was destruction of iliac fossa of the pelvic bone [Figure 2]. Bronchoscopy showed extra luminal lesion in the left lower lobe bronchus, CT guided lung biopsy revealed squamous cell carcinoma [Figure 3] and CT guided fine needle aspiration cytology of iliac muscle showed metastatic squamous cell carcinoma [Figure 4]. Immunohistochemistry of lung and muscle biopsy revealed cytokeratin 5/6 positive and thyroid transcription factor-1 negative.

Ultimately, the final diagnosis squamous cell carcinoma of the lung with ISMM with paraneoplastic hypercalcemia.

Finally, the patient was managed with forced diuresis, bisphosphonates and one session of hemodialysis for hypercalcemia. Serum calcium dropped to 10.5 mg/dl and renal functions improved with serum urea of 40 mg/dl and serum creatinine of 1.5 mg/dl. The patient received palliative six cycles of taxol based chemotherapy with the

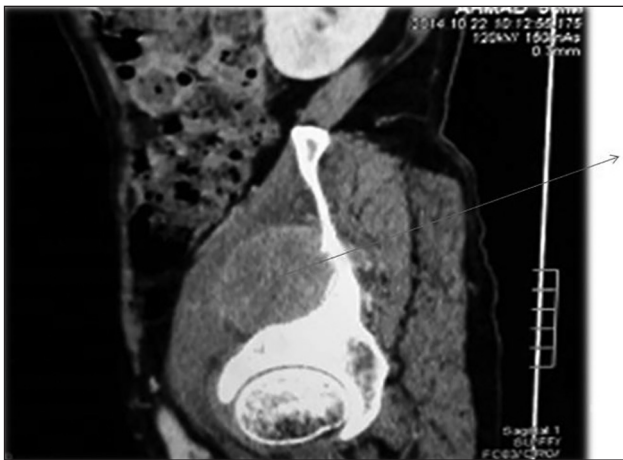

Figure 1: Contrast enhanced computed tomography chest showing left hilar mass marked with arrow.

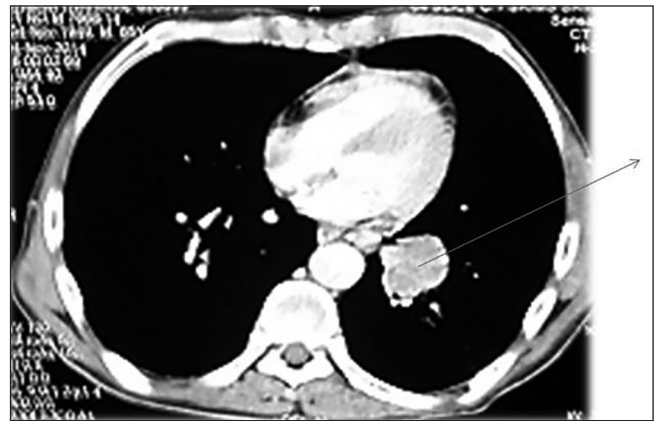

Figure 2: Contrast enhanced computed tomography hip region showing muscle metastasis with underlying bone.

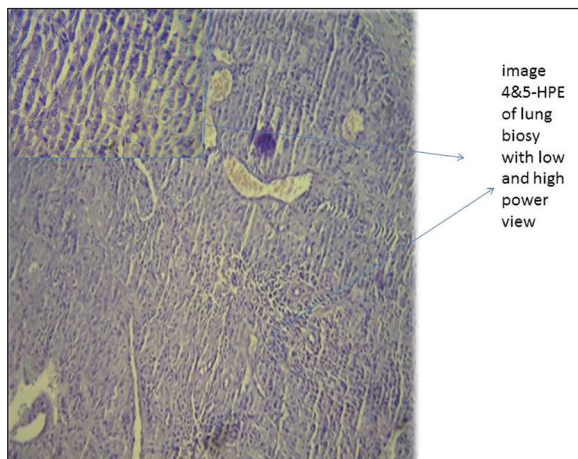


Figure 3: Lung biopsy showing squamous cell carcinoma - both high power and low power view.

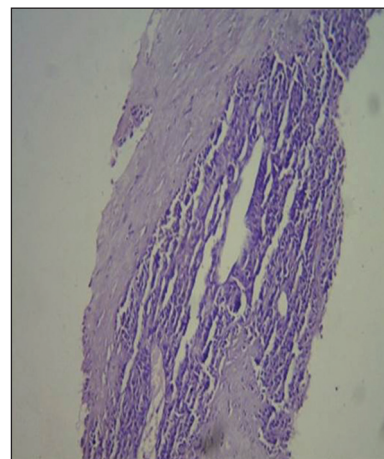


Figure 4: Biopsy of muscle metastasis (iliacus muscle) showing squamous cell carcinoma deposit.

partial response of primary lesion and complete response of metastatic lesion.

DISCUSSION

Skeletal muscles are an uncommon site of hematogenous metastases from epithelial neoplasms. Solitary muscle metastasis has been reported in lung cancer.^[1] Tuoheti *et al.* found that only 4 (0.16%) out of 2557 patients with lung cancer developed metastasis to the skeletal muscle.^[2] Most frequent muscle involvement is seen in the thigh, iliopsoas, and paraspinal muscle.^[3] In the present case, however, ISMM with severe hypercalcemia without bone metastasis was the presenting feature with, no pulmonary symptoms. The dual presentation is rarely seen, but can develop in the course of the disease.

According to Prior,^[4] the first description of muscle metastasis was reported by Wittich in 1854, and Willis was the first to report a muscle metastasis of lung origin. Despite being highly vascular, the exact incidence is not well-known. Subclinical metastasis may indeed be more common than generally thought. One large autopsy study of 5298 people found that 6% involved skeletal muscle metastasis (SMM) of the chest or abdominal wall.^[5]

Nowadays, an autopsy on all cancer-related deaths is not performed routinely. An important help is the 18 fluoro-deoxy-glucose positron emission tomoscintigraphy-scan mostly for detecting subclinical metastasis.^[6,7] Since this imaging procedure was introduced into practice in 2004, single SMM has rarely been seen. Certainly, there are several limitations to muscle enhancement in positron emission tomography scan, so in this study only the patients with CT-scan confirmation and a histologic sample of one metastatic deposit was taken as an absolute metastatic deposit. Almost 1/3 of metastases in this study were discovered before the lung cancer. The most common appearance (83%) of the lesions on contrast-enhanced helical CT is that of a rim-enhancing mass with central hypo-attenuation.^[8,9]

There are several theories to explain muscle resistance of metastatic disease. The most important hypotheses are mechanical (muscle contraction, high tissue pressure^[8] and extremely variable blood flow^[10]), metabolic (pH, lactic acid production^[11] and toxic-free radical oxygen^[12]) or immunologic (cellular, humoral immunity and hypersensitivity reaction).^[13] None of them in isolation can explain the full mechanism, but a combination of them could.

Almost all types of non-small cell lung carcinoma (NSCLC) can metastasize in the muscle with no particular preferences. The prognosis is obscure, but most patients died with a median survival of only 6 months. The role of local treatment in the global survival rate is difficult to define.

CONCLUSION

Our patient had an only single metastatic deposit in the right iliac muscle as a presenting feature with no pulmonary symptoms. The dual presentation of hypercalcemia with ISMM in NSCLC has not been reported so far in literature. This case report is, therefore, unique in lung cancer presentation.

Financial support and sponsorship

Nil.

Conflict of interest

There are no conflicts of interest.

REFERENCES

1. Di Giorgio A, Sammartino P, Cardini CL, Al Mansour M, Accarpio F, Sibio S, *et al.* Lung cancer and skeletal muscle metastases. *Ann Thorac Surg* 2004;78:709-11.
2. Tuoheti Y, Okada K, Osanai T, Nishida J, Ehara S, Hashimoto M, *et al.* Skeletal muscle metastases of carcinoma: A clinicopathological study of 12 cases. *Jpn J Clin Oncol* 2004;34:210-4.
3. Kaira K, Ishizuka T, Yanagitani N, Sunaga N, Tsuchiya T, Hisada T, *et al.* Forearm muscle metastasis as an initial clinical manifestation of lung cancer. *South Med J* 2009;102:79-81.
4. Prior C. Metastatic tumors in striated muscle; review and case report. *Riv Anat Patol Oncol* 1953;6:543-60.
5. Picken JW. Use and limitations of autopsy data. In: Weiss L, editor. *Fundamental Aspects of Metastasis*. Amsterdam: North-Holland; 1976. p. 377-84.
6. Heffernan E, Fennelly D, Collins CD. Multiple metastases to skeletal muscle from carcinoma of the esophagus detected by FDG PET-CT imaging. *Clin Nucl Med* 2006;31:810-1.
7. Liu Y, Ghesani N, Mirani N, Zuckier LS. PET-CT demonstration of extensive muscle metastases from breast cancer. *Clin Nucl Med* 2006;31:266-8.
8. Pretorius ES, Fishman EK. Helical CT of skeletal muscle metastases from primary carcinomas. *AJR Am J Roentgenol* 2000;174:401-4.
9. Toussiro E, Lafforgue P, Tonolli I, Acquaviva PC. Disclosing muscular metastases. Their peculiarities apropos of 3 cases. *Rev Rhum Ed Fr* 1993;60:167-71.
10. Weiss L. Biomechanical destruction of cancer cells in skeletal muscle: A rate-regulator for hematogenous metastasis. *Clin Exp Metastasis* 1989;7:483-91.
11. Seely S. Possible reasons for the high resistance of muscle to cancer. *Med Hypotheses* 1980;6:133-7.
12. Sridhar KS, Rao RK, Kunhardt B. Skeletal muscle metastases from lung cancer. *Cancer* 1987;59:1530-4.
13. Stein-Werblowsky R. Skeletal muscle and tumour metastasis. *Experientia* 1974;30:423-4.