



Case report

Case series: Use of stromal lenticule as patch graft

Yong Ju Song^a, Sumi Kim^b, Gil Joong Yoon^{c,*}^a Department of Ophthalmology, Chosun University College of Medicine, Gwangju, South Korea^b Department of Dentistry, Hallym University Gangnam Sacred Heart Hospital, Seoul, South Korea^c Happy Eye21 Hospital, Gwangju, South Korea

ARTICLE INFO

Keywords:

Stromal lenticule

Patch graft

Ahmed valve tube exposure

Bullous keratopathy

ABSTRACT

Purpose: To introduce cases of the use, as patch grafts, of stromal lenticules obtained by small incision lenticule extraction (SMILE) surgery.

Observations: Case 1 was a 79-year-old man who presented with Ahmed-valve-tube exposure in his left eye. His uncorrected visual acuity (UCVA) was 20/40, best-corrected visual acuity (BCVA) 20/32, and intraocular pressure (IOP) 11 mmHg. He was treated with stromal lenticule patch that had been extracted by SMILE surgery. The patch was positioned underneath of the conjunctiva and sutured to it. At postoperative 8 months, the graft site was well maintained without Ahmed valve-tube exposure, the UCVA was 20/32, BCVA 20/20, and IOP 12 mmHg.

Case 2 was a 60-year-old man who presented with Ahmed-valve-tube exposure in his right eye. His UCVA was finger-count (FC) 30 cm, his BCVA 20/125, and his IOP 14 mmHg. He was treated with stromal lenticule patch by the same method as employed in case 1. At postoperative 10 days, tube re-exposure and displacement of the Ahmed valve external plate toward the limbus area occurred due to loosening of the anchoring suture. So, we removed the Ahmed valve device, which had been implanted in the supero-temporal area, and performed new Ahmed valve implantation, with a stromal lenticule flap instead of a partial scleral flap, in the supero-nasal area. As of 6 months post-reoperation, the patient was stable, with UCVA 20/200, BCVA 20/40 and IOP 13 mmHg.

Case 3 was a 74-year-old man who presented with bullous keratopathy in his right eye, which was blind. Due to severe adhesions, his conjunctiva could not cover the entire cornea. Therefore, we performed a stromal lenticule patch graft with conjunctival advance flap. At postoperative 3 months, the patient's right eye was stable, without displacement or melting of the lenticule graft.

Conclusions & importance: It is suggested that the stromal lenticule, with its biocompatibility, sufficient strength, ease of handling and low cost, is a useful patch graft for various therapeutic purposes in the ophthalmic field.

1. Introduction

Various types of patch grafts have been used in the treatment of various diseases in the field of ophthalmology. Patch grafts have been used with the cornea, sclera, pericardium, fascia lata, dura mater and amniotic membrane.¹ Recently, there was a report on the patch-graft treatment of corneal perforation by SMILE surgery-extracted stromal lenticules with the amniotic membrane.²

The utility of the stromal lenticule as an alternative tissue to the corneal stroma for autologous future re-implantation or allogenic donor implantation has been reported. There have been studies on stromal expansion with a lenticule for ultrathin-cornea crosslinking and lenticule implantation for keratoconus, hyperopia and presbyopia.^{3–7} The utility of the stromal lenticule as a patch graft in the treatment of other

ocular diseases, however, has not been explored, the one exception being the above-noted study on corneal perforation.

We herein report the application of the stromal lenticule as a patch graft for the treatment of 2 patients with Ahmed valve exposure and 1 patient with bullous keratopathy.

2. Case reports

2.1. Case 1

A 79-year-old Asian man visited our clinic due to ocular pain and foreign-body sensation in the left eye. His uncorrected visual acuity (UCVA) was 20/40, best-corrected visual acuity (BCVA) 20/32, and intraocular pressure (IOP) 11 mmHg. The patient had undergone

* Corresponding author. Happy Eye21 Hospital, 950, Mujin-daero, Seo-gu, Gwangju, 61932, Republic of Korea.

E-mail address: yoonalpha@gmail.com (G.J. Yoon).

<https://doi.org/10.1016/j.ajoc.2018.09.009>

Received 15 June 2018; Received in revised form 20 September 2018; Accepted 25 September 2018

Available online 27 September 2018

2451-9936/© 2018 The Authors. Published by Elsevier Inc. This is an open access article under the CC BY-NC-ND license

(<http://creativecommons.org/licenses/by-nc-nd/4.0/>).

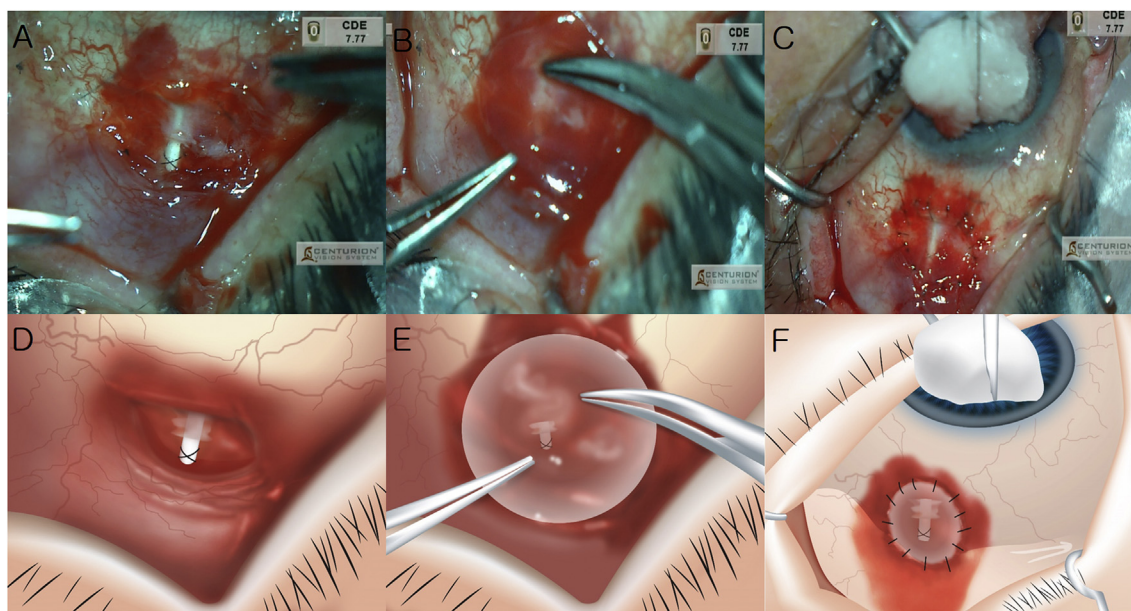


Fig. 1. Treatment procedure of Ahmed valve tube exposure using lenticule in case 1.
 (A) Ahmed valve tube was exposed at supero-temporal area.
 (B) Stromal lenticule was placed over the Ahmed valve-exposure area.
 (C) Stromal lenticule was placed underneath the conjunctiva and sutured with surrounding conjunctiva.
 (D) Illustration of fig.(A)
 (E) Illustration of fig.(B)
 (F) Illustration of fig.(C).

cataract surgery in both eyes 6 years previously and Ahmed valve implantation with partial scleral flap for uveitic glaucoma in the left eye 1 month previously. His left eye was being treated with 1 anti-glaucoma medication. On slit lamp examination, the Ahmed valve tube, which was fixed to the sclera with sutures, was exposed. We determined to repair the exposure site using a stromal lenticule.

The stromal lenticule was extracted by SMILE surgery on the day of Ahmed valve-exposure repair surgery. The surgery was performed using a 120 μm cap thickness, a 7.9 mm cap diameter, a 6.5 mm lenticule diameter and a 120° side-cut angle. Lenticule donors with corrected spherical equivalents of 6 diopters or more had been selected in order to be able to obtain a stromal lenticule thickness of more than 100 μm . Testing for human immunodeficiency virus, syphilis, herpes virus and hepatitis was performed. The lenticule donor did not have any history of corneal disease, infections, immune deficiency or ocular surgery.

In performing the graft surgery, first, debridement of the surrounding conjunctiva was performed at the site of Ahmed valve exposure (Fig. 1A). Then, the stromal lenticule (thickness: 100 μm ; diameter: 6.5 mm) was placed underneath the conjunctiva and centered over the Ahmed valve-exposure area (Fig. 1B). Using nylon 10-0 with spatula needle, 16 interrupted sutures were performed to connect the lenticule to the surrounding conjunctiva (including tenon) tissue (Fig. 1C). We made a watertight suture to prevent leakage of aqueous humor. This is the one of reasons of tube re-exposure. The operation was completed by confirming the proper tension of the sutures.

At postoperative 8 months, the suture site was well maintained without Ahmed valve-tube exposure (Fig. 3A), the UCVA was 20/32, the BCVA 20/20, and the IOP 12 mmHg.

2.2. Case 2

A 60-year-old Asian man visited our clinic due to ocular pain and foreign-body sensation in the right eye. His UCVA was finger-count (FC) 30 cm, his BCVA 20/125, and his IOP 14 mmHg. He had undergone cataract surgery, pars plana vitrectomy and silicone oil infusion for

diabetic tractional retinal detachment in the right eye 6 months previously. Five months previously, the silicone oil had been removed, but it was determined that he required glaucoma surgery and Ahmed valve implantation with partial scleral flap for neovascular glaucoma (NVG) in the supero-temporal area. His right eye was being treated with 2 anti-glaucoma medications. After 5 months of glaucoma surgery, on slit lamp examination, the distal portion of the Ahmed valve tube was exposed (i.e., it was not covered by the scleral flap). We treated the patient by stromal lenticule graft, following the same procedure as in case 1.

The stromal lenticule was extracted by SMILE surgery on the day of Ahmed valve-exposure repair surgery. Then, the stromal lenticule (thickness: 100 μm ; diameter: 6.5 mm) was placed underneath the conjunctiva and centered over the Ahmed valve-exposure area. Using nylon 10-0 with spatula needle, 10 interrupted sutures were performed to connect the lenticule to the surrounding conjunctiva (including tenon) tissue.

At postoperative 1 week, the suture site was well maintained without Ahmed valve tube exposure. However, at postoperative 8 days, lenticule melting was observed in the supero-temporal area of the recipient site. At postoperative 10 days, tube re-exposure and displacement of the Ahmed valve external plate toward the limbus area occurred due to loosening of the anchoring suture. So, at postoperative 12 days, we removed the Ahmed valve device, which had been implanted in the supero-temporal area, and performed new Ahmed valve implantation, with a stromal lenticule flap instead of a partial scleral flap, in the supero-nasal area. The tube put into sulcus to avoid further corneal damage.

As of 6 months post-reoperation, the patient was stable with UCVA 20/200, BCVA 20/40 and IOP 13 mmHg (Fig. 3B).

2.3. Case 3

A 74-year-old Asian man visited our clinic due to bullous keratopathy in the right eye, which required routine exchange of a therapeutic

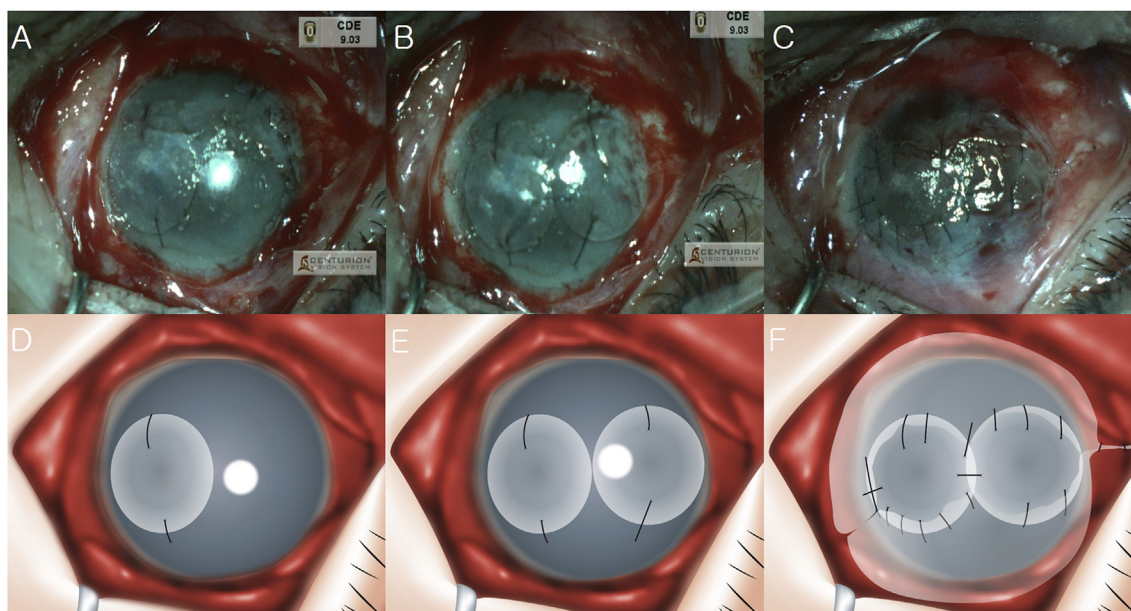


Fig. 2. Treatment procedure of bullous keratopathy using lenticule in case 3. (A) One stromal lenticule was placed in the 3°/c position of the cornea and fixed in right eye. (B) A second stromal lenticule was placed in the 9°/c position of the cornea and fixed. (C) Advancement of the inferior and superior conjunctival flap was performed. (D) Illustration of fig.(A) (E) Illustration of fig.(B) (F) Illustration of fig.(C).

contact lens. His right eye was blind. He had been uncomfortable due to frequent clinic visits and lens exchange. Due to severe adhesions, his conjunctiva could not cover the entire cornea. Therefore, we performed a stromal lenticule patch graft and conjunctival advance flap to solve the problem.

First, the epithelium of the cornea was removed. One stromal lenticule extracted by SMILE surgery was placed in the 3°/c position of the cornea and fixed at the 6 and 12°/c positions with nylon 10-0 sutures (Fig. 2A). Then, a second stromal lenticule was placed in the 9°/c position of the cornea and fixed at the 6 and 12°/c positions (Fig. 2B). Advancement of the inferior conjunctival flap was performed in the direction of the cornea, after which it was fixed to each of the lenticules (including cornea) by sutures (Fig. 2C). Advancement of the superior conjunctival flap in the direction of the cornea and fixation to each of the lenticules (including cornea) was performed as well.

Postoperatively, the patient's right eye was stable, without displacement or melting of the lenticule graft. At postoperative 3 months, he was able to forego use of the therapeutic contact lens (Fig. 3C).

3. Discussion

SMILE is a refractive surgery by which the stromal lenticule is extracted through a small incision, unlike laser-assisted in situ keratomileusis (LASIK), which utilizes a large flap. It has been reported that in

comparison with LASIK, SMILE showed similar or better results in regard to visual acuity prognosis, dry eyes, and the safety of corneal tissue. SMILE is now a popular refractive surgery.⁸

The stromal lenticule as extracted by SMILE surgery has been utilized for various purposes in the ophthalmic field. As noted above, lenticule implantation to the corneal stroma has been used in the treatment of keratoconus, hyperopia and presbyopia.^{3–7} There have also been reports on lenticule use as a patch graft for corneal perforation and partial corneal defect.^{2,9} In order to determine the effectiveness of the lenticule as a patch graft for other ocular diseases, we treated 2 patients with Ahmed valve exposure and 1 patient with bullous keratopathy using lenticules. Although 1 patient showed tube exposure, we believe that this problem was not lenticule related but was due rather to improper fixation of the Ahmed valve device (i.e., displacement toward the limbus area). After Ahmed valve removal and new Ahmed valve implantation using a stromal lenticule flap instead of a partial scleral flap, there was no reoccurrence of valve exposure. Thus, we could confirm the usefulness of the stromal lenticule as a patch graft.

Indeed, the stromal lenticule has several merits. First, it offers the benefits of the corneal patch graft. As is known, the corneal patch graft provides good biocompatibility and strength, and compared with the scleral patch graft, it is thin and transparent, and thus cosmetically superior.^{1,10} The stromal lenticule, significantly, is even thinner than

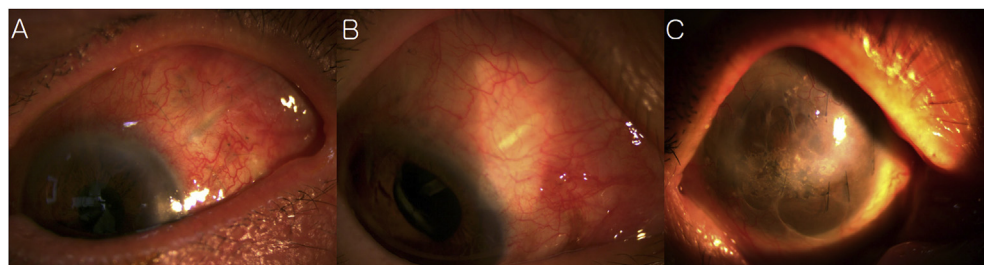

Fig. 3. Result of treatment using lenticule in case 1, 2 and 3. (A) At postoperative 8 months, the suture site was well maintained without Ahmed valve-tube exposure in case 1. (B) At postoperative 6 months, the suture site was well maintained without Ahmed valve-tube exposure in case 2. (C) At postoperative 3 months, the patient's right eye was stable, without displacement or melting of the lenticule graft in case 3.

the corneal patch graft (100 vs. 300 μm), and showed good strength in the present study. Moreover, the lenticule offers good accessibility: the corneal patch graft and the other patch grafts are difficult to obtain, which procedure is charged to the patient, whereas the lenticule is easily extracted by SMILE surgery and can be performed inexpensively.² All of this notwithstanding, the stromal lenticule has several shortcomings. It is difficult to obtain in hospitals that do not perform SMILE surgery. Also, although it can be preserved at room temperature for up to 48 hours after extraction without special management, longer preservation does require special management.¹¹ So, optimally, it needs to be used within a small time window after extraction.

The limitation of our report is that it includes no cases of the use of the stromal lenticule with the amniotic membrane. A study using lenticules for corneal perforation reported that when they were employed with the amniotic membrane, the success rate was higher than for lenticules alone.²

4. Conclusions

The preliminary results of this study show that the SMILE-extracted stromal lenticule was useful for complication-free treatment of an Ahmed-valve-tube-exposure and bullous keratopathy patient. It is suggested that the stromal lenticule, with its biocompatibility, sufficient strength, ease of handling and low cost, is a useful patch graft for various therapeutic purposes in the ophthalmic field.

Patient consent

All of the patients consented, in writing, to publication of their respective data.

Acknowledgements and disclosures

Funding

There was no funding.

Conflicts of interest

The following authors have no financial disclosures: YJS, SMK, GJY.

Authorship

All of the authors attest that they meet the current ICMJE criteria for authorship.

Acknowledgments

None.

Appendix A. Supplementary data

Supplementary data to this article can be found online at <https://doi.org/10.1016/j.ajoc.2018.09.009>.

References

- Lind JT, Shute TS, Sheybani A. Patch graft materials for glaucoma tube implants. *Curr Opin Ophthalmol*. 2017;28(2):194–198.
- Abd Elaziz MS, Zaky AG, El SaebaySarhan AR. Stromal lenticule transplantation for management of corneal perforations; one year results. *Graefes Arch Clin Exp Ophthalmol*. 2017;255(6):1179–1184.
- Sachdev MS, Gupta D, Sachdev G, Sachdev R. Tailored stromal expansion with a refractive lenticule for crosslinking the ultrathin cornea. *J Cataract Refract Surg*. 2015;41(5):918–923.
- Pradhan KR, Reinstein DZ, Carp GI, Archer TJ, Gobbe M, Gurung R. Femtosecond laser-assisted keyhole endokeratophakia: correction of hyperopia by implantation of an allogeneic lenticule obtained by SMILE from a myopic donor. *J Refract Surg*. 2013;29(11):777–782.
- Ganesh S, Brar S. Femtosecond intrastromal lenticular implantation combined with accelerated collagen cross-linking for the treatment of keratoconus—initial clinical result in 6 eyes. *Cornea*. 2015;34(10):1331–1339.
- Sun L, Yao P, Li M, Shen Y, Zhao J, Zhou X. The safety and predictability of implanting autologous lenticule obtained by SMILE for hyperopia. *J Refract Surg*. 2015;31(6):374–379.
- Jacob S, Kumar DA, Agarwal A, Agarwal A, Aravind R, Saijimal AI. Preliminary evidence of successful near vision enhancement with a new technique: PrEsbyopic allogeneic refractive lenticule (PEARL) corneal inlay using a SMILE lenticule. *J Refract Surg*. 2017;33(4):224–229.
- Lee JK, Chuck RS, Park CY. Femtosecond laser refractive surgery: small-incision lenticule extraction vs. femtosecond laser-assisted LASIK. *Curr Opin Ophthalmol*. 2015;26(4):260–264.
- Bhandari V, Ganesh S, Brar S, Pandey R. Application of the SMILE-derived glued lenticule patch graft in microperforations and partial-thickness corneal defects. *Cornea*. 2016;35(3):408–412.
- Spierer O, Waisbourd M, Golan Y, Newman H, Rachmiel R. Partial thickness corneal tissue as a patch graft material for prevention of glaucoma drainage device exposure. *BMC Ophthalmol*. 2016;16:20.
- Liu YC, Williams GP, George BL, et al. Corneal lenticule storage before reimplantation. *Mol Vis*. 2017;23:753–764.