

## CASE REPORT

# Acute appendicitis with appendix duplicity in Eritrea: A case report

Rami Yassin  | Mhmoud Mohmed  | Tekeste Fekadu

Department of Surgery, Orotta College of Medicine and Health Sciences, Orotta Referral Hospital, Asmara, Eritrea

**Correspondence**

Rami Yassin, Orotta College of Medicine and Health Sciences, Orotta Referral Hospital, Asmara, Eritrea.  
Email: [ramyyassin84@gmail.com](mailto:ramyyassin84@gmail.com)

**Abstract**

Duplicity of the appendices is very rare. A 32-year-old man presented with type B2 duplicity of the appendix and acute appendicitis. An appendectomy was done for both. Intraoperative incidental finding is the only chance to avoid missing appendix duplicity and appendicectomy should be done for both.

**KEYWORDS**

acute appendicitis, appendix duplicity, missed appendix

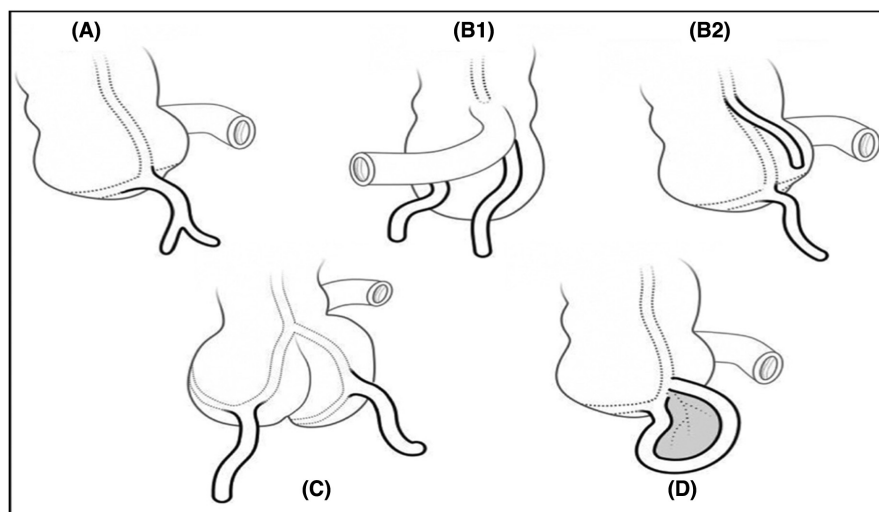
## 1 | INTRODUCTION

Congenital anomalies of the appendix are extremely rare. The reported incidence is 0.004%. They include agenesis, duplication, and anatomical variation related to length and position. Appendix duplicity is the most common type, of which type B2 is the most common variant and commonly associated with acute appendicitis. A total of 141 cases of duplicity were reported.<sup>1</sup> However,

appendicitis of the double appendix was reported in <15 cases.<sup>2</sup> According to the modified Cave-Wallbridge classification (Figure 1), type B2 is the most common variant reported in the literature.

Routine preoperative imaging modalities, CT scans, and abdominal ultrasound did not reveal duplicity.<sup>3</sup> The failure to identify duplicity in appendectomy can lead to significant uncertainty in assessing the right lower quadrant pain if the second appendix (missed appendix) is inflamed

**FIGURE 1** Modified Cave-Wallbridge classification. Type A, partial duplication of the appendix; Type B1 (bird type), two appendices are placed symmetrically on both sides of the ileocaecal valve; Type B2 (taenia coli type), one appendix is in the usual place, and the other is far along with the taenia coli; Type C, duplication of the caecum and appendix; Type D (horseshoe type), one appendix has two openings in the caecum (2).



This is an open access article under the terms of the [Creative Commons Attribution-NonCommercial](https://creativecommons.org/licenses/by-nc/4.0/) License, which permits use, distribution and reproduction in any medium, provided the original work is properly cited and is not used for commercial purposes.

© 2022 The Authors. *Clinical Case Reports* published by John Wiley & Sons Ltd.

in the future. For this uncertainty of the diagnosis, appendicitis of missed appendix may lead to increased morbidity and mortality and serious medico-legal consequences.

In this clinical case report, we present a rare case of double appendix in a patient with acute appendicitis discovered incidentally during the surgery. The surgery was done in Orotta referral hospital, Asmara, Eritrea.

## 2 | CASE REPORT

A 32-year-old male was brought to the Emergency Department of the Orotta Referral Hospital, Asmara, Eritrea, with complaints of central abdominal pain that was shifted to the right iliac fossa for 1 day. It was aggravated by movement and was associated with nausea and vomiting. Otherwise, he had clear systemic review and denied any significant past medical history.

On physical examination, the pulse rate was 90/minute, the respiratory rate was 18/minute and temperature of 37°C. There was right iliac fossa tenderness and guarding. The white blood cell counts were normal with a left neutrophilic shift. The urine examination and renal function test were within the normal range. Preoperative imaging studies were not performed, and the diagnosis of acute appendicitis was made based on clinical evaluation.

An open appendectomy was performed in the same day of admission. A minimal seropurulent fluid collection was found in the right iliac fossa. There were two separate appendices attached to a single caecum in the taenia coli and joined by a single mesoappendix (Figure 2A). Only one appendix was apparently inflamed. The mesoappendix was ligated, and both appendices were removed (Figure 2B,C). The postoperative period passed

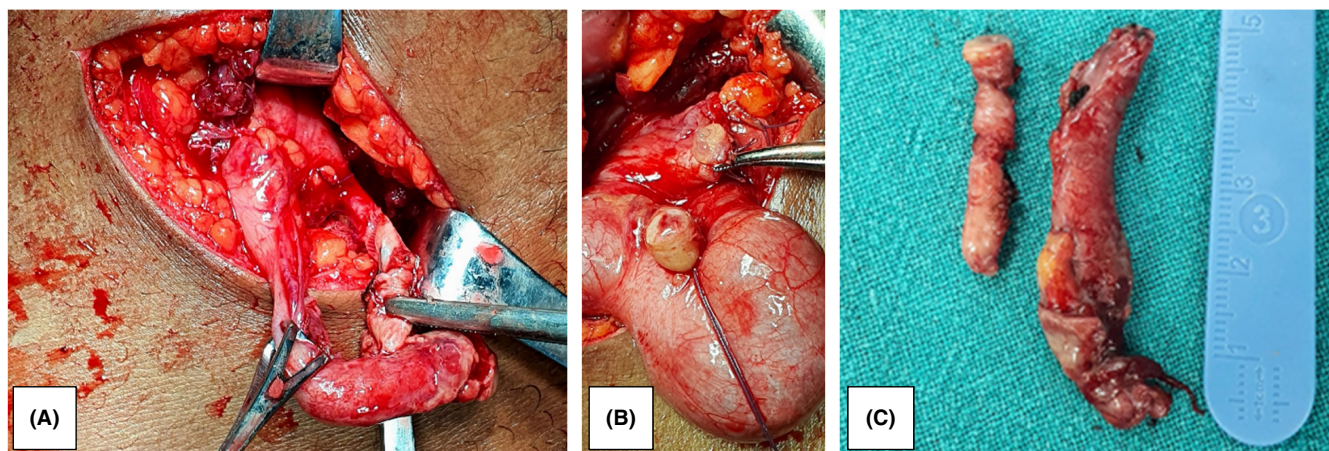
uneventful, and the patient discharged in good general condition after 72 h.

## 3 | DISCUSSION

With regard to the extreme scarcity of appendiceal anomalies, duplication of the appendix is the most common anomaly that has been reported. A review of published reported cases identified 141 duplicate appendices.<sup>1</sup> According to the Modified Cave-Wallbridge classification of the anatomical variation of duplication, B2 is the most common type.<sup>2</sup> The literature reported <15 cases of appendicitis in double appendices. For these considerable matchings and similarity to our case, we think that the literature background strongly supports our findings.

The preoperative diagnosis of appendix duplicity is challenging.<sup>3</sup> It is almost always identified intraoperatively. In this case, we did not perform image studies, as signs and symptoms were typical of acute appendicitis. Duplicity of the appendices may be missed if the second appendix is concealed in the retrocaecal position.<sup>2,4</sup> Generally, surgical field exposure is inadequate during open appendectomy, and routine caecal mobilization and retrocaecal exploration are not performed routinely during the procedure. Laparoscopy can increase the detection rate due to a better visualization of the abdominal cavity.<sup>5</sup>

In our case, we fortunately detected and removed both appendices. Intraoperative missing of the second appendix has serious medico-legal consequences and increases the risk of complications if the missed appendix got inflamed in the future. The literature reported a case of ruptured appendix in the retrocaecal space presented after a



**FIGURE 2** The two appendices based on a single caecum (A), the two appendiceal stumps after appendectomy (B), and the two appendices (C).

previous laparoscopic appendectomy.<sup>4</sup> The diagnosis of appendix duplicity should be considered in any patient with a history of appendectomy who present with similar symptoms and signs of acute appendicitis.

## 4 | CONCLUSION

Duplicity in the Appendix, even though rare, should not be overlooked. The clinical judgment in the diagnosis of typical acute appendicitis without preoperative imaging studies makes the diagnosis of duplicity almost difficult before the surgery. Intraoperative incidental finding is the only chance to avoid missing appendix duplicity and appendectomy should be done for both.

## AUTHOR CONTRIBUTIONS

**Rami Yassin:** Formal analysis; investigation. **Mhmoud Mohamed:** Formal analysis; investigation; software; writing – review and editing. **Tekeste Fekadu:** Writing – review and editing.

## ACKNOWLEDGMENT

We thank Dr. Mohamed Elfatih for his help in manuscript revision.

## CONFLICT OF INTEREST

None declared.

## DATA AVAILABILITY STATEMENT


The data are available at the Department of Surgery Oratta Referral Hospital, Asmara, Eritrea.

## CONSENT

Written informed consent was obtained from the patient to publish this report in accordance with the journal's patient consent policy.

## ORCID

Rami Yassin  <https://orcid.org/0000-0002-1325-6449>

Mhmoud Mohamed  <https://orcid.org/0000-0002-6512-7403>

## REFERENCES

1. Nageswaran H, Khan U, Hill F, Maw A. Appendix duplication: a comprehensive review of published cases and clinical recommendations. *World J Surg*. 2018;42:574-581.
2. De PL VE, Bonato LM, Da SGGP, Gurgel JL. Congenital abnormalities and anatomical variations of the vermiform appendix and the mesoappendix. *J Coloproctol*. 2019;39(3):279-287.
3. Christodoulidis G, Symeonidis D, Spyridakis M, et al. Acute appendicitis in a duplicated appendix. *Int J Surg Case Rep*. 2012;3(11):559-562.
4. Travis JR, Weppner JL, Paugh JC II. Duplex vermiform appendix: case report of a ruptured second appendix. *J Pediatr Surg*. 2008;43(9):1726-1728.
5. Nazir S, Bulanov A, Ilyas MIM, Jabbour II, Griffith L. Duplicate appendix with acute ruptured appendicitis: a case report. *Int Surg*. 2015;100(4):662-665.

**How to cite this article:** Yassin R, Mohamed M, Fekadu T. Acute appendicitis with appendix duplicity in Eritrea: A case report. *Clin Case Rep*. 2022;10:e06635. doi: [10.1002/ccr3.6635](https://doi.org/10.1002/ccr3.6635)