

Endourology

Facilitate Stent Removal: Magnetic DJ Stent

Hakan Ozturk



Department of Urology, Medicalpark Izmir Hospital, Yeni Girne Boulevard 1825 St. No: 12, 35350, Karsiyaka, Izmir, Turkey

ARTICLE INFO

Article history:

Received 25 October 2016

Received in revised form

14 November 2016

Accepted 25 November 2016

Keywords:

Ureteral stent

Magnetic DJ stent

Stent removal

ABSTRACT

A 23-year-old male patient was performed semirigid ureterorenoscopy and laser lithotripsy with placement magnetic DJ stent because of right urethral stone. Removal of the magnetic DJ stent does not need a second procedure such as cystoscopy for the patients. This technique is easy to learn and should be considered as suitable for use on an outpatient basis.

© 2017 The Author. Published by Elsevier Inc. This is an open access article under the CC BY-NC-ND license (<http://creativecommons.org/licenses/by-nc-nd/4.0/>).

Double-J stenting is a common procedure in urology because of prophylactic and therapeutic indications. Ureteroscopy is one of the most common methods to treat urinary stones. In many cases, ureteral stent insertion follows ureteroscopy.¹ Removing DJ stent is the most important stage in patients. A loop suture to facilitate removal is easy to use and applicable in women but is not used in men. Cystoscopy is the standard technique used to removal a ureteral stent. After URS, ureteral stents are removed at post-operative 1 or 2 weeks, typically by cystoscopic retrograde removal.

A flexible cystoscopy is a good alternative to rigid cystoscopy to reduce pain during procedure, but flexible cystoscopy is less available in the world. However, rigid cystoscopy is needed for use of foreign body forceps. On the other hand, because of the rigidity and larger diameter of cystoscopes, most patients need analgesia and some patients need deep sedation during the procedure.^{2,3}

Furthermore, it is reported that removal of the stent with local anesthesia is more traumatic than the actual operation.⁴ Therefore, it is obvious that there is need to simpler, more reliable and easy to apply, requiring low-cost cystoscopy for stent removal procedure.

Ureteral stent consists of aliphatic polyurethane with magnets (NdFeB 52) Retrieval device consists of Tiemann-type with 15 Fr diameter and magnet. The method of removing the ureteral stent from the ureter consists of introducing into the bladder a retrieving urinary catheter with a permanent magnet at its tip. Two permanent magnets in the bladder connect, and removal of the catheter follows by extraction. Due to the high magnetization value of

magnetic tips, both two magnetic parts can't be broken up from each other during removal (Fig. 1).

Ureteral stent removal using a magnetic DJ stent with small Tiemann-type magnetic capture devices is considered feasible. Anyway this easy procedure can be applied by a medical student or nurse.⁵

Conflict of interest

None declared.

Acknowledgments

There were no acknowledgements.

References

1. Tang L, Gao X, Xu B, et al. Placement of ureteral stent after uncomplicated ureteroscopy: do we really need it? *Urology*. 2011;78:1248–1256.
2. Wetton CW, Gedroyc WM. Retrograde radiologic retrieval and replacement of double-J ureteric stents. *Clin Radiol*. 1995;50:562–565.
3. Park SW, Cha IH, Hong SJ, et al. Fluoroscopy guided transurethral removal and exchange of ureteral stents in female patients: technical notes. *J Vasc Interv Radiol*. 2007;18:251–256.
4. Al-Hammouri F, Al-Kabneh A. Stenting versus nonstenting after uncomplicated ureteroscopy for lower ureteric stone management. *Calicut Med J*. 2005;3:e6.
5. Altarac S, Vražić M. A new type of ureteral stent will facilitate stent removal. *Eur Urol*. 2012 Jan;61(1):225–226.

E-mail address: drhakanozturk@yahoo.com.tr

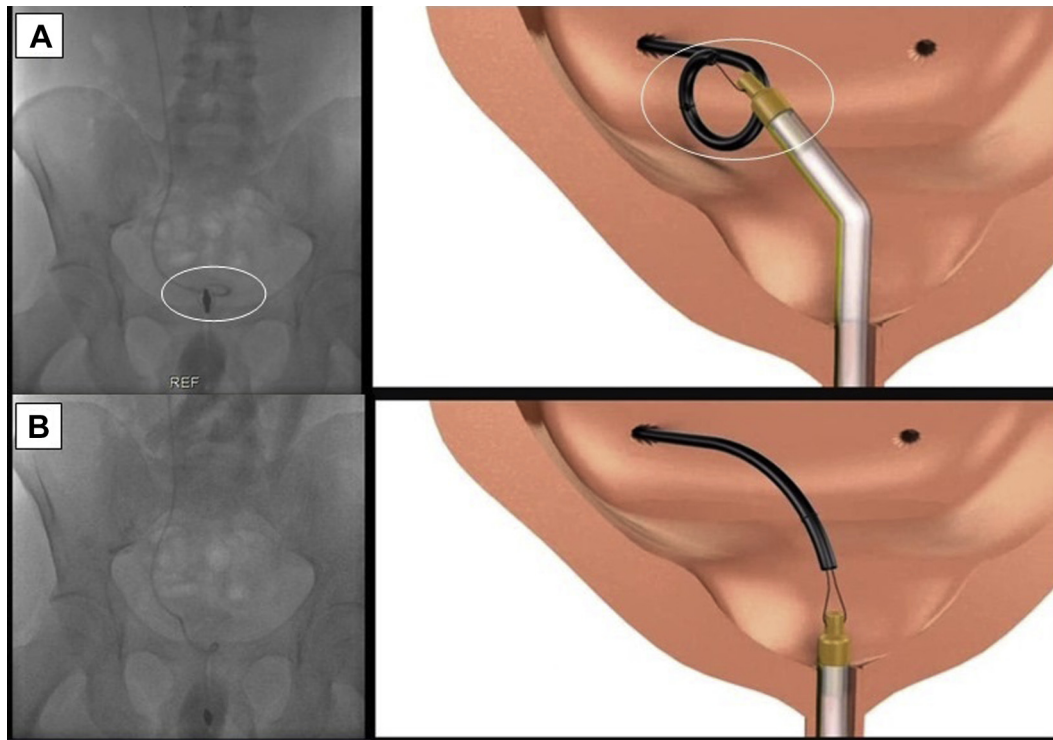


Figure 1. A. Two permanent magnets in the bladder connect. B. Removal of the catheter.