

Anterior release and nonstructural bone grafting and posterior fixation for old lower cervical dislocations with locked facets

Chen Ding, MD, Ting-Kui Wu, MD, Quan Gong, MD, Tao Li, MD, Li-Tai Ma, MD, Bei-Yu Wang, MD, Yu-Xiao Deng, MD, Hao Liu, MD*

Abstract

Lower cervical dislocations are often missed at the time of initial injury for several reasons. The treatment of old facet dislocations of the lower cervical spine is difficult, and the optimal method has not been established. The objective of the present study was to evaluate the clinical outcomes of a surgical technique, anterior release, and nonstructural bone grafting combined with posterior fixation, for the treatment of old lower cervical dislocations with locked facets.

This was a retrospective study of 17 patients (13 men and 4 women) with old facet dislocations, who underwent the same surgical treatment at our hospital between April 2010 and January 2016. The anterior procedure was conducted to remove the fusion mass and to achieve discectomy and morselized bone grafting. Subsequent posterior procedure included release, reduction, and posterior fusion. The neurologic status, clinical data (Japanese Orthopedic Association [JOA], Neck Disability Index [NDI], and Visual Analog Scale [VAS] scores), and radiographic information (local sagittal alignment and bone graft fusion) were recorded and evaluated pre and postoperatively.

All patients achieved a nearly complete reduction intraoperatively. The mean operative time was 178 ± 49 minutes. The mean blood loss was 174 ± 73 mL. Each patient completed at least 12 months of follow-up. The mean follow-up duration was 32.6 ± 18.5 months. The neurologic status according to the Frankel grade was significantly improved at the last follow-up. The JOA, NDI, and VAS scores all demonstrated significant improvements compared with the preoperative values ($P < .05$). The kyphosis angle of the dislocated segments was $10.5 \pm 5.9^\circ$ at preoperation, and was corrected to $5.9 \pm 4.3^\circ$ lordosis postoperatively. Anterior and posterior solid fusion was observed in all patients within 12 months of follow-up. Fat liquefaction and delayed healing of the posterior wound occurred in 1 patient. Cerebrospinal fluid leakage occurred in another patient. There was no neurologic deterioration and no procedure-related complications.

Anterior release and nonstructural bone grafting combined with posterior fixation provides a safe and effective option for treating old lower cervical dislocations with locked facets.

Abbreviations: CT = computed tomography, JOA = Japanese Orthopedic Association, MRI = magnetic resonance imaging, NDI = Neck Disability Index, VAS = Visual Analog Scale.

Keywords: anterior cervical fusion, bone graft, lower cervical spine, old facet dislocations, posterior cervical fusion

1. Introduction

The flexion-distraction forces on the neck may damage the lower cervical spine, sometimes causing unilateral or bilateral facet dislocations.^[1] These are unstable 3-column injuries and increase the risk of neurologic impairment. Emergent intervention

commonly involves closed reduction on skull traction under intensive observation of neurologic status, and operative reduction and fixation via anterior, posterior, or combined approach.^[2–5] The operative strategy is mainly based on whether or not the closed reduction succeeded. Old dislocations of the lower cervical spine (presentation more than 3 weeks after the initial injury) are not rare among cervical spine injuries, especially in developing countries.^[6] The treatment of this kind of old injury is more challenging and different from that of fresh injuries. Also, surgical treatment has been widely accepted. However, only few reports in the English literature concern the management of old lower cervical dislocations, and there is a lack of consensus among them.^[7–9]

In our previous study, we successfully treated 21 cases of acute facet dislocation with traumatic disc herniation by using a new anterior-posterior procedure, anterior decompression, and nonstructural interbody bone graft followed by posterior fixation.^[10] This technique is less risky and eliminates the need for a second anterior approach. It also provides effective decompression, satisfactory reduction, and absolute stability. To confirm the feasibility and utility of our technique for the treatment of old facet dislocations, we presented clinical

Editor: Phil Phan.

The authors report no conflicts of interest.

Department of Orthopedic Surgery, West China Hospital, Sichuan University, Chengdu, Sichuan, China.

* Correspondence: Hao Liu, Department of Orthopedic Surgery, West China Hospital, Sichuan University, No. 37 Guoxue Road, Chengdu, Sichuan 610041, China (e-mail: dr.liuhao6304@hotmail.com).

Copyright © 2017 the Author(s). Published by Wolters Kluwer Health, Inc. This is an open access article distributed under the Creative Commons Attribution-NoDerivatives License 4.0, which allows for redistribution, commercial and non-commercial, as long as it is passed along unchanged and in whole, with credit to the author.

Medicine (2017) 96:46(e8809)

Received: 25 July 2017 / Received in final form: 27 October 2017 / Accepted: 31 October 2017

<http://dx.doi.org/10.1097/MD.0000000000008809>

and radiographic outcomes of 17 consecutive patients in this study.

2. Materials and methods

2.1. Patients' information

The study was approved by the Ethical Committee of West China Hospital, Sichuan University. All patients had signed the informed consent before their data was used for research purposes.

Between April 2010 and January 2016, 17 patients were enrolled in this series according to the following criteria: 1) unilateral or bilateral facet dislocations of the lower cervical spine; 2) the injury was defined as old; 3) a reduction could not be achieved after discectomy by the anterior approach. Patients with acute injuries, vertebral fractures, or severe concomitant diseases were excluded. They were all treated using the proposed procedure at our institution. Thirteen patients were men and 4 were women. The average age at surgery was 45.2 ± 14.6 years (range 17–72 years). The mechanisms of injury included road traffic accident (8 patients), fall from a height (5 patients), sport injury (2 patients), and direct collision of a heavy object (2 patients). The diagnosis was missed in 10 patients. Among them, 4 patients had life-threatening multiple injuries, including severe brain injuries (2 patients) and unstable pelvic fractures (2 patients), and 6 patients did not receive complete imaging assessment at first hospital admission. Two patients gave up seeking medical help because the initial symptoms are slight. The other 5 patients failed closed reduction after prolonged traction lasting more than 3 weeks in local hospitals. The mean interval from the initial injury to surgery was 13.7 ± 14.1 weeks (range 4–54 weeks).

All patients suffered from restricted cervical range of motion and persistent neck pain. Neurologic status on admission is highly variable. According to the Frankel scale, 1 patient was graded as A, 3 as B, 5 as C, 6 as D, and 2 as E. Preoperative imaging studies included static and dynamic plain radiographs, reconstructive computed tomography (CT), and magnetic resonance imaging (MRI). The most common level of dislocation was C6–C7 (6 patients), followed by C5–C6 (5 patients), C4–C5 (3 patients), C7–T1 (2 patients), and C3–C4 (1 patients). Of the 17 patients, 10 patients were unilateral facet dislocations, whereas 7 patients were bilateral facet dislocations. MRI confirmed a traumatic disc herniation at the affected level in 8 patients.

For 3 patients treated in 2010, skull traction (the weight ranged between 6 and 10 kg) was applied and maintained for more than 1 week; however, closed reduction failed in all of these patients. For the other patients, closed reduction was not attempted because a long time had passed since the accident and there were signs of bony fusion or facet remodeling at the dislocated segments on CT scans (Fig. 1).

2.2. Operative technique and postoperative treatment

Trachea traction exercise was regularly performed after hospitalization. Prophylactic antibiotics were administered 30 minutes before surgery. The operations were performed by the same senior surgeon (HL), as previously described.^[10] The patients were placed in the supine position under general anesthesia. A roll was placed beneath the shoulders and another beneath the iliac crest donor site to facilitate the operative

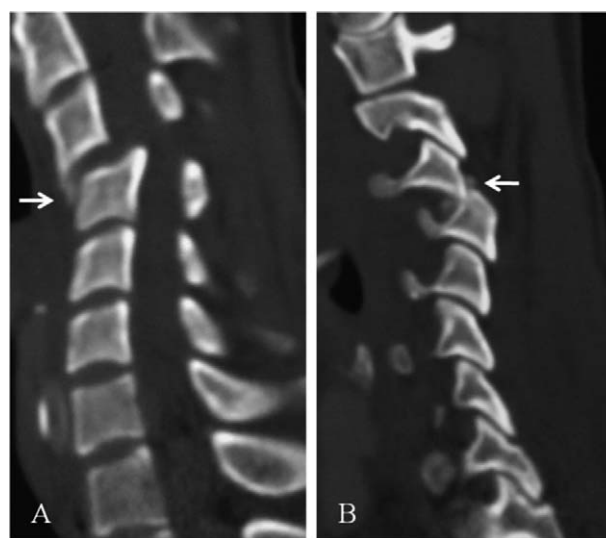


Figure 1. A 36-year-old male patient presenting 12 weeks after injury with C3–C4 dislocation. (A and B) The sagittal reconstruction CT images showed signs of bony fusion between the adjacent vertebral bodies and around the locked facets (the arrow). CT = computed tomography.

manipulation. The injured spinal segments were exposed through a standard Smith-Robinson anterior cervical approach. The fibro-cartilaginous tissue or bony callus was removed from the anterior surface of the involved vertebral bodies. A discectomy was carried out, and the disc space was distracted 1 to 3 mm by a Caspar distractor to restore a normal disc height. Meanwhile, the distraction allowed a partial correction of kyphosis. Then, an anterior release was achieved by removal of residual disc material and resection of fibro-cartilaginous tissue and osteophytes around deformed uncovertebral joints. The posterior longitudinal ligament was broken in 9 of the 17 patients, and it was resected in each patient to ensure thorough decompression. The vertebral endplates were carefully prepared to be even to accept the autologous graft. Before the bone graft, a piece of absorbable gelatin sponge is gently placed into posterior one-third of the disc space to protect the exposed dura and prevent the excursion of the graft. Then morselized cancellous bone grafts harvested from the iliac crest was compressed into anterior two-thirds of the disc space, to restore the disc height and lordosis. Care was taken to keep the grafts flush with the anterior surface of the inferior vertebral body. The grafts were then covered by another piece of gelatin sponge, which was stitched carefully onto the longus colli muscle on both sides. Thus, the grafts were encapsulated by 2 pieces of gelatin sponge, while permitting the segmental translation and angulation required by a posterior reduction. The anterior incision was drained and closed in the standard manner.

The patients were then placed carefully in the prone position with a Mayfield head holder. A posterior midline incision and approach was made to expose the posterior elements of the relevant segments, including the lateral masses. The locked facets were characteristically enveloped by fibro-cartilaginous tissue. In 8 of 17 patients, there was partial bony fusion between the facets. The scar tissues and a portion of the inferior vertebra facets were removed to facilitate reduction. The dislocation was reduced by applying a distraction force between the spinous processes gradually and translating the proximal dislocated segment

posteriorly. During the procedure, fluoroscopy was used to verify the appropriate position of the grafts and successful reduction. After that, lateral mass screws were inserted after Magerl method, and the rods were secured on the screws. Adequate morselized cancellous bone was used for posterior element fusion in all patients. The incision was washed repeatedly and closed with a drainage tube.

After surgery, the drainage tubes were conventionally removed within 72 hours. Intravenous antibiotics were continued for 48 to 72 hours. The patients were mobilized in a custom-built collar for 12 weeks.

2.3. Data collection

The surgical data, including operative time, blood loss, and length of hospital stay, were noted. Outcome data were collected preoperatively and at 1 week, 3, 6, 12 months postoperatively, and every 2 years thereafter. The neurologic function was assessed using the Frankel grade and the Japanese Orthopedic Association (JOA) score. JOA recovery rate at the last follow-up was calculated using the equation: $(\text{postoperative score} - \text{preoperative score}) / (17 - \text{preoperative score}) \times 100\%$. The Neck Disability Index (NDI) was used to measure how much the neck pain affects a patient's ability to manage daily activities. The Visual Analog Scale (VAS) was used to evaluate the neck pain. Radiographic evaluation included anteroposterior and lateral radiographs, and CT scans. The segmental kyphosis/lordosis was measured from the angle between the cranial endplate of the superior vertebra and the caudal endplate of the inferior vertebra in the lateral radiograph. Based on radiographs and CT scans, successful fusion was defined as the formation of bridging trabecular bone across the interface of graft-vertebral body, no signs of instrumentation failure, and less than 50% radiolucency covering the outer surface of the bone graft.^[11] The radiographic assessments were done by 2 independent spine surgeons (QG and BW). In case of disagreement on solid fusion, a third independent surgeon (TL) was consulted, and consensus was achieved by discussion.

2.4. Statistical analysis

Statistical analysis was performed using SPSS version 17.0 software (SPSS Inc, Chicago, IL). Continuous variables were expressed as mean \pm standard deviation (SD). Preoperative data and follow-up data were compared using paired *t* tests. A value of $P < .05$ was considered statistically significant.

3. Results

Nearly anatomic reduction and sagittal alignment was achieved by this anterior-posterior procedure in all patients. Posterior single level fixation was performed in 10 patients with unilateral facet dislocations. Also, the long-segment fixation, with 1 segment above and 1 segment below fixed, was used in 7 patients with bilateral dislocations. The operative time averaged 178 ± 49 minutes (range 130–270 minutes). The intraoperative blood loss averaged 174 ± 73 mL (range 80–350 mL). Length of hospital stay averaged 12.8 ± 6.6 days (range 7–30 days). The mean follow-up duration was 32.6 ± 18.5 months (range 12–74 months). The patients' neurologic function get better over time. Of the 15 patients with preoperative neurologic impairment, 11 patients (73.3%) recovered at least 1 Frankel grade and 2 patients (13.3%) recovered 2 Frankel grade at the last follow-up.

Table 1

Change of the Frankel scale (preoperative to the last follow-up).

Preoperative	Last follow-up				
	A	B	C	D	E
A (n=1)			1		
B (n=3)		1	1	1	
C (n=5)			1	4	4
D (n=6)				2	2
E (n=2)					

However, 4 patients did not show any neurologic improvement during the follow-up (Table 1).

The JOA score was 7.5 ± 5.4 before surgery, 10.1 ± 4.3 at 1 week after surgery, and 12.4 ± 4.6 at the last follow-up ($P < .05$). The final recovery rate was 51.6%. NDI and VAS scores also decreased significantly at 1 week after surgery and further decreased at the last follow-up ($P < .05$) (Table 2). The local sagittal alignment at the dislocated segment was $10.5 \pm 5.9^\circ$ kyphosis preoperatively. At 1-week follow-up, it was corrected to $5.9 \pm 4.3^\circ$ lordosis and remained at $5.5 \pm 3.9^\circ$ at the last follow-up ($P > .05$) (Table 2). No instrumentation failure was found and solid fusion was obtained in all patients at 12 months follow-up. A typical case is shown in Fig. 2. Fat liquefaction without evidence of infection occurred in 1 patient. The posterior wound was treated by repeated debridement, and healing was delayed for 2 weeks. Cerebrospinal fluid (CSF) leakage was detected intraoperatively in another patient, and solved by surgical repair, effective drainage, and bed rest. There was no neurologic deterioration and no procedure-related complications during the follow-up period.

4. Discussion

Cervical spine injuries are easily missed at the initial evaluation. More than 30 years ago, Bohlman^[12] reported that of 300 patients with severe cervical spinal injuries, 100 were not recognized initially. A retrospective study published by Platzer et al^[13] in 2006 showed an incidence of delayed diagnosis of 4.9%. Also, most of the old injuries involve the lower cervical spine. With the development of radiologic technology, the missed or delayed diagnosis happened less frequently in recent years, but is still a problem for spine surgeons. The delayed diagnosis has been attributed to various reasons in previous studies, including radiologic misreading, inadequate images, multiple injuries, inappropriate initial treatments, or absence of symptoms at the first presentation.^[13,14] With regard to the causes of delayed diagnosis in our series of old facets dislocations, inadequate images were responsible in 35% of patients, ineffective initial treatments were responsible in 29%, serious concomitant injuries

Table 2

The clinical and radiographic data before versus after surgery.

Time points	JOA	NDI	VAS	Lordosis/kyphosis ($^\circ$)
Preoperative	7.5 ± 5.4	32.9 ± 9.9	5.7 ± 2.1	—/ 10.5 ± 5.9
1-week follow-up	$10.1 \pm 4.3^*$	$26.4 \pm 6.4^*$	$3.1 \pm 1.4^*$	$5.9 \pm 4.3/—$
Last follow-up	$12.4 \pm 4.6^{*,\dagger}$	$18.5 \pm 6.8^{*,\dagger}$	$1.5 \pm 0.9^{*,\dagger}$	$5.5 \pm 3.9/—$

JOA=Japanese Orthopedic Association, NDI=Neck Disability Index, VAS=Visual Analog Scale.

* Statistically significant difference ($P < .05$) between pre and postoperative scores.

† Statistically significant difference ($P < .05$) between scores at 1-week and last follow-up.

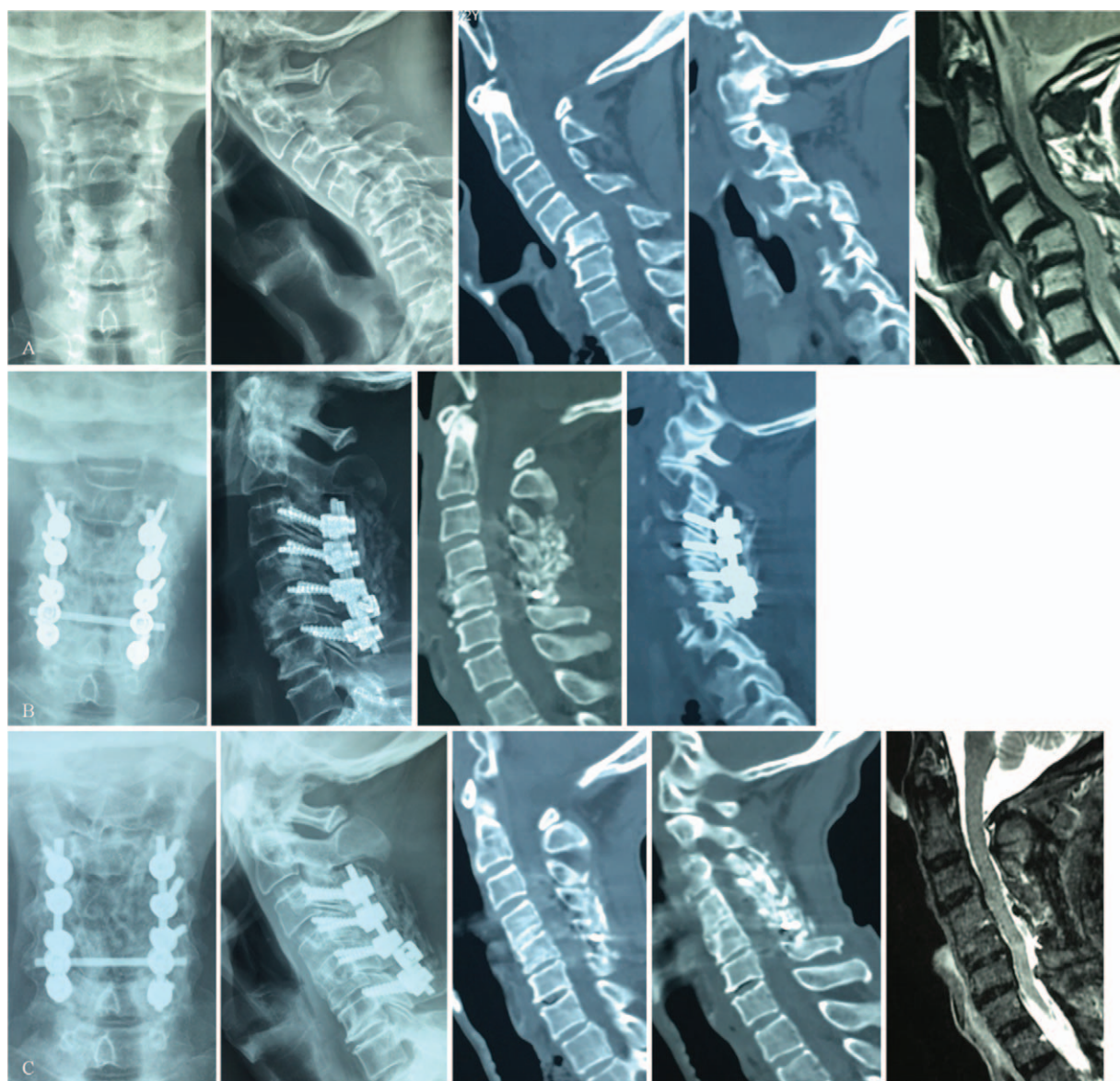

Figure 2. A 72-year-old male patient suffered from a fall injury. The diagnosis was delayed for 8 months because he just had mild neck pain after the accident. (A) Preoperative radiographs and sagittal reconstruction CT demonstrated C4–C5 dislocation with bilateral locked facets and remodeling of the facets. The MRI indicated obvious compression of the spinal cord. (B) At 1 week after surgery, radiographs and CT images showed perfect restoration of the dislocated segments and adequate amount of bone graft. (C) At 15 months of follow-up, the radiographs and CT images confirmed the anterior and posterior fusion. The CT and MRI images revealed enlarged spinal canal at C4–C5 level. CT=computed tomography, MRI=magnetic resonance imaging.

were responsible in 24%, and neurologic integrity accounted for the remaining 12%. Detailed medical history and careful physical examination must be emphasized for patients with suspected cervical spine injuries. Patients with neck pain, local tenderness, or restricted range of motion should be advised to receive more extensive radiologic examinations, such as dynamic radiographs, CT scan, and MRI.^[15]

Closed reduction has been proven helpful for patients with acute facet dislocations. But in the literature, there was a large difference among the success rates of closed reduction for old dislocations. In Basu et al's^[16] series, 10 of 14 patients with unilateral facet dislocations and 1 of 5 patients with bilateral facet dislocations (a mean delay of 7 days) were successfully reduced with skull traction (58%). However, Kahn et al^[14] reported that the success rate of closed reduction for patients

presenting with delayed cervical facet dislocation (at least 72 hours) is only 20%, compared with 64% in acute dislocations. In another group of old cervical dislocations with a mean delay of 114.9 days, skull traction was used in 9 patients with moderate spinal stenosis, and not attempted in 5 with severe spinal stenosis.^[17] The reduction was achieved in only 1 patient before surgery and in 2 patients with the increase of traction weight during surgery. It has been generally accepted that, in patients with old dislocations, closed reduction would be resisted by the fibrous tissue or bony callus around the dislocated segments. In consideration of the low success rate, poor tolerance, and related morbidity, closed reduction was discarded after 2010 in our study.

A combined procedure, which releases the anterior and posterior links and unlocks the facet joints, is an inevitable

choice for irreducible dislocations. Although only few published studies pay attention to the old facet dislocations of the lower cervical spine, several different approaches have been adopted. Hassan^[9] reported the surgical treatment of 10 patients with old facet dislocations who failed closed reduction. A posterior release was performed in all 10 patients, and surgical reduction was achieved in only 1 patient, who thus underwent a lateral mass fusion with plate-screw fixation. The other 9 patients had to receive another 1-week traction and the following anterior fusion. The multistage procedure was safe, but led to 2 different surgeries, 2 weeks of traction, and a long hospital stay. Bartels and Donk^[18] used an anterior-posterior-anterior procedure in 2 cases, but failed to reduce the old dislocations. Also, they were obliged to conduct a fourth posterior procedure. A posterior-anterior-posterior procedure was attempted which was successful in the third case. So, they suggested that the latter is recommended for this old injury. Payer and Tessitore^[8] and Farooque et al^[19] described satisfactory results with anterior-posterior-anterior procedure for reduction in 1 and 2 such patients, respectively. They stated that it has an advantage of less times of postural change when compared with the posterior-anterior-posterior approach. Liu et al^[7] and Jain et al,^[20] in the treatment of 9 and 4 patients, respectively, introduced a 2-stage posterior-anterior procedure, which is probably less invasive and risky than the above mentioned 3-stage procedures. The posterior procedure mainly consists of contracted tissue release, facetectomy, partial reduction, and interspinous wire fixation. Decompression, final reduction, and stabilization was accomplished through the following anterior approach. It has been proven that anterior instrumentation provides less stability than posterior fixation.^[21,22] That is a potential problem of this posterior-anterior procedure. Moreover, in Liu et al's series, 1 patient with bilateral facet dislocation at the C6–C7 level encountered a partial loss of reduction 3 months after surgery. Moreover, Allred and Sledge^[1] proposed an anterior-posterior procedure, which is similar to ours, for the treatment of irreducible cervical dislocations with a prolapsed disc. However, the involved tricortical bone graft may be oversized and become a hindrance to anatomic reduction. The anterior plate is not for stabilization and may result in dysphasia. Also, the fixation strength provided by the interspinous wire is not sufficient.

Our technique only has 2 stages, and certainly minimizes the surgical risks, operative time, blood loss, hospital stays, and increases the cost-benefit, when compared with the multistage or 3-stage procedures. And apparently, our procedure is technically less demanding than that of Allred Sledge. We used a morselized cancellous autograft for anterior fusion. The graft is simply encapsulated in the disc space by 2 pieces of gelatin sponge. It moves under the control of gelatin sponge, thus allowing the segmental translation and angulation during the posterior reduction. In the current study, anatomic or nearly anatomic reduction was attained in all patients, the segmental alignment was kyphotic before surgery and become lordotic after surgery. Morselized cancellous grafts has a faster vascularization and a higher porosity than cortical grafts, which theoretically increases the fusion rate.^[23] In addition, the biomechanical property of morselized cancellous grafts has been testified by our previous study.^[10] Accordingly, both anterior and posterior fusion was observed in our series. We also deem that our procedure shows superiority over the posterior-anterior procedure, especially when the old dislocation is accompanied by a prolapsed disc. In the posterior-anterior procedure, attempting partial reduction posteriorly

without anterior release and decompression is difficult, and increases the risk of cord compression by the prolapsed disc. Also, it has been reported that posterior reduction maneuver may aggravate the spinal cord injury in patients with severe spinal stenosis.^[24] Our procedure is more secure, because the posterior reduction is attempted only after discectomy and decompression is accomplished. On the contrary, the lateral mass screw-rod system provides a higher stability than the anterior plate. There was no neurologic deterioration in our group. The lordotic alignment was well-maintained and no loss of reduction was found during the follow-up. The good clinical outcomes should be ascribed to thorough decompression, successful reduction, rigid fixation, and solid fusion.

Several limitations exist in our study. First of all, in 7 patients with bilateral facet dislocations, the application of long-segment fixation sacrificed the motion of adjacent segments. The reason for this is that a more rigid fixation is needed to prevent redislocation in patients with severe dislocations. Second, it is a retrospective, single-center study with a small sample size, which may affect the statistical validity. And we cannot directly compare our technique with others without a control group. Therefore, further studies with large sample size and long-time follow-up are needed to verify our results.

5. Conclusions

Old lower cervical dislocations with locked facets are not rare, and closed reduction is hardly achieved. Anterior release and nonstructural bone grafting combined with posterior fixation provides a safe and effective option for the treatment of this old injury.

References

- [1] Allred CD, Sledge JB. Irreducible dislocations of the cervical spine with a prolapsed disc: preliminary results from a treatment technique. *Spine (Phila Pa 1976)* 2001;26:1927–30. [discussion 1931].
- [2] Lee JY, Nassr A, Eck JC, et al. Controversies in the treatment of cervical spine dislocations. *Spine J* 2009;9:418–23.
- [3] Jiang X, Yao Y, Yu M, et al. Surgical treatment for subaxial cervical facet dislocations with incomplete or without neurological deficit: a prospective study of 52 cases. *Med Sci Monit* 2017;23:732–40.
- [4] Nakashima H, Yukawa Y, Ito K, et al. Posterior approach for cervical fracture-dislocations with traumatic disc herniation. *Eur Spine J* 2011;20:387–94.
- [5] Del Curto D, Tamaoki MJ, Martins DE, et al. Surgical approaches for cervical spine facet dislocations in adults. *Cochrane Database Syst Rev* 2014;CD008129.
- [6] Davis JW, Phreaner DL, Hoyt DB, et al. The etiology of missed cervical spine injuries. *J Trauma* 1993;34:342–6.
- [7] Liu P, Zhao J, Liu F, et al. A novel operative approach for the treatment of old distractive flexion injuries of subaxial cervical spine. *Spine (Phila Pa 1976)* 2008;33:1459–64.
- [8] Payer M, Tessitore E. Delayed surgical management of a traumatic bilateral cervical facet dislocation by an anterior-posterior-anterior approach. *J Clin Neurosci* 2007;14:782–6.
- [9] Hassan MG. Treatment of old dislocations of the lower cervical spine. *Int Orthop* 2002;26:263–7.
- [10] Feng G, Hong Y, Li L, et al. Anterior decompression and nonstructural bone grafting and posterior fixation for cervical facet dislocation with traumatic disc herniation. *Spine (Phila Pa 1976)* 2012;37:2082–8.
- [11] Song KJ, Taghavi CE, Lee KB, et al. The efficacy of plate construct augmentation versus cage alone in anterior cervical fusion. *Spine (Phila Pa 1976)* 2009;34:2886–92.
- [12] Bohlman HH. Acute fractures and dislocations of the cervical spine. An analysis of three hundred hospitalized patients and review of the literature. *J Bone Joint Surg Am* 1979;61:1119–42.
- [13] Platzer P, Hauswirth N, Jaendl M, et al. Delayed or missed diagnosis of cervical spine injuries. *J Trauma* 2006;61:150–5.

- [14] Kahn A, Leggon R, Lindsey RW. Cervical facet dislocation: management following delayed diagnosis. *Orthopedics* 1998;21:1089–91.
- [15] Sengupta DK. Neglected spinal injuries. *Clin Orthop Relat Res* 2005;93–103.
- [16] Basu S, Malik FH, Ghosh JD, et al. Delayed presentation of cervical facet dislocations. *J Orthop Surg (Hong Kong)* 2011;19:331–5.
- [17] Jiang X, Cao Y, Yao Y, et al. Surgical management of old lower cervical dislocations with locked facet. *Clin Spine Surg* 2016;29:E319–324.
- [18] Bartels RH, Donk R. Delayed management of traumatic bilateral cervical facet dislocation: surgical strategy. Report of three cases. *J Neurosurg* 2002;97(3 suppl):362–5.
- [19] Farooque K, Khatri K, Gupta B, et al. Management of neglected traumatic bilateral cervical facet dislocations without neurological deficit. *Trauma Mon* 2015;20:e18385.
- [20] Jain AK, Dhammi IK, Singh AP, et al. Neglected traumatic dislocation of the subaxial cervical spine. *J Bone Joint Surg Br* 2010;92:246–9.
- [21] Kim SM, Lim TJ, Paterno J, et al. A biomechanical comparison of three surgical approaches in bilateral subaxial cervical facet dislocation. *J Neurosurg Spine* 2004;1:108–15.
- [22] Bozkus H, Ames CP, Chamberlain RH, et al. Biomechanical analysis of rigid stabilization techniques for three-column injury in the lower cervical spine. *Spine (Phila Pa 1976)* 2005;30:915–22.
- [23] Buttermann GR, Glazer PA, Bradford DS. The use of bone allografts in the spine. *Clin Orthop Relat Res* 1996;75–85.
- [24] Mahale YJ, Silver JR, Henderson NJ. Neurological complications of the reduction of cervical spine dislocations. *J Bone Joint Surg Br* 1993;75:403–9.