

# Predictive Factors of Keloid Formation in Congenital Foot Syndactyly

Sang Ho Oh, MD  
Sang Hyun Woo, MD, PhD

**Background:** Keloid formation after syndactyly division is a stressful situation for patients. In our experience, digital enlargement may be involved in keloid formation following syndactyly divisions. Therefore, we aimed to identify predictive factors and reference values for keloid formation.

**Methods:** In this retrospective study, 11 keloid patients (seven children, four adults) and 11 nonkeloid patients after syndactyly division (control group) with the same sex, age, webspace division site, and operation were enrolled between 2008 and 2020. Using preoperative x-ray images, we compared bony width, length, area, and protruding index relative to the great toe between keloid and control groups. Additionally, reference values for keloid formation were obtained using receiver operating characteristic curves. Statistical analysis was performed using Spearman's correlation test.

**Results:** When compared with the same digit in the normal foot, distal phalanx (P3) bony base width, area, and protruding index on keloid foot were significantly different between keloid group and control group. The reference values for keloid formation after syndactyly release were 1.34 for the P3 area ratio and 1.61 for the P3 triangular area ratio (using the horizontal length of the P3 base and P3 vertical length). The reliability of reference values for the P3 area ratio and P3 triangular area ratio was excellent for all patients.

**Conclusions:** If digital enlargement in distal phalanx is present when compared with adjacent toe in patients who had undergone primary foot syndactyly divisions, risk of keloid development should be communicated preoperatively, and preventive strategies for keloid development and close observations are required. (*Plast Reconstr Surg Glob Open* 2021;9:e3946; doi: [10.1097/GOX.0000000000003946](https://doi.org/10.1097/GOX.0000000000003946); Published online 29 November 2021.)

## INTRODUCTION

Keloids are a fibroproliferative disease of the skin.<sup>1</sup> They involve normal skin, have a strange appearance, and induce pain or an itching sensation. Many studies have been conducted to identify the keloid formation mechanism and effective treatments.<sup>2,3</sup> However, the mechanism of keloid formation is still unclear, and there is no established treatment method for keloids.<sup>4</sup>

At our institute, we have seen a few keloid patients after foot syndactyly division (Fig. 1). The keloid scars formed

after foot syndactyly division make large and unusual scars on the webspace, resulting in syndactyly recurrence, a significantly stressful situation for the patient and their guardians. If the keloid develops without the patients and guardians having received a detailed explanation of such risk preoperatively, they would not understand the cause of keloid formation and the need for additional surgery.

Fortunately, keloid formation after foot syndactyly division is significantly rare, and there are few cases reported in the literature.<sup>5-10</sup> However, once the keloid occurs, it continuously progresses, and operative results can be detrimental. Therefore, if an anticipatory tool for keloids is available, it would allow surgeons, patients, and guardians to prepare for keloid formation. According to a previous study, digital enlargement may be involved with keloid formation following syndactyly divisions.<sup>7</sup> Conventionally, the larger digit means a larger width and longer length. Therefore, based on prior case reports and our own experience, we believe that not only digital enlargement but also digital protrusion is associated with keloid formation.<sup>5-10</sup>

From the W Institute for Congenital Deformity of the Extremities, W Institute for Hand and Reconstructive Microsurgery, W General Hospital, Daegu, South Korea.

Received for publication July 21, 2021; accepted September 28, 2021.

Copyright © 2021 The Authors. Published by Wolters Kluwer Health, Inc. on behalf of The American Society of Plastic Surgeons. This is an open-access article distributed under the terms of the [Creative Commons Attribution-Non Commercial-No Derivatives License 4.0 \(CCBY-NC-ND\)](https://creativecommons.org/licenses/by-nc-nd/4.0/), where it is permissible to download and share the work provided it is properly cited. The work cannot be changed in any way or used commercially without permission from the journal.

DOI: [10.1097/GOX.0000000000003946](https://doi.org/10.1097/GOX.0000000000003946)

**Disclosure:** The authors have no financial interest to declare in relation to the content of this article.

Therefore, we hypothesized that keloid formation would be associated with digital enlargement and digital protrusion, and we aimed to identify the predictive factors and reference values for keloid formation following syndactyly division.

## PATIENTS AND METHODS

Before this retrospective case-control study was conducted, the experimental plan was approved by the institutional review board of our medical centers. Patients provided informed consent for the publication of the clinical photographs in this article.

### Patients

A total of 272 primary simple foot syndactyly cases were recorded from 2008 to 2020. The inclusion criterion was patients who underwent primary simple foot syndactyly division from 2008 to 2020 in our institute. The exclusion criteria were (1) patients with other foot deformities or anomalies, such as syndromic disease, and (2) patients with a family history of keloids. After the participants were selected, gender, age, webspace division site, and surgery were provided from electrical medical records. The patients with a keloid at the operative site were classified as the keloid group. Conversely, we also selected a “control group” of patients that matched with keloid group based on gender, age, webspace division site, and surgery received.

### Surgical Technique and Postoperative Managements

The procedure was performed on patients by a single plastic surgeon. Conventional dorsal rectangular flaps, volar triangular flaps, and skin grafts were used for syndactyly division in all patients. After flap elevation, defatting was performed under the subdermal layer without compromising flap circulation. After flap inseting, the remaining raw surface was measured and the full-thickness skin graft was harvested sufficiently to cover the raw surface without tension around flap margin from the ipsilateral plantar area. During flap and skin graft inseting, tension-free sutures were important. Mild compressive

### Takeaways

**Question:** Keloid formation is the one of the most disastrous complications after syndactyly division. However, the mechanism of keloid formation is still unclear. Therefore, we aim to identify predictive factors of keloid formation after syndactyly divisions.

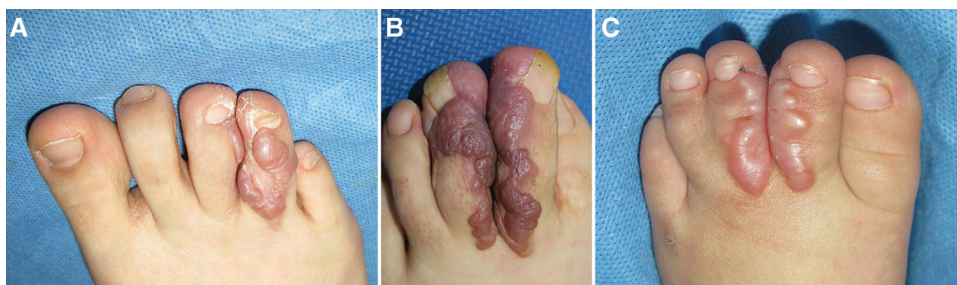
**Findings:** With a retrospective study, distal phalanx bony width, area, and protruding index on the keloid foot were significantly different compared with the normal foot. In these factors, the distal phalanx area was the most reliable factor for predicting keloid formation.

**Meaning:** If the distal phalanx shows digital enlargement, the risk of keloid development should be communicated preoperatively to the patients, and preventive strategies for keloid development and close observation are required.

dressings were placed over the skin graft. During postoperative management, leg elevation and hyperbaric oxygen therapy were performed until 2 weeks postoperatively. Foot elevation resolved the fluid collection under the skin graft, and hyperbaric oxygen therapy increased the skin graft survival rate.

### Measurement and Statistical Analyses

Our study measurements were conducted using a preoperative x-ray. We obtained a foot standing anteroposterior view preoperatively, and this x-ray was used for the analysis because of the synchronization of the foot position. We named the distal phalanx “P3,” the middle phalanx “P2,” the proximal phalanx “P1,” the medial side of the digit in the webspace the “tibial side,” and the lateral side of the digit in the webspace the “fibular side.” In both feet, the foot with syndactyly was referred to as the “affected foot,” whereas the opposite foot without syndactyly was referred to as the “normal foot.” We subsequently investigated the digital enlargement and protrusion. First, digital enlargement was analyzed using bony width, length, and area. Second, digital protrusion was analyzed using protrusion length relative to the great toe. We used



**Fig. 1.** Cases of keloid formation following syndactyly division. A, An 18-year-old woman complained of a painful scar with a strange appearance at 5 months postoperative, which indicates the onset of keloid scar formation. B, A 20-year-old woman shows erythematous changes in the scar at 2 months postoperative, and the onset of the keloid scar formation was observed at 5 months postoperative. C, A 15-month-old boy showing signs of keloid scar formation in the webspace at 6 months postoperative.

the great toe as a reference because it is the most static toe (unchanged according to the position of the foot), whereas the other toes can be easily flexed or clawed when in a standing position. We compared these measurements with the same digit on the other foot in both the keloid and control groups.

The measurement of the bony width, length, and area was performed using ImageJ 1.45s (Wayne Rasband, National Institutes of Health, USA). Statistical analyses were performed on the ratio of the affected foot to the normal foot.

### Digital Enlargement

**Bony width (horizontal length):** we measured the bony width at the base of the distal phalanx and the center of distal phalanx. The horizontal lengths of the tibial and the fibular sides of the toe on the affected and normal feet were measured, and we averaged the values of the tibial and fibular sides. Subsequently, the ratio of the affected foot to the normal foot was calculated and referred to as the “width ratio” (Fig. 2).

**In calculating bony length (vertical length),** each length is both the longest length of the radiopaque area on the x-ray and half of the length of radiolucent area on the x-ray. Measurements of both tibial and fibular sides on the affected and normal feet were obtained, and we calculated the average for the tibial and fibular sides. Subsequently, the ratio of the affected foot to the normal foot was calculated and referred to as the “length ratio” (Fig. 2).

The bony area (area width) is defined as the sum of the width of the radiopaque area on the x-ray and half the width of the radiolucent area on the x-ray (Fig. 2).

Measurements of both the tibial and fibular sides on the affected and normal feet were obtained, and we summed the tibial and fibular sides. Subsequently, the ratio of the affected foot to the normal foot was calculated and referred to as the “area ratio P3, P2, and P1.” However, it is difficult to accurately and directly measure the width in a clinical situation. Considering that the bony shapes of P1 and P2 are usually square and that of P3 is triangular, if they showed a statistical correlation with keloid formation after syndactyly division, the analysis was performed by obtaining the area width of the triangle or square using the longitudinal length of the phalangeal bone base and the vertical phalangeal bone length in only the radiopaque area (Fig. 2).

The area following the removal of the bony area from each phalangeal portion is defined as the soft tissue area. Each phalangeal area is divided based on the center of the radiopaque area of each joint (PIPJ and DIPJ) (Fig. 3).

### Digital Protrusion

To measure the protrusion length relative to the great toe (protruding index), we measured the protrusion lengths of the tibial and fibular sides of the toe compared with the great toe tip, based on soft tissue opacity (Fig. 4). The tibial and fibular protrusion lengths were measured respectively, and the average protrusion lengths for both

sides were calculated and referred to as the “protruding index.” The measurement was performed on both feet of the same digits. If the toe was longer than the great toe, the protrusion length value was positive, whereas if the toe was shorter than the great toe, the protrusion length value was negative. Subsequently, the ratio of the affected side to the normal side was calculated and referred to as the “protruding ratio.”

### Statistical Analyses

A Spearman’s correlation test was performed for each index to analyze whether there was a statistically significant difference between the keloid and control groups, and whether each of their index and keloid formation after syndactyly division was positively or negatively correlated. If the correlation was statistically significant ( $P < 0.05$ ) and the correlation coefficient was positive, then the index in question was significantly positively correlated with keloid formation after syndactyly division. Similarly, a statistically significant negative correlation coefficient would indicate that the index in question was significantly negatively correlated with keloid formation after syndactyly division. Additionally, if an index was significantly correlated, receiver operating characteristic (ROC) curves (SPSS 19.0, IBM, Armonk, N.Y.) were created, and the cut-off value was identified. In an ROC curve, the cut-off value was defined as a point with the highest sensitivity and specificity values, which represents the reference values of bony width, length, area, and protruding index for predicting keloid formation after syndactyly division.

## RESULTS

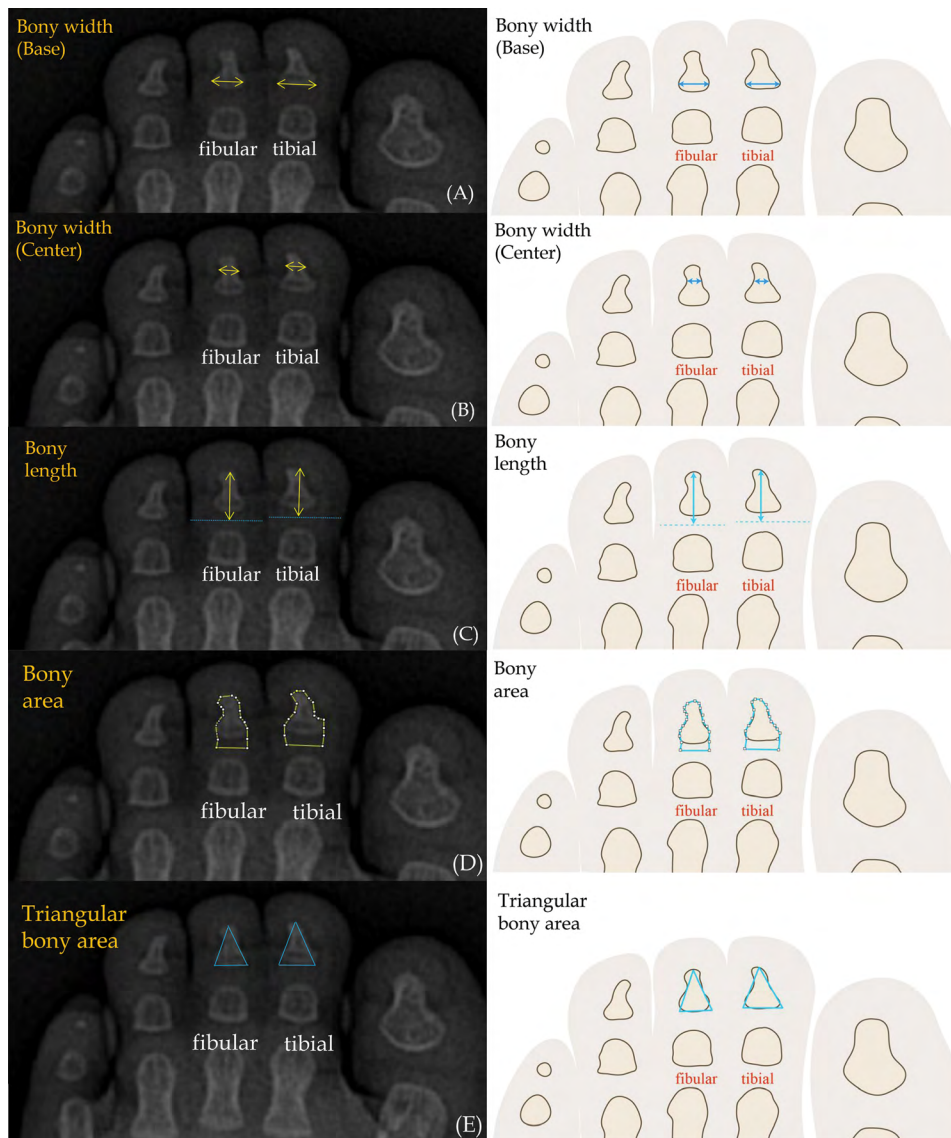
### Patient Demographics and Statistical Analyses

In our institute, 11 (4% of total 272 primary foot simple syndactyly patients) postsyndactyly division keloid patients (seven children and four adults) were enrolled. The 11 keloid cases included one incomplete and 10 complete cases. The incomplete case was a nearly complete type that showed the toe merged until midpoint of toe nail. Table 1 shows the patient demographics. After matching to the keloid group by gender, age, syndactyly location, and operation, 11 patients were selected for the control group. Each group comprised seven young children (aged under 2 years) and four adults. As the ROC curve requires more than seven patients for reliable analysis, we performed this analysis separately in only the pediatric group. Tables 2 and 3 show the results of the statistical analyses.

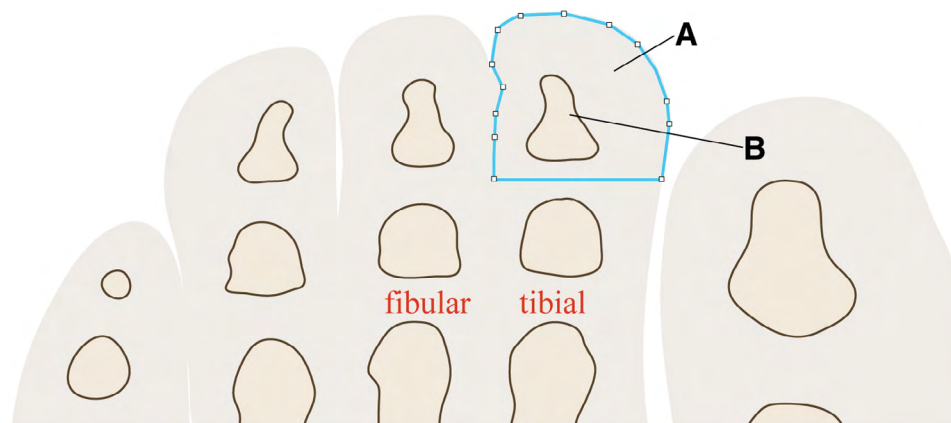
### Digital Enlargement

Regarding bony width (horizontal length), Spearman’s correlation test showed that P3 base and center width ratios were significantly different between keloid and control groups ( $P < 0.01$ ). Additionally, the correlation coefficient was positive, indicating that the P3 base and center width ratios were positively correlated with keloid formation after syndactyly division. In the pediatric group, the

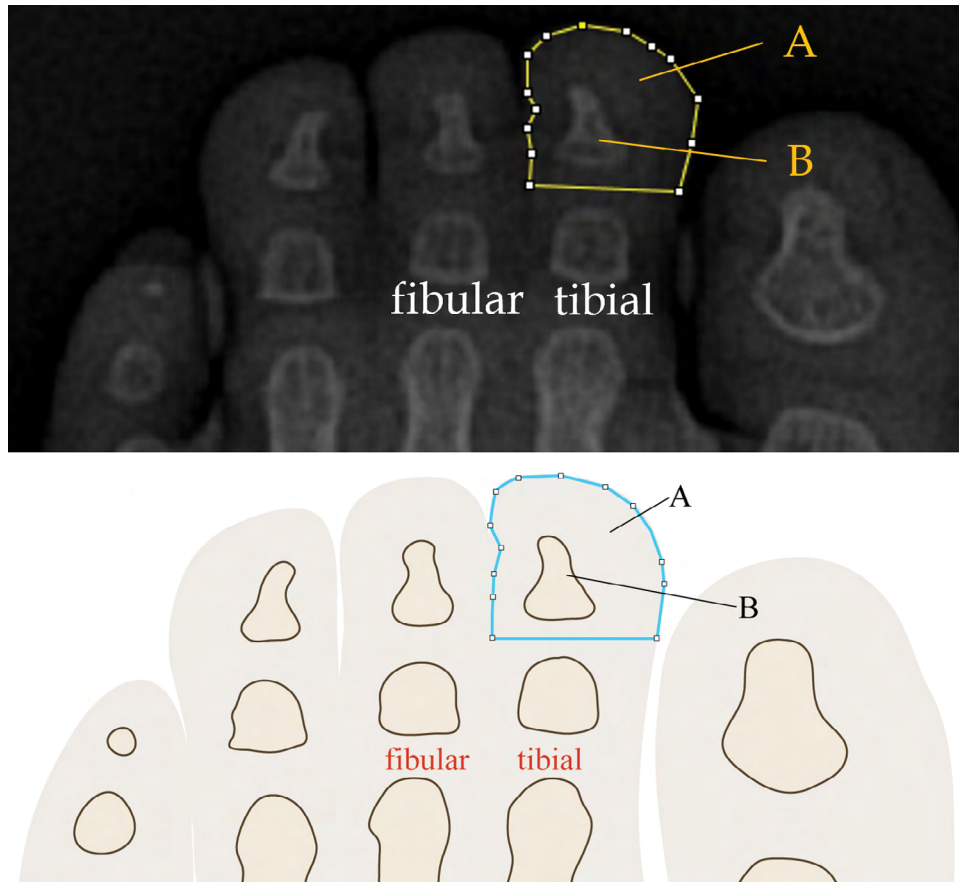




**Fig. 2.** Measurements of the bony width and area. Measurements on the preoperative x-ray image (left) and a brief diagram of the preoperative x-ray image (right). A, Measurement of the phalangeal bony base width (horizontal length). B, Measurement of the phalangeal bony center width (horizontal length). C, Measurement of bony length (vertical length) of the distal phalanx. D, Measurement of the area of the distal phalangeal bone. E, Measurement of the triangular phalangeal area.



**Fig. 3.** Measurement of the soft tissue area of the distal phalanx on a preoperative x-ray. The area after removing “A” from “B” is defined as the P3 soft tissue area.



**Fig. 4.** The protruding index is determined using the average protrusion lengths of both syndactyly toes from the reference line, which is the distal tip of the adjacent great toe in the standing view of the foot.

P3 base width ratio was also significantly different between the keloid and control groups ( $P < 0.01$ ) and also showed a positive correlation with keloid formation after syndactyly division.

Regarding bony length (vertical length), Spearman’s correlation test showed that the P3 length ratio was significantly different between the keloid and control groups ( $P < 0.01$ ). The positive correlation coefficient indicates that the P3 length ratio was positively correlated with keloid formation after syndactyly division. In the pediatric group, the P3 length ratio was also significantly different

between keloid and control groups ( $P < 0.01$ ) and also showed a positive correlation with keloid formation after syndactyly division.

Regarding the bony area (area width), Spearman’s correlation test showed a significant between-group difference in the actual P3 area ratio using ImageJ, although the between-group differences for P2 and P1 were insignificant. Additionally, the P3 triangular area ratio (base  $\times$  vertical length) of the P3 radiopaque portion was significant. Again, positive correlation coefficients observed indicate that the actual P3 area ratio and P3 triangular area ratio

**Table 1. Demographics of Patients in the Keloid and Control Groups**

Patient	Keloid Group			Control Group		
	Gender	Age at Surgery	No. Webspaces	Gender	Age at Surgery	No. Webspaces
1	M	15 mo	2	M	16 mo	2
2	F	16 y	1	F	18 y	1
3	M	11 mo	1	M	11 mo	1
4	F	13 mo	2	F	10 mo	2
5	F	10 mo	3	F	10 mo	3
6	F	18 y	3	F	16 y	3
7	F	16 y	2	F	19 y	2
8	F	6 mo	3	F	8 mo	3
9	M	8 mo	2	M	10 mo	2
10	F	20 y	2	F	22 y	2
11	M	17 mo	2	M	16 mo	2

M, male; F, female.

**Table 2. Statistical Analysis of the Digital Enlargement in All Patients Using Spearman’s Correlation Test**

	Average of the Keloid Group	Correlation Coefficient	P*	AUC	Cut-off Value
Width ratio					
P3 base	1.53	0.667	0.002	0.884	1.23
P3 center	1.38	0.496	0.023	0.785	1.29
P2, P1 base and center			>0.05		
Length ratio					
P3	1.50	0.790	0.001	0.905	1.27
P2, P1			>0.05		
Area ratio					
P3	2.05	0.826	0.001	0.975	1.34
P2, P1			>0.05		
P3 triangular area ratio	2.94	0.803	0.001	0.955	1.61
P2, P1 square area ratio			>0.05		
P1, P2, P3 soft tissue area ratio			>0.05		

\*Spearman’s correlation test.

P3: Distal phalanx; P2: Middle phalanx; P1: Proximal phalanx . When AUC > 0.9, the reliability of the cut-off value is excellent.

**Table 3. Statistical Analysis of Digital Enlargement in the Pediatric Group Using Spearman’s Correlation Test**

	Average of the Keloid Group	Correlation Coefficient	P*	AUC	Cut-off Value
Width ratio					
P3 base	1.56	0.763	0.006	0.895	1.41
P3 center			>0.05		
P2, P1 base and center			>0.05		
Length ratio					
P3	1.50	0.689	0.004	0.775	1.28
P2, P1			>0.05		
Area ratio					
P3	1.98	0.789	0.003	0.959	1.34
P2, P1			>0.05		
P3 triangular area ratio	3.30	0.778	0.003	0.959	2.19
P2, P1 square area ratio			>0.05		
P1, P2, P3 soft tissue area ratio			>0.05		

\*Spearman’s correlation test.

P3: Distal phalanx; P2: Middle phalanx; P1: Proximal phalanx . When AUC > 0.9, the reliability of the cut-off value is excellent.

were also positively correlated with keloid formation after syndactyly division. Similar results were observed in the analysis of the pediatric group.

**Digital Protrusion**

Regarding the measurement of protrusion length relative to the great toe (protruding index), the measurement was performed on nine keloid patients (excluding two patients with first webspace syndactyly). Statistical analysis was performed using the ratio of the affected to the normal foot and the protruding index.

According to Spearman’s correlation test, the protruding index of the affected side was significantly different between the keloid and control groups ( $P < 0.05$ ). The correlation coefficient of the protruding index of the affected side was positive (Table 4). However, protruding index of the normal side and the protruding ratio were not significantly different between the keloid and control groups ( $P > 0.05$ ).

**The ROC Curve**

In the ROC curves, the larger the area under the curve (AUC), the more reliable the reference value. In general, when AUC is 0.9 or greater, the reliability of the reference values is considered excellent, whereas if the AUC is 0.8–0.9, the reliability of reference values is considered good. In the analysis of digital enlargement, AUCs of the P3 area ratio, P3 Uriangular area ratio, and P3 length ratio were greater than 0.9, and the cut-off values were 1.34, 1.61,

and 1.27, respectively. In the analysis of digital protrusion, AUC of the affected protruding index was 0.8, and the cut-off value was 1.83mm (Fig. 5). In the pediatric group (n = 7), the AUCs of the P3 area ratio and P3 triangular area ratio were greater than 0.9, and the reference values were 1.34 and 2.19, respectively. A reference value for the affected foot of the protruding index was not obtained in the adult group because the number of adult patients was insufficient.

**DISCUSSION**

Keloid and hypertrophic scars show chronic inflammation of the reticular dermis, and hyper-fibroblast proliferation in the pathologic scar.<sup>4</sup> Keloids are commonly found in the earlobe, umbilicus, anterior chest, and shoulder.<sup>11</sup> The digits are not predisposed to develop keloids, and until now, few studies on keloid formation and treatment following syndactyly divisions have been conducted.<sup>5,6,8–10</sup>

At our institute, we use various methods such as steroid injection, methotrexate, and compression therapy to prevent keloids after syndactyly division. However, because patients with syndactyly were usually significantly young, we do not apply these methods easily. Radiotherapy cannot be used in children because of its effect on growth potential.<sup>7</sup> Additionally, methotrexate requires regular laboratory follow-up, and there are no established treatment guidelines for children.

**Table 4. Statistical Analysis of the Digital Protrusion Using Spearman’s Correlation Test**

	Average of the Keloid Group (mm)	Correlation Coefficient	P*	AUC	Cut-off Value (mm)
Protruding index (affected side)	3.2	0.428	0.038	0.8	1.83
Protruding index (normal side)			>0.05		
Protruding index ratio			>0.05		

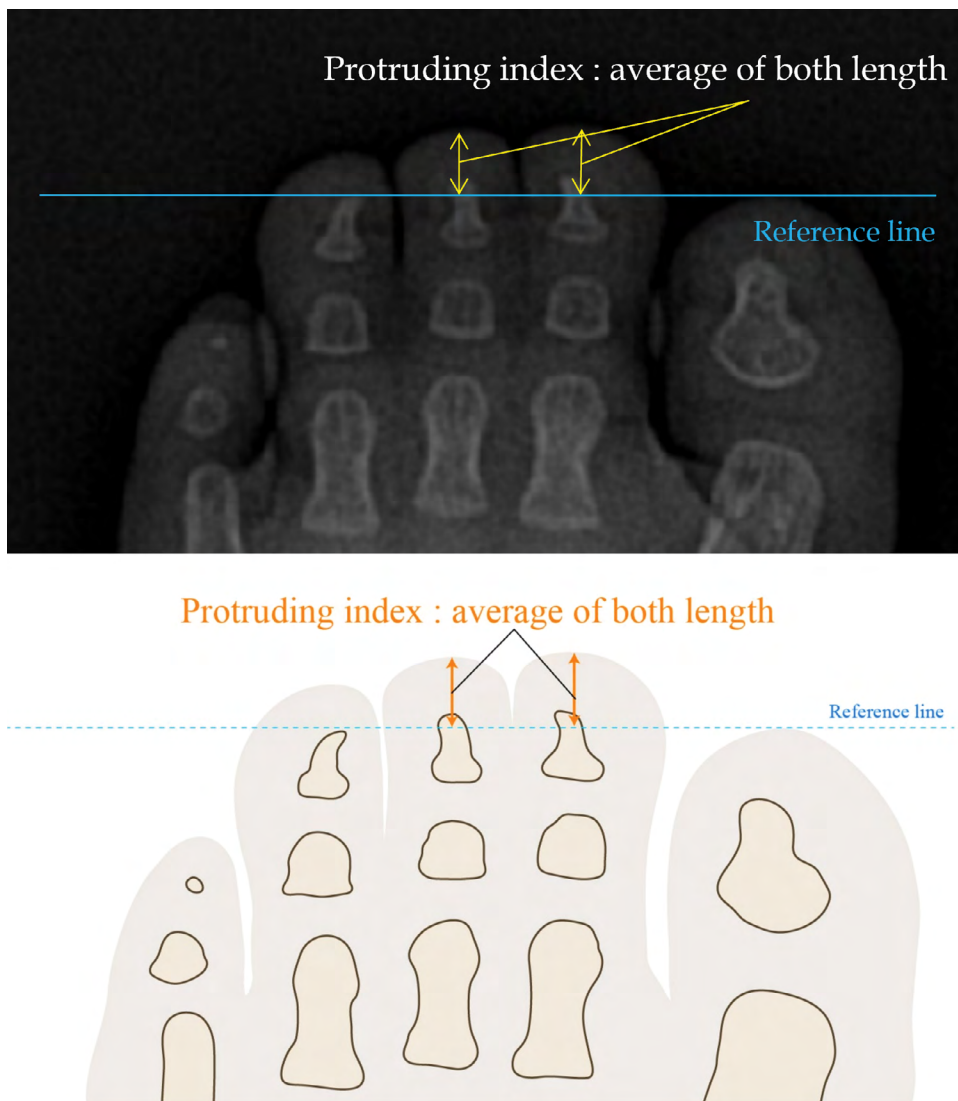
\*Spearman’s correlation test.

If additional surgery is needed for keloid treatment, then we suggest that it is important to wait until sufficient collagen synthesis has taken place before starting with the keloid treatment, which may be approximately 2–3 years.<sup>12</sup> Although this is significantly stressful and takes a long time, we build a rapport with the children and their guardians, and with close observation and meticulous care, keloids can be relatively overcome.

The onset of keloid formation in patients during the wound healing process is sudden. Because keloids are

difficult to predict in advance, treatments have always been delayed. Therefore, identifying the predictive factors and reference values for keloid formation is clinically meaningful.

In our study, we performed the analyses for digital enlargement and protrusion. From the analysis of the digital enlargement, we generated a reference value (or cut-off value) for keloid development following foot syndactyly divisions. Clinically, because bony structure can be observed clearly on the x-ray images, the bony index



**Fig. 5.** The ROC curve. The larger the AUC of each index, the more reliable the reference value of each index. Among these six curves, the P3 area ratio, P3 triangular area ratio, and P3 length ratio were excellent reference values of predicting keloid formation after foot syndactyly division (AUC > 0.9).



(width, length, and area, especially triangular area or square area) was a useful marker in preoperative x-ray of syndactyly patients. P3 width ratio, P3 length ratio, P3 area ratio, and P3 triangular area ratio were also significant, with the P3 area ratio being the most reliable predictive factor. However, true P3 width on the x-ray image cannot be measured without the ImageJ program. Instead, the triangular width of P3 can be measured simply, and as such, it can be used clinically as an effective preoperative predictor of keloid formation. In addition, we also performed a soft tissue analysis. Although the P3 width ratio (including triangular ratio) was significantly associated with keloid formation, soft tissue area ratio was not associated with keloid formation. In our study, the keloid formation after foot syndactyly was not associated with soft tissue area, but the P3 bony area.

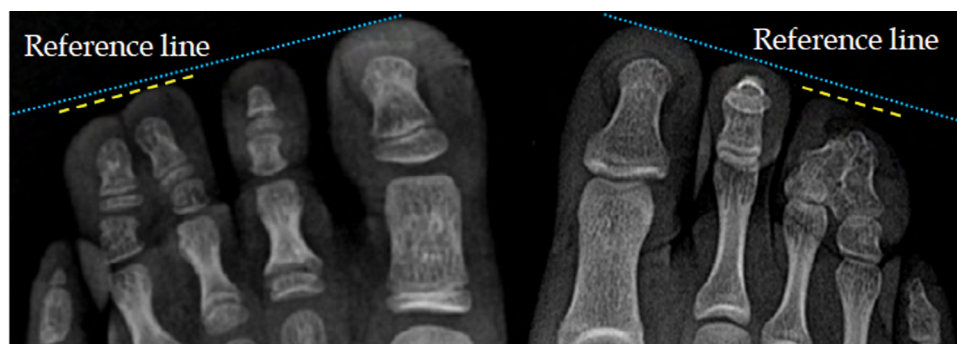From the analysis of digital protrusion, digital enlargement and protrusion defined by Mufuzzar et al were largely observed when compared with the adjacent digits.<sup>7</sup> Few studies have reported that keloids developed easily with digital enlargement, although interestingly, when looking at the presented clinical photographs, digital enlargement was more easily observed in the affected digits compared with the adjacent digits.<sup>5,6,8-10</sup> We initially generated the reference value of 1.83mm as the protruding index for clinical use. In general, the other toes are shorter than the great toe. However, our result would indicate that, in patients who had undergone syndactyly division, a toe with a length greater than or equal to the length of the great toe is at risk of keloid formation. This reference value of protruding index may be helpful for predicting the risk of bilateral syndactyly patients. However, further studies are required due to a relatively low coefficient correlation value. Additionally, toe protrusion length is generally shorter on the fibular side than on the tibial side in adults. Interestingly, in our study, the toe protrusion length of the great toe was similar on both the tibial and fibular sides in the keloid group (Fig. 6).

Although the precise correlation between keloid and digital enlargement was unclear, we have two hypotheses for the role that digital enlargement plays in the development of keloids following foot syndactyly divisions. The first is that if digital enlargement is a mild form of macrodactyly, because macrodactyly is related to digital nerve overstimulation that causes overgrowth, it may also affect

the fibroblast of the epidermis and dermal layers. Further experimental studies may be needed to clarify this. The second hypothesis concerns mechanical force. Mechanical force is an important factor in keloid formation.<sup>13</sup> In gait processes, more pressure may be applied in an enlarged and protruding digit. In our study, keloids occurred only on the medial side of the foot (ie, first, second, and third webspace). Additionally, other studies have shown that keloids do not occur in the fourth webspace.<sup>5,6,10</sup> Alvarez et al showed data of the dynamic pedobarography in children with normal feet and reported that pressure is mainly exerted on the medial side of the foot.<sup>14</sup> This may explain the keloid formation on the medial side of the foot.

This current study may present the largest number of syndactyly divisions performed by a single surgeon. Additionally, our study is the first to calculate the reference values for predicting keloid development following syndactyly divisions and to compare these values with those of the same digit of the other foot. These values are significantly helpful for pre- and postoperative management of patients undergoing foot syndactyly divisions.

However, our study has several limitations. This study had a small sample size and a retrospective study design. Because we relied only on medical records, other factors affecting the development of keloid scar could not be completely excluded. Additionally, despite a large number of hand and foot syndactyly cases, we only performed analysis on foot syndactyly cases. We could not perform a statistical analysis of the hand syndactyly cases or obtain reference values for predicting the development of keloids in the hand because there was only one case of a keloid developing on the hand. Therefore, further studies may be needed to generate the reference values for the hand. However, we performed several steps to overcome this limitation in our study. First, we selected a control group with factors affecting keloid development and matched those individuals with individuals in the keloid group. Second, we used not the absolute value but the “ratio” between both feet in one patient for analysis. Globally, keloid formations suggest that syndactyly division in the foot is not usually performed. However, in Korea, because physical appearance is significantly important according to the social consciousness, syndactyly division in the foot is performed in many patients. Therefore, determining predictive values of keloid formation in the foot is important. Additionally,



**Fig. 6.** Preoperative x-ray in keloid patients shows that the yellow line as a reference line of the great toe is similar to the blue line as a protrusion length in the involved webspace.



the present study is considered the cornerstone of future studies regarding keloid formation in hand syndactyly.

### CONCLUSIONS

To prevent keloid formation after syndactyly division, reliable predictive factors are needed. According to our results, patients with distal phalangeal bony enlargement and protrusion are at risk for keloid formation after syndactyly division. Among these various factors, the most reliable were the P3 area ratio and triangular area ratio on preoperative x-ray. If distal phalanx shows digital enlargement, when compared with the adjacent toe, the risk of keloid development should be communicated preoperatively to the patients, and preventive strategies for keloid development and close observation are required. The other reference values in our study are also helpful for predicting keloid formation after foot syndactyly divisions. These generated reference values will need to be clarified in further studies with larger sample sizes.

**Sang Hyun Woo, MD, PhD**

W Institute for Congenital Deformity of the Extremities

W Institute for Hand and Reconstructive Microsurgery

W General Hospital, 1632 Dalgubeol-daero

Dalseo-gu, Daegu 42642

South Korea

E-mail: handwoo303@gmail.com

### REFERENCES

1. Akaishi S, Ogawa R, Hyakusoku H. Keloid and hypertrophic scar: neurogenic inflammation hypotheses. *Med Hypotheses*. 2008;71:32–38.
2. Rosen DJ, Patel MK, Freeman K, et al. A primary protocol for the management of ear keloids: results of excision combined with intraoperative and postoperative steroid injections. *Plast Reconstr Surg*. 2007;120:1395–1400.
3. Shin JY, Lee JW, Roh SG, et al. A comparison of the effectiveness of triamcinolone and radiation therapy for ear keloids after surgical excision: a systematic review and meta-analysis. *Plast Reconstr Surg*. 2016;137:1718–1725.
4. Al-Attar A, Mess S, Thomassen JM, et al. Keloid pathogenesis and treatment. *Plast Reconstr Surg*. 2006;117:286–300.
5. Yamawaki S, Naitoh M, Ishiko T, et al. A toe keloid after syndactyly release treated with surgical excision and intralesional steroid injection. *Plast Reconstr Surg Glob Open*. 2014;2:e186.
6. Tolerton SK, Tonkin MA. Keloid formation after syndactyly release in patients with associated macrodactyly: management with methotrexate therapy. *J Hand Surg Eur Vol*. 2011;36:490–497.
7. Muzaffar AR, Rafols F, Masson J, et al. Keloid formation after syndactyly reconstruction: associated conditions, prevalence, and preliminary report of a treatment method. *J Hand Surg Am*. 2004;29:201–208.
8. Wood VE. Keloid formation in a simple syndactyly release: a case report. *J Hand Surg Am*. 1992;17:479–480.
9. Tonkin MA, Willis KR, Lawson RD. Keloid formation resulting in acquired syndactyly of an initially normal web space following syndactyly release of an adjacent webspace. *J Hand Surg Eur*. 2008;33:29–31.
10. Kong BY, Baek GH, Gong HS. Treatment of keloid formation following syndactyly division: surgical technique. *Hand Surg*. 2012;17:433–437.
11. Murray JC. Scars and keloids. *Dermatol Clin*. 1993;11:697–708.
12. Craig RD, Schofield JD, Jackson DS. Collagen biosynthesis in normal and hypertrophic scars and keloid as a function of the duration of the scar. *Br J Surg*. 1975;62:741–744.
13. Ogawa R. Keloid and hypertrophic scars are the result of chronic inflammation in the reticular dermis. *Int J Mol Sci*. 2017;18:E606.
14. Alvarez C, De Vera M, Chhina H, et al. Normative data for the dynamic pedobarographic profiles of children. *Gait Posture*. 2008;28:309–315.