

# Multiple jaw cysts-unveiling the Gorlin-Goltz syndrome

S. MANJIMA, ZAMEERA NAIK, VAISHALI KELUSKAR, ANJANA BAGEWADI

## Abstract

Gorlin-Goltz syndrome or basal cell nevus syndrome is a comparatively rare syndrome characterized by basal cell nevi, odontogenic keratocysts, and skeletal anomalies. Diagnosis is based on the major and minor clinical and radiographic criteria. Dentist plays a major role in the diagnosis of this disease due to the oral and maxillofacial manifestations of the syndrome. In some cases, jaw cysts are diagnosed by routine radiographs advised by the dentists. Odontogenic keratocysts in such syndromic patients will be multiple and extensive and in some cases results in cortical expansion and facial disfigurement. Thorough clinical examination and investigations prompt an early confirmation of the syndrome, which is very essential to avoid morbidity associated with the syndrome. Here, we report a case of multiple odontogenic cysts in a 16-year-old patient which later was diagnosed as a case of Gorlin Goltz syndrome.

**Keywords:** Goltz-gorlin syndrome, jaw, odontogenic keratocyst

## Introduction

Gorlin-Goltz syndrome, also known as Nevoid Basal Cell Carcinoma Syndrome (NBCCS), is a multisystem disorder which was first described by Gorlin and Goltz.<sup>[1]</sup> The incidence of this disorder is estimated to be 1 in 50,000–1,50,000 in the general population, varying by region.<sup>[2]</sup> It is an uncommon, autosomal dominant disorder affecting multiple organ systems which include skeletal, eye, skin, reproductive, and neural system, although all the features are rarely observed in a single patient.<sup>[3]</sup> The pathogenesis of NBCCS is attributed to abnormalities linked to the long arm of chromosome 9 (q22.3–q31) PTCH1 gene with no apparent heterogeneity.<sup>[4]</sup> The principal clinical features of Gorlin's syndrome comprise multiple odontogenic keratocyst, basal cell nevi, and skeletal anomalies.<sup>[3]</sup> This article reports a case of 16-year-old patient who reported with multiple odontogenic keratocysts which later was diagnosed as Gorlin-Goltz syndrome, thus emphasizing the need for thorough clinical and radiographic evaluation of patients with jaw cysts.

*Department of Oral Medicine and Radiology, KLE VKIDS, Belgaum, Karnataka Belgaum, India*

**Correspondence:** Dr. S. Manjima,  
Department of Oral Medicine and Radiology, KLE VKIDS,  
Belgaum, Karnataka, India.  
E-mail: drmanjimas@gmail.com

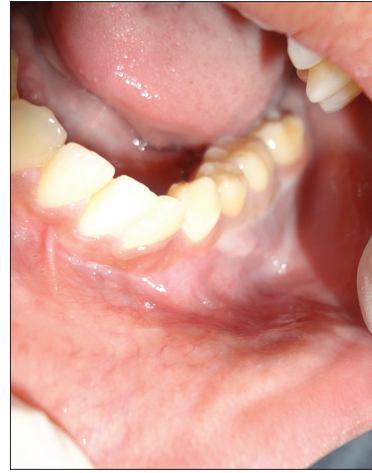## Case Report

A 16-year-old male patient reported to the Department of Oral Medicine and Radiology, KLE VK Institute of Dental Sciences, Belgaum with a chief complaint of a swelling in the Left back region of the jaw since 15 days. The history revealed that the swelling was of sudden onset and was not associated with pain or any kind of discharge. Patient's medical, family, dental, and personal histories were noncontributory. On general physical examination, the patient was moderately built and nourished, presented with normal gait and kyphosis. Extraoral examination revealed facial asymmetry, mandibular prognathism, hypertelorism and strabismus with left eye [Figure 1]. On intraoral examination, a swelling measuring 3 cm × 1 cm in size was present obliterating the buccal vestibule from 34 to 36 region with missing 33. [Figure 2] and 33 was missing. On palpation, swelling was firm in consistency; nontender with expansion of buccal cortical plate extending from 34 to 36 region. Based on the history and clinical findings, we arrived at a provisional diagnosis of dentigerous cyst and odontogenic keratocyst was considered as a differential diagnosis. Panoramic radiograph showed four multilocular radiolucencies and one unilocular radiolucency with scalloped margins. Multilocular radiolucencies involved the right and left mandibular body region extending to the ramus and also left symphysis region. Unilocular radiolucency was seen in the left maxillary tuberosity area [Figure 3]. Fine-needle aspiration cytology of the swelling was performed using 24 gauge needle and the aspirate was creamy white in color, and the protein estimate was 3.3 g/100 ml. Considering the possibility of the Gorlin-Goltz syndrome, further evaluation was done with chest radiographs, computed tomography (CT) scan and lateral cephalogram. Chest radiograph revealed bifid ribs in relation to right 2<sup>nd</sup>, 3<sup>rd</sup> and 4<sup>th</sup>, and left 3<sup>rd</sup> and 4<sup>th</sup> ribs [Figure 4]. CT scan showed bilateral expansile lytic lesion with mandible [Figure 5], and lateral cephalogram showed bridging of sella turcica [Figure 6].

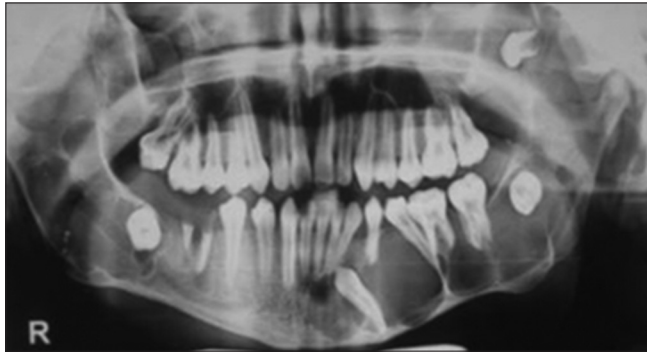
Access this article online	
Quick Response Code: 	Website: <a href="http://www.contempclindent.org">www.contempclindent.org</a>
	DOI: 10.4103/0976-237X.152959



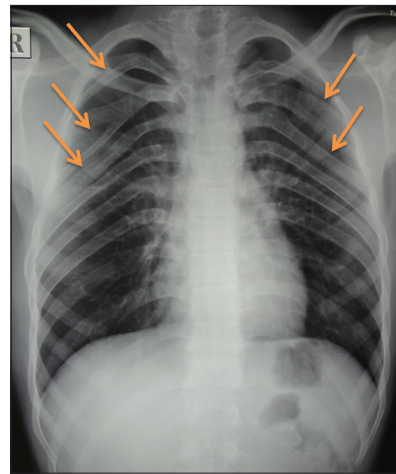
**Figure 1:** Extraoral examination revealing facial asymmetry and eyes showing hypertelorism and strabismus



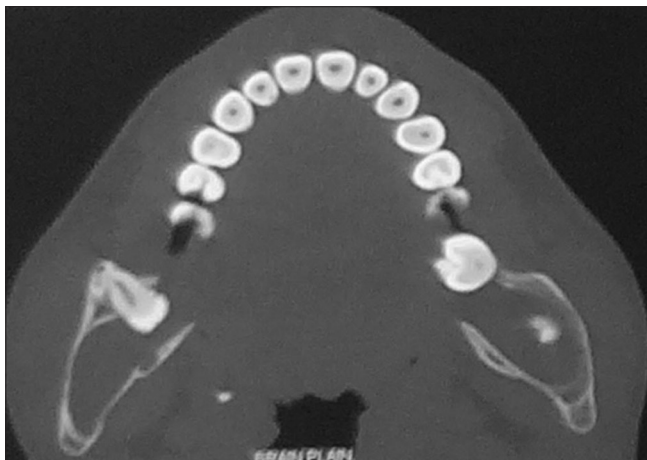
**Figure 2:** Intraoral swelling obliterating the buccal vestibule



**Figure 3:** OPG showing multiple multilocular radiolucency with scalloped margins

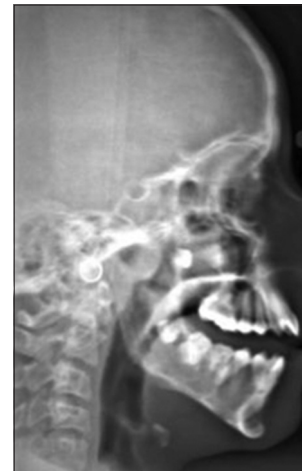

**Figure 4:** Chest radiograph showing bifid ribs



**Figure 5:** Computed tomography image showing bilateral expansile lesion

An incisional biopsy of the swelling was advised. Histopathological examination of specimen revealed cystic epithelium composed of darkly stained basal cells arranged in a palisading pattern. Superficial layer was showing parakeratinization and corrugated appearance which was suggestive of odontogenic keratocyst [Figure 7].



**Figure 6:** Lateral cephalogram showing bridging of sella turcica

## Discussion

Gorlin-Goltz syndrome occurs with an equal frequency in men and women and almost all ethnic groups.<sup>[5]</sup> This

syndrome is occasionally diagnosed in very young patients, but in most cases, it occurs in people aged between 17 and 35 years.<sup>[6]</sup> The condition is very difficult to diagnose in early childhood because its symptoms appear gradually during the growing phase, but good prognosis is seen in early diagnosed cases.<sup>[7]</sup> Following are the major and minor criteria specified by Evans *et al.* in 1993 for the diagnosis of Gorlin-Goltz syndrome.<sup>[7]</sup>

Major criteria consist of:

- More than two basal cell carcinomas or one in patient <20-years-old
- Odontogenic keratocysts of the jaw
- Three or more palmar or plantar pits
- Bilamellar calcifications of falx cerebri and tentorium
- Bifid or fused, or markedly splayed ribs
- First-degree relative with Gorlin-Goltz syndrome.

Minor criteria consist of:

- Macrocephaly,
- Congenital anomalies (cleft lip or palate, frontal bossing, coarse facies, and moderate or severe hypertelorism)
- Other skeletal anomalies (Sprengel deformity, marked pectus deformity, and marked syndactyly of the digits)
- Radiologic anomalies such as bridging of the sella turcica, vertebral anomalies, modeling defects of the hands and feet, or flame-shaped lucencies of the hands and the feet
- Ovarian fibroma or myeloblastoma.

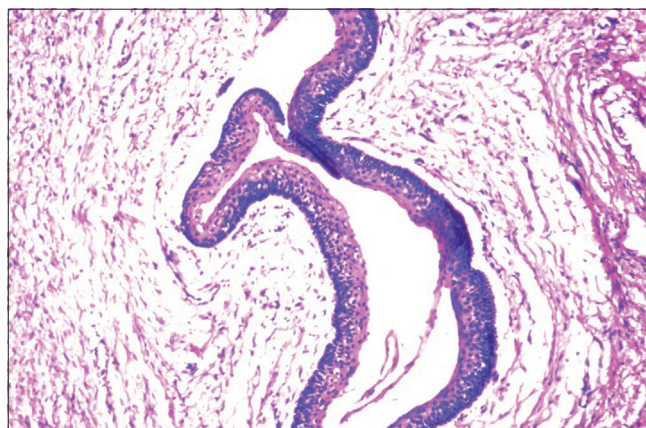
Two major criteria or one major and two minor criteria are obligatory for diagnosis of Gorlin-Goltz syndrome. In our case, diagnosis was confirmed with the presence of two major criteria (odontogenic keratocysts of the jaw and bifid ribs) and two minor criteria such as congenital anomalies (frontal bossing and hypertelorism) and radiologic anomalies (kyphosis and bridging of sella turcica).

Odontogenic keratocyst can be the first feature of the syndrome. The cyst is typically found as an incidental radiographic finding. The cyst may manifest clinically if it becomes infected or cause symptoms such as swelling. The presence of the cyst was the symptom which further substantiated the syndrome in our cases. Keratocystic odontogenic tumors in Gorlin-Goltz syndrome usually comprise unilocular or multilocular radiolucencies of the mandibular body, angle, or ramus.

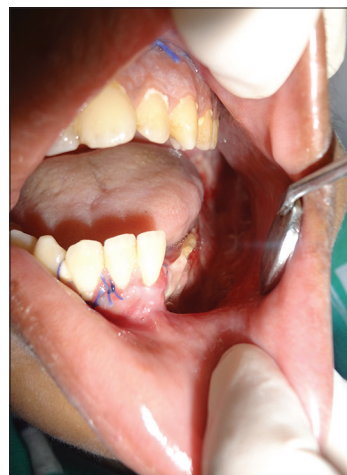Various conservative approaches have been proposed for young patients with large cysts to save soft and hard tissues including the teeth. These include marsupialization, decompression, enucleation with Carnoy's solution, peripheral ostectomy with or without Carnoy's solution, jaw resection and surgical excision of the keratocyst followed by cryotherapy or Carnoy's solution.<sup>[8]</sup> Genetic counseling is compulsory for all patients as the patient has 50% chances of transferring the same condition to the child.<sup>[9]</sup> Prenatal

testing for pregnancies can be done in cases of identified mutation in the affected family.

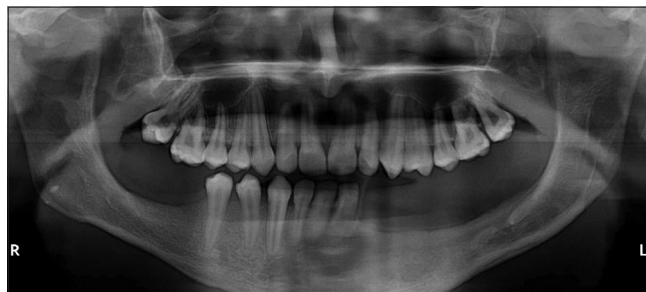In our case, the patient was referred to Department of Oral and Maxillofacial Surgery and underwent enucleation and curettage of cystic lesions [Figure 8]. Patient was informed about the syndrome and advised to avoid prolonged exposure to sunlight. Six months postoperative radiograph showed good healing of cystic cavities with satisfactory bone formation. Patient is still kept under follow-up [Figure 9].



**Figure 7:** Hyperchromatic palisaded basal layer and corrugated parakeratotic surface (H and E, x10)



**Figure 8:** After surgical enucleation of the cyst



**Figure 9:** OPG showing healing of bone after 6 months



## Conclusion

A patient with Gorlin-Goltz syndrome needs particular multidisciplinary medical and dental approach for management. An early diagnosis creates an opportunity for effective prevention of complications and proper treatment. Young patient those who do not have basal cell carcinoma can take precautions to avoid radiation exposure. Already diagnosed and treated cases should be kept under strict follow-up since the recurrence rate up to 63% is reported.<sup>[7]</sup>

## References

1. Patil K, Mahima VG, Gupta B. Gorlin syndrome: A case report. *J Indian Soc Pedod Prev Dent* 2005;23:198-203.
2. Gorlin RJ, Goltz RW. Multiple nevoid basal-cell epithelioma, jaw cysts and bifid rib. A syndrome. *N Engl J Med* 1960;262:908-12.
3. Manfredi M, Vescovi P, Bonanini M, Porter S. Nevoid basal cell carcinoma syndrome: A review of the literature. *Int J Oral Maxillofac Surg* 2004;33:117-24.
4. Gailani MR, Bale SJ, Leffell DJ, DiGiovanna JJ, Peck GL, Poliak S, *et al.* Developmental defects in Gorlin syndrome related to a putative tumor suppressor gene on chromosome 9. *Cell* 1992;69:111-7.
5. Jawa DS, Sircar K, Somani R, Grover N, Jaidka S, Singh S. Gorlin-Goltz syndrome. *J Oral Maxillofac Pathol* 2009;13:89-92.
6. Baliga SD, Rao SS. Nevoid-basal cell carcinoma syndrome: A case report and overview on diagnosis and management. *J Maxillofac Oral Surg* 2010;9:82-6.
7. Karthiga KS, Sivapatha Sundharam B, Manikandan R. Nevoid basal cell carcinoma syndrome. *Indian J Dent Res* 2006;17:50-3.
8. Matijevic S, Damjanovic Z, Lazic Z, Gardasevic M, Radenovic-Djuric D. Peripheral ostectomy with the use of Carnoy's solution as a rational surgical approach to odontogenic keratocyst: A case report with a 5-year follow-up. *Vojnosanit Pregl* 2012;69:1101-5.
9. Lo Muzio L. Nevoid basal cell carcinoma syndrome (Gorlin syndrome). *Orphanet J Rare Dis* 2008;3:32.

**How to cite this article:** Manjima S, Naik Z, Keluskar V, Bagewadi A. Multiple jaw cysts-unveiling the Gorlin-Goltz syndrome. *Contemp Clin Dent* 2015;6:S102-5.

**Source of Support:** Nil. **Conflict of Interest:** None declared.