

Treatment of missed Monteggia fracture with intact annular ligament after an interval of 9 years: a case report and literature review

Journal of International Medical Research

48(8) 1–8

© The Author(s) 2020

Article reuse guidelines:

sagepub.com/journals-permissions

DOI: 10.1177/0300060520949079

journals.sagepub.com/home/imr



Weizheng Zhou¹ , Lianyong Li¹ and Mingzhang Mu² 

Abstract

Objective: Missed Monteggia fractures are commonly observed among children. Both the interval from the injury to surgery and the patient's age at operation are thought to be correlated directly with the success of the surgery and prognosis. The aim of the present work was to report one interesting adult case of a missed Monteggia fracture with an intact annular ligament 9 years after injury and the outcomes at a 7-year follow-up.

Case description: One missed lesion with a 9-year delay for surgery occurred in a skeletally mature individual, and it was treated by open reduction and ulnar angulation and elongation osteotomy. The annular ligament was interpositioned intact in the radiocapitellar joint, and therefore, instead of the annular ligament reconstruction (ALR), relocation was performed.

Results: After one revision surgery for the complication of nonunion, good radiographic and functional outcomes were eventually sustained at the 7-year follow up.

Conclusion: Good radiographic and functional outcomes can be expected in adult patients in whom the annular ligament is intact and interpositioned, and this was treated by open reduction and ulnar osteotomy 9 years after the initial injury in our patient.

Keywords

Missed Monteggia fracture, annular ligament, radial head dislocation, ulnar osteotomy, case report, open reduction

Date received: 8 May 2020; accepted: 20 July 2020

¹Department of Pediatric Orthopedics, Shengjing Hospital of China Medical University, Shenyang, Liaoning, China

²Department of Orthopedic Surgery, Yantaishan Hospital, Yantai City, Shandong Province, China

Corresponding author:

Mingzhang Mu, Department of Orthopaedic Surgery, Yantaishan Hospital, No. 91 Jiefang Road, Yantai City, Shandong Province 264001, China.
Email: mingzhangmu@163.com



Background and purpose

In 1814, Monteggia fracture-dislocation was first described by Giovanni Monteggia as a fracture of the proximal ulna that was associated with the anterior dislocation of the radial head, and it is relatively rare and commonly missed in children.^{1,2} A missed Monteggia fracture is generally defined as a persistent dislocation of the radiocapitellar joint that is still present 4 weeks after injury. Moreover, substantial surgical procedures have been performed to reduce a dislocated radial head, including annular ligament repair or reconstruction (ALR) or an osteotomy of the ulna, radius, or both,³ which is widely applied in children but rarely performed in adults, especially 9 years after injury. For management outcomes, most of the previous studies have focused on the pediatric population and limitations in elbow motion. Thus, we reported the outcomes of an adult patient who was diagnosed with a missed Monteggia fracture and underwent delayed treatment 9 years after the injury. Excellent function was observed at the 7-year follow-up.

Case description

Patient information

A 19-year-old man who underwent delayed treatment for a missed Monteggia fracture dislocation after 9 years was referred to our clinic with complaints of an obvious left cubitus valgus deformity and snapping during wrist pronation–supination. In addition to movement limitations and cosmetic problems, the patient also had elbow arthralgia while lifting weights. The physical examination showed that the bony prominence of the radial head could be felt at the anteriolateral region of the elbow joint. No neurological complications, including tardy ulnar nerve palsy and posterior interosseous nerve palsy were

observed. Bado type I lesions were identified on the radiographs in the anteroposterior and lateral views of the affected forearm (Figure 1a and 1e).

Surgical technique

The current case report conforms to the 1995 Declaration of Helsinki and subsequent amendments and was approved by the local ethics committee. Written informed consent was obtained before surgery and for publication of this report. The patient was placed in the supine position under general anesthesia, and a tourniquet was inflated on the left upper arm. We used the Henry approach, as described in previous studies.⁴ Once the muscles adjacent to the radiocapitellar joint had been cleared, the pseudocapsule surrounding the capsule was opened from the distal to the proximal region to expose the radial head. Then, we evaluated the state of the cartilage of the radial head. The radial head was surrounded with dense fibrous scar tissue, which was excised. Thereafter, we observed that the intact annular ligament was displaced into the radiocapitellar joint (Figure 2a). Reduction of the radial head was then attempted, but it failed. We then performed an oblique osteotomy at the proximal one-third of the ulna through the same incision. Angulation and elongation were temporarily maintained by an external fixator, and the interposed ligament was stretched from the joint space and was reduced around the radial head, as described in our previous study.⁵ Next, the osteotomy was fixed with a prebent plate in exchange of a temporary external fixator (Figure 2b and 2c). The stability of the radial head was assessed in flexion–extension under direct visualization, and the residual annular ligament was sutured *in situ*. Additionally, it was also important to assess the stability of the radiocapitellar joint with the forearm in full pronation and

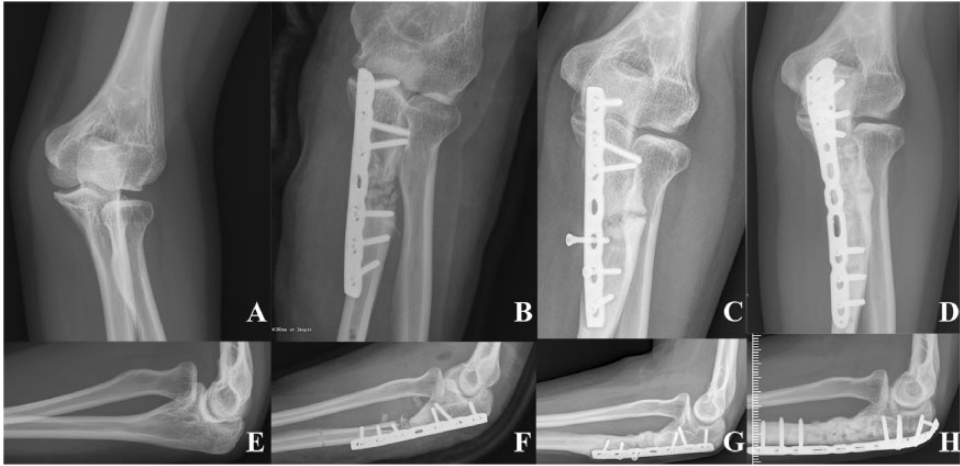


Figure 1. A 19-year-old man had a Bado type I missed Monteggia fracture that was noted on preoperative radiographs (a, e). Open reduction and ulnar angulation osteotomy with plate fixation was initially performed (b, f). Nonunion was demonstrated 4 years after the first surgery (c, g). Eventually, the osteotomy was healed via revision surgery using an autogenous bone graft (d, h).

flexion angles exceeding 90 degrees. Finally, the incision was closed one layer at a time.

After the operation, an elbow cast was applied at 90° of elbow flexion and full supination of the forearm. Postoperative radiographs were taken weekly to assess the level of radiocapitellar congruency. The elbow cast was removed at the end of week 6, and active elbow range of motion exercises were started immediately.

At 4 years after surgery, unfortunately, nonunion was observed, and a revision surgery was performed using a local autogenous bone graft that was harvested from the iliac crest (Figure 1c and 1g). The internal plate was then removed successfully after the osteotomy healed.

Outcomes

The patient had been followed-up for 7 years. At this time, a full range of extension–flexion and pronation–supination motions were available (Figure 3). The Kim elbow score^{6,7} at the final follow-up was graded as excellent. Moreover, a good

radiographic result was obtained, in accordance with Nakamura et al.⁸

Discussion

The missed Monteggia lesion was diagnosed based on the duration of the dislocated radial head after injury. In addition, both the interval of injury to surgery and age at operation had direct correlations with surgical success because of the development of dysplastic changes in the distal humerus and proximal radius.⁹ However, controversial information is available in the literature, but there is no statistically significant evidence. Patients who had not yet reached adolescence were more likely to exhibit satisfactory radiographic outcome.¹⁰ However, there are very few cases with a long delay from injury to treatment among skeletally mature patients. Previously, a good reduction was expected in patients who were 18 to 20 years of age, but they underwent surgery 2 to 7 months after the injury, and deformities of the radial head were minimal.¹¹ To the best of our

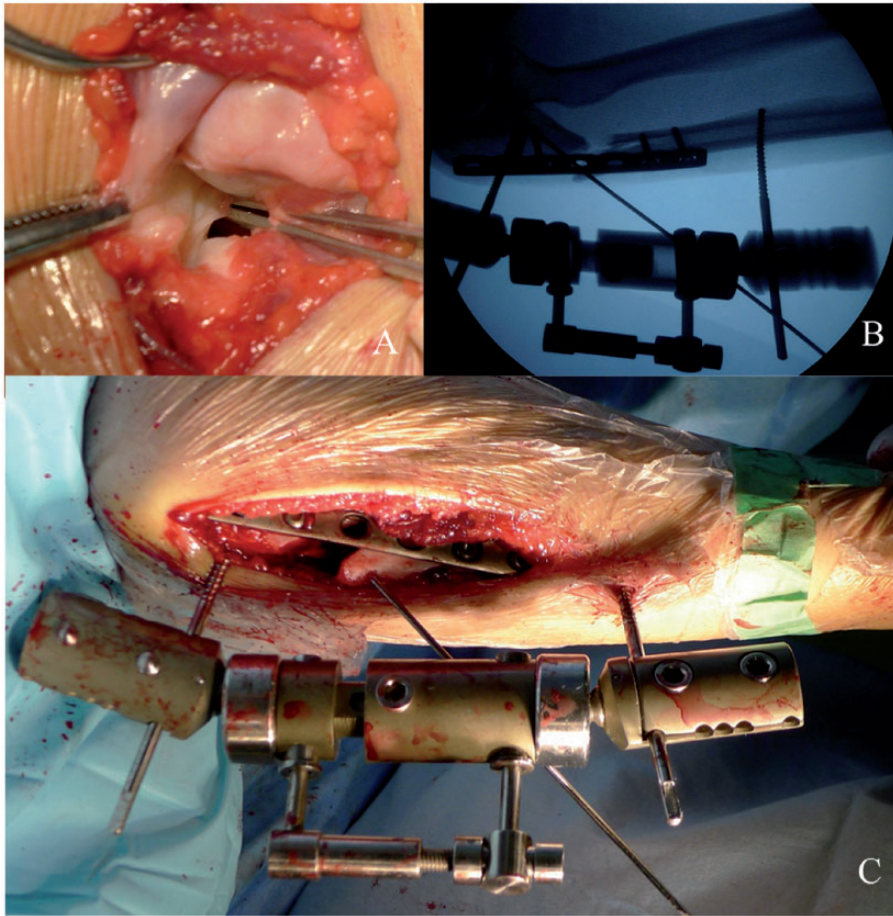


Figure 2. Intraoperatively, the annular ligament was intact and interpositioned in the radiocapitellar joint (a), which that meant dislocation of the radial head resulted from sliding out instead of annular ligament rupture, and a temporary external fixator was applied to check the status of the reduction and repetitive adjustment (b, c).

knowledge, our case was the first adult patient with a 9-year delay, and good radiographic and functional outcomes persisted at the 7-year follow-up. Therefore, there is no conclusive time frame in which annular reconstruction should be performed, and patient's age and duration of the dislocation was also seemed to be unimportant.¹²

The goal of treatment for missed Monteggia fractures is to restore and maintain the radiocapitellar alignment as soon as possible because chronic changes in the

proximal radioulnar joint can lead to arthritis in the distal radioulnar joint over time.¹³ However, it is difficult to reduce a long-standing radial head dislocation with an ulnar plastic deformation merely by closed manipulation. Thus, the radiocapitellar joint was first to be exposed intraoperatively in the patient in our study. On the one hand, it might be not sufficient to restore the alignment of the radiocapitellar joint simply by ulnar osteotomy because a dislocated or torn annular ligament can

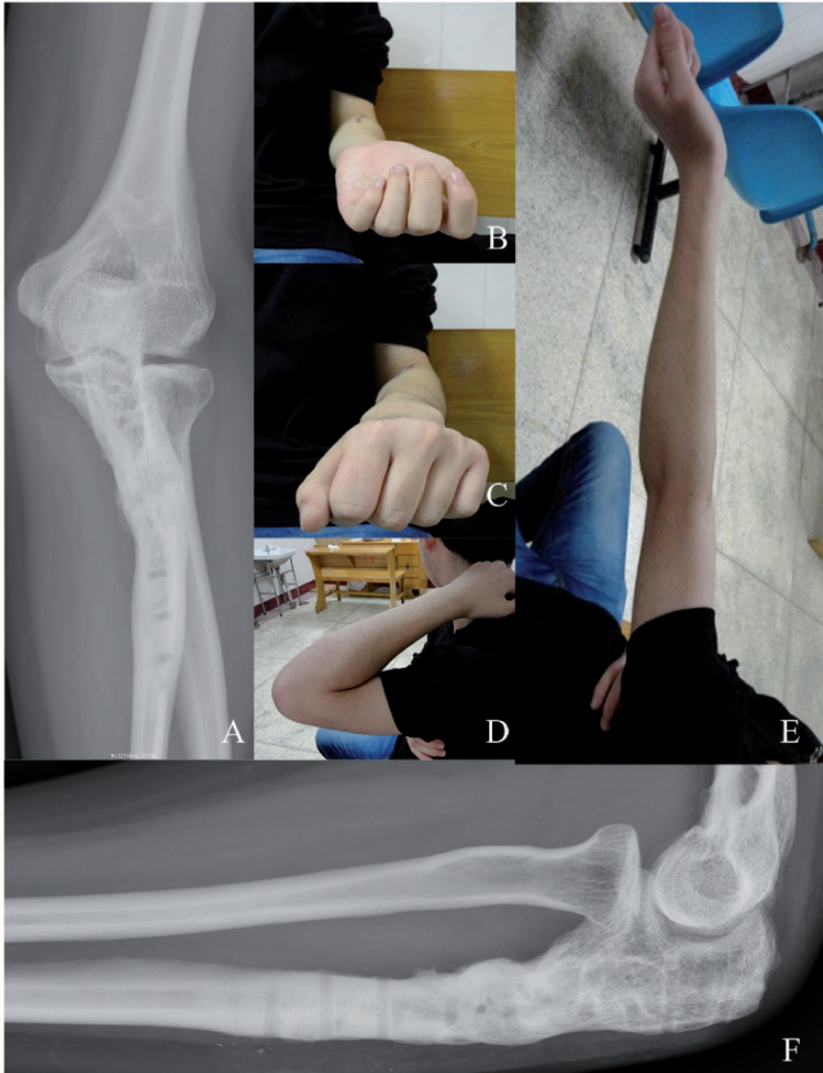


Figure 3. The radiographic (a, f) and functional (b to e) outcomes at the 7-year follow-up were both evaluated. A stable reduction and full range of elbow motion was found.

form meniscoid scar tissue, although several cases have been treated successfully.¹⁴ Therefore, we initially preferred to excise the tissue that might have prevented the reduction. On the other hand, because of the chronicity of the injury, a congruent proximal radiocapitellar reduction might be difficult to perform. Similarly, some authors have recommended an ulnar osteotomy as the second

step, only if reduction via a closed or open methods fails.¹⁵ Furthermore, an open reduction can also provide access to evaluate the radial head and decompress the involved nerve when necessary for direct visualization. However, open reduction of the radial head without correction of the ulnar deformity is no longer considered to be an appropriate treatment,¹⁶ and it is indicated for only

select patients. For example, Park et al.¹⁴ found that an open reduction alone could successfully treat radial head dislocation when the maximum ulnar bow (MUB) was less than 4 mm and it was located in the distal 40% of the ulna in individuals who had not previously experienced a displaced ulnar fracture.

Conversely, Ladermann et al.¹⁷ only recommended open radial head reduction when the reduction was not achieved spontaneously after ulnar osteotomy. In particular, there were also several reports about successful closed reduction of the radial head by ulnar osteotomy in missed Monteggia fractures.¹⁴ Thus, it is generally accepted that correction of ulnar malalignment and relief of the tension in the interosseous membrane are the most important factors for achieving and maintaining reduction of the radial head.¹⁸ Thus, the correction of malalignment with ulnar osteotomy is the key to a good surgical result. However, various modalities of the ulnar osteotomy have been applied, especially with respect to the osteotomy location and method. We noticed that the preferred location of ulnar osteotomy was the proximal one-third of the ulna because the osteotomy location should be as proximal as possible to protection from delayed union and nonunion.¹⁸ However, some authors suggested that the location of the osteotomy, whether it was at the proximal metaphysis or at the place of deformity in the ulna, was irrelevant because it may not be possible to detect the initial location of the deformity after some time has elapsed.¹⁹ This is why we chose the proximal one-third of the ulna as the osteotomy location in the current case. Regarding the osteotomy method, ulnar angulation osteotomy with and without elongation have both recently been reported.⁹ Moreover, ulnar fixation following osteotomy can be accomplished with a plate and screws, an external fixator, or intramedullary fixation, as shown in

previous studies.^{9,17,18} In our case, we used an external fixator for temporary fixation to intraoperatively adjust the elongation and angulation of the ulnar osteotomy. The radial head can be gradually reduced by elongation and angulation of the ulna, but there is a high risk for repetitive adjustments.¹⁸ Once a stable reduction was expected, a prebent plate was applied, and the external fixator was then removed.

Although the annular ligament was dramatically intact and interpositioned in the radiocapitellar joint at 9 years after injury in the present case and no ALR was needed, the necessity of the repair or reconstruction of the annular ligament and whether the annular ligament should be repaired *in situ* or reconstructed by a tendon or fascia graft has been contentious. Several surgeons have argued that reconstruction of the annular ligament was unnecessary because most of the radial head was stable without reconstruction.¹⁷ In particular, Delpont et al.²⁰ found that ALR did not seem to be useful when compared with not performing ALR. Additionally, ALR was also considered to be the cause of postoperative limitations in elbow motion.²¹ Therefore, open reduction of the radial head with concurrent ulnar osteotomy, but not ALR, has been increasingly performed. However, the annular ligament is the primary stabilizer of the radial head during all phases of rotation, while the interosseous membrane contributes significantly only during the terminal phase of the supination arc. Thus, it has been stated that the annular ligament is the most important structure in maintaining the anatomical position of the radial head. In addition, Gyr et al.¹² suggested that any surgical attempt at reduction of the radial head without annular ligament reconstruction would fail and result in recurrent dislocation. Thus, annular ligament reconstruction was recommended for all patients who were undergoing restoration of elbow biomechanics. Consequently, open reduction of

the radial head with reconstruction of the annular ligament combined with angulation and elongation osteotomy of the proximal ulna is still more acceptable.

In summary, missed Monteggia fractures are rare among skeletally mature patients. The annular ligament is occasionally intact instead of ruptured. Good radiographic and functional outcomes can be expected in adult patients in whom the annular ligament is intact and interpositioned, and it was treated by open reduction and ulnar osteotomy without annular ligament reconstruction 9 years after the initial injury.

Authors' contributions

WZZ was a major contributor in writing the manuscript. MZM and LYL performed the surgery together and completed the follow-up data collection. All authors read and approved the final manuscript.

Declaration of conflicting interest

The authors declare that there is no conflict of interest.

Ethics approval and consent

The current case report conforms to the 1995 Declaration of Helsinki and subsequent amendments, and was approved by the local ethics committee at Yantaishan Hospital, Shandong Province, China. Written informed consent was obtained from the patient for the publication of this case report and any accompanying images.

Funding

This research received no specific grant from any funding agency in the public, commercial, or not-for-profit sectors.

ORCID iDs

Weizheng Zhou  <https://orcid.org/0000-0001-9967-1477>

Mingzhang Mu  <https://orcid.org/0000-0002-0974-1273>

References

1. Monteggia GB. Lussazioni delle ossa delle estremita superiori. *Instituzioni Chirurgiches* 1814; 5: 131–133.
2. Bado JL. The Monteggia lesion. *Clin Orthop Relat Res* 1967; 50: 71–86.
3. Goyal T, Arora SS, Banerjee S, et al. Neglected Monteggia fracture dislocations in children: a systematic review. *J Pediatr Orthop B* 2015; 24: 191–199. DOI: 10.1097/BPB.000000000000147.
4. Lu X, Yan G, Wang Y, et al. Repositioning of the annular ligament in the management of missed Monteggia fracture. *J Pediatr Orthop* 2017; 37: 20–22. DOI: 10.1097/BPO.0000000000000584.
5. Tan JW, Mu MZ, Liao GJ, et al. Pathology of the annular ligament in paediatric Monteggia fractures. *Injury* 2008; 39: 451–455.
6. Kim HT, Park BG, Suh JT, et al. Chronic radial head dislocation in children, Part 2: results of open treatment and factors affecting final outcome. *J Pediatr Orthop* 2002; 22: 591–597. DOI: 10.1097/01241398-200209000-00005.
7. Kim HT, Conjares JNV, Suh JT, et al. Chronic radial head dislocation in children, Part 1: pathologic changes preventing stable reduction and surgical correction. *J Pediatr Orthop* 2002; 22: 583–590. DOI: 10.1097/01241398-200209000-00004.
8. Nakamura K, Hirachi K, Uchiyama S, et al. Long-term clinical and radiographic outcomes after open reduction for missed Monteggia fracture-dislocations in children. *J Bone Joint Surg Am* 2009; 91-A: 1394–1404. DOI: 10.2106/JBJS.H.00644.
9. Eamsobhana P, Chalayon O, Kaewpornawan K, et al. Missed Monteggia fracture dislocations treated by open reduction of the radial head. *Bone Joint J* 2018; 100-B: 1117–1124. DOI: 10.1302/0301-620X.100B8.BJJ-2017-0866.R3.
10. Stragier B, Smet LD and Degreef I. Long-term follow-up of corrective ulnar osteotomy for missed Monteggia fractures in children. *J Shoulder Elbow Surg* 2018; 27: e337–e343. DOI: 10.1016/j.jse.2018.06.029.
11. Horii E, Nakamura R, Koh S, et al. Surgical treatment for chronic radial head dislocation.

- J Bone Joint Surg Am* 2002; 84-A: 1183–1188. DOI: 10.2106/00004623-200207000-00014.
12. Gyr BM, Stevens PM and Smith JT. Chronic Monteggia fractures in children: outcome after treatment with the Bell–Tawse procedure. *J Pediatr Orthop B* 2004; 13: 402–406. DOI: 10.1097/01202412-200411000-00011.
 13. Cibula Z, Hrubina M, Melišík M, et al. [Osteotomy after distal radius fractures - Five-year clinical and radiological outcomes]. *Acta Chir Orthop Traumatol Cech* 2018; 85: 254–260.
 14. Park H, Park KW, Park KB, et al. Impact of open reduction on surgical strategies for missed Monteggia fracture in children. *Yonsei Med J* 2017; 58: 829–836. DOI: 10.3349/ymj.2017.58.4.829.
 15. Fowles JV, Sliman N and Kassab MT. The Monteggia lesion in children. Fracture of the ulna and dislocation of the radial head. *J Bone Joint Surg Am* 1983; 65-A: 1276–1282.
 16. Kemnitz S, De Schrijver F and De Smet L. Radial head dislocation with plastic deformation of the ulna in children. A rare and frequently missed condition. *Acta Orthop Belg* 2000; 66: 359–362.
 17. Lädermann A, Ceroni D, Lefèvre Y, et al. Surgical treatment of missed Monteggia lesions in children. *J Child Orthop* 2007; 1: 237–242. DOI: 10.1007/s11832-007-0039-z.
 18. Di Gennaro GL, Martinelli A, Bettuzzi C, et al. Outcomes after surgical treatment of missed Monteggia fractures in children. *Musculoskelet Surg* 2015; 99: S75–S82. DOI: 10.1007/s12306-015-0362-3.
 19. Belangero WD, Livani B and Zogaib RK. Treatment of chronic radial head dislocations in children. *Int Orthop* 2007; 31: 151–154. DOI: 10.1007/s00264-006-0153-4.
 20. Delpont M, Jouve JL, Sales De Gauzy J, et al. Proximal ulnar osteotomy in the treatment of neglected childhood Monteggia lesion. *Orthop Traumatol Surg Res* 2014; 100: 803–807. DOI: 10.1016/j.otsr.2014.06.022.
 21. Bor N. Chronic anterior Monteggia lesions in children: report of 4 cases treated with closed reduction by ulnar osteotomy and external fixation. *J Pediatr Orthop* 2015; 35: 7–10.