

Contents lists available at [ScienceDirect](https://www.sciencedirect.com)

Urology Case Reports

journal homepage: www.elsevier.com/locate/eucr

Transitional cell carcinoma in untreated adult bladder exstrophy: A rare case report

Richardo R. Handoko^a, Jufriady Ismy^{b,*}, Istanul Badiri^c

^a Department of Urology, Faculty of Medicine, Universitas Padjadjaran, Hasan Sadikin Hospital, Bandung, Indonesia

^b Division of Urology, Department of Surgery, Faculty of Medicine, Universitas Syiah Kuala, Zainoel Abidin Hospital, Banda Aceh, Indonesia

^c Department of Pathological Anatomy, Faculty of Medicine, Universitas Syiah Kuala, Zainoel Abidin Hospital, Banda Aceh, Indonesia

ARTICLE INFO

Keywords:

Bladder exstrophy
Transitional carcinoma
Radical cystectomy

ABSTRACT

Untreated adult bladder exstrophy is a very rare entity and has a higher risk of developing bladder cancer. A 41-year old man with acute kidney injury and bilateral hydronephrosis was consulted to Urology Division. Examination revealed bladder exstrophy with suspected malignancy. The incisional biopsy result showed transitional cell carcinoma which is the most common bladder cancer, but extremely rare in bladder exstrophy. Radical cystectomy and urinary diversion with double-barrel ureterocutaneostomy were conducted. Abdominal defect was closed with surgical mesh application and rotational skin flap. The patient was well recovered with improved quality of life.

1. Introduction

Bladder exstrophy is a rare genitourinary malformation. It occurs in 1/46,000 live births. The obvious deformity is usually treated soon after birth, thus bladder exstrophy in adults is very rare. The untreated bladder exstrophy has a higher risk of developing malignancy with age. Adenocarcinoma and squamous cell carcinoma are the most common bladder exstrophy malignancy. Surgical treatment is challenging to achieve complete tumor removal and lower abdominal defect closure.

2. Case presentation

A 41-year-old man was consulted by Internal Medicine Department to Urology Division of Zainoel Abidin Hospital (Aceh, Indonesia) with COVID-19 positive, elevated serum creatinine, and bilateral hydronephrosis. He also complained of complete incontinence since birth. The urine seeped from the suprapubic mass that was covered with a lump of cloth and plastic wrap. Penis was deformed but able to erect and eject semen from its base. The patient lived in remote area and had never received any surgical intervention. Regardless of the condition, he experienced no limitation of daily activities.

On physical examination, there was a 7 × 6 cm sized non-tender, exophytic bladder plate with thickened and easily bled mucosa, suspected neoplasms. Ureteral orifices could not be identified. A 5-cm long

epispadias penis was present below the bladder plate. Scrotum was fully developed with normal bilateral testes. Umbilicus was absent. Anus was normal. There was no palpable inguinal lymph node.

Laboratory analysis showed hemoglobin level 3.4 g/dL, serum urea 443 mg/dL, and serum creatinine 21.8 mg/dL. Ultrasound examination revealed bilateral hydronephrosis. After hemodialysis and blood transfusion, bilateral percutaneous nephrostomy and biopsy of the bladder plate were performed which brought serum creatinine level to 5.7 mg/dL in five days. The biopsy result was invasive transitional cell carcinoma.

Computed tomography scanning revealed absent bladder cavity with calcified mass beneath the thickened and exophytic bladder plate and bilateral hydronephrosis (Fig. 1). Pelvic X-ray showed 8 cm wide separation of the pubic symphysis. Chest X-ray was normal.

The patient underwent radical cystectomy and double-barrel ureterocutaneostomy. Both ureteral stomas were located on the right abdominal side, the left ureteral stoma was above the right stoma. Subsequently, a 12 × 9 cm lower abdominal defect was present. Primary closure with approximation of rectus muscle and skin was not possible. A coated polypropylene surgical mesh was applied. A skin flap from left lower abdomen was rotated to cover the skin defect above the mesh. A vacuum drain was placed to prevent blood and fluid collection between the mesh and skin flap (Fig. 2). Reconstruction of the pubic symphysis and penis was not conducted.

* Corresponding author.

E-mail address: jufriadyismy@unsyiah.ac.id (J. Ismy).

<https://doi.org/10.1016/j.eucr.2022.102004>

Received 19 December 2021; Received in revised form 14 January 2022; Accepted 16 January 2022

Available online 17 January 2022

2214-4420/© 2022 The Authors.

Published by Elsevier Inc.

This is an open access article under the CC BY-NC-ND license

(<http://creativecommons.org/licenses/by-nc-nd/4.0/>).

Histopathological examination revealed transitional cell carcinoma of the bladder, all margins free of tumor (Fig. 3). No adjuvant therapy was given. The patient was recovering well with serum creatinine level 2.6 mg/dL and better quality of life. He had no intention for penile reconstruction in the near future.

3. Discussion

Bladder exstrophy is a rare genitourinary malformation, commonly associated with epispadias and overlying skeletal defects. The incidence is 1/46,000 live births with a male to female ratio 2.3:1. The obvious deformity is usually treated soon after birth, thus bladder exstrophy in

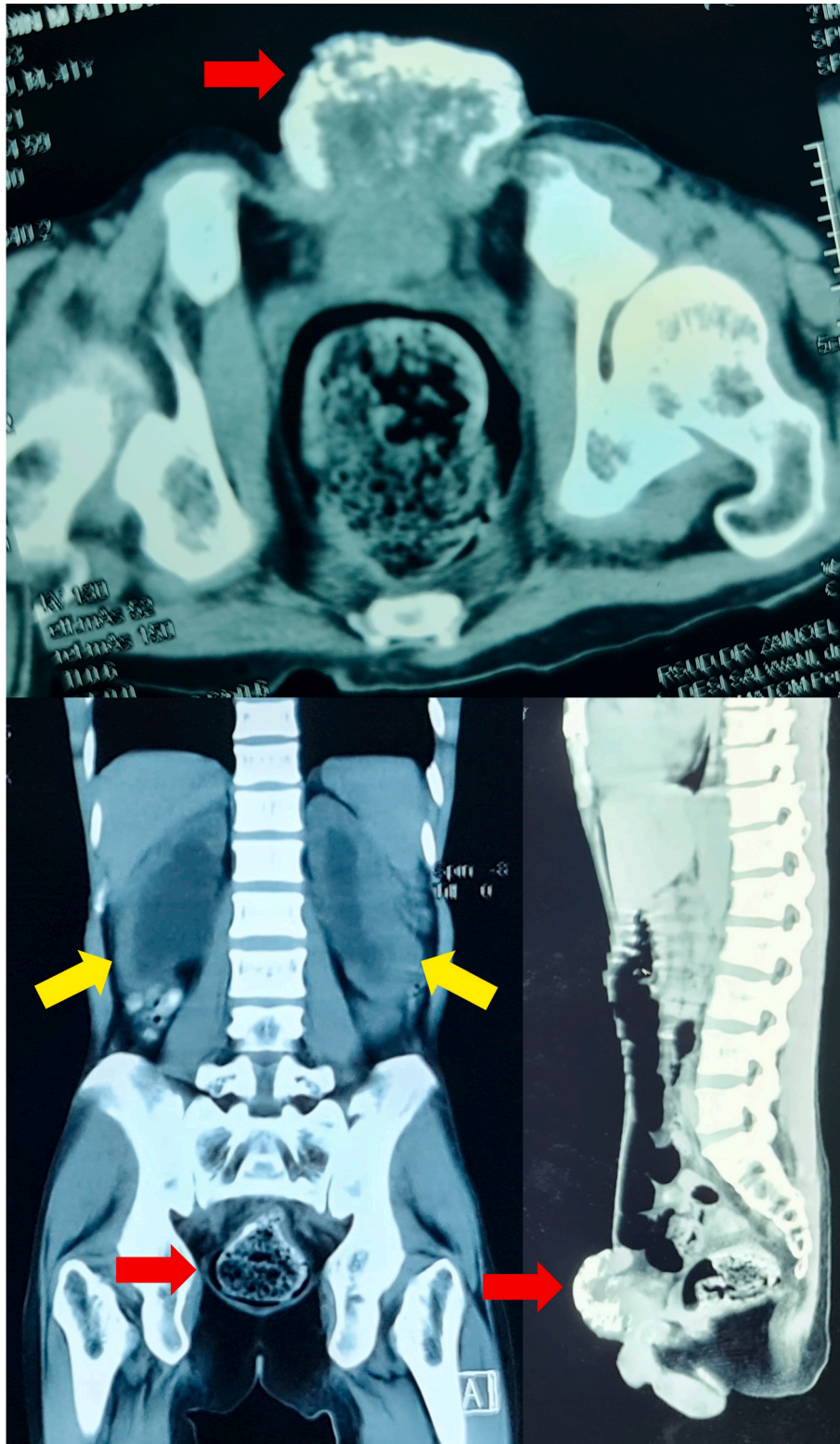


Fig. 1. CT Scan Examination (Red arrow: Bladder exstrophy; Yellow arrow: Bilateral hydronephrosis). (For interpretation of the references to colour in this figure legend, the reader is referred to the Web version of this article.)

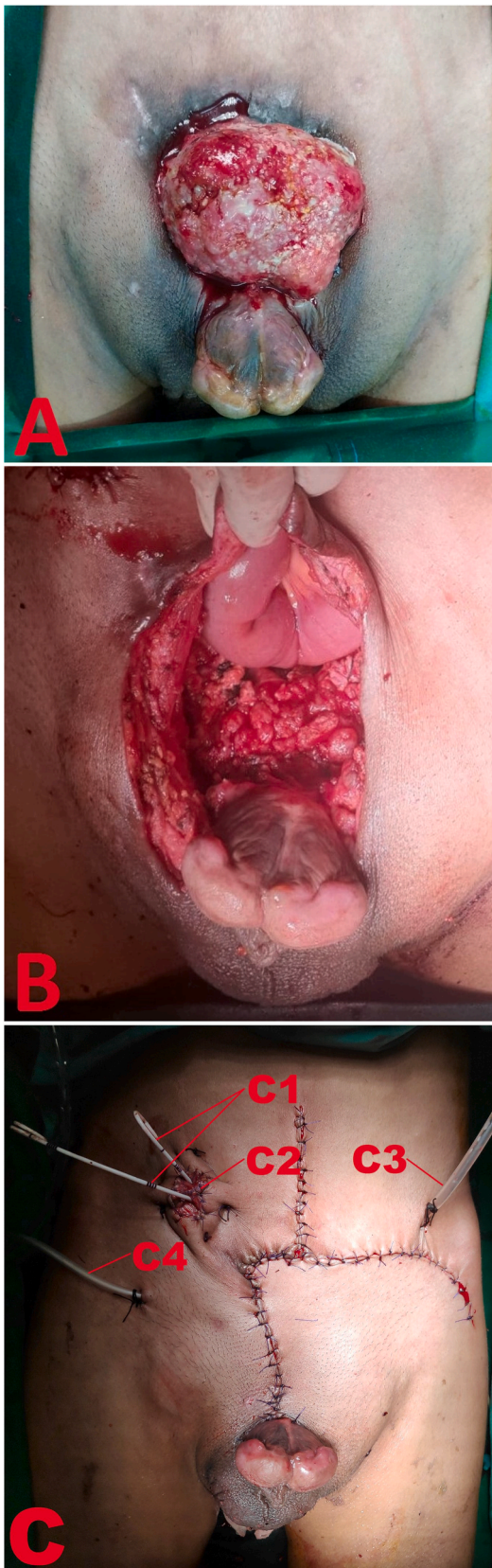


Fig. 2. Clinical presentation (A. Preoperative presentation; B. Lower abdominal defect; C. Post operative presentation; C1. Bilateral Double J Stent; C2. Ureteral stomas; C3. Pelvic drain; C4. Vacuum drain).

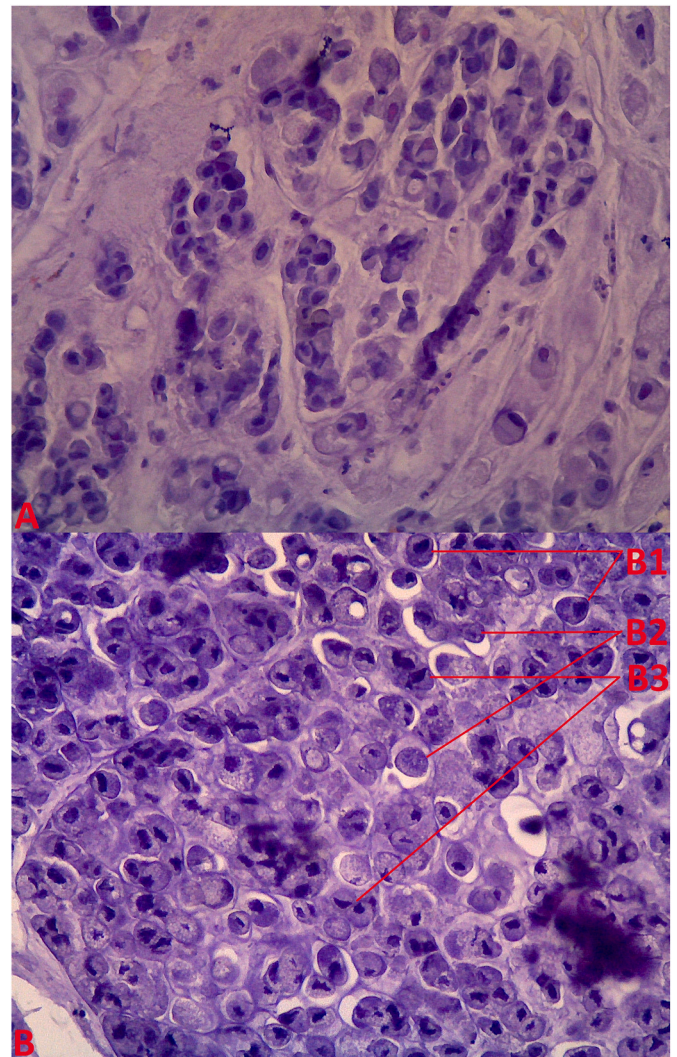


Fig. 3. Microscopic histopathological appearance (A. Incisional biopsy histopathology; B. Radical cystectomy histopathology; B1. Hyperchromatic cells; B2. Pleomorphic cells; B3. Mitotic cells).

adults is extremely rare.¹ As in our patient, poor socio-economic status, lack of education, and remote access to health care are the most common causes of treatment delay. Patients cope up with the anomaly until they seek treatment for the first time in adulthood.² Physical and functional abnormalities are not the only burdens, but also social, sexual, and psychological problems.¹

Bladder exstrophy is classically present as an open, inside-out bladder on the surface of lower abdominal wall.³ If left untreated, the exposed bladder has 694-times higher risk of developing bladder cancer, 60% occurs in the fourth and fifth decade. Although the exact mechanism of tumor development is not clear, long exposure to external environment and chronic irritation seem to be the most logical possibility. Careful screening for any malignant lesions in adult cases is necessary.⁴ Smeulders et al. described the most common malignancies in untreated exstrophy are adenocarcinoma (75–85%) and squamous cell carcinoma (5%).⁵ The histopathological result in our patient showed invasive transitional cell carcinoma which was the most common bladder cancer, but extremely rare in bladder exstrophy. Altered kidney function was caused by obstructed ureteral meatus.

The treatment of bladder exstrophy is challenging. The primary goals are to achieve urinary continence, upper tract preservation, cosmetically acceptable abdominal wall, and external genitalia. In adult patients, the treatment poses several difficult situations. The bladder plate is usually

small, fibrotic, and needs augmentation. Dysplastic/neoplastic changes may be present. The symphysis gap is hardly reduced due to the fusion of pelvic bones.²

The published literature on adult bladder exstrophy is scarce, small sample size, and varied in reconstruction procedures. Several possible treatments are ureterosigmoidostomy, cystectomy with continent reservoir pouch, ileocystoplasty and bladder neck reconstruction. In patients with malignancy, radical cystectomy and urinary diversion are the best treatments. Because of the deficient abdominal wall and anteriorly opened bony pelvis, abdominal closure is very difficult. Osteotomy in adult case was controversial and not conducted in our patient. It may facilitate easier approximation of the soft tissues, but also reduce pelvic stability.²⁻⁴ The role of chemotherapy or radiotherapy cannot be specified due to a small number of patients.⁴ Regardless of various techniques, almost all patients reported improved quality of life.

Our patient underwent radical cystectomy and incontinent urinary diversion due to abnormal renal function. Double-barrel ureterocutaneostomy was chosen rather than ileal conduit to minimize operative time and morbidity since no ileal segment was resected. A surgical mesh was applied to help reconstruct the lower abdominal wall. Reconstruction of epispadias was not planned in this procedure. Later, the patient showed no intention of undergoing the surgery. He was recovering well and had better quality of life.

4. Conclusion

Untreated adult bladder exstrophy is a very rare entity and has a higher risk of developing bladder cancer. Transitional cell carcinoma is the most common bladder cancer, but extremely rare in bladder exstrophy. Radical cystectomy was conducted with surgical mesh application and rotational skin flap for abdominal defect closure. The patient was well recovered with improved quality of life.

References

1. Gearhart JP, Carlo HND. Exstrophy-epispadias complex. In: Partin AW, Dmochowski RR, Kavoussi LR, Peters CA, eds. *Campbell-Walsh-Wein Urology*. 12 ed. Philadelphia: Elsevier, Inc.; 2021.
2. Kiran PS, Panaiyadiyan S, Singh P, Nayak B, Nayyar R, Seth A. Management of untreated classical bladder exstrophy in adults: a single-institutional experience. *Urology*. 2020;146:293–298.
3. Zhu X, Klijn AJ, de Kort LMO. Urological, sexual, and quality of life evaluation of adult patients with exstrophy-epispadias complex: long-term results from a Dutch cohort. *Urology*. 2020;136:272–277.
4. Altan M, Çıtamak B, Haberal HB, et al. Invasive squamous carcinoma and adenocarcinoma of an unreconstructed exstrophic bladder with HPV infection. *Current Urol*. 2015;9(2):109–112.
5. Smeulders N, Woodhouse CRJ. Neoplasia in adult exstrophy patients. *BJU Int*. 2001; 87(7):623–628.