



# Application of Continuous Positive Airway Pressure During Video-Assisted Thoracoscopic Surgery

Javier H. Campos<sup>1</sup> · Dionne Peacher<sup>2</sup>

Accepted: 9 June 2021 / Published online: 10 August 2021

© The Author(s), under exclusive licence to Springer Science+Business Media, LLC, part of Springer Nature 2021

## Abstract

**Purpose of Review** Video-assisted thoracoscopic surgery (VATS) and robotic-assisted thoracoscopic surgery (RATS) are used for anatomic resection of early stage cancer. These surgical techniques require the use of one-lung ventilation (OLV). During OLV, an obligatory intrapulmonary shunt may produce hypoxemia. One method to correct hypoxemia is with the use of continuous positive airway pressure (CPAP). This review focuses on 1) the lung physiology of OLV; 2) application of CPAP in VATS or RATS during supine and lateral position; and 3) the application of CPAP in COVID-19 patients during OLV.

**Recent Findings** Studies have shown the beneficial effects of CPAP to improve oxygenation during OLV while the patient is in the lateral decubitus position. In contrast, studies have shown no benefit on improving oxygenation with CPAP in patients undergoing OLV in supine position.

**Summary** The application of CPAP to the non-dependent lung is one of the options to treat hypoxemia during VATS or RATS.

**Keywords** Video-assisted thoracoscopic surgery (VATS) · Robotic-assisted thoracoscopic surgery (RATS) · Hypoxemia · One-lung ventilation (OLV) · Continuous positive airway pressure (CPAP) · Lung isolation techniques

## Introduction

Video-assisted thoracoscopic surgery (VATS) has become the most common minimally invasive approach for anatomic resection of early-stage lung cancer worldwide [1]. VATS allows for smaller incisions with fewer chest wall traumas and less impact on respiratory mechanics, which has been shown to result in shorter hospital length of stay (LOS), lower rates of pulmonary complications and less postoperative pain when compared with thoracotomy [2]. In addition, with the introduction of the robotic DaVinci technology, robotic video-assisted thoracoscopic surgery (RATS) has become a popular technique in recent years to perform

lobectomies or segmentectomies [3]. Robotic lobectomy uses a completely port-based approach, which is considered the least invasive technology [2–4].

At the present time, many thoracic surgical procedures are performed as a VATS or RATS which requires the use of one-lung ventilation (OLV) with the associated deleterious impairment on oxygenation [5•]. One method to correct hypoxemia and maintain oxygenation is with the use of continuous positive airway pressure (CPAP) during OLV. This review focuses on the following: 1) the lung physiology during OLV, 2) the use of CPAP during supine and lateral decubitus position, in VATS or RATS, 3) the application of CPAP in COVID-19 patients undergoing OLV, and 4) an update on and recommendations for the use of CPAP as an alternative to treat hypoxemia during OLV.

## Lung Physiology of One-Lung Ventilation

One-lung ventilation (OLV) is required in patients undergoing minimally invasive thoracic surgery such as VATS or RATS in order to facilitate surgical exposure. The vast majority of these patients are operated on in a lateral decubitus position and very few surgical procedures are done in a

This article is part of the Topical Collection on *Thoracic Anesthesia*

✉ Javier H. Campos  
javier-campos@uiowa.edu

<sup>1</sup> Department of Anesthesia, University of Iowa Carver College of Medicine, University of Iowa Healthcare, 200 Hawkins Drive, Iowa City, IA 5221, USA

<sup>2</sup> Department of Anesthesia, University of Iowa Carver College of Medicine, Iowa City, IA, USA

supine position. During OLV, an obligatory intrapulmonary shunt may produce hypoxemia because of collapse of the non-dependent lung and the presence of atelectatic areas in the dependent lung due in part to the weight of the mediastinum and the effect that it produces on reducing tidal volume and functional residual capacity on the dependent lung [6].

Hypoxemia during OLV is diagnosed by a decrease in oxygen saturation ( $SPO_2$ ) measured by a pulse oximetry to less than 88–90%, usually these episodes can be transient and usually last a few minutes. In addition, hypoxemia is diagnosed if an arterial oxygen tension ( $PaO_2$ ) is less than 60 mm Hg when the patient is being ventilated at an inspired oxygen fraction ( $FiO_2$ ) of 100%. Episodes of hypoxemia during OLV in VATS or RATS can be detrimental in patients with severe chronic obstructive pulmonary disease or patients with severe history of coronary artery disease [6].

When hypoxemia occurs during OLV, this phenomenon triggers a direct effect on pulmonary vessels due to a low regional partial pressure of alveolar oxygen and activates what is known as hypoxic pulmonary vasoconstriction (HPV) which is considered an auto regulatory mechanism that will decrease the shunt fraction by diverting the pulmonary blood flow to the dependent lung [5•, 7].

### Factors that Predict Hypoxemia During OLV in VATS or RATS

A number of factors may predict which patients are most likely to develop hypoxemia during OLV undergoing VATS or RATS. Patients requiring a right-sided surgery where right lung collapse occurs while left-sided lung ventilation is maintained, in one study [8] it was reported a difference in  $PaO_2$  of 110 mm Hg (280 versus 170 mm Hg) in  $PaO_2$  when right and left lungs were ventilated with a  $FiO_2$  of 100% during OLV. The potential explanation is because the right lung is approximately 10% larger than the left lung there is a better oxygenation during left VATS or RATS than right-sided minimally invasive surgery.

Another factor that might predict hypoxemia during VATS or RATS includes the percentage of forced expiratory volume in seconds ( $FEV_1$ ): an inverse correlation exists between the  $FEV_1$  and  $PaO_2$ . For example, patients who have severe chronic obstructive pulmonary disease may develop auto positive end expiratory pressure (PEEP). The air trapping which occurs at the end of expiration appears to reduce atelectasis and, in the meantime, preserve oxygenation.

In addition, decreased values of  $PaO_2$  intraoperatively during two-lung ventilation in a lateral decubitus position. An interesting study [8] involving lung perfusion studies prior to the surgical procedures demonstrated that the nonventilated and collapsed lung is more impaired in

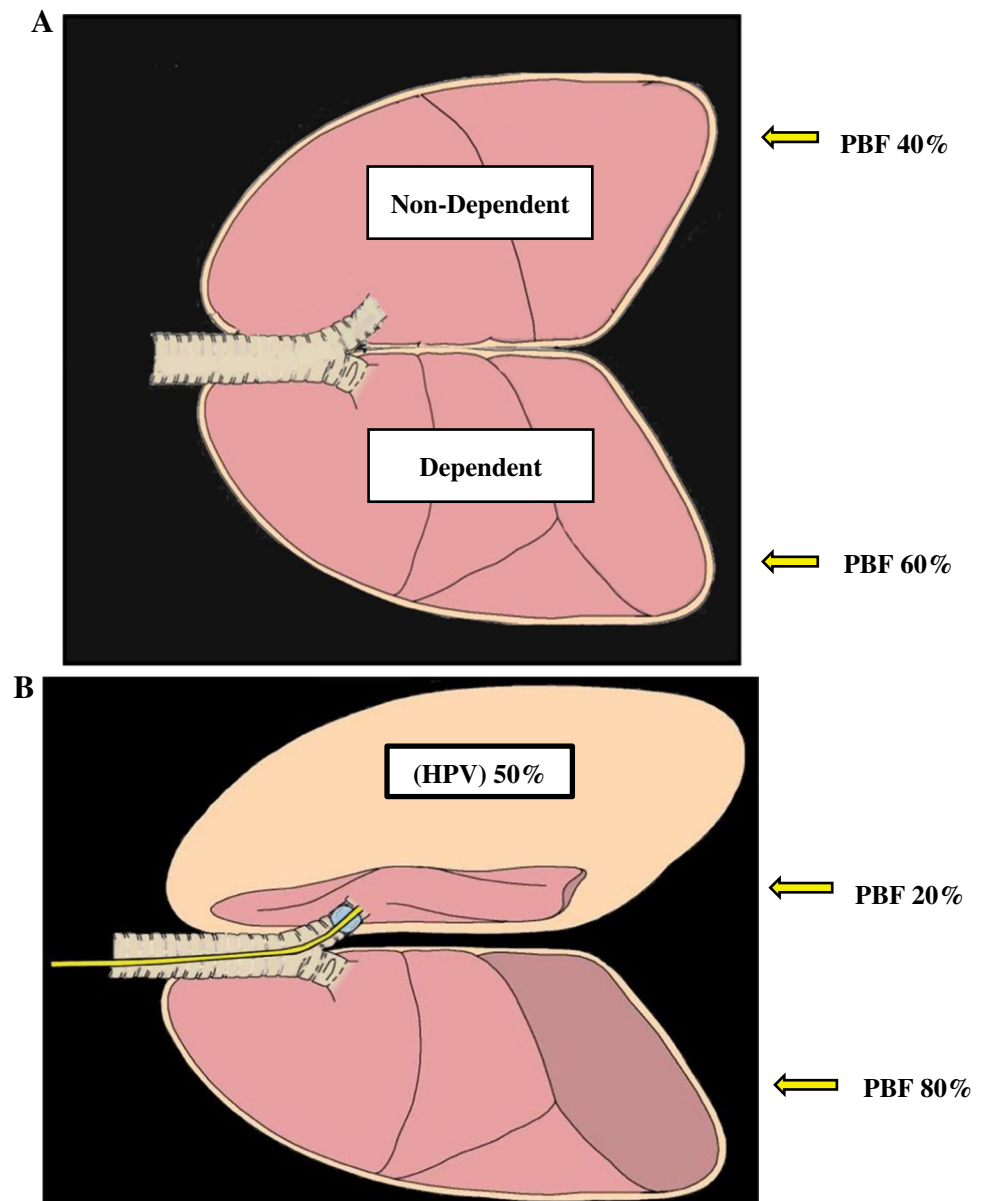
patients undergoing major thoracic surgical procedure such as pneumonectomy or lobectomy than in patients with solitary lung nodes requiring lung biopsy under VATS. A potential explanation is that patients with small tumors with solitary nodes have more perfusion to the non-dependent or operated lung particularly during OLV and probably will experience more transient episodes of hypoxemia in contrast to the large central tumors in patients undergoing pneumonectomy that will have less perfusion to the non-dependent lung and more perfusion to the dependent and ventilated lung during OLV; therefore, oxygenation can be maintained.

Another factor to consider during VATS or RATS is the patient's operative position, since gravity is a major determinant of shunt fraction and perfusion. Studies [9] have shown that the  $PaO_2$  was significantly higher in the group of patients operated in the lateral position undergoing OLV when compared to the group of patients operated on in a supine position. Patients operated in a lateral decubitus position, gravity will augment the redistribution of perfusion to the ventilated lung, in improving and maintaining oxygenation to some degree.

Hypoxemia during OLV is caused by venous and admixture through shunts and areas of low V/Q gas-exchanging units [10]. Studies on the animal model [11] have demonstrated that the maximal HPV response during OLV decreases the pulmonary blood flow to the non-dependent or operated lung by 50%. The amount of shunt fraction during OLV can range from approximately 20 to 40% of the total cardiac output. Factors that can modify the HPV response during OLV in VATS or RATS surgery include the hemodynamic and respiratory changes including severe hypotension, hypocapnia, the presence of severe chronic obstructive pulmonary disease and in some degree the anesthetic agents used [5•].

In a lateral decubitus position when both lungs are being ventilated, the proportion of the pulmonary blood flow is distributed as follows: the dependent lung receives approximately 60% of the pulmonary blood flow (more perfusion) whereas the non-dependent lung receives only 40% of the total pulmonary blood flow. When OLV is required, the non-dependent and collapsed lung becomes atelectatic. Because the alveolar oxygen tension decrease hypoxia sets in and HPV is activated, in which the blood flow is diverted towards the dependent lung, under these conditions the non-dependent lung receives approximately 20% of the total pulmonary blood flow and the dependent lung will receive 80% of the total pulmonary blood flow under stable physiological conditions such as normotension, normocapnia and normothermia. Figure 1 displays the redistribution of pulmonary blood flow in the lateral decubitus position while both lungs are being ventilated.

**Fig. 1** (A) The redistribution of pulmonary blood flow in the lateral decubitus position while both lungs are being ventilated. (B) The atelectatic non-ventilated lung along with the percentage of HPV response. In addition, the ventilated lung presents some atelectatic areas at the base of the lung during general anesthesia. With permission from reference #5 Campos JH, Feider A *J Cardiothorac Vasc Anesth* 2018;32:2330–2338



### The Role of Continuous Positive Airway Pressure in OLV

The application of CPAP to the non-ventilated lung during OLV for thoracic surgery was first described by Capan et al. [12], in 21 patients undergoing pulmonary resection via thoracotomy in lateral decubitus position. In this patient population, CPAP applied to the non-ventilated lung at 10 cmH<sub>2</sub>O improved arterial PO<sub>2</sub> compared to OLV without CPAP to the non-ventilated lung or OLV with positive end expiratory pressure (PEEP) applied to the ventilated or dependent lung. A subsequent study by Slinger et al., improved the technique by demonstrating that CPAP applied after an alveolar recruitment was more effective than CPAP applied to an atelectatic lung in treating intraoperative hypoxemia

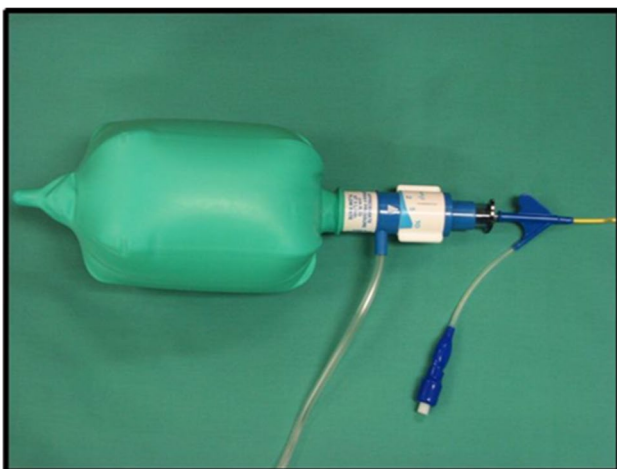
during OLV for thoracotomy [13]. Additional studies in the following decade confirmed the effectiveness of CPAP in OLV [14], demonstrating that levels of CPAP as low as 2 cmH<sub>2</sub>O improved arterial oxygenation [15].

During VATS or RATS after the hypoxemic event is identified, the first intervention is to expand both lungs and inspect the optimal position of the lung isolation device [5•] (please refer to this reference for detailed information). After the proper position is confirmed then the application of CPAP to the non-dependent or collapsed lung is one of the options to treat hypoxemia during OLV in VATS or RATS surgeries. CPAP with oxygen to the non-ventilated lung is a reliable method to improve PaO<sub>2</sub> during OLV. CPAP should be applied to an inflated (recruited) lung to be completely effective. The opening pressure of atelectatic lung regions

is greater than 20 cm H<sub>2</sub>O and the units will not be recruited by simple application of CPAP levels of 5 to 10 cm H<sub>2</sub>O. When CPAP is applied to an inflated lung, levels of CPAP as low as 1 to 2 cm H<sub>2</sub>O can be used. Because the normal transpulmonary pressure of the lung at functional residual capacity is approximately 5 cm H<sub>2</sub>O, levels of 5 to 10 cm H<sub>2</sub>O CPAP applied to a fully recruited lung results in a large-volume lung that impedes surgery particularly during minimally invasive procedures. Lower FiO<sub>2</sub> levels of CPAP are clinically beneficial and can be titrated to the ventilated lung in patients at risk of oxygen toxicity in VATS or RATS by using an air/oxygen blender regulator [16, 17].

There are various anesthetic systems to apply CPAP to the non-ventilated lung. Essentially the system consists of a CPAP valve, oxygen source and reservoir bag. One commercially available CPAP system is the Mallinckrodt® CPAP system (Fig. 2). CPAP application, even when properly administered, is not completely reliable to improve oxygenation during OLV, i.e., when the bronchus is open to atmosphere (bronchopleural fistula or endobronchial surgery). Also, in VATS or RATS where access to operative hemithorax is limited CPAP can significantly interfere with surgery.

CPAP has traditionally been used to treat hypoxemia because of the obligatory shunt developed by the non-dependent (collapsed) lung. Application of CPAP has been suggested in the deflation phase of tidal volume (V<sub>T</sub>) breath. CPAP is thought to improve oxygenation by a passive mechanism (uptake of oxygen by the alveoli with continuous oxygen administration). It is recommended to start with 5 cm H<sub>2</sub>O CPAP and progressively increase to no more than 10 cm H<sub>2</sub>O. For CPAP to work, it must be applied to an at least partially re-expanded lung before it is adjusted to the desired volume [18]. A Mallinckrodt® CPAP system can be



**Fig. 2** Mallinckrodt® continuous positive airway pressure system attached to a center channel of a bronchial blocker

used by attaching the circuit to one of the limb connectors of the double-lumen endotracheal tube (DLT) or the center channel of the bronchial blocker. Figure 2 shows a CPAP circuit attached to a center channel of a bronchial blocker. The beneficial effect of CPAP is primarily due to oxygen uptake from the non-ventilated lung, not to blood flow diversion to the ventilated lung.

### Application of Continuous Positive Airway Pressure During Supine or Lateral Decubitus Position

One-lung ventilation in the supine position spans a number of clinical indications such as anterior mediastinum, and in addition cardiac procedures including surgical ablation of atrial fibrillation by VATS [19, 20]. OLV in the supine position presents an additional management challenge due to the effects of gravity on shunt fraction (Q<sub>s</sub>/Q<sub>t</sub>) and perfusion [9]. Hypoxemia during OLV in the supine position is more frequent and more severe compared with OLV in the lateral decubitus position or semi lateral position [9, 21].

The effects of CPAP on the non-ventilated lung on oxygen delivery (DO<sub>2</sub>) during OLV for surgical ablation of atrial fibrillation via a VATS in the supine position have been reported [22•]. In this prospective, randomized study, the authors evaluated the use of CPAP in the supine position. One group of patients (*n* = 9) received 10 cm H<sub>2</sub>O of CPAP to the non-ventilated lung during OLV, the comparative group received no CPAP. Groups underwent to capnothorax (10 cm H<sub>2</sub>O) during OLV and were managed with standardized ventilation strategies. In their study of 22 patients, the authors reported that CPAP applied to the non-ventilated lung in 9 patients did not improve DO<sub>2</sub>. Cardiac index similarly increased over the course of the data collection period during surgery for both groups. Q<sub>s</sub>/Q<sub>t</sub> and mean pulmonary artery pressure increased during OLV compared with initial two-lung ventilation and remained elevated after resumption of two-lung ventilation, but there were no significant differences between the two groups studied. In particular, decrease of Q<sub>s</sub>/Q<sub>t</sub> was not observed with the application of CPAP during OLV with capnothorax. Based on these findings, the authors concluded that CPAP of the non-ventilated lung was ineffective in reducing Q<sub>s</sub>/Q<sub>t</sub> during OLV in the supine position. In the current state of evidence, the role of CPAP in OLV during surgery in the supine position remains to be fully elucidated [23].

The effectiveness of CPAP on the non-dependent lung during OLV in the lateral decubitus position is augmented when CPAP is applied after an alveolar recruitment maneuver compared to a complete atelectatic lung [18]. Alveolar recruitment is an effective maneuver that reverts alveolar collapse by increasing the transpulmonary pressure. In

contrast to CPAP, PEEP during OLV by adding alveolar recruitment maneuvers and resting functional residual capacity improved arterial oxygenation and ventilatory efficiency during VATS requiring OLV in the supine position. In a prospective, randomized study [19], involving 92 patients undergoing supine VATS for mediastinal procedure, the subjects were divided into two groups; a control group received no PEEP and no alveolar recruitment maneuvers during OLV, and in contrast the study group received an alveolar recruitment maneuvers prior to OLV and application of PEEP 8 cm H<sub>2</sub>O to the dependent lung during OLV. Results showed that the PaO<sub>2</sub> increased with the application of PEEP and alveolar recruitment maneuvers in patients undergoing VATS with capnothorax in patients operated in the supine position. This alternative method has shown beneficial effects in order to improve oxygenation in VATS with patients in the supine position.

### **The Application of Continuous Positive Airway Pressure with the Use of the Bronchial Blocker**

The use of the bronchial blockers has been reported [24] in 45 patients undergoing esophageal tumor surgery using VATS with right-sided lung deflation. This study showed that bronchial blockers are effective alternative for left-OLV with right VATS. Previous studies [17] have shown that the application of CPAP during selective or total lung collapse improves arterial oxygenation during OLV.

The application of CPAP with the use of the bronchial blocker is a different alternative to maintain and improve oxygenation during VATS and OLV [25, 26]. With the use of the bronchial blocker (such as Arndt®, Cohen®, Fuji-Uniblocker® and EZ-blocker®), CPAP can easily be applied by using the center channel of the bronchial blocker and adapting a Mallinckrodt® system while applying 5 L of oxygen [27]. Anesthesiologists infrequently apply CPAP through the center channel of a bronchial blocker because of concerns about lung reinflation. This concern of lung reinflation may be due to improper CPAP application during lung isolation with a bronchial blocker. Lung deflation through a bronchial blocker takes longer than with a DLT due in part to the smaller luminal diameter of the endobronchial blocker.

In a case report [25], the authors recommend that CPAP should not be applied until lung collapse has occurred. The application of CPAP immediately after lung isolation with a bronchial blocker inhibits timely deflation of the lung and makes the VATS and RATS challenging. Clear and direct communication with the surgeon is crucial to coordinate the management of hypoxemia while CPAP is in use and surgery still is in progress.

### **The Role of Continuous Positive Airway Pressure During OLV in VATS**

It is worthwhile to note that the studies that established the technique of CPAP on the non-ventilated lung during OLV [12–15] were conducted prior to the widespread adoption of VATS surgery. In contrast to thoracotomy, VATS introduces an additional challenge of surgical exposure due to limited access to the operative field. Effective lung isolation and maximal lung collapse is even more important in VATS compared to thoracotomy, and any inflation of the operative lung can impede surgical progress [28]. It is a common conception that CPAP applied to the non-ventilated lung in OLV for VATS is likely to disrupt surgical visualization, to the extent that some experts consider CPAP on the non-ventilated lung contraindicated in VATS [29, 30]. This belief may have also influenced the design of some studies that investigated the effectiveness of CPAP in VATS as the study designs avoided an alveolar recruitment maneuver prior to application of CPAP [31, 32]. Evidence to support the negative effect of CPAP on surgical visualization is mixed: impediment of surgical exposure has been reported in some studies [32] and refuted in others [25, 33]. As an alternative to CPAP, some authors have reported effective interventions for hypoxemia during VATS, such as apneic oxygen insufflation of the non-ventilated lung [34], high frequency jet ventilation [33], differential ventilation of the non-ventilated lung [31], and selective lobar oxygen insufflation of the non-ventilated lung using the suction/insufflation channel of the fiberoptic bronchoscope [35]. A summary of selected studies investigating CPAP during OLV in VATS is shown in Table 1.

### **Does Continuous Positive Airway Pressure Impede Surgical Exposure During VATS?**

Reported empiric experience suggests that CPAP applied at 5–10 cm H<sub>2</sub>O to the non-ventilated lung in VATS impedes visualization of the operative field [28]. There is also empiric support that CPAP can be applied to the non-ventilated lung in VATS without impeding surgical exposure [25]. Evidence investigating the quality of surgical visualization and degree of CPAP applied is limited. In a study of CPAP applied at 5 cm H<sub>2</sub>O to the non-ventilated lung in thoracoscopic esophagectomy, interruption of surgical visualization was observed in nearly one-third of patients (9 out of 30). Notably, in this study, alveolar recruitment prior to application of CPAP to the non-ventilated lung was specifically avoided due to concerns regarding disruption of surgical exposure [32]. One study

**Table 1** Studies of the use of continuous positive airway pressure in video-assisted thoracoscopic surgery

Authors	Surgery	Study design	Sample size	Patient position	Level of CPAP (cmH <sub>2</sub> O)	Lung inflation prior to CPAP	Insufflation for operative hemithorax	Control	Intervention	Primary outcome	Secondary outcomes	Key results	Limitations
El-Tahan [33]	Thoracoscopic lung or pleural surgery	Single center prospective randomized Cross-over	Total n = 30 CPAP group n = 15 HFPPV-CPAP group n = 15	Lateral decubitus	2	Inflation to Ppeak 30 cmH <sub>2</sub> O for 30 s	None	CPAP applied to nonventilated lung	HFPPV applied to nonventilated lung	Operative field visualization rated on visual analog scale	Arterial PO <sub>2</sub>	Operative field visualization was better with CPAP than HFPPV	Types of operations included in study limit generalizability Cross-over design

Table 1 (continued)

Authors	Surgery	Study design	Sample size	Patient position	Level of CPAP (cmH <sub>2</sub> O)	Lung inflation prior to CPAP	Insufflation for operative hemithorax	Control	Intervention	Primary outcome	Secondary outcomes	Key results	Limitations
Verhage [32]	Robotic-assisted thoracoscopic esophagectomy	Single center prospective randomized controlled	Total n = 30 CPAP group n = 15 No CPAP group n = 15	Left lateral decubitus	5	None	Not specified	No CPAP applied to nonventilated lung	CPAP applied to nonventilated lung	Pulmonary cytokine reduction (postoperative Interleukin-8)	Pulmonary pneumonia	CPAP reduced local cytokine levels in the non-ventilated lung No difference in serum cytokine levels No difference in hemodynamic/ventilatory variables or clinical outcomes (e.g., pneumonia, length of stay)	Alveolar recruitment maneuver (lung inflation) not performed prior to CPAP Rate of conversion to thoracotomy (5 of 30) may limit clinical applicability of results CPAP discontinued or paused in 9 patients in CPAP group due to surgical field visualization Single operation type (right-sided only approach) limits generalizability

**Table 1** (continued)

Authors	Surgery	Study design	Sample size	Patient position	Level of CPAP (cmH <sub>2</sub> O)	Lung inflation prior to CPAP	Insufflation for operative hemithorax	Control	Intervention	Primary outcome	Secondary outcomes	Key results	Limitations
Kremer [31]	Video assisted thoracoscopic lobectomy	Single center prospective randomized cross-over	Total n = 30 CPAP first group n = 15 Differential lung ventilation first n = 15	Lateral decubitus	5	None	None	CPAP applied to nonventilated lung	Differential lung ventilation (8 breaths per minute, FiO <sub>2</sub> 1.0, tidal volume 50 mL, peak pressure 10 cmH <sub>2</sub> O)	Arterial PO <sub>2</sub>	Spirometry measurements, surgeons' evaluation of surgical field	Differential lung ventilation increased arterial oxygenation compared to OLV with CPAP	Alveolar recruitment maneuver (lung inflation) not performed prior to CPAP Cross-over design
L'Acqua [22•]	Minimally invasive surgical ablation for atrial fibrillation (right VATS)	Single center prospective randomized controlled	Total n = 22 CPAP group n = 9 No CPAP group n = 13	Supine	10	Not specified	10 cmH <sub>2</sub> O capnothorax	No CPAP applied to nonventilated lung	CPAP applied to nonventilated lung	DO <sub>2</sub> (oxygen delivery)	Arterial PO <sub>2</sub> , cardiac index, intrapulmonary shunt (Qs/Qt)	No significant difference in DO <sub>2</sub> , arterial PO <sub>2</sub> , cardiac index, or intrapulmonary shunt between CPAP and No CPAP groups	Underpowered due to change in surgical approach Supine position and right sided only procedure limits generalizability

CPAP continuous positive airway pressure, HFPPV high-frequency positive pressure ventilation, VATS video-assisted thoracoscopic surgery



that demonstrated good surgical field visualization with CPAP applied at 2 cmH<sub>2</sub>O to the non-ventilated lung after an alveolar recruitment maneuver included only relatively peripheral operations in the chest (e.g., bleb resection, bullectomy, pleurectomy, pleurodesis, pleural biopsy, and transthoracic sympathectomy) [36]. Generalization of such a study to other thoracoscopic operations that require reliable visualization of central structures for hilar dissection (e.g., lobectomy) is likely to be limited.

### Application of CPAP in Robotic-Assisted Thoracoscopic Surgery

In addition to cardiovascular and pulmonary considerations related to VATS, RATS can introduce additional challenges due to insufflation of the hemithorax with carbon dioxide to facilitate surgical exposure and enhance visualization. Insufflation is instituted and maintained at a low pressure (less than 15 mmHg) to minimize hemodynamic perturbations; however, lung perfusion and physiology can be affected [37, 38]. Capnothorax at 10 or 15 cm H<sub>2</sub>O has been shown to reduce cardiac index during OLV in VATS, hypothesized to be due to decreased venous return caused by the increased intrathoracic pressure (tension pneumothorax physiology) [39].

Furthermore, application of CPAP to the operative lung in the presence of insufflation of the hemithorax in RATS is likely to be less effective. In order to overcome the intrathoracic pressure from insufflation, the level of CPAP used may need to be increased.

### The Application of Continuous Positive Airway Pressure for COVID-19 Patients

The COVID-19 pandemic has changed the delivery of surgical care for thoracic malignancies and other urgent and elective procedures. The Society of Thoracic Surgeons and other societies have developed guidelines to manage these patients [40, 41•].

The most ideal lung isolation device to use in patients with known or suspected COVID-19 is the one that is most indicated for the specific clinical setting and for which the anesthesiologist is most familiar. A negative/neutral pressure operating room is preferred, and appropriate protective equipment should be worn by all operating room personnel. For bronchoscopy examination in order to confirm the optimal placement of lung isolation device a disposable fiberoptic bronchoscope is recommended [40].

One of the challenges for COVID-19 patients is to treat hypoxemia during OLV with CPAP to the non-ventilated non-dependent lung. A recommendation from the Australian

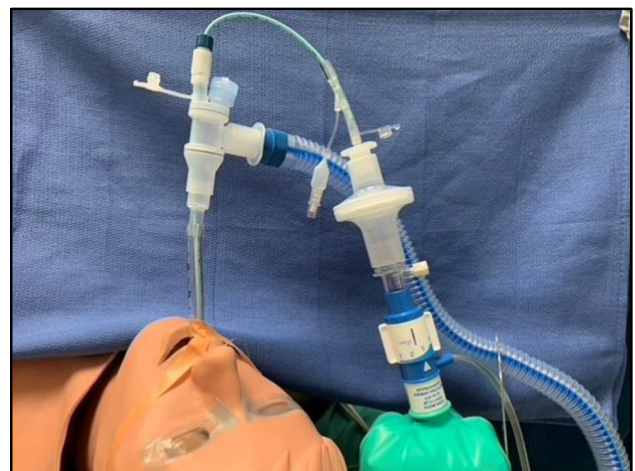and New Zealand Cardiothoracic Surgeons and Anesthesiologists [41•] recommends the use of high efficiency particulate air (HEPA) filter to protect against aerosol generating procedures such as the application of CPAP. A HEPA filter can be attached to a CPAP adapter or the 15 mm connector from a 3.0 ETT fitted to the proximal end to achieve appropriate airborne precautions without limiting deflation of the operative lung. Figure 3 displays the use of HEPA filter along with the Mallinckrodt® system to safely apply CPAP to a COVID-19 positive patient.

### Future Areas of Research

Potential areas of research could include measuring the inflammatory response to the application of CPAP to the non-ventilated lung, along with lung injury due to potential interference with surgery in VATS or RATS. Another area of interest could include the unbiased assessment of lung collapse quality by a thoracic surgeon while different levels of CPAP are applied during VATS or RATS.

### Summary

Studies clearly have shown an improvement on PaO<sub>2</sub> and maintaining oxygenation during the application of CPAP to the non-dependent and collapsed lung during OLV for VATS or RATS while the patient is operated on in lateral decubitus position. At the present time, the use of CPAP for VATS in a supine position is not recommended and finally for a COVID-19-positive patient who requires OLV



**Fig. 3** A Mallinckrodt® continuous positive airway pressure (CPAP) system attached to a HEPA filter to protect against aerosol spread contamination

and needs CPAP a HEPA filter is recommended to prevent aerosol spread.

## Compliance with Ethical Standards

**Conflict of Interest** The authors declare no competing interests.

**Human and Animal Rights and Informed Consent** This article does not contain any studies with human or animal subjects performed by any of the authors.

## References

### • Of importance

- Ng CSH, MacDonald JK, Gilbert S, Khan AZ, Kim YT, Louie BE, et al. Expert Consensus Statement on Optimal Approach to Lobectomy for Non-Small Cell Lung Cancer. *Innovations*. 2019;14:87–9.
- Power AD, Merritt RE, Abdel-Rasoul M, Moffatt-Bruce SD, D'Souza DM, Kneuert PJ. Estimating the risk of conversion from video-assisted thoracoscopic lung surgery to thoracotomy—a systematic review and meta-analysis. *J Thorac Dis*. 2021;13:812–23.
- Kneuert PJ, D'Souza DM, Moffatt-Bruce SD, Merritt RE. Robotic lobectomy has the greatest benefit in patients with marginal pulmonary function. *J Cardiothorac Surg*. 2018;13:56.
- Kneuert PJ, Singer E, D'Souza DM, Abdel-Rasoul M, Moffatt-Bruce SD, Merritt R. Hospital cost and clinical effectiveness of robotic-assisted versus video-assisted thoracoscopic and open lobectomy: A propensity score-weighted comparison. *J Thorac Cardiovasc Surg*. 2019;157:2018–26.
- Campos JH, Feider A. Hypoxia During One-Lung Ventilation—A Review and Update. *J Cardiothorac Vasc Anesth*. 2018;32:2330–8 **This is a review article expanding on hypoxia during OLV. This is one of the latest reviews on the topic with specific details step by step on how to manage hypoxia during OLV.**
- Campos JH. Hypoxia during Thoracic Surgery. *ASA Refresher Course*. 2016;1–7
- Lumb AB, Slinger P. Hypoxic pulmonary vasoconstriction: physiology and anesthetic implications. *Anesthesiology*. 2015;122:932–46.
- Schwarzkopf K, Klein U, Schreiber T, Preussetaler NP, Bloos F, Helfritsch H, et al. Oxygenation during one-lung ventilation: the effects of inhaled nitric oxide and increasing levels of inspired fraction of oxygen. *Anesth Analg*. 2001;92:842–7.
- Bardoczky GI, Szegedi LL, d'Hollander AA, Moures JM, de Franquien P, Yernault JC. Two-lung and one-lung ventilation in patients with chronic obstructive pulmonary disease: the effects of position and FiO<sub>2</sub>. *Anesth Analg*. 2000;90:35–41.
- Ward DS. Intra-Operative Ventilation Strategies for Thoracic Surgery. In: Slinger P, editor. *Principles and Practice of Anesthesia for Thoracic Surgery*. New York: Springer; 2011. p. 297–308.
- Glasser SA, Domino KB, Lindgren L, Parcella P, Marshall C, Marshall BE. Pulmonary blood pressure and flow during atelectasis in the dog. *Anesthesiology*. 1983;58:225–31.
- Capan LM, Turndorf H, Patel C, Ramanathan S, Acinapura A, Chalon J. Optimization of Arterial Oxygenation during One-Lung Anesthesia. *Anesth Analg*. 1980;59:847–51.
- Slinger P, Triolet W, Wilson J. Improving Arterial Oxygenation during One-lung Ventilation. *Anesthesiology*. 1988;68:291–5.
- Cohen E, Eisenkraft JB, Thys DM, Kirschner PA, Kaplan JA. Oxygenation and hemodynamic changes during one-lung ventilation: Effects of CPAP<sub>10</sub>, PEEP<sub>10</sub>, and CPAP<sub>10</sub>/PEEP<sub>10</sub>. *J Cardiothorac Anesth*. 1988;2:34–40.
- Hogue CW Jr. Effectiveness of low levels of nonventilated lung continuous positive airway pressure in improving arterial oxygenation during one-lung ventilation. *Anesth Analg*. 1994;79:364–7.
- Slinger PD, Campos JH. Anesthesia for Thoracic Surgery, Chapter. 53. In: *Miller's Anesthesia*. 9th ed. 2020. p. 1648–1716
- Campos JH. Effects on oxygenation during selective lobar versus total lung collapse with or without continuous positive airway pressure. *Anesth Analg*. 1997;85:583–6.
- Campos JH. Hypoxia during Thoracic Surgery: Practical Advice for the Anesthesiologist. *ASA Refresher Course*. 2013;41:38–46.
- Choi YS, Bae MK, Kim SH, Park JE, Kim SY, Oh YJ. Effects of Alveolar Recruitment and Positive End-Expiratory Pressure on Oxygenation during One-Lung Ventilation in the Supine Position. *Yonsei Med J*. 2015;56:1421–7.
- Hedenstierna G, Tening A. The lung during and after thoracic anaesthesia. *Curr Opin Anaesthesiol*. 2005;18:23–8.
- Rollin A, Mandel F, Grunenwald E, Mondoly P, Monteil B, Marcheix B, et al. Hybrid surgical ablation for persistent or long standing persistent atrial fibrillation: A French single centre experience. *Ann Cardiol Angeiol*. 2020;69:86–92.
- L'Acqua C, Meli A, Rondello N, Polvani G, Salvi: CPAP Effects on Oxygen Delivery in One-Lung Ventilation During Minimally Invasive Surgical Ablation for Atrial Fibrillation in The Supine Position. *J Cardiothorac Vasc Anesth*. 2020;34:2931–6 **This is a recent research study on the CPAP effects on oxygen delivery in OLV in minimally invasive surgery in the supine position. The authors showed that the use of CPAP is not effective on reducing the Qs/Qt an increase arterial partial pressure of oxygen in minimally invasive surgery in supine position.**
- Peacher D, Campos JH. Is There a Role for Continuous Positive Airway Pressure Application During One-Lung Ventilation for Video-Assisted Thoracoscopic Surgery in the Supine Position? *J Cardiothorac Vasc Anesth*. 2020;34:2937–9.
- Lu Y, Dai W, Zong Z, Xiao Y, Wu D, Li X, et al. Bronchial Blocker Versus Left Double-Lumen Endotracheal Tube for One-Lung Ventilation in Right Video-Assisted Thoracoscopic Surgery. *J Cardiothorac Vasc Anesth*. 2018;32:297–301.
- Pineda P, Awad H, Essandoh M. Hypoxemia Treatment During Lung Isolation With an Endobronchial Blocker: Continuous Positive Airway Pressure Application Should Be Common Practice. *J Cardiothorac Vasc Anesth*. 2019;33:2104–5.
- Sumitani M, Matsubara Y, Mashimo T, Takeda S. Selective lobar bronchial blockade using a double-lumen endotracheal tube and bronchial blocker. *Gen Thorac Cardiovasc Surg*. 2007;55:225–57.
- Campos J. Lung Isolation. Chapter 16 in *Principles and Practice of Anesthesia for Thoracic Surgery*. Springer Nature Switzerland; 2019. pp. 283–309
- Bailey J, Mikhail M, Haddy S, Thangathurai D. Problems with CPAP during one-lung ventilation in thoracoscopic surgery. *J Cardiothorac Vasc Anesth*. 1998;12:239.
- Şentürk M, Slinger P, Cohen E. Intraoperative mechanical ventilation strategies for one-lung ventilation. *Best Pract Res Clin Anaesthesiol*. 2015;9:357–69.
- Lohser J. Managing hypoxemia during minimally invasive thoracic surgery. *Anesthesiol Clin*. 2012;30:683–97.
- Kremer R, Aboud W, Haberfeld O, Armaili M, Barak M. Differential lung ventilation for increased oxygenation during one

- lung ventilation for video assisted lung surgery. *J Cardiothorac Surg.* 2019;14:89.
32. Verhage RJ, Boone J, Rijkers GT, Cromheecke GJ, Kroese AC, Weijs TJ, et al. Reduced local immune response with continuous positive airway pressure during one-lung ventilation for oesophagectomy. *Br J Anaesth.* 2014;112:920–8.
  33. El-Tahan MR, El Ghoneimy YF, Regal MA, El Emam H. Comparative study of the non-dependent continuous positive pressure ventilation and high-frequency positive-pressure ventilation during one-lung ventilation for video-assisted thoracoscopic surgery. *Interact Cardiovasc Thorac Surg.* 2011;12:899–902.
  34. Jung DM, Ahn HJ, Jung S-H, Yang M, Kim JA, Shin SM. Apneic oxygen insufflation decreases the incidence of hypoxemia during one-lung ventilation in open and thoracoscopic pulmonary lobectomy: A randomized controlled trial. *J Thorac Cardiovasc Surg.* 2017;154:360–6.
  35. Ku CM, Slinger P, Waddell TK. A novel method of treating hypoxemia during one-lung ventilation for thoracoscopic surgery. *J Cardiothorac Vasc Anesth.* 2009;23:850–2.
  36. Boisen ML, Fernando RJ, Kolarczyk L, Teeter E, Schisler T, LaColla L, et al. The Year in Thoracic Anesthesia: Selected Highlights from 2020. *J Cardiothorac Vasc Anesth.* <https://doi.org/10.1053/j.jvca.2021.04.012>
  37. Campos JH, Ueda K. Update on Anesthetic Complications of Robotic Thoracic Surgery. *Minerva Anesthesiol.* 2014;80:83–8.
  38. McCall P, Steven M, Shelley B. Anaesthesia for video-assisted and robotic thoracic surgery. *BJA Educ.* 2019;19:405–11.
  39. Brock H, Rieger R, Gabriel C, Pölz W, Moosbauer W, Neccek S. Haemodynamic changes during thoracoscopic surgery the effects of one-lung ventilation compared with carbon dioxide insufflation. *Anaesthesia.* 2000;55:10–6.
  40. Pritchett MA, Ober CL, Belanger A, De Cardenas J, Cheng G, Nacheli GC, et al. Society for Advanced Bronchoscopy Consensus Statement and Guidelines for bronchoscopy and airway management amid the COVID-19 pandemic. *J Thorac Dis.* 2020;12:1781–98.
  41. Irons JF, Pavey W, Bennetts JS, Granger E, Tutungi E, Almeida A. COVID-19 safety: aerosol-generating procedures and cardiothoracic surgery and anaesthesia - Australian and New Zealand consensus statement. *Med J Aust.* 2021;214:40–4 **The authors have done an excellent review and recommendations to prevent aerosol generating procedures in thoracic anesthesia including the recommendation of HEPA filters in the CPAP system.**

**Publisher's Note** Springer Nature remains neutral with regard to jurisdictional claims in published maps and institutional affiliations.