

# Topiramate-induced acute bilateral angle closure glaucoma confirmed by ultrasound biomicroscopy

Osama AlNageeb<sup>1</sup>, Saud Aljohani<sup>2</sup>, Abdulaziz Alshehri<sup>1</sup>

## Access this article online

Quick Response Code:



## Website:

www.saudijophthalmol.org

## DOI:

10.4103/1319-4534.322600

## Abstract:

Topiramate is a sulfamate-substituted monosaccharide used in the treatment of epilepsy and migraines. This case report demonstrates a 29-year-old female who complained of severe bilateral loss of vision 14 days after using topiramate for her migraine. On initial examination, visual acuities were counting fingers in both eyes. Intraocular pressures were 55 mmHg and 58 mmHg in the right and left eyes, respectively. Anterior segment examination showed bilateral conjunctival chemosis, mild corneal edema, and markedly shallow anterior chambers with closed angles on gonioscopy. Ultrasound biomicroscopy revealed bilateral anterior rotation of ciliary body with choroidal effusion. Topiramate was immediately discontinued, topical and systemic anti-glaucomatous treatment was administered. After 1-week follow-up, the patient had fully recovered.

## Keywords:

Bilateral angle closure, Saudi, topiramate

## INTRODUCTION

Topiramate is classified as a sulfamate -substituted monosaccharide, it was used in 1996 for the treatment of epilepsy. In 2004, topiramate was repurposed as a prophylaxis treatment for migraines, and other indications includes infantile spasms, neuropathic pain, smoking cessation, postherpetic neuralgia, and others.<sup>[1]</sup> Importantly, the side effects of topiramate which is rare, many of which are unfavorable, including bilateral acute angle closure glaucoma, massive choroidal effusion, unilateral hemianopsia, and irreversible maculopathy.<sup>[2]</sup>

Here, we report a case of bilateral acute angle closure glaucoma with choroidal effusion after use of topiramate. To the best of our knowledge, this is one of the first case to be reported in the Kingdom of Saudi Arabia (KSA).

## CASE REPORT

A 29-year-old Saudi female presented herself to the emergency department in Dhahran Eye

Specialist Hospital complaining of acute bilateral blurred vision and eye pain associated with a severe frontal headache for 1 day.

Two weeks prior to the presentation, the patient began taking oral topiramate (50 mg), twice daily as a prophylaxis for migraine.

Initial examination revealed visual acuity of finger counting at two meters OU. Pupils were round, regular with sluggish reaction OU. Intraocular pressures (IOP) by Goldmann tonometry were 55 mmHg OD and 58 mmHg OS. Anterior segment examination showed bilateral conjunctival chemosis, mild corneal edema, and markedly shallow anterior chambers (ACs). Gonioscopy revealed 360 degrees of angle closure OU. Fundus examination showed cup disc ratio 0.5 and flat retina in both eyes. The ultrasound biomicroscopy (UBM) showed bilateral closed angles, anterior rotation of the ciliary body (CB) with choroidal effusion [Figure 1a and b].

Based on the patient assessment, a diagnosis of acute bilateral angle closure glaucoma was made. Accordingly, topiramate use was immediately discontinued, and the patient was started on topical anti-glaucoma (timolol 0.5%, brimonidine 0.15%, latanoprost 0.005%, and dorzolamide 2%) and

<sup>1</sup>Dhahran Eye Specialist Hospital, Dhahran, <sup>2</sup>Imam Abdulrahman Bin Faisal University, Dammam, Saudi Arabia.

## Address for correspondence:

Dr. Saud Aljohani,  
Imam Abdulrahman Bin Faisal  
University, Dammam, Saudi  
Arabia.  
E-mail: alameer1212@hotmail.  
com

Submitted: 16-Feb-2019

Revised: 19-May-2019

Accepted: 07-Oct-2019

Published: 29-Jul-2021

This is an open access journal, and articles are distributed under the terms of the Creative Commons Attribution-NonCommercial-ShareAlike 4.0 License, which allows others to remix, tweak, and build upon the work non-commercially, as long as appropriate credit is given and the new creations are licensed under the identical terms.

For reprints contact: WKHLRPMedknow\_reprints@wolterskluwer.com

**How to cite this article:** AlNageeb O, Aljohani S, Alshehri A. Topiramate-induced acute bilateral angle closure glaucoma confirmed by ultrasound biomicroscopy first case reported in Saudi Arabia. Saudi J Ophthalmol 2020;34:316-8.

systemic (intravenous acetazolamide 500 mg) medications. After one hour, the IOP was 50 mmHg and 38 mmHg in the left and right eyes, respectively. The patient was hospitalized, and IOP in both eyes on the 2<sup>nd</sup> day had fallen to 38 mmHg. Furthermore, BCVA had improved to 20/200 OU. Anterior segment examination showed shallow AC and sluggish reaction of the pupil.

The patient was discharged on full anti-glaucoma medications plus (Prednisolone 1% and Atropine 1%). On the 5<sup>th</sup> day after having discontinued topiramate treatment, the patient's BCVA was 20/22 OU, and the pupils responded normally. The AC depth was within the normal limit [Figure 2a and b], and the IOP values were 9 mmHg OD and 7 mmHg OS. Gonioscopy revealed an open angle in both eyes, while UBM indicated a normal angle and CB configuration in both eyes [Figure 3a and b].

## Discussion

Acute angle closure glaucoma (AACG) is a devastating condition that leads to optic nerve damage with visual field defect and vision impairment if IOP is persistent. These patients may present with eye pain, headache, blurred vision, nausea, and vomiting.

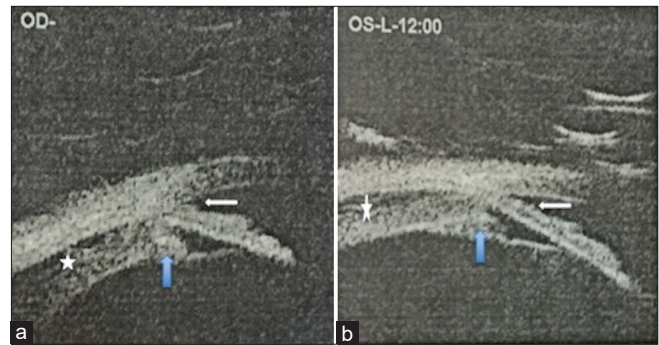
Given the short axial length of the globe, particularly in hyperopic patients, AACG is a prevalent condition in the KSA, as well as in other parts of Asia.<sup>[3]</sup>

Primary angle closure glaucoma incidence is highest in sixth and seventh decades of life, and most attacks are unilateral, with just 5% to 10% of the cases affecting both eyes simultaneously.<sup>[4]</sup> Based on the younger age, history of topiramate usage and bilateral attacks in our case, primary angle closure glaucoma was less likely in this patient.

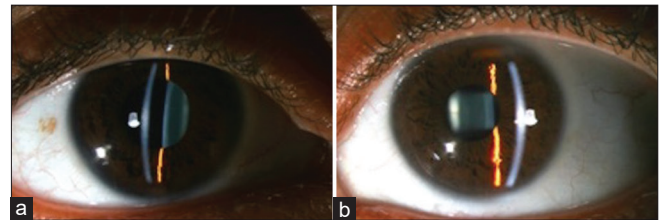
Secondary causes were therefore considered, including drug-induced or forward displacement of the lens diaphragm (e.g., due to high pressure posterior to the lens arising from ciliochoroidal effusion, aqueous misdirection, or massive subretinal hemorrhage). The UBM confirmed ciliochoroidal effusion in the present case. Esam *et al.*, drew attention to another uncommon cause of bilateral angle closure glaucoma in a female hyperopic patient. This patient presented with acute angle closure glaucoma several hours after hyperopic laser *in situ* keratomileusis correction.<sup>[3]</sup>

Angle closure glaucoma onset generally occurs within 2 weeks of topiramate administration, but it can happen anywhere between 1 and 49 days.<sup>[5]</sup> In the present case, the patient presented with the condition 2 weeks after starting the topiramate. Furthermore, delayed topiramate-induced bilateral angle closure may occur after several months.<sup>[5]</sup>

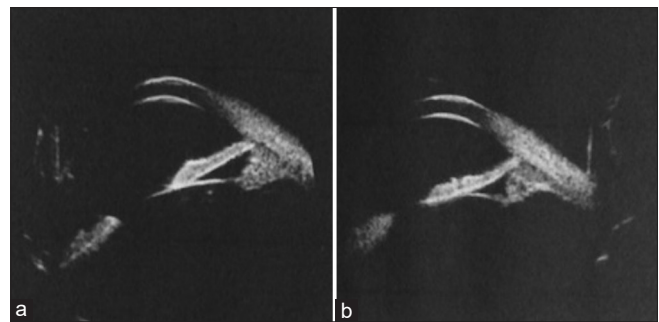
Kang *et al.* examined the mechanism of action of ciliochoroidal effusion and CB edema in terms of causing acute angle closure glaucoma. The researchers explained how CB edema and anterior choroidal effusion resulted in the anterolateral rotation of the ciliary processes around the scleral spur, thereby shifting the lens-iris diaphragm forward and moreover, obliterating the ciliary sulcus. As a consequence of these mechanisms, this



**Figure 1:** (a and b) Ultrasound biomicroscopy shows angle closure with shallow anterior chamber (white arrow), anterior rotation of ciliary body (blue arrow) with suprachoroidal effusion in both eyes (asterisk)



**Figure 2:** (a and b) Normal anterior chamber depth in both eyes



**Figure 3:** (a and b) Normal angle and ciliary body configuration in both eyes

leads to the shallow AC.<sup>[6]</sup> Comparable findings were observed with UBM in the present case report, indicating that CB edema and ciliochoroidal effusion may result in bilateral angle closure.

In the earlier study conducted by Kang *et al.*, two cases of topiramate-induced bilateral angle closure glaucoma were discussed. In both cases, the IOP normalization was achieved by topical administration of anti-glaucoma medications.<sup>[6]</sup>

In this case, a review of the medical history, critical thinking, and analysis of the pertinent findings were crucial in identifying the key elements when making a diagnosis. Review of the patient's history and medication revealed significant factors.

Topiramate may cause CB rotation, leading to anterior displacement of the lens-iris diaphragm and causing acute angle-closure glaucoma. However, normalization of the intraocular pressure and AC depth can be successfully achieved after discontinuation of topiramate and initiation

of antiglaucoma therapy. The widespread use of topiramate and its evident potentially blinding side effects has resulted in the counseling of patients and their prescribing providers of the medication becoming increasingly important. To the best of our knowledge, this is the first case to be reported in the KSA that addresses topiramate-induced bilateral acute angle closure glaucoma.

### Declaration of patient consent

The authors certify that they have obtained all appropriate patient consent forms. In the form the patient(s) has/have given his/her/their consent for his/her/their images and other clinical information to be reported in the journal. The patients understand that their names and initials will not be published and due efforts will be made to conceal their identity, but anonymity cannot be guaranteed.

### Financial support and sponsorship

Nil.

### Conflicts of interest

There are no conflicts of interest.

### REFERENCES

1. Quagliato LB, Barella K, Abreu Neto JM, Quagliato EM. Topiramate-associated acute, bilateral, angle-closure glaucoma: Case report. *Arq Bras Oftalmol* 2013;76:48-9.
2. Abtahi MA, Abtahi SH, Fazel F, Roomizadeh P, Etemadifar M, Jenab K, *et al.* Topiramate and the vision: A systematic review. *Clin Ophthalmol* 2012;6:117-31.
3. Osman EA, Alsaleh AA, Al Turki T, Al Obeidan SA. Bilateral acute angle closure glaucoma after hyperopic LASIK correction. *Saudi J Ophthalmol* 2009;23:215-7.
4. Lan YW, Hsieh JW. Bilateral acute angle closure glaucoma and myopic shift by topiramate-induced ciliochoroidal effusion: Case report and literature review. *Int Ophthalmol* 2018;38:2639-48.
5. Czyz CN, Clark CM, Justice JD, Pokabla MJ, Weber PA. Delayed topiramate-induced bilateral angle-closure glaucoma. *J Glaucoma* 2014;23:577-8.
6. Kang YK, Son BJ, Park DH, Shin JP. Angiographic features of drug-induced bilateral angle closure and transient myopia with ciliochoroidal effusion. *BMC Ophthalmol* 2019;19:213.