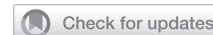

## TRANSGENDER HEALTH

# Comparison of Permanent Hair Removal Procedures before Gender-Affirming Vaginoplasty: Why We Should Consider Laser Hair Removal as a First-Line Treatment for Patients Who Meet Criteria



Nance Yuan, MD,<sup>1,5</sup> Alexandra Terris Feldman, BA,<sup>1</sup> Patrick Chin, BA,<sup>1,2</sup> Michael Zaliznyak, BA,<sup>3</sup> Susan Rabizadeh, MD, MBA,<sup>1,4</sup> and Maurice M. Garcia, MD, MAS<sup>1,5,6,7</sup>

## ABSTRACT

**Introduction:** Permanent genital hair removal is required before gender-affirming vaginoplasty to prevent hair-related complications. No previous studies have directly compared the relative efficacy, costs, and patient experiences with laser hair removal (LHR) vs electrolysis treatments. Food and Drug Administration (FDA) oversight of medical devices is poorly understood and commonly misrepresented, adversely affecting patient care.

**Aim:** This study compares treatment outcomes of electrolysis and LHR for genital hair removal and investigates FDA regulation of electrolysis and LHR devices.

**Methods:** Penile-inversion vaginoplasty and shallow-depth vaginoplasty patients completed surveys about their preoperative hair removal, including procedure type, number/frequency of sessions, cost, and discomfort. Publicly available FDA-review documents and databases were reviewed.

**Main Outcomes Measure:** Compared to electrolysis, LHR was associated with greater efficiency, decreased cost, decreased pain, and improved patient satisfaction.

**Results:** Of 52 total (44 full-depth and 8 shallow-depth) vaginoplasty patients, 22 of 52 underwent electrolysis only, 15 of 52 underwent laser only, and 15 of 52 used both techniques. Compared to patients that underwent LHR only, patients that underwent only electrolysis required a significantly greater number of treatment sessions (mean 24.3 electrolysis vs 8.1 LHR sessions,  $P < .01$ ) and more frequent sessions (every 2.4 weeks for electrolysis vs 5.3 weeks for LHR,  $P < .01$ ) to complete treatment (defined as absence of re-growth over 2 months). Electrolysis sessions were significantly longer than LHR sessions (152 minutes vs 26 minutes,  $P < .01$ ). Total treatment costs for electrolysis (\$5,161) were significantly greater than for laser (\$981,  $P < .01$ ). Electrolysis was associated with greater pain and significantly increased need for pretreatment analgesia, which further contributed to higher net costs for treatment with electrolysis vs laser. Many LHR and electrolysis devices have been FDA-cleared for safety, but the FDA does not assess or compare clinical efficacy or efficiency.

**Clinical Implications:** For patients with dark-pigmented hair, providers should consider LHR as the first-line treatment option for preoperative hair removal before gender-affirming vaginoplasty.

**Strength and Limitations:** This is the first study to compare electrolysis and LHR for genital hair removal. The discussion addresses FDA review/oversight of devices, which is commonly misrepresented. Limitations include the survey format for data collection.

**Conclusion:** When compared with electrolysis, LHR showed greater treatment efficiency (shorter and fewer treatment sessions to complete treatment), less pain, greater tolerability, and lower total cost. Our data suggests that, for patients with dark genital hair, providers should consider recommending laser as the first-line treatment for permanent genital hair removal before vaginoplasty. **Yuan N, Feldman A, Chin P, et al.**

Received March 3, 2022. Accepted June 21, 2022.

<sup>1</sup>Cedars-Sinai Transgender Surgery and Health Program, Cedars-Sinai Medical Center, Los Angeles, CA, USA;

<sup>2</sup>David Geffen School of Medicine, UCLA, Los Angeles, CA, USA;

<sup>3</sup>Saint Louis University School of Medicine, St. Louis, MO, USA;

<sup>4</sup>Department of Dermatology, Cedars-Sinai Medical Center, Los Angeles, CA, USA;

<sup>5</sup>Division of Urology, Cedars-Sinai Medical Center, Los Angeles, CA, USA;

<sup>6</sup>Department of Urology, University of California San Francisco, San Francisco, CA, USA;

<sup>7</sup>Department of Anatomy, University of California San Francisco, San Francisco, CA, USA

Copyright © 2022 The Authors. Published by Elsevier Inc. on behalf of the International Society for Sexual Medicine. This is an open access article under the CC BY-NC-ND license (<http://creativecommons.org/licenses/by-nc-nd/4.0/>).  
<https://doi.org/10.1016/j.esxm.2022.100545>

## Comparison of Permanent Hair Removal Procedures before Gender-Affirming Vaginoplasty: Why We Should Consider Laser Hair Removal as a First-Line Treatment for Patients Who Meet Criteria. *Sex Med* 2022;10:100545.

Copyright © 2022 The Authors. Published by Elsevier Inc. on behalf of the International Society for Sexual Medicine. This is an open access article under the CC BY-NC-ND license (<http://creativecommons.org/licenses/by-nc-nd/4.0/>).

**Key Words:** Hair Removal; Laser; Electrolysis; Vaginoplasty; Transgender; Gender-Affirming Surgery

## INTRODUCTION

Penile-inversion vaginoplasty is the first-line treatment for feminizing genital gender-affirming surgery (gGAS), which can significantly improve quality of life and mental health for patients suffering from gender dysphoria.<sup>1–3</sup> Because hair-bearing penile and/or scrotal skin are used to line the neovaginal canal, preoperative permanent genital hair removal is crucial for avoiding postoperative complications from intravaginal hair, including chronic infections, folliculitis, malodor, hairballs/calculi, dyspareunia, externally visible hair, and worsened gender dysphoria.<sup>4,5</sup> Hair removal must be completed preoperatively, as hair becomes inaccessible once inside the vaginal canal. The World Professional Association for Transgender Health *Standards of Care* guidelines emphasize the importance of avoiding use of hair-bearing skin for genital reconstructive surgery.<sup>6</sup>

Electrolysis and laser hair removal (LHR) are both techniques that can achieve permanent hair removal over many sessions.<sup>7–9</sup> Few studies have directly compared the efficacy, cost, and tolerability of these 2 techniques.<sup>8,10</sup> Furthermore, no prior studies have compared electrolysis and laser for removal of genital hair,<sup>8,10</sup> which has anatomy and physiology different from hair in other body regions.<sup>11</sup>

Understanding relative outcomes of electrolysis and LHR is crucial for helping patients select the most optimal hair-removal techniques in preparation for surgery. Optimizing the process of hair removal has the potential to significantly improve patients' quality of life by minimizing delays in proceeding with surgery, maximizing efficiency and tolerability, and minimizing cost.

U.S. Food and Drug Administration (FDA) oversight of hair-removal devices is poorly understood by both patients and providers. In the United States, electrolysis is frequently touted as “the only FDA-approved method of permanent hair removal,”<sup>12</sup> which is inaccurate. Poor understanding of FDA processes negatively impacts patient counseling on hair-removal options.

## Study Aims

The overarching goal of this study is to provide evidence-based real-world research data to guide patient counseling and treatment for preoperative genital hair removal.<sup>13–15</sup> We seek to answer the following questions: Is preoperative permanent hair removal of the genital area and limbs of patients undergoing genital gender affirming surgery

is *more efficient* (defined as the time duration of each individual treatment, total number of individual treatments, total time to complete all treatments), *more cost-effective*, and *better tolerated* with treatment using Laser, as compared to electrolysis?

## Relevance and Timeliness of the Study Aims

This work is timely because there is a lack of literature to assess the absolute and comparative effectiveness and efficiency of these 2 modalities for permanent hair removal of the genitals and extremities. This work is relevant because permanent hair removal treatment of the aforementioned body-areas is recognized as a *standard of care* preoperative requirement before genital gender affirming surgery where hair-bearing skin is transposed into a reconstructed body cavity.

## MATERIALS AND METHODS

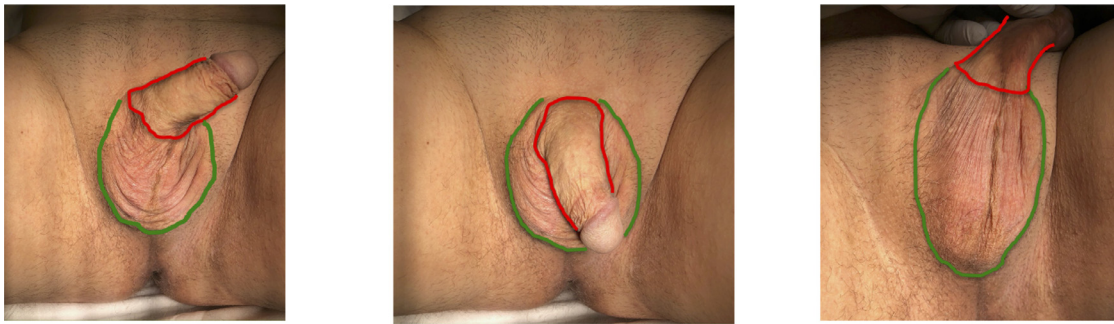
This study was approved by our Institutional Review Board (Protocol #00055933).

## Clinical Survey

We surveyed all consecutive patients undergoing primary penile-inversion vaginoplasty or shallow-depth vaginoplasty at our institution between August 2017 and November 2020. Patients were asked about the following: preoperative genital hair-removal treatment type (electrolysis, laser, or both); number, duration, and frequency of treatment sessions; use of pain medications; pain/discomfort level; and treatment and pain-medication costs. Cost was defined as the full cost billed to insurance (including patient co-pay) or the full cost charged to the patient in cases of no insurance coverage.

Patients were asked to rate treatment-related pain as well as dissatisfaction based on non-pain factors, such as personal discomfort, embarrassment, or inconvenience. These were each rated on a Likert scale from 1 to 10 (1 = no pain/dissatisfaction; 10 = extreme pain/dissatisfaction). Patients that underwent both LHR and electrolysis rated each technique separately.

All patients were examined before and after hair-removal treatments. Exclusion criteria included vaginoplasty techniques other than penile-inversion or shallow-depth vaginoplasty, hair removal before initial consultation, hair removal in a country



**Figure 1.** Skin of the penis and scrotum before vaginoplasty surgery. *Red outline:* Patients undergoing vaginoplasty *with* or *without* creation of a vaginal canal are required to undergo permanent hair removal of the entire penis shaft. This is because most people with a penis have hair growth at the shaft-base and the mid-shaft, and with vaginoplasty, this skin will be used to construct the clitoris hood and the vulva skin located between the clitoris and vaginal introitus areas. *Green outline:* The green outline marks the anterior, lateral, and posterior borders of the scrotum, which is easily distinguished from surrounding groin and perineal skin by the prominent rugae present on scrotal skin. Patients who will undergo vaginoplasty with creation of a vaginal canal augmented by use of scrotal skin (ie, circumcised patients and others whose shaft skin is insufficient to line the entire vaginal canal), must undergo permanent hair removal from the entire scrotum. (Color version of figure is available online.)

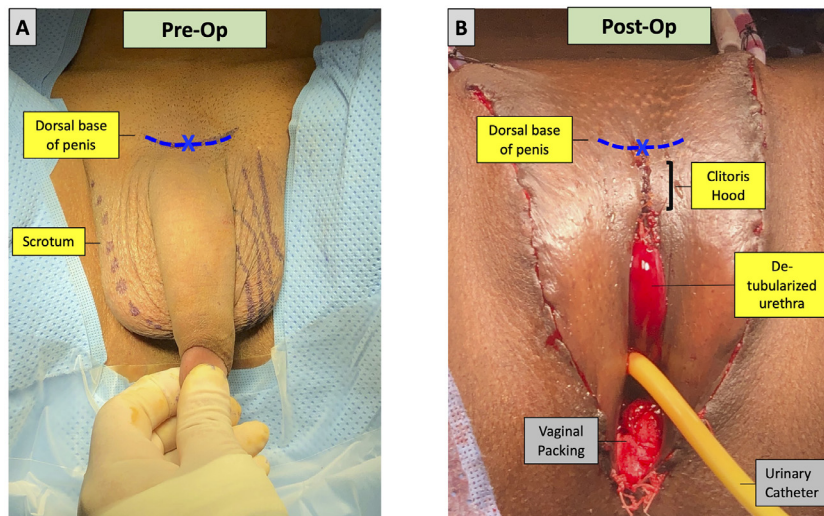
other than the United States (to minimize geographic variability in cost and device types), and treatments including concurrent hair removal of non-genital body areas. All patients were assessed for gross hair re-growth (using speculum exam and urethroscopy) at follow-up visits at 3–4 months postop.

**Patient Instructions Regarding Preoperative Permanent Hair Removal**

In our practice, patients undergoing vaginoplasty with or without creation of a vaginal canal are instructed to complete

permanent hair removal of the entire penile shaft and penile base as shown in **Figure 1**. This skin becomes skin surrounding the neo-clitoris, urethra, and vaginal introitus and would be painful or dangerous to treat postoperatively (**Figure 2**). Patients with expected need for scrotal skin grafts to line the neovaginal canal are also instructed to have hair removed from the entire scrotum.

All patients were counseled to continue treatments until achieving fewer than 5 hairs of regrowth in the treatment area for 2 consecutive months after the last treatment. Hair-free status was confirmed immediately before surgery. All subjects included in the present study met these criteria.



**Figure 2.** A. Penis and scrotum before vaginoplasty surgery. The *blue hatched line* and “X” mark the dorsal base of the penis shaft, at midline. Penis skin has no ink markings, whereas the scrotum has been marked with ink, so that skin originating from each can be distinguished in the postvaginoplasty photo (B). B. Immediate postvaginoplasty. Note that the skin corresponding to the dorsal base of the penis *preop* is located anterior to the skin used to construct the clitoris hood (*bracket*), and is easily accessible for additional permanent hair removal treatments postop. Note that all skin medial to the surgical scar line is derived from penis shaft skin, and none is from the scrotum. Hence, any hair-bearing skin posterior to the blue line (ie, penis shaft) will reside postop in an undesirable location (either within the folds of the clitoris hood, or, along skin immediately lateral to the pink de-tubularized urethra, which will be the *Labia minora*).

## Data Collection and Analysis

Results for electrolysis and LHR were compared. Fitzpatrick skin-color types (Fitzpatrick I–VI; I = fair to VI = dark) were recorded.<sup>16,17</sup> Statistical analysis was performed using Student's t-Test, Mann-Whitney U-test, or Chi-square test, as indicated. Statistical significance was defined as  $P < .05$  on a 2-tailed test.

Subset analysis for combination treatment with both electrolysis and LHR was performed. To better represent the combined effects of both techniques together, patients that used both techniques were excluded from subset analysis if they only underwent a minimal treatment amount with one of the techniques (defined as  $\leq 10\%$  of average total treatment time needed to reach hair-free status with that technique alone).

## Review of U.S. Food and Drug Administration (FDA) Published Statements and Databases

The FDA website ([www.fda.gov](http://www.fda.gov))<sup>18</sup> was searched using relevant key terms, including “hair removal,” “electrolysis,” and “laser.” We contacted representatives from the FDA's Division of Industry and Consumer Education<sup>19</sup> by phone and email to confirm FDA regulatory processes. With assistance from FDA representatives, we searched the FDA's 510k clearance database<sup>20</sup> specifically for electrolysis and LHR devices and reviewed their statements/ summaries.

## RESULTS

Of 52 patients who underwent vaginoplasty and completed the survey, 42% underwent electrolysis only, 29% underwent laser only, and 29% underwent both electrolysis and laser (Table 1). Patients in all treatment categories reflected the full spectrum of Fitzpatrick skin-color types.

**Table 1.** Hair-removal technique by vaginoplasty technique

	All	Full-depth vaginoplasty	Shallow-depth vaginoplasty
Total patients; <i>n</i>	52	44	8
Electrolysis ONLY; <i>n</i> (%)	22/52 (42.3%)	19/44 (43.2%)	3/8 (37.5%)
Laser ONLY; <i>n</i> (%)	15/52 (28.8%)	10/44 (22.7%)	5/8 (62.5%)
Both electrolysis AND laser; <i>n</i> (%)	15/52 (28.8%)	15/44 (34.1%)	0 (0%)

**Table 2.** Mean session duration and overall time to completion using a single-hair removal technique: full-depth vaginoplasty

Full-depth vaginoplasty	Electrolysis ( <i>n</i> = 19)	Laser ( <i>n</i> = 10)	<i>P</i> -value
Number of sessions (SD)	24.3 (18.5)	8.1 ( $\pm$ 2.3)	<.001*
Session duration (SD)	152.6 (94.5) min	13.7 (8.2) min	<.001*
Time between individual sessions (SD)	2.4 (2.0) wk	5.3 (0.9) wk	<.001*
Net treatment time spent in sessions (SD)	48.1 (38.4) h	1.9 (1.46) h	.010*
Total treatment time, all sessions (SD)	41.4 (29.0) wk	44.3 (14.5) wk	.362

Presented values = mean; SD= standard deviation.

\*Indicates that the P value is <0.05 (i.e. statistically significant; with a 2-tailed alpha of 0.05 and Power = 0.80).

## Pre and Postsurgery Clinical Outcomes

All patients in this series met the stated hair removal criteria before proceeding with surgery, and had 5 or fewer re-grown hairs within the entire treatment area. In clinical follow-up, no patient in this series was found to have more than 5 hairs of re-growth within the treatment area during the initial 4-month postoperative period.

## Treatment Duration, Frequency, and Time to Completion to Achieve Total Treatment Completion

All patients met criteria for treatment completion (interval regrowth of fewer than 5 hairs within the treatment area) before surgery and study evaluation/data collection. For full-depth vaginoplasty patients that used only 1 hair-removal technique, mean duration of LHR sessions (13.7 minutes) to achieve complete hair removal was significantly shorter than that of electrolysis sessions (153 minutes,  $P < .01$ ) (Table 2). LHR-only patients required significantly fewer and less frequent sessions to complete treatment. Net time spent undergoing treatment (all treatment sessions combined) was significantly shorter for LHR ( $1.9 \pm 1.5$  total hours) than for electrolysis ( $48.1 \pm 38.4$  hours,  $P = .01$ ).

Although there were too few shallow-depth vaginoplasty patients for formal statistical analysis, the shallow-depth vaginoplasty group showed trends similar to the full-depth vaginoplasty group (Table 3). LHR was associated with fewer and less frequent sessions, shorter treatment sessions, and less net time spent undergoing treatment.

## Pain and Dissatisfaction

LHR was significantly less painful than electrolysis (Table 4). Most electrolysis patients (91.7%) required pain medication during treatments, with 47.2% of electrolysis patients using local injected anesthetic. The remainder used topical medications. In

**Table 3.** Mean session duration and overall time to completion using only a single hair-removal technique: shallow-depth vaginoplasty

Shallow-depth vaginoplasty	Electrolysis (n = 3)	Laser (n = 5)
Number of sessions (SD)	13.7 (14.4)	10.6 (0.9)
Mean session duration (SD)	222 (35) min	26.0 (13.9) min
Time between individual sessions (SD)	2.5 (2.1) wk	4.5 (1.7) wk
Net treatment time spent in sessions (SD)	44.7 (33.1) h	4.7 (2.7) h
Total treatment time, all sessions (SD)	35.7 (34.6) wk	48.4 (19.8) wk

Presented values = mean; SD= standard deviation.

**Table 4.** Usage/cost of pretreatment medication, pain, and treatment satisfaction scores, by hair-removal technique

	Electrolysis (n = 36)	Laser (n = 30)	P-value
Used any anesthetic, n (%)	33/36 (91.7%)	10/30 (33.3%)	<.001*
Used injections of local anesthetic, n (%)	17/36 (47.2%)	0/30 (0%)	<.001*
Used topical anesthetic, n (%)	16/36 (44.4%)	10/30 (33.3%)	.22
Pain rating (SD), Likert: 1–10, 10 = worst pain imaginable	6.9 (2.7)	4.4 (2.8)	<.001*
Dissatisfaction rating (SD), non-pain related; Likert: 1–10, 10 = extremely dissatisfied	6.3 (3.1)	3.6 (2.8)	<.001*

Presented values = mean; SD = standard deviation; USD = U.S. dollars.

\*Indicates that the P value is <0.05 (i.e. statistically significant; with a 2-tailed alpha of 0.05 and Power = 0.80).

contrast, only 33.3% of laser patients used any pain medication; only topical medication was used. Pain and dissatisfaction scores were both higher for electrolysis (mean pain 7.0, dissatisfaction 6.2) than for LHR (mean pain 4.3, dissatisfaction 3.4;  $P < .01$ ).

### Treatment Cost

Overall treatment costs were significantly lower for LHR than for electrolysis (Table 5). Individual LHR sessions were

less expensive than electrolysis sessions, even though each LHR session treats the entire field, whereas each electrolysis session only treats part of the field. For both full-depth vaginoplasty and shallow-depth vaginoplasty patients, the net cost of all combined sessions to complete treatment (excluding pain medication) was much less expensive and less variable with LHR than with electrolysis. For full-depth vaginoplasty, average net cost was \$962 for LHR, compared to \$5161 for electrolysis ( $P < .001$ ).

**Table 5.** Net treatment cost, by hair-removal technique

	Electrolysis only	Laser only	P-value
Cost per session (for all vaginoplasty techniques), USD (SD)	\$284.1 (\$261.8)	\$138.9 (126.6)	.005*
Full-depth vaginoplasty			
Net cost without pain medication, USD (SD)	\$5,160.8 (\$4042.1)	\$961.7 (\$703.9)	<.001*
Net cost with pain medication, USD (SD)	\$5,703.1 (\$4,785.6)	\$973.3 (\$698.1)	<.001*
Mean additional cost of pain medication (including all medication types and patients with no medication use), USD (SD)	\$616 (\$1,020)	\$2 (\$4.5)	.015
Mean additional cost of pain medication for patients that used injected local anesthesia, USD (SD)	\$1,470 (\$1,475)	-	-
Mean additional cost of pain medication for patients that used topical anesthesia, USD (SD)	\$270.1 (\$201.8)	\$5 (\$5)	-
Shallow-depth vaginoplasty			
Net cost without pain medication, USD (SD)	\$4,350.0 (\$2,757.7)	\$1,234.0 (\$659.4)	-
Net cost (with pain medication)	\$4,450.0 (\$2,616.3)	\$1,240 (\$656.8)	-
Mean additional cost of pain medication (including all medication types and patients with no medication use), USD (SD)	\$475 (\$275)	\$7.5 (\$13.0)	-
Mean additional cost of pain medication for patients that used injected local anesthesia, USD (SD)	\$475 (\$275)	-	-
Mean additional cost of pain medication for patients that used topical anesthesia, USD (SD)	-	\$30 (1 patient)	-

Presented values = mean; SD = standard deviation; USD = U.S. dollars; statistical comparisons not performed when sample sizes were small.

\*Indicates that the P value is <0.05 (i.e. statistically significant; with a 2-tailed alpha of 0.05 and Power = 0.80).

Significantly increased pain-medication requirements with electrolysis further widened the cost gap between laser and electrolysis. When including all patients (including patients using any medication type and patients with no medication use), full-depth vaginoplasty patients that underwent electrolysis exclusively incurred an average additional \$616 ( $\pm 1,020$ ) for pain medication, whereas patients that used LHR exclusively incurred only an average additional \$2 ( $\pm 4.5$ ) due to pain medication ( $P = .015$ ). Injected local anesthesia, which was only required for electrolysis, was particularly expensive. For full-depth vaginoplasty patients that used injected local anesthesia during electrolysis, mean total pain-medication cost for all treatments was \$1470. Full-depth vaginoplasty patients using topical anesthesia during electrolysis still incurred mean total \$270.1 for pain medication alone. In contrast, most LHR patients did not use any topical pain medication at all; when they did, the cost averages were only \$5 for full-depth vaginoplasty.

### Combined Laser and Electrolysis Treatment

After applying criteria as described in Methods, 8 patients were included in subset analysis for combination treatment with both LHR and electrolysis. As this small group showed significant heterogeneity in relative proportions of each treatment and the sequence of treatments, statistical comparison with LHR-only and electrolysis-only groups was not feasible. However, it was noted that 6 (75%) patients in the combination-treatment group had total hair-removal costs that were less than the average net cost in the “electrolysis only” group.

### Clarification of FDA Oversight of LHR and Electrolysis

The FDA clarified that it has no role in judging the superiority of one technology over another. Instead, the FDA regulates individual medical devices using a risk-based, tiered approach<sup>21</sup> to ensure consumer safety. While the term “FDA approval” is commonly used by the lay public, only the highest-risk devices (class III), such as mechanical heart valves or implantable infusion pumps, receive FDA “approval.” Electrolysis and laser devices are lower-risk class II devices that instead undergo “clearance,” a different and less rigorous process that allows for device marketing. 510k clearance involves demonstrating that a device is “substantially equivalent” to an already legally marketed device in safety and effectiveness<sup>20</sup> for a particular indication, but no specific level of effectiveness must be achieved. Of note, early devices marketed in the U.S. before 1976, such as earlier-generation electrolysis devices, were grandfathered into the system as pre-amendment devices and considered 510k exempt, without undergoing the same clearance process.

While electrolysis devices are FDA-cleared for “permanent hair removal,” LHR devices are cleared for “permanent hair reduction.” This difference in language/terminology is due to the device clearance process itself and *not* due to differences in

clinical efficacy. Early electrolysis devices had already been in use for many years before FDA regulation began. In contrast, LHR devices had much less data available at the time of initial clearance. Per the FDA, the term “permanent hair reduction” was selected to reflect the data available at the time.

## DISCUSSION

Electrolysis and LHR can both be used for permanent genital hair removal in preparation for gender-affirming vaginoplasty.<sup>4,5,22–25</sup> Direct comparison studies of these 2 techniques for non-genital hair support LHR’s superiority with regards to efficiency, cost, and patient satisfaction.<sup>8,10</sup> This study is the first to compare electrolysis and LHR for genital hair removal. Our findings show that, in patients with dark hair, LHR is associated with improved efficiency, decreased costs, decreased pain, and improved patient satisfaction. This study also clarifies common misconceptions about the FDA and its regulation of electrolysis and LHR devices.

### Electrolysis

With electrolysis, a hair-removal technique first reported in 1875,<sup>10,26</sup> a thin wire-needle is inserted into/beside each hair follicle to destroy it via electric current.<sup>24,25,27,28</sup> Types of electrolysis include galvanic electrolysis, which uses low-flow direct current to trigger a destructive intra-follicular chemical reaction<sup>12,25,28–30</sup> and thermolysis,<sup>12,29</sup> which destroys follicle germinative cells by heating water molecules with high-frequency alternating current.<sup>27</sup> Thermolysis is faster but less effective and is associated with regrowth of 20%–40% of treated follicles.<sup>12</sup> Newer electrolysis methods that blend galvanic and thermolysis techniques have become the preferred technology for most providers today to maximize treatment speed and efficacy.<sup>7,30,31</sup>

Electrolysis is generally effective for all skin and hair colors and types,<sup>25,32</sup> but results can vary for thicker or curved hairs.<sup>7</sup> Treatment efficacy is especially operator-dependent, as outcomes rely on exact needle positioning.<sup>27,29</sup> Regrowth rates vary<sup>33</sup> and can be as high as 15%–40%, even when performed by “skilled” electrologists.<sup>12,31</sup> Treatment risks include skin scarring, pigment changes, and inflammation.<sup>12,34</sup> Due to the slow “hair by hair” labor-intensive nature of electrolysis, this technique is impractical for larger areas of hair-bearing skin.<sup>33</sup>

### Laser Hair Removal

Compared to electrolysis, LHR is significantly newer and ever-evolving, with the first lasers for LHR marketed in the 1990s.<sup>35</sup> LHR damages hair follicles through photo-thermolysis that selectively targets intrafollicular melanin.<sup>12,24,33</sup> Because LHR works only on naturally dark melanin-bearing hair follicles, it is ineffective on white, blonde, or red hair. Experimental strategies with topical exogenous chromophores to sensitize naturally

light-colored hair have had limited success<sup>36</sup> and are not currently standard clinical practice.

Various lasers of different wavelengths (including intense pulsed light, Nd:YAG, diode, alexandrite, and ruby)<sup>37,38</sup> have been used for LHR. Each afford unique benefits and risks.<sup>39,40</sup> Destruction of hair follicles can be optimized by adjusting specific laser parameters, such as wavelength, fluence, and pulse duration.<sup>41</sup> Widely accepted advantages of LHR include treatment efficiency, affordability, and tolerability.<sup>42–46</sup> LHR can quickly target large areas of hair.<sup>24,25</sup> Three treatments can achieve 30%–70% hair reduction, with additional treatments leading to 90% or more clearance.<sup>35</sup> With appropriate settings, LHR patients typically report only minor, temporary side effects, with minimal risk of scarring.<sup>45,47</sup>

One common misconception regarding LHR is that it is only effective in patients with light skin tones, due to competitive light absorption from epidermal melanin.<sup>48</sup> Multiple studies have actually found satisfactory results with LHR in darker-skinned patients (Fitzpatrick IV–VI). Nd:YAG lasers are considered the safest and most effective option for darker skin.<sup>41,44,49,50</sup> One meta-analysis of comparison trials for LHR with various laser types recommends diode laser for lighter skin and Nd:YAG laser for darker skin.<sup>37</sup> Our study had all Fitzpatrick skin types well-represented in all treatment categories. Corroborating prior studies, we found excellent hair clearance among patients with darker skin.

### Comparison of Laser and Electrolysis—Efficiency and Pain

Though electrolysis is often touted as having “permanent” results, studies have found hair regrowth rates of at least 20%.<sup>12</sup> Both electrolysis and LHR are nearly always associated with *some* degree of hair regrowth.<sup>11,23,33,44,51–56</sup> Many studies support the durability of LHR results.<sup>23,33,44,51–56</sup> One study reported that both diode and alexandrite lasers resulted in over 70% hair clearance lasting 18 months (the study duration) after 6 treatments.<sup>57</sup> Another found maintenance of LHR results for about twenty years (the study duration).<sup>58</sup> LHR is also up to 60 times faster than electrolysis.<sup>24</sup>

LHR has been reported to be less painful than electrolysis,<sup>8,59,60</sup> with high patient satisfaction.<sup>61</sup> Topical anesthetics provide adequate pain control.<sup>62,63</sup> Our study confirmed this, with no LHR patients requiring injected local anesthesia and only a third using topical anesthetics. In contrast, almost all (91.7%) electrolysis patients needed some form of anesthesia, with nearly half requiring injected local anesthesia. Although electrolysis patients used much more anesthesia, pain and dissatisfaction scores were still higher in the electrolysis group.

Our findings show that LHR is associated with increased efficiency and decreased pain compared to electrolysis, corroborating prior comparison studies on non-genital hair. One U.K. study treated participants with LHR on one-half of the face and

electrolysis on the other half.<sup>10</sup> Twenty-four of 25 patients (96%) reported significantly higher satisfaction with LHR. LHR was also more efficacious: after five treatments, LHR resulted in 77% hair reduction, whereas electrolysis resulted in only 55% reduction.<sup>9</sup> Similarly, a trial comparing LHR with electrolysis in the axillary region<sup>8</sup> found that LHR was associated with less pain and greater hair clearance (70% clearance for LHR vs 35% for electrolysis) 6 months from initial treatment.

Patients should be allotted ample preoperative time to complete hair removal, given the lengthy total time required for any technique. Pre-operative hair-removal progress should be monitored at serial clinic visits, as the total number of required treatments varies. Patients should be counseled that total treatment time and cost can vary significantly.

### Comparison of Laser and Electrolysis—Cost

Transgender patients encounter significant financial barriers to treatment<sup>64</sup> that can worsen dysphoria and mental stress.<sup>65</sup> Hair-removal costs are often not covered by insurance.<sup>9,28,66</sup> This study confirms prior findings that LHR treatment is more cost-effective than electrolysis,<sup>24,60</sup> even when not accounting for the costs of pre-treatment pain medication. Increased medication requirements with electrolysis further widen the cost gap between electrolysis and LHR.

Health-insurance companies should consider categorical coverage of both LHR and electrolysis, with LHR considered the first-line treatment for dark hair, and electrolysis the first-line treatment for red and light/white hair. Such policy changes would likely yield improved treatment efficiency and optimized costs and patient satisfaction. Furthermore, given our study’s findings that electrolysis is painful even with pre-medication with analgesics, such analgesics should be considered a necessary part of electrolysis and thus considered for insurance coverage.

### Combination Treatment with Laser and Electrolysis

Given the clear advantages of LHR over electrolysis, we hypothesized that combination therapy with *both* techniques would lead to improvements in treatment time, pain, and cost when compared to electrolysis alone. In our “combined laser and electrolysis” group, most patients indeed had lower costs than the average electrolysis-only patient. However, such benefits were not uniform, with 2 patients requiring even greater treatment time and costs than the average electrolysis-only patient. This observed variability was likely due to heterogeneity within the group, with varied proportions of LHR to electrolysis and differences in treatment sequences. Furthermore, hair type/ hair density were not recorded—some patients have hair that is exceedingly dense or difficult to treat. Future studies accounting for these variables are indicated.

Based on our experience, an optimal treatment approach for patients with mixed dark and white hair is to first initiate LHR for the entire treatment field to debulk the field of dark hairs

which may hinder electrolysis. As soon as feasible, electrolysis treatment targeting only the white hairs should begin. This approach optimizes the effectiveness of both techniques.

### Clarification of FDA Language

The prevalence of inaccurate language used in association with the FDA and hair-removal techniques reflects how patients and providers alike have poor understanding of the FDA's role. Unfortunately, such misunderstandings drive not only selection of hair-removal techniques but also health-insurance policies regarding what treatments are/are not covered. Our center's experience is that most health-insurance companies in the United States cover pre-operative hair removal *only* with electrolysis and not LHR.

Patients and providers should understand that many electrolysis and LHR devices have been FDA-cleared for hair removal, meaning they are considered safe for marketing and use, but that neither technology is more endorsed by the FDA. The FDA has no role in clinically comparing different devices that are used for the same indication. Clear understanding of FDA oversight is crucial for accurate and thorough patient counseling when guiding patients in selecting hair-removal techniques.

### Limitations

Study limitations include the use of a survey, which relies on patient participation and recall, for data collection. Results for efficiency, cost, and pain were affected by expected variability among electrolysis and laser providers and devices. Individual patient factors, such as quality and density of hair, likely contributed to variations in cost and hair-removal needs. Skin color also plays a role; in our study, we did record skin color and found that both lighter skin tones (Fitzpatrick I–III) and darker skin tones (Fitzpatrick IV–VI) were well-represented in both the LHR and electrolysis groups. However, our study was not designed to correlate outcomes with individual Fitzpatrick skin types more specifically. Geographic variability may have also affected costs. Lastly, this study does not capture possible delayed regrowth of hair beyond 2 months. The phenomenon of delayed regrowth has been reported,<sup>67,68</sup> but data is limited and further studies are needed to determine the optimal waiting period after hair removal to minimize risks of regrowth.

### CONCLUSION

For patients who must undergo genital hair removal before gender-affirming vaginoplasty, the present work shows that LHR is associated with improved treatment efficiency (fewer, shorter, and less frequent treatment sessions), lower overall costs, less pain, and improved satisfaction when compared to electrolysis. These findings suggest that LHR should be considered the first-line option for genital hair removal before gender-affirming vaginoplasty in patients who qualify for LHR: those with darker-

pigmented hair. By default, patients with blond, red or white hair should undergo electrolysis. Health-insurance companies should consider improving coverage for hair-removal when it is specifically required for reconstructive surgery, and offer coverage of both treatment modalities. Patients with both dark and light-colored hairs may possibly benefit from combination treatment with laser and electrolysis. In these cases, we recommend treatment with LHR first, followed by electrolysis for the residual hair. The FDA does not make claims regarding the comparative efficacy of laser vs electrolysis for genital hair removal. Accurate and informative language should always be used during patient counseling.

**Corresponding Author:** Maurice M. Garcia, MD, MAS, Cedars-Sinai Medical Center, Division of Urology, 8635 W. Third Street, Suite 1070W, Los Angeles, CA 90048, USA. Tel: +1-310 423-4254; Fax: 310 423-4711; E-mail: [maurice.garcia@csmc.edu](mailto:maurice.garcia@csmc.edu)

*Conflict of Interest:* The authors report no conflicts of interest.

*Funding:* None.

### STATEMENT OF AUTHORSHIP

Nance Yuan: conceptualization, methodology, formal analysis, investigation, data curation, writing – original draft, writing – review and editing, and project administration. Alexandra Feldman: conceptualization, methodology, formal analysis, investigation, data curation, writing – original draft, writing – review and editing, and project administration. Patrick Chin: conceptualization, methodology, formal analysis, investigation, data curation, writing – original draft, writing – review and editing, and project administration. Michael Zaliznyak: conceptualization, methodology, formal analysis, investigation, data curation, writing – original draft, writing – review and editing, and project administration. Susan Rabizadeh: conceptualization, methodology, formal analysis, investigation, data curation, writing – original draft, writing – review and editing, and project administration. Maurice M. Garcia: conceptualization, methodology, formal analysis, investigation, data curation, writing – original draft, writing – review and editing, and project administration

### REFERENCES

1. Buncamper ME, van der Sluis WB, van der Pas RS, et al. Surgical outcome after penile inversion vaginoplasty: a retrospective study of 475 transgender women. *Plast Reconstr Surg* 2016;138:999–1007.
2. Massie JP, Morrison SD, Van Maasdam J, et al. Predictors of patient satisfaction and postoperative complications in penile inversion vaginoplasty. *Plast Reconstr Surg* 2018;141:911e–921e.



3. Garcia M, et al. Genital gender-affirming surgery for transgender patients. *AUA Update Series* 2017;43–54.
4. Ginsberg BA, Calderon M, Seminara NM, et al. A potential role for the dermatologist in the physical transformation of transgender people: a survey of attitudes and practices within the transgender community. *J Am Acad Dermatol* 2016;74:303–308.
5. Schardein JN, Zhao LC, Nikolavsky D. Management of vaginoplasty and phalloplasty complications. *Urol Clin North Am* 2019;46:605–618.
6. Coleman E, Bockting W, Botzer M, et al. Standards of care for the health of transsexual, transgender, and gender-nonconforming people, version 7. *Int J Transgenderism* 2012;13:165–232.
7. Richards RN, Meharg GE. Electrolysis: observations from 13 years and 140,000 hours of experience. *J Am Acad Dermatol* 1995;33:662–666.
8. Görgü M, Aslan G, Aköz T, et al. Comparison of alexandrite laser and electrolysis for hair removal. *Dermatol Surg* 2000;26:37–41.
9. Marks DH, Hagigeorges D, Manatis-Lornell AJ, et al. Excess hair, hair removal methods, and barriers to care in gender minority patients: a survey study. *J Cosmet Dermatol* 2020;19:1494–1498.
10. Harris K, Ferguson J, Hills S. A comparative study of hair removal at an NHS hospital: luminette intense pulsed light versus electrolysis. *J Dermatolog Treat* 2014;25:169–173.
11. Buffoli B, Rinaldi F, Labanca M, et al. The human hair: from anatomy to physiology. *Int J Dermatol* 2014;53:331–341.
12. Fernandez AA, França K, Chacon AH, et al. From flint razors to lasers: a timeline of hair removal methods. *J Cosmet Dermatol* 2013;12:153–162.
13. Bowrin K, Briere JB, Levy P, et al. Cost-effectiveness analyses using real-world data: an overview of the literature. *J Med Econ* 2019;22:545–553.
14. Mc Cord KA. The personalized medicine challenge: shifting to population health through real-world data. *Int J Public Health* 2019;64:1255–1256.
15. U.S. Food & Drug Administration. Real-World Evidence - What it is and what can it tell us?. *FDA Sci Res Spec Top 2019* Available at: <https://www.fda.gov/science-research/science-and-research-special-topics/real-world-evidence>.
16. Gupta V, Sharma VK. Skin typing: Fitzpatrick grading and others. *Clin Dermatol* 2019;37:430–436.
17. Fayne RA, Perper M, Eber AE, et al. Laser and light treatments for hair reduction in fitzpatrick skin types IV–VI: a comprehensive review of the literature. *Am J Clin Dermatol* 2018;19:237–252.
18. U.S. Food and Drug Administration. Home Page, Available at: <https://www.fda.gov>. Accessed March 5, 2022.
19. U.S. Food and Drug Administration. Contact FDA, Available at: <https://www.fda.gov/about-fda/contact-fda>. Accessed March 5, 2022.
20. Administration USFD. 510 k clearances. Available at: <https://www.fda.gov/medical-devices/device-approvals-denials-and-clearances/510k-clearances#:~:text=Overview.%20Section%20510%20%28k%29%20of%20the%20Food%2C%20Drug,the%20device%20is%20equivalent%20to%20a%20device%20already>. 2018. Accessed December 14, 2020.
21. Administration USFD. Is it really “FDA approved”? <https://www.fda.gov/consumers/consumer-updates/it-really-fda-approved>. Accessed December 14, 2020, 2020.
22. Suchak T, Hussey J, Takhar M, et al. Postoperative trans women in sexual health clinics: managing common problems after vaginoplasty. *J Fam Plann Reprod Health Care* 2015;41:245–247.
23. Chen ML, Reyblat P, Poh MM, et al. Overview of surgical techniques in gender-affirming genital surgery. *Transl Androl Urol* 2019;8:191–208.
24. Zhang WR, Garrett GL, Arron ST, et al. Laser hair removal for genital gender affirming surgery. *Transl Androl Urol* 2016;5:381–387.
25. Marks DH, Peebles JK, Dommasch E. Hair reduction for transgender persons: what dermatologists should know and how they can help. *JAMA Dermatol* 2019;155:525–526.
26. Michel C. Permanent hair removal with electrolysis, 2. *St Louis Clin Rec*; 1875. p. 145–148.
27. Ramos-e-Silva M, de Castro MCR, Carneiro Jr LV. Hair removal. *Clin Dermatol* 2001;19:437–444.
28. Reeves, C., Deutch, M., Stark, JW. Hair removal. University of California San Francisco (UCSF) Transgender Care & Treatment Guidelines. San Francisco, California. Available at: <https://transcare.ucsf.edu/guidelines/hair-removal>. Published 2016. Accessed October 14, 2020.
29. Olsen EA. Methods of hair removal. *J Am Acad Dermatol* 1999;40:143–155.
30. Liew SH. Unwanted body hair and its removal: a review. *Dermatol Surg* 1999;25:431–439.
31. Draelos ZK. Cosmetics: an overview. *Curr Probl Dermatol* 1995;7:45–64.
32. U.S. Food and Drug Administration. Removing hair safely. U. S. Food and Drug Administration. Available at: <https://www.fda.gov/consumers/consumer-updates/removing-hair-safely>. 2010. Updated June 30, 2010. Accessed October 14, 2020.
33. Ibrahimi OA, Avram MM, Hanke CW, et al. Laser hair removal. *Dermatol Ther* 2011;24:94–107.
34. Wanitphakdeedecha R, Alster TS. Physical means of treating unwanted hair. *Dermatol Ther* 2008;21:392–401.
35. Lepselter J, Elman M. Biological and clinical aspects in laser hair removal. *J Dermatolog Treat* 2004;15:72–83.
36. Tierney EP, Goldberg DJ. Laser hair removal pearls. *J Cosmet Laser Ther* 2008;10:17–23.
37. Sadighha A, Mohaghegh Zahed G. Meta-analysis of hair removal laser trials. *Lasers Med Sci* 2009;24:21–25.
38. Nanni CA, Alster TS. A practical review of laser-assisted hair removal using the Q-switched Nd: YAG, long-pulsed ruby, and long-pulsed alexandrite lasers. *Dermatol Surg* 1998;24:1399–1405.

39. Amin SP, Goldberg DJ. Clinical comparison of four hair removal lasers and light sources. *J Cosmet Laser Ther* 2006;8:65–68.
40. Haak C, Nymann P, Pedersen A, et al. Hair removal in hirsute women with normal testosterone levels: a randomized controlled trial of long-pulsed diode laser vs. intense pulsed light. *Br J Dermatol* 2010;163:1007–1013.
41. Gan SD, Graber EM. Laser hair removal: a review. *Dermatol Surg* 2013;39:823–838.
42. Haedersdal M, Gøtzsche PC. Laser and photoepilation for unwanted hair growth. *Cochrane Database Syst Rev* 2006; Cd004684.
43. Haedersdal M, Wulf HC. Evidence-based review of hair removal using lasers and light sources. *J Eur Acad Dermatol Venereol* 2006;20:9–20.
44. Ross EV, Ibrahimi OA, Kilmer S. Long-term clinical evaluation of hair clearance in darkly pigmented individuals using a novel diode1060nm wavelength with multiple treatment handpieces: a prospective analysis with modeling and histological findings. *Lasers Surg Med* 2018;50:893–901.
45. Lim SP, Lanigan SW. A review of the adverse effects of laser hair removal. *Lasers Med Sci* 2006;21:121–125.
46. Liew SH. Laser hair removal: guidelines for management. *Am J Clin Dermatol* 2002;3:107–115.
47. Ismail SA. Long-pulsed Nd:YAG laser vs. intense pulsed light for hair removal in dark skin: a randomized controlled trial. *Br J Dermatol* 2012;166:317–321.
48. Keller GS, Toft KM, Lacombe V, et al. *Lasers in aesthetic surgery*. New York: George Thieme Verlag; 2001.
49. Battle Jr EF. Advances in laser hair removal in skin of color. *J Drugs Dermatol* 2011;10:1235–1239.
50. Battle E. *Laser hair removal for darker skin types*. Skin of color. New York: Springer; 2013. p. 237–246.
51. Dierickx CC, Grossman MC, Farinelli WA, et al. Permanent hair removal by normal-mode ruby laser. *Arch Dermatol* 1998;134:837–842.
52. Lou WW, Quintana AT, Geronemus RG, et al. Prospective study of hair reduction by diode laser (800 nm) with long-term follow-up. *Dermatol Surg* 2000;26:428–432.
53. Eremia S, Li C, Newman N. Laser hair removal with alexandrite versus diode laser using four treatment sessions: 1-year results. *Dermatol Surg* 2001;27:925–930.
54. Chen J, Liu XJ, Huo MH. Split-leg comparison of low fluence diode laser and high fluence intense pulsed light in permanent hair reduction in skin types III to IV. *Australas J Dermatol* 2012;53:186–189.
55. Campos VB, Dierickx CC, Farinelli WA, et al. Ruby laser hair removal: evaluation of long-term efficacy and side effects. *Lasers Surg Med* 2000;26:177–185.
56. Grossman MC, Dierickx C, Farinelli W, et al. Damage to hair follicles by normal-mode ruby laser pulses. *J Am Acad Dermatol* 1996;35:889–894.
57. Grunewald S, Bodendorf MO, Zygouris A, et al. Long-term efficacy of linear-scanning 808nm diode laser for hair removal compared to a scanned alexandrite laser. *Lasers Surg Med* 2014;46:13–19.
58. Tuchayi SM FW, Grossman M, Anderson R, et al. Is laser hair removal treatment permanent? *J Am Acad Dermatol* 2019;81:AB229.
59. Salim A, Poh M. Gender-affirming penile inversion vaginoplasty. *Clin Plast Surg* 2018;45:343–350.
60. Hovenic W, DeSpain J. Laser hair reduction and removal. *Facial Plast Surg Clin North Am* 2011;19:325–333.
61. Preston PW, Lanigan SW. Patient satisfaction with laser hair removal. *J Cosmet Dermatol* 2003;2:68–72.
62. Sobanko JF, Miller CJ, Alster TS. Topical anesthetics for dermatologic procedures: a review. *Dermatol Surg* 2012;38:709–721.
63. Cohen JL. Pain management with a topical lidocaine and tetracaine 7%/7% cream with laser dermatologic procedures. *J Drugs Dermatol* 2013;12:986–989.
64. Gonzales G, Henning-Smith C. Barriers to care among transgender and gender nonconforming adults. *Milbank Q* 2017;95:726–748.
65. Koch JM, McLachlan Ct, Victor CJ, et al. The cost of being transgender: where socio-economic status, global health care systems, and gender identity intersect. *Psychol Sex* 2020;11:103–119.
66. Thoreson N, Marks DH, Peebles JK, et al. Health insurance coverage of permanent hair removal in transgender and gender-minority patients. *JAMA Dermatol* 2020;156:561–565.
67. Nanni CA, Alster TS. Optimizing treatment parameters for hair removal using a topical carbon-based solution and 1064-nm Q-switched neodymium:YAG laser energy. *Arch Dermatol* 1997;133:1546–1549.
68. Wheeland RG. Laser-assisted hair removal. *Dermatol Clin* 1997;15:469–477.