

Prospective Trial of Sacroiliac Joint Fusion Using 3D-Printed Triangular Titanium Implants: 24-Month Follow-Up

Vikas Patel¹
Don Kovalsky²
S Craig Meyer³
Abhineet Chowdhary⁴
Julie LaCombe⁴
Harry Lockstadt⁵
Fernando Techy⁶
Casey Langel⁷
Robert Limoni⁸
Philip Yuan⁹
Andy Kranenburg¹⁰
Daniel Cher¹¹
Gabriel Tender¹²

¹Department of Orthopedics, University of Colorado, Aurora, CO, USA;

²Orthopaedic Center of Southern Illinois, Mt. Vernon, IL, USA; ³Columbia Orthopaedic Medical Group, Columbia, MO, USA; ⁴Overlake Medical Center, Bellevue, WA, USA; ⁵Bluegrass Orthopaedics, Lexington, KY, USA;

⁶ClinTech Center for Spine Health, Johnstown, CO, USA; ⁷The B.A.C.K. Center, Melbourne, FL, USA; ⁸BayCare Clinic Orthopedics & Sports Medicine, Green Bay, WI, USA; ⁹Memorial Orthopaedic Surgical Group, Long Beach, CA, USA; ¹⁰South Oregon Orthopedics, Medford, OR, USA; ¹¹SI-BONE, Inc, Santa Clara, CA, USA; ¹²Department of Neurosurgery, Louisiana State University, New Orleans, LA, USA

Correspondence: Vikas Patel
Tel +1 303 724-8936
Email Vikas.Patel@CUAnschutz.edu

Background: Strong evidence supports minimally invasive sacroiliac joint (SIJ) fusion using triangular titanium implants (TTI) for chronic SIJ dysfunction.

Objective: To report safety and effectiveness of SIJF using a 3D-printed TTI at 24 months.

Methods: SIJF with TTI was performed in 51 subjects. Structured follow-up occurred at 3, 6, 12 and 24 months. Both quality of life questionnaires and functional tests were performed at all study visits.

Results: 84% of subjects were available for 24-month follow-up. Observed were rapid and persistent improvements in dysfunction due to pain (Oswestry Disability Index [ODI], mean 52.8 at baseline and 28.3 at 24 months, $p < 0.0001$) and SIJ pain ratings (mean 78.5 at baseline [0–100 scale] to 21.5 at 24 months). Opioid use for SIJ pain decreased markedly from baseline. Physical function tests impaired by SIJ pain showed persistent improvements compared to baseline. There was no evidence of device breakage, migration or subsidence and few late adverse events occurred attributable to the device.

Conclusion: In this prospective study, SIJF using 3D-printed TTI resulted in immediate, marked and persistent improvements in pain and quality of life, with improved physical function, reduced opioid use and a low rate of late device-related adverse events.

Level of Evidence: Level II.

Keywords: sacroiliac joint pain, sacroiliac joint arthrodesis, chronic low back pain, triangular titanium implants

Plain Language Summary

Fifty-one patients with chronic sacroiliac (SI) joint pain underwent surgical fusion of the SI joint at 11 centers in the United States. At two years, patients showed large, sustained improvement in pain, disability and quality of life as well related to SI joint pain as improvements in physical function and decreased use of opioid medications for pain relief.

The sacroiliac joint (SIJ) is thought to be responsible for up to 30% of all chronic low back pain.^{1–5} While evidence for non-surgical treatment of SIJ dysfunction is very sparse, increasing evidence supports the use of lateral transiliac SIJF. The most commonly reported device is triangular titanium implants (TTI, iFuse Implant System, SI-BONE, Inc., Santa Clara, California, USA), with positive results from prospective trials^{6–8} and case series.^{9–14} Prior TTI studies reported use of solid (milled and coated) implants. More recently, 3D-printing of titanium implants has become more common. 3D-printing allows

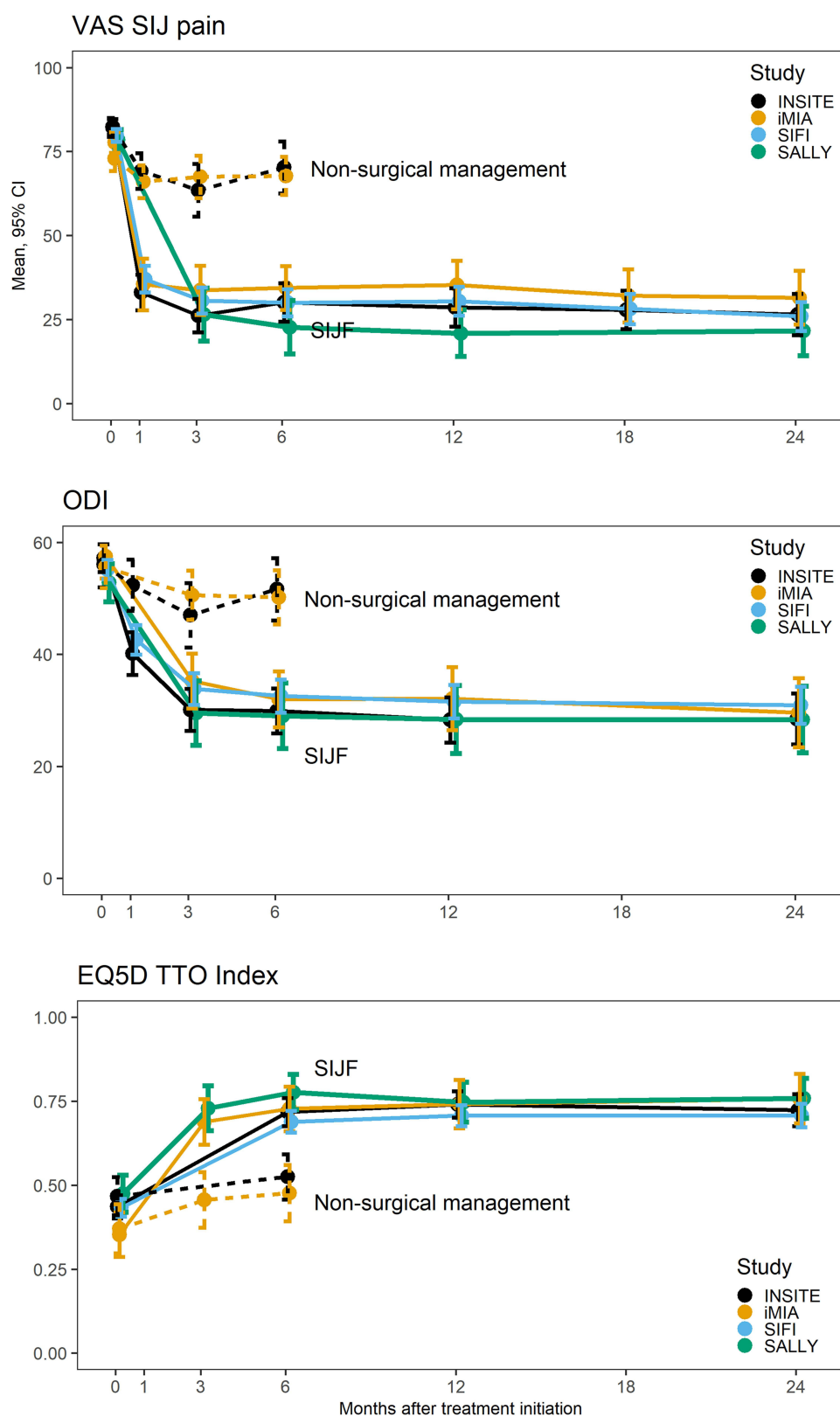


Figure 1 Improvement in SIJ pain (top), Oswestry Disability index (middle) and EuroQOL-5D time trade-off index over time comparing the current study (SALLY, green) with two prior randomized trials (INSITE⁶ [black] and iMIA⁸ [orange]), both of which compared SIJ fusion (solid lines) to non-surgical management (dotted lines) and a large single-arm trial SIFI⁷ (blue solid line).

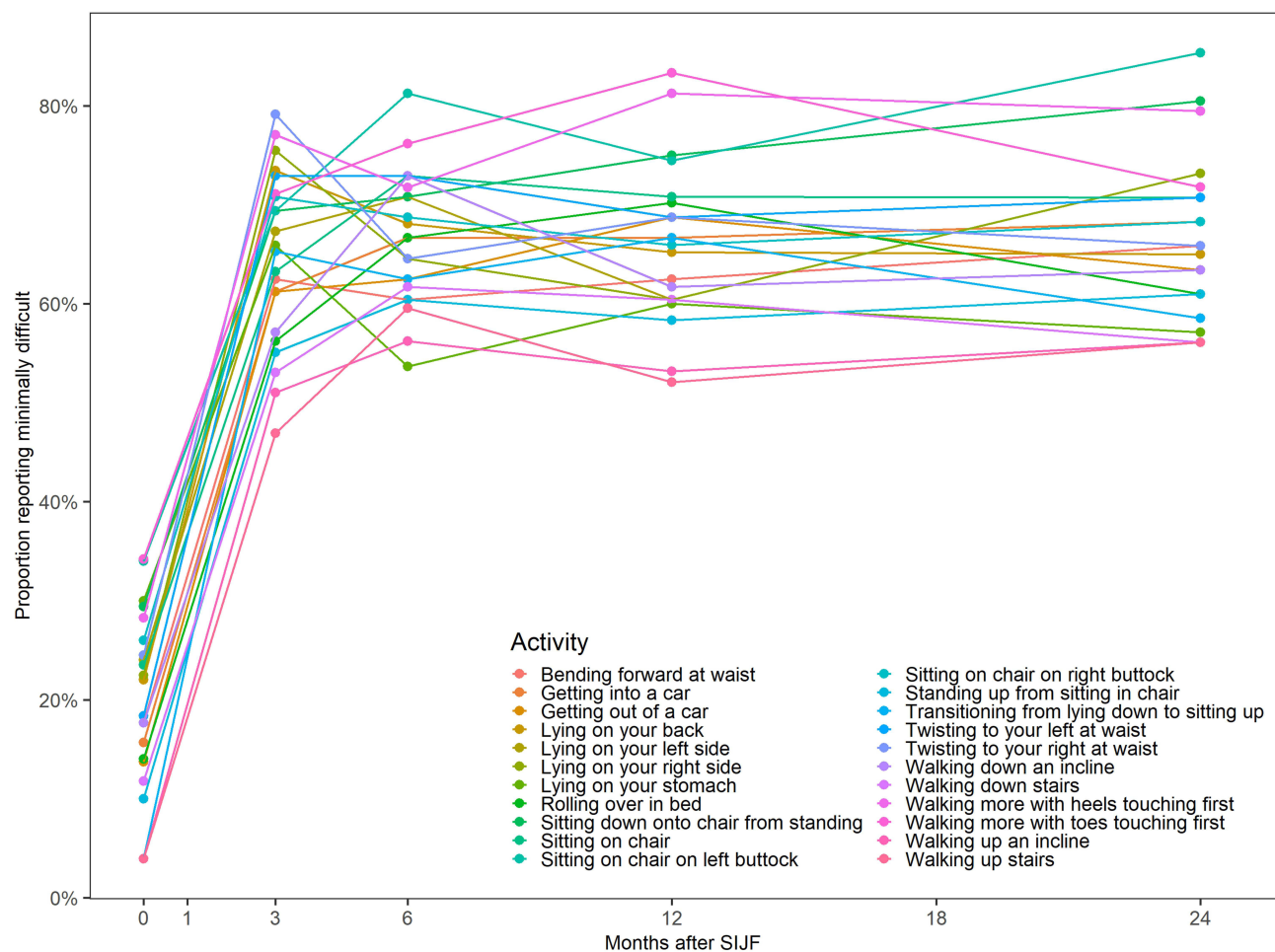


Figure 2 Change in proportion reporting minimal difficulty performing activities related to chronic low back/pelvic pain.

creation of implant surfaces that optimize bone adherence, even in the setting of smoking or osteoporosis.^{15,16} Previously, we reported positive clinical and radiographic outcomes at one year from a prospective multicenter clinical trial (NCT03122899) of SIJF using 3D-printed TTI in patients with chronic SIJ dysfunction.¹⁷ Herein we report 2-year follow-up from the same cohort.

As described previously¹⁷ patients in 11 US spine surgeons' clinics were diagnosed with SIJ dysfunction using a standardized algorithm consisting of typical history findings (buttock pain, possible radiation, often worse with prolonged sitting on the affected side), positive response to standardized physical examinations and at least a 50% reduction in acute pain on image-guided injection of local anesthetic into the target joint. Upon confirmation of eligibility and signing the consent form, baseline demographics, medical history and responses to quality of life

questionnaires (Oswestry Disability Index,¹⁸ visual analog scale SIJ pain ratings [0–100 scale], and EuroQOL-5D-3L¹⁹) were recorded. Subjects underwent minimally invasive lateral transiliac SIJ fusion using 3D-printed TTI (iFuse-3D) and an associated instrument set. After hospital discharge, subjects returned to clinic at 3, 6, 12 and 24 months for repeat questionnaire assessment and review of adverse events. Final follow-up will be at 5 years.

Of 51 subjects enrolled and treated between October 2017 and January 2019, 24-month follow-up was obtained in 43 (84%). Reasons for lack of follow-up included loss to follow-up (6 subjects), voluntary withdrawal (1), and death from prostate cancer (1). At enrollment, mean age was 53 years and 76% were women. SIJ pain was present for a mean of 8 years. Forty-six underwent unilateral SIJF and 5 underwent staged bilateral SIJF. Mean procedure time was 52 minutes and blood loss was minimal (<50cc in most cases). Fifty-one percent were

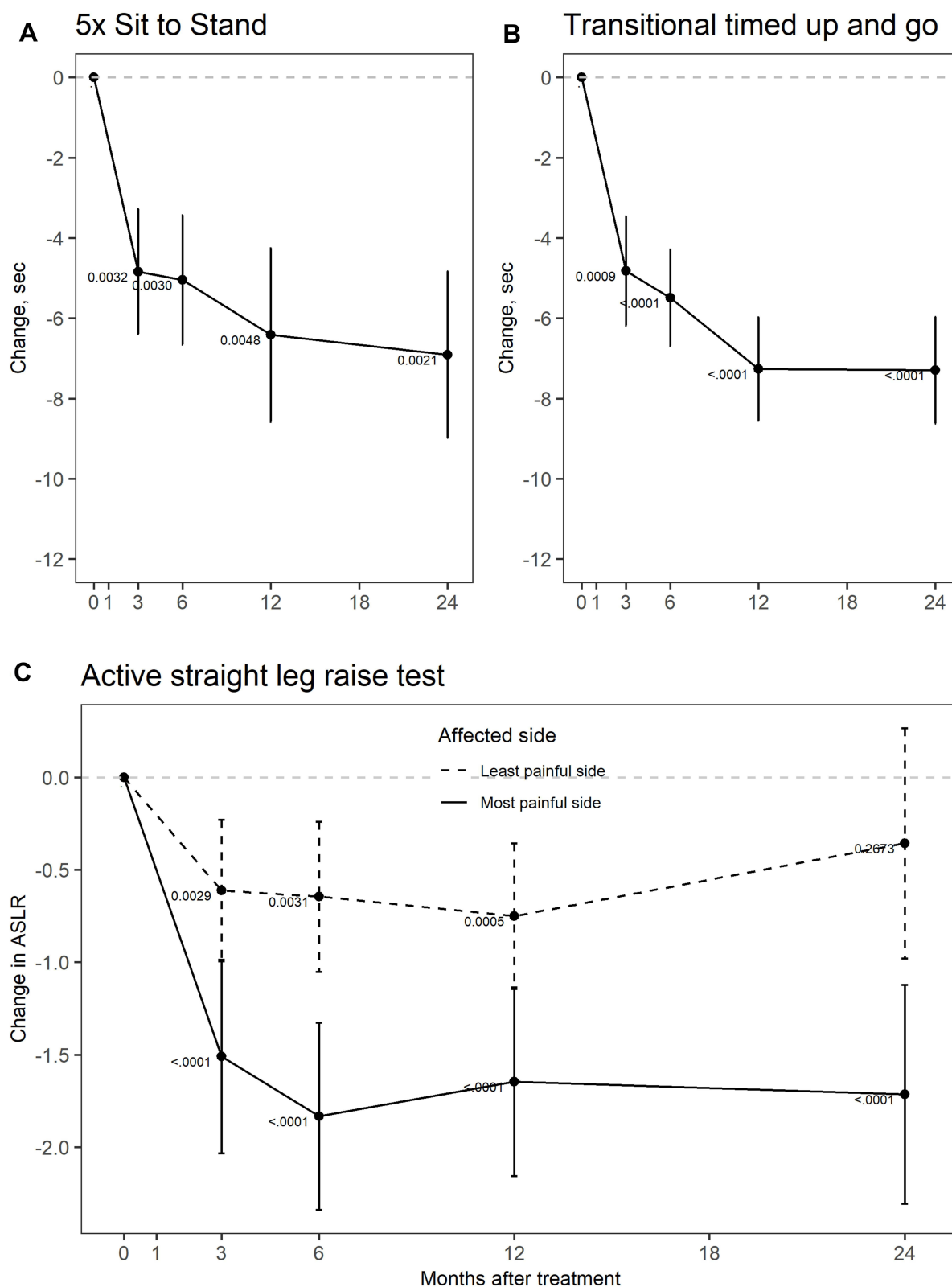


Figure 3 Improvement in performance on functional tests before and 3, 6, 12 and 24 after SIJF. Top left panel shows mean time to complete 5 times sit-to-stand. Top-right panel (A,B) show mean time for transitional timed up and go. The bottom panel (C) shows mean ratings on active straight leg raise test. Small numbers are p-values from one-sample two-tailed t tests. Values shown are mean and 95% confidence limits.

discharged from the hospital/surgical facility the day of surgery.

Mean ODI improved from 52.8 at baseline to 28.3 at 24-month follow-up; mean SIJ pain levels improved from 78.5 at baseline to 21.5 (Figure 1); mean EuroQOL-5D time trade-off index improved from 0.45 at baseline to 0.81 at follow-up. All 24-month changes were statistically significant ($p < 0.0001$) compared to baseline. At month 24, 66% had a 15-or-more point improvement from baseline in ODI. The proportion of subjects reporting difficulty with activities of daily living improved rapidly and remained improved at each postoperative timepoint (Figure 2). Physical function, assessed active straight leg raise test (ASLR),²⁰ five times sit-to-stand, and transitional timed up-and-go, showed immediate and sustained improvement (Figure 3). Ninety-one percent were either “satisfied” or “very satisfied” at 24 months and 79% would have the procedure again. Opioid use decreased from 59% at baseline to 18% at 24 months.

Between month 12 and 24, 30 adverse events occurred in 18 subjects. Of these, only 2 (both SIJ pain) were procedure-related. In one case, a subject had chronic SIJ pain and underwent intrathecal pump placement. This subject had previously reported chronic neuropathic pain related to implant malposition. In another subject, SIJ pain returned by between month 12 and 24; the subject underwent corticosteroid injections and radiofrequency ablation of lateral branches of L5, S1 and S2 nerve roots. An additional 5 subjects experienced pelvis-related AEs: contralateral SIJ pain (2 subject), ipsilateral SIJ pain (1 subject), gluteus medius tendonitis (1 subject), and fall causing piriformis syndrome (1 case). No subject underwent surgical revision between year 1 and 2. By year 2, 2 subjects had undergone surgical revision; one for acute irritation of the left L5 nerve root due to implant malposition and one related to pain acutely worsened by a car accident.

In summary, in our multicenter prospective study, minimally invasive SIJF using 3D-printed TTI provided immediate and sustained benefits to patients with chronic SIJ pain across all assessed endpoints, including pain, disability related to pain, quality of life, activities related to pain, reduced opioid use, satisfaction and physical functional testing. Efficacy endpoints were similar to prior trials of a predecessor device. The rate of adverse events was low and late adverse events related to the study procedure were uncommon. Not all subjects responded to treatment and not

all back pain-related disability resolved (some of which was likely related to other ongoing back problems). Nonetheless, long-term results were encouraging and consistent with prior long-term reports.^{21–23} Our prior report¹⁷ noted 100% binding of bone to the implants’ surfaces within the ilium and sacrum, and a high rate of bridging bone within the joint itself (70% at 6 months and 77% at 12 months). These findings are consistent with the following mechanism of action for TTI: 1) immediate stabilization of the joint through press-fit of multiple implants whose triangular cross-section resists joint rotation, 2) mid-term stabilization through bone binding to implant surfaces on both sides of the joint, and 3) late intraarticular SI joint fusion. Follow-up to 24 months indicates that minimally invasive SIJF with 3D-printed TTI provides marked benefits to patients with a high benefit–risk ratio.

Ethical Approval

All sites obtained written approval from a local or central institutional review board prior to first enrollment. The study was conducted according to the Declaration of Helsinki and relevant items from ISO 14155:2011. Subjects were paid nominal amounts (approved by the IRB) for their time and expense to complete study assessments. All subjects provided written informed consent prior to participating. Institutional review boards (IRBs) overseeing the study are:

WCG IRB, 11491 Woodside Ave, Santee, CA 92071, USA

Louisiana State University Health Sciences IRB, Office of Research Services, 433 Bolivar Street, Room 206, New Orleans, LA 70112, USA

Providence Health Services, 5251 NE Glisan, Building A, 3rd Floor, Portland, OR 97213, USA

Study data were collected using an electronic case report form system. Data entered into case report forms were 100% source-verified. Qualified requestors may obtain study data through Yale University’s Yale Open Data Access (YODA) platform. Data provided will include de-identified subject data, the study protocol and annotated case report forms. The study was sponsored by the device manufacturer (SI-BONE, Inc., Santa Clara, CA).

Disclosure

All authors conduct clinical research as part of prospective trials sponsored by SI-BONE. S. Craig Meyer, Harry Lockstadt, Andy Kranenburg, and Abhineet Chowdhary are consultants to SI-BONE. All are involved in teaching about SIJ pain/surgery and/or product development. Dr Vikas Patel reports grants from Orthofix, Medicea, Globus, Pfizer,

Premia, Mainstay Medical, Spinal Kinetics, consulting for Baxter, Zimmer Biomet, Stryker, and Aesculap, outside the submitted work. Dr Fernando Techy reports grants from SI-BONE, during the conduct of the study; personal fees from Spine Up, outside the submitted work. Dr Philip Yuan reports grants for research support from SI-BONE, during the conduct of the study. Dr Andy Kranenburg reports grants for study-related costs from SI-BONE, during the conduct of the study; teaching stipend from SI-BONE, outside the submitted work. Daniel Cher is an employee of SI-BONE, the company that manufactures implants used in this study and reported in the manuscript. The authors report no other conflicts of interest in this work.

References

- Bernard TN, Kirkaldy-Willis WH. Recognizing specific characteristics of nonspecific low back pain. *Clin Orthop*. 1987;(217):266–280. doi:10.1097/00003086-198704000-00029
- Schwarzer AC, Aprill CN, Bogduk N. The sacroiliac joint in chronic low back pain. *Spine*. 1995;20(1):31–37. doi:10.1097/00007632-199501000-00007
- Maigne JY, Aivaliklis A, Pfefer F. Results of sacroiliac joint double block and value of sacroiliac pain provocation tests in 54 patients with low back pain. *Spine*. 1996;21(16):1889–1892. doi:10.1097/00007632-199608150-00012
- Irwin RW, Watson T, Minick RP, Ambrosius WT. Age, body mass index, and gender differences in sacroiliac joint pathology. *Am J Phys Med Rehabil*. 2007;86(1):37–44. doi:10.1097/PHM.0b013e31802b8554
- Sembrano JN, Polly DW. How often is low back pain not coming from the back? *Spine*. 2009;34(1):E27–32. doi:10.1097/BRS.0b013e31818b8882
- Polly DW, Swofford J, Whang PG, et al. Two-year outcomes from a randomized controlled trial of minimally invasive sacroiliac joint fusion vs. non-surgical management for sacroiliac joint dysfunction. *Int J Spine Surg*. 2016;10:Article 28. doi:10.14444/3028
- Duhon BS, Bitan F, Lockstadt H, Kovalsky D, Cher D, Hillen T. Triangular titanium implants for minimally invasive sacroiliac joint fusion: 2-year follow-up from a prospective multicenter trial. *Int J Spine Surg*. 2016;10:Article 13. doi:10.14444/3013
- Dengler J, Kools D, Pflugmacher R, et al. Randomized trial of sacroiliac joint arthrodesis compared with conservative management for chronic low back pain attributed to the sacroiliac joint. *J Bone Jt Surg*. 2019;101(5):400–411. doi:10.2106/JBJS.18.00022
- Rudolf L. Sacroiliac joint arthrodesis-mis technique with titanium implants: report of the first 50 patients and outcomes. *Open Orthop J*. 2012;6(1):495–502. doi:10.2174/1874325001206010495
- Rudolf L. MIS Fusion of the SI joint: does prior lumbar spinal fusion affect patient outcomes? *Open Orthop J*. 2013;7:163–168. doi:10.2174/1874325001307010163
- Sachs D, Capobianco R. One year successful outcomes for novel sacroiliac joint arthrodesis system. *Ann Surg Innov Res*. 2012;6(1):13. doi:10.1186/1750-1164-6-13
- Sachs D, Capobianco R. Minimally invasive sacroiliac joint fusion: one-year outcomes in 40 patients. *Adv Orthop*. 2013;2013:536128. doi:10.1155/2013/536128
- Cummings J Jr, Capobianco RA. Minimally invasive sacroiliac joint fusion: one-year outcomes in 18 patients. *Ann Surg Innov Res*. 2013;7(1):1–7. doi:10.1186/1750-1164-7-12
- Schroeder JE, Cunningham ME, Ross T, Boachie-Adjei O. Early results of sacro-iliac joint fixation following long fusion to the sacrum in adult spine deformity. *Hosp Spec Surg J*. 2013;10(1):30–35. doi:10.1007/s11420-013-9374-4
- Linden M-S-S, Paranhos L-R, De Carli J-P, et al. Influence of nicotine on machined- and anodized-surface implants. Histometric analysis. *J Clin Exp Dent*. 2017;9(10):e1207–e1211. doi:10.4317/jced.54127
- Alsahhaf A, Alshagroud RS, Al-Aali KA, Alofi RS, Vohra F, Abduljabbar T. Survival of titanium-zirconium and titanium dental implants in cigarette-smokers and never-smokers: a 5-year follow-up. *Chin J Dent Res off J Sci Sect Chin Stomatol Assoc CSA*. 2019;22(4):265–272. doi:10.3290/j.cjdr.a43737
- Patel V, Kovalsky D, Meyer SC, et al. Prospective trial of sacroiliac joint fusion using 3D-Printed triangular titanium implants. *Med Devices Auckl NZ*. 2020;13:173–182. doi:10.2147/MDER.S253741
- Fairbank JC, Pynsent PB. The Oswestry disability index. *Spine*. 2000;25(22):2940–2952; discussion 2952. doi:10.1097/00007632-200011150-00017
- EuroQol Group. EuroQol—a new facility for the measurement of health-related quality of life. *Health Policy Amst Neth*. 1990;16(3):199–208. doi:10.1016/0168-8510(90)90421-9
- Mens JM, Vleeming A, Snijders CJ, Koes BW, Stam HJ. Reliability and validity of the active straight leg raise test in posterior pelvic pain since pregnancy. *Spine*. 2001;26(10):1167–1171. doi:10.1097/00007632-200105150-00015
- Whang PG, Darr E, Meyer SC, et al. Long-term prospective clinical and radiographic outcomes after minimally invasive lateral transiliac sacroiliac joint fusion using triangular titanium implants. *Med Devices Auckl NZ*. 2019;12:411–422. doi:10.2147/MDER.S219862
- Vanaclocha V, Herrera JM, Sáiz-Sapena N, Rivera-Paz M, Verdú-López F. Minimally invasive sacroiliac joint fusion, radiofrequency denervation, and conservative management for sacroiliac joint pain: 6-year comparative case series. *Neurosurgery*. 2018;82(1):48–55. doi:10.1093/neuros/nyx185
- Rudolf L, Capobianco R. Five-year clinical and radiographic outcomes after minimally invasive sacroiliac joint fusion using triangular implants. *Open Orthop J*. 2014;8:375–383. doi:10.2174/1874325001408010375

Medical Devices: Evidence and Research

Dovepress

Publish your work in this journal

Medical Devices: Evidence and Research is an international, peer-reviewed, open access journal that focuses on the evidence, technology, research, and expert opinion supporting the use and application of medical devices in the diagnosis, monitoring, treatment and management of clinical conditions and physiological processes. The identification of novel devices and optimal use of existing devices

which will lead to improved clinical outcomes and more effective patient management and safety is a key feature of the journal. The manuscript management system is completely online and includes a very quick and fair peer-review system. Visit <http://www.dovepress.com/testimonials.php> to read real quotes from published authors.

Submit your manuscript here: <https://www.dovepress.com/medical-devices-evidence-and-research-journal>