


Lasers and ancillary treatments for scar management: personal experience over two decades and contextual review of the literature. Part I: Burn scars

Scars, Burns & Healing
Volume 2: 1–7
DOI: 10.1177/2059513116642090
Reprints and permissions:
sagepub.co.uk/journalsPermissions.nav
© The Author(s) 2016
sbh.sagepub.com


Rory B McGoldrick^{1,2}, Adam Sawyer^{1,3}, Christopher R Davis⁴,
Evgenia Theodorakopoulou¹ and Maxwell Murison¹



Abstract

The formation of a wide range of excessive scars following various skin injuries is a natural consequence of healing. Scars resulting from surgery or trauma affect approximately 100 million people per annum in the developed world and can have profound physical, aesthetic, psychological and social consequences. Thus, scar treatment is a priority for the plastic surgeon.



We aim to explore new approaches to the management of such scarring. The senior authors current use of laser technology, chemotherapeutic agents, pharmacotherapy and cryosurgery will be reviewed. This is placed in the context of the current literature and evidence base and is illustrated with case studies, starting with burns scars in part I, and focusing on keloid and hypertrophic scars in part II, acne scars in part III and finally pigmented scars in part IV. In Part I we focus on burns scar treatment with fractional ablative 10,600 nm wavelength carbon dioxide (CO₂) laser therapy.



Keywords

Scars, lasers, acne scars, burns scars, hypertrophic scars, keloid scars, steroids, pigmented scars, 5-Fluorouracil

Lay Summary

Scars can result as part of the normal healing process after a burn or other trauma such as surgery or injury. However, there is a range of scarring from 'good' to 'bad' depending on various features of the scars. Some can be lumpy and raised (hypertrophic and keloid scars), have changes in pigmentation (increased or decreased colouration) or have specific features related to the cause (for instance acne scars, burns scars). We review the senior author's experience over twenty years in treating scars with a range of treatments in conjunction with lasers. This first article from a 4-part series looks at burns scars. Subsequent articles focus on thickened scars known as hypertrophic and keloid scars; acne scars; and the treatment of pigmented scars (parts 2-4). Central to the treatment strategy in this article on burns scars is the carbon dioxide laser which is an ablative laser (removes tissue and penetrates tissue) requiring some down time for healing sometimes with dressings.

¹Welsh Regional Burns, Plastic, Reconstructive Surgery and Laser Unit, Morriston Hospital, Heol Maes Eglwys, Morriston, Swansea SA6 6NL, UK

²The Royal Marsden Hospital, Fulham Road, London SW3 6JJ, UK

³St. Thomas' Hospital, Westminster Bridge Road, London SE1 7EH, UK

⁴The Royal Free Hospital, Pond Street, London NW3 2QG, UK

Corresponding author:

Rory B McGoldrick, Morriston Hospital, Welsh Centre for Burns and Plastic Surgery, Swansea SA6 6NL, UK.

Email: rorymcgoldrick@hotmail.com



Introduction

The formation of a wide range of excessive, unaesthetic scars following cutaneous injury is a natural consequence of wound healing. The process occurs through reparative mechanisms and is an undesirable yet necessary outcome of recovery from a skin injury. Scars resulting from elective surgery or trauma affect approximately 100 million people per annum in the developed world.^{1,2} The incidence of symptomatic scars within this cohort is more challenging to quantify; it is estimated that approximately 15 million suffer excessive or unaesthetic scars.¹ Such scarring can have profound physical, aesthetic, psychological and social consequences. Physical symptoms may include itching, stiffness, scar contractures with functional deficits, tenderness and pain.^{3,4} Psychological and social consequences include anxiety, mood disturbance, reduced self-esteem and social ostracism leading to isolation and reduced engagement in society.⁵⁻⁶ Treatment of symptomatic scarring is a priority for clinicians in this arena. The senior author's experience and current use of laser technology and ancillary chemotherapeutic agents, pharmacotherapy and also cryosurgery for a wide range of cutaneous scars will be reviewed. This is placed in the context of the current literature and evidence base and illustrated with case studies, starting with burns scars in part I, and focusing on keloid and hypertrophic scars in part II, acne scars in part III and pigmented scars in part IV.

Despite decades of research, the evidence base in relation to scar management remains relatively poor. A number of factors hinder research progression in this field and include:

- The wide variation of aetiology of scars treated;
- The wide range of scar types treated;
- The variability in patient demographics including age, ethnic background and comorbidity;
- The tendency and necessity for multi-modality treatments for successful outcomes;
- Relatively low numbers of scars with comparable parameters;
- The expense and logistics of funding and undertaking large clinical controlled trials independent of equipment manufacturers and the pharmaceutical industry;

- Lack of widespread availability of some modalities such as lasers;
- A distribution of care that often includes the private healthcare sector;
- Variability of iatrogenic events such as skin grafting.;
- A tendency for natural improvement over time over a period of 2 years; and
- Many others.

In particular, the power of studies needed to take into account all these variables is difficult to achieve to the extent that superlative randomised clinical controlled trials that have adjusted for all important variables have been elusive to date in the world literature. It is therefore not unsurprising that the majority of the published literature lies in the realms of case series and personal experience (evidence levels IV and V) but this has at least shaped and stimulated the context of further research over time and provided numerous success stories at the clinical front line. With these challenges in mind, the management of hypertrophic, keloid, burns, acne, pigmented and tattooed scars are all addressed in our series of articles with focus on the contribution of lasers.

Lasers

LASER is a word derived from the acronym for Light Amplification by the Stimulated Emission of Radiation. They are electro-optical devices that emit organised light in a very narrow and intense beam by a process of optical feedback and amplification. The radiant energy emitted is of the same wavelength (monochromatic) and unidirectional (collimated), and is temporally and spatially coherent. They target a specific chemical entity, known as a chromophore, that absorbs a specific wavelength of the electromagnetic spectrum. There are essentially three variables the surgeon can control, namely: power, measured in watts; spot size, measured in either square millimetres or square centimetres; and finally, exposure time (pulse duration), measured in fractions of seconds. For each burns scar case presentation, the settings for each treatment described are presented below the clinical photographs.

Power is the least useful variable and may be kept constant with widely varying effects, depending on the spot size and the duration of exposure. Irradiance is a more useful measure of the intensity of the beam at the focal point because it considers the surface area of the spot. Specifically,

irradiance is expressed (in W/cm^2) as power in the focal spot divided by spot area.

One can vary the amount of energy delivered to the target tissue (and hence proportional to the depth of penetration) by varying the exposure time (pulse width).

Burn scars

Despite recent advances in perioperative resuscitation and surgery for burn injuries,^{7–10} the sequelae of burns scarring has the potential for both profound functional and psychological impact on the individual.^{11–13} Indeed, these injuries can produce some of the most disfiguring scars seen in clinical practice and present unique challenges in terms of treatment. As burn wounds heal, patients often develop tight, neuropathically painful, pruritic hypertrophic scars that are conventionally treated with the use of massage, moisture, topical silicone and pressure therapy – the evidence base for which has been more historical than scientific, but which are widely acknowledged as standard practice and indeed standard of care. Pharmacological adjuncts include intralesional steroid injection, antihistamines, opioids, anxiolytics and antidepressants in conjunction with aggressive physical and occupational therapy. Patients presenting with large areas of mature stiff, thick, dense plaques with ‘plastic like’ textural changes with contracting bands are often treated with surgical scar excision. Thereafter, resurfacing with skin grafts, dermal substitutes, flap transfer or preoperative tissue expansion is commonplace in order to restore form and function. Many clinical interventions themselves cause iatrogenic problems that sometimes require treatment, ranging from telangiectasia and atrophy from corticosteroid use to the residual mesh pattern from skin grafts.

The senior author’s practice is to reframe the problem by using carbon dioxide lasers which result in selective collagen remodelling of burn scar texture by targeting the skin water (chromophore) content in abnormal collagen to improve scar colour match, thickness, pliability, pain, pruritus and tightness. The histological effects of lasers with their ability to act directly on dermal collagen as well as the epidermis is quite remarkable.^{14–17}

This effect achieved through fractionated photothermolysis¹⁸ through the use of fractional ablative 10,600 nm wavelength carbon dioxide (CO_2) laser therapy. There are numerous commercially available fractional devices, but our unit uses the Lumenis Ultrapulse® device with either ActiveFX®, DeepFX® or SCAAR FX™

(Synergistic Coagulation and Ablation for Advanced Resurfacing) modes (Lumenis Ltd., Yokneum, Israel), or in combination (TotalFX®) depending on the intended effect. The ActiveFX® mode has a collimated spot size of 1.3 mm with a variety of pattern shapes and sizes that can be adapted for burn scar morphology. Depth of penetration is determined by fluence to a maximum of 300 μm that allows for a broad-based superficial pattern of ablation that is limited to the epidermis and superficial papillary dermis. This mode employs a pulse width that is 8–10 times longer than that of the DeepFX® mode, with a much larger spot size. In contrast, the DeepFX® mode has a spot size of 120 μm , short pulse width and a fluence up to 50 mJ which translates to extend treatment from the epidermis to as deep as 1.5 mm. This mode utilises a shortened pulse width with a smaller spot size, which allows for deep columns of tissue ablation. Deeper still is the penetration into the reticular dermis seen in the SCAAR FX™ mode, which allows for columnar ablation up to 4 mm due to fluence of up to 150 mJ and a short pulse width. By manipulating the number of pulses, density and energy per pulse, the degree of thermal injury to the burn scar tissue can be controlled. Only a single pass is performed with each of the deep and superficial hand pieces, but these complementary approaches can be safely combined over the same scar area.

Anaesthesia for small scars can be achieved with combination of topical and injected local anaesthetic agents. Grafted and traumatised sites are often insensate and pain is quite often limited to the deeper treatment of normal border skin which is treated for 5 mm as often the tightness of scars can extend subclinically into these regions. Larger more confluent areas of burn scars and paediatric patients necessitate general anaesthesia. Fractional CO_2 laser therapy parameters should be selected to avoid bulk heating of the scar tissue (see case illustrations).

General principles include a minimum ablation threshold of 5 J/cm^2 , a short pulse width to approximate the thermal relaxation time of skin (<1 ms) and a relatively narrow beam (<500 μm) to maintain ablation but limit excessive collateral thermal injury and thus potentially delayed healing with the risk of further scarring. Isolated areas of textural, pigment abnormalities or atrophy can be treated with lower pulse energies and higher densities whereas thicker scars require higher pulse energies and lower treatment densities. Immediately post-treatment erythema lasts for a few hours only and the sensation is similar to that of sunburn with a mild serous

discharge. Treatment interval is normally 3 months. Postoperative care regimen includes daily wash with antimicrobial and emollient lotion and application of petrolatum- or petroleum based ointment until the treatment site is fully epithelialized, normally within 5 days of treatment. Viral prophylaxis and antibiotics are given to those patients at risk of infection and 1% hydrocortisone is given if pruritus is a feature. Normal activities can resume immediately post-operatively with avoidance of hot water, ovens and hair dryers due to wound sensitivity. Once healed, a thin SPF30 or greater lotion is recommended.

The fractional technology operates via ultra-fast pulses of energy to produce tissue ablation and minimise heat deposition. This produces a microfractional wound with a distinctive thermal damage pattern by creating thousands of narrow, non-contiguous microcolumns of injury up to a depth of 4 mm, allowing treatment of deep scars, referred to as microthermal treatment zones (MTZ). This thermally alters a fraction of the skin and burn scar while leaving intervening areas of untreated normal skin.^{19,20} The degree of epithelial loss is confined to the narrow diameter of the MTZ allowing rapid re-epithelialisation and deeper ablated columns of disorganised elastotic dermal type III collagen is also disrupted allowing replacement of the older injured collagen matrix with new organised type I collagen in a controlled manner.¹⁷ It is postulated that there is an upregulation of type III collagen specific matrix metalloproteinase (MMP)-1 and microRNAs miR-18-19a cluster expression with an associated alteration of type I and III procollagen mRNA levels and downregulation of transforming growth factors (TGF)- β 1-3 and basic fibroblast growth factor (bFGF) along with isolated MTZ fibroblastic apoptosis.²¹⁻²³ As a result, the microperforations in the scarring improves elements that involve the entire thickness of the dermis such as its pliability and depending on the depth of penetration may also cause a weakening of adhesions between the scar and underlying tissue such as muscle or tendon aiding functional recovery.²⁴

The fractional technique has delivered a renewed interest in CO₂ laser resurfacing in the management of burn scars in recent years as it offers distinct advantages over the traditional pulsed planar one-dimensional CO₂ laser technology. While initially counterintuitive, the application of fractionated light therapy to a burn injury theoretically avoids excessive thermal injury, prolonged erythema, hypopigmentation and the potential of severe scarring.²⁵⁻³³ We have observed improvement in scar characteristics as well functionality

and symptoms most marked within the first 2 weeks following the first session, with more modest improvements following subsequent treatments; a so-called therapeutic ceiling is reached. Strikingly, at the first treatment, there is an immediate photomechanical effect analogous to meshing a split thickness graft with visible and palpable relaxation of plaque like and banded scars. In addition, we have seen improvements in the integrity of unstable burn scars following treatment. Despite these results, the treatment carries inherent risks most notably related to delayed wound healing which include the worsening of existing scarring or the development of new scars or permanent hypopigmentation. Interestingly, patients often note and comment upon an immediately experience response within days or even hours of treatment, and if a limb is affected by a burn scar contracture on improved range of movement. The sense of progress expressed by this patient group after treatment cannot be overstated, even in circumstances where clinical response appears marginal and which patients describe as physical not psychological in nature with descriptors such as 'smoothness, tone, flexibility' which are very difficult to measure objectively. There is much further work to be done in delineating all the factors at play.

Burn scar case illustrations

1. A 33-year-old woman, Fitzpatrick type V, presented with 20% TBSA boiling water scalds to anterior neck, chest wall, bilateral axillae, right arm and abdomen sustained as a 10-year-old girl (Figure 1). Previously treated burn scar related breast asymmetry with symmetrising reduction to left, otherwise fit and well. Complained of chest wall tightness on inspiration, restricted shoulder abduction, tight pruritic, dyschromic hypertrophic burn scars. She underwent three sessions of fractional ablative CO₂ laser therapy. Marked improvement in burn scar texture, skin tone match and pliability, skin thickness, breast size with a remarkable patient reported immediate relief of chest wall tightness on inspiration and bilateral shoulder range of motion. Pictures pre treatment (left) and 3 months post last treatment (right). Treatment interval 3 months.
2. A 52-year-old man, Fitzpatrick type I, presented 3 years following 24% TBSA burns to face, chest and arms from an oil refinery explosion (Figure 2). Originally treated with split thickness skin grafting, he complained of red, pruritic, thickened, stiff

hypertrophic scar plaques and bands over his nose, nasolabial folds, chin, cheeks and preauricular regions bilaterally. He underwent three sessions of both fractional and Ultrapulse® ablative CO₂ laser therapy. Marked improvement in burn scar texture, band release, skin tone match and pliability, skin thickness. Pictures pre treatment (top row) and post treatment (bottom row). Treatment interval 3 months.

3. A 51-year-old male bodybuilder, Fitzpatrick type II, presented 2 years following a 5% TBSA molten steel contact burns to extensor surfaces both arms (Figure 3). Originally treated with split thickness skin grafting, he complained of red, pruritic, both hypertrophic and atrophic, unstable,

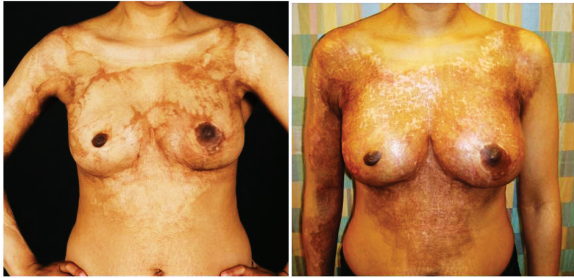

Figure 1. Laser settings. First cycle DeepFX® 12.5 MJ 600 Hz 2-10-1-5%, ActiveFX® 80 mJ 3-7-3. Second cycle DeepFX® 20 mJ 600 Hz 20 mJ 2-10-1-5. Final cycle SCAAR FX™ 150 mJ for thickest resistant scar bands and 60 mJ for the remainder, 600 Hz and 2-10-1-1% and ActiveFX® 80 mJ 3-7-3.

stiff scars over right elbow region. He underwent one session of ablative CO₂ laser therapy in combination with intralesional chemotherapy and pharmacotherapy. After one treatment, the wound was fully epithelialised and stable on full elbow flexion with an improvement of texture, thickness and pliability after 3 months. Pictures pre treatment (top row) and post treatment (bottom row).

4. A 64-year-old right-hand dominant man, Fitzpatrick type II, who sustained a right ring finger volar burn treated with excision and full thickness skin grafting presented with an area of unstable hyperkeratotic scar (Figure 4). He complained of recurrent wound breakdown, sensitivity and loss of function. After 1 month, the wound healed with soft pliable scar with full range of movement and functionality restored and no hyperkeratosis. Pre treatment (top row) and 1 month post treatment (bottom row).

Conclusions

Burns scars can have devastating consequences for patients. Currently, there is no standardised treatment protocol or indeed single modality used for all scars. This is due in part to the variability in both presentation, aetiology and surgical intervention as well as differences in individual response to treatment. This paper outlines the current burns scar management protocols of

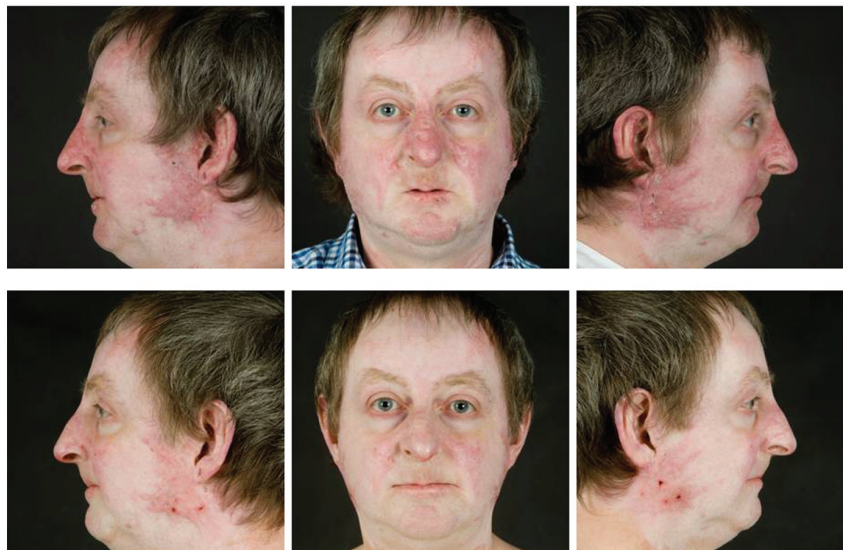

Figure 2. Laser settings. First cycle Ultrapulse® 2 mm true spot hand piece 175–225 mJ multiple passes to scar pits in the nasolabial folds and DeepFX® 25 mJ 600 Hz 2-10-1-5% to nasolabial folds and cheeks. Second cycle SCAAR FX™ 150 mJ 2-10-1-1% 250 Hz one pass for thickest resistant scar bands. Final cycle SCAAR FX™ 150 mJ 2-10-1-1% 300 Hz two passes for thickest resistant scar bands and ActiveFX® 80 mJ 3-7-3 one pass in the preauricular regions.

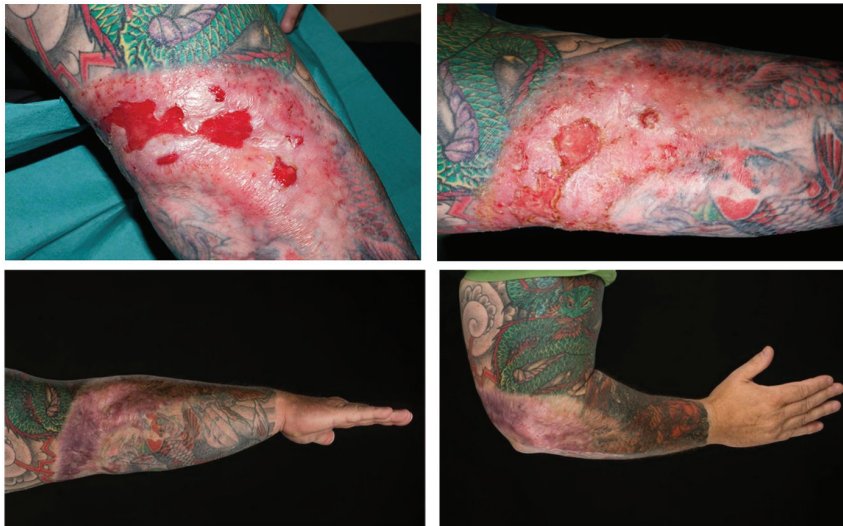

Figure 3. Laser settings and treatment. First cycle DeepFX® 20 mJ 600 Hz 2-10-1-10% to whole scar right elbow (including ulceration) with 100 mg of 5-Fluouracil and 40 mg of Triamcinolone injected to the thickest hypertrophic components.

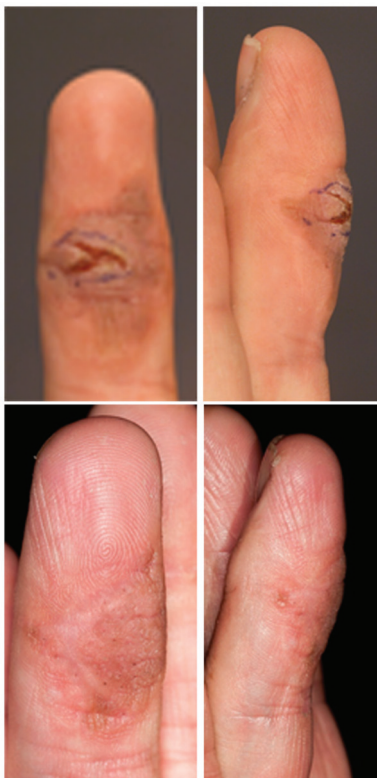

Figure 4. Laser settings. A single ablative CO₂ laser treatment with the Ultrapulse® 2 mm true spot hand piece 175 mJ multiple passes to ablate the hyperkeratosis and with the fractional DeepFX® 15 mJ 300 Hz 2-6-1-10% to whole scar right (including ulceration).

the senior author given his experience using multiple modalities. Individual case presentations are given to aid support for scar improvement following these treatments. Over the next decade further

advances in technology and the emergence of randomised clinical controlled trials will play a role in developing further strategies and techniques for the management of this diverse array of scar presentations and impact on form and function. In the meantime, we hope that our perspectives can assist in management of difficult cases. While subjective improvement and happy patients are the consistent outcomes of our practice as illustrated by these cases, further development of currently crude outcome measures for scars that are relevant to the front line are an additional and important area for further research.

Levels of evidence³³

Level 1: High-quality, multicentre or single-centre randomised controlled trial with adequate power; or systematic review of these studies.

Level 2: Lesser-quality randomised controlled trial; prospective cohort study; or systematic review of these studies.

Level 3: Retrospective comparative study; case-control study; or systematic review of these studies.

Level 4: Case series.

Level 5: Expert opinion; case report or clinical example; or evidence based on physiology, bench research, or 'first principles'.

Declaration of conflicting interests

The authors declared no potential conflicts of interest with respect to the research, authorship, and/or publication of this article.

Ethical approval

The authors confirm that the necessary written, informed consent was obtained from patients for this article.

Funding

This research received no specific grant from any funding agency in the public, commercial, or not-for-profit sectors.

References

- Sund B. [Clinical Report]. In: *New developments in wound care, vol. 86*. London: PJB Publications CBS, 2000: 1–255.
- Gauglitz GG, Korting HC, Pavicic T, et al. Hypertrophic scarring and keloids: Pathomechanisms and current and emerging treatment strategies. *Mol Med* 2011; 17: 113–125.
- Van Loey NE, Bremer M, Faber AW, et al. Itching following burns: epidemiology and predictors. *Br J Dermatol* 2008; 158: 95–100.
- Bell L, McAdams T, Morgan R, et al. Pruritus in burns: a descriptive study. *J Burn Care Rehabil* 1988; 9: 305–308.
- Robert R, Meyer W, Bishop S, et al. Disfiguring burn scars and adolescent self-esteem. *Burns* 1999; 25: 581–585.
- Bakker A, Maertens KJ, Van Son MJ, et al. Psychological consequences of pediatric burns from a child and family perspective: a review of the empirical literature. *Clin Psychol Rev* 2013; 33: 361–371.
- Pape SA, Skouras CA and Byrne PO. An audit of the use of Laser Doppler Imaging (LDI) in the assessment of burns of intermediate depth. *Burns* 2001; 27: 233–239.
- Xiao-Wu W, Herndon DN, Spies M, et al. Effects of delayed wound excision and grafting in severely burned children by early burn wound excision in the first 24 hours. *Arch Surg* 2003; 138: 127–132.
- Cubison T, Pape SA and Jeffery SLA. Dermal preservation using the Versajet hydrosurgery system for debridement of paediatric burns. *Burns* 2006; 32: 714–720.
- Jeffery SLA. Device related tangential excision in burns. *Injury* 2007; 38: S34–S37.
- Hawkins HK and Pereira CT. Pathophysiology of the burn scar. In: Herndon DN (ed.) *Total Burn Care*. 3rd ed. Philadelphia, PA: Saunders Elsevier, 2007: 608–619.
- Schneider JC, Holavanahalli R, Helm P, et al. Contractures in burn injury: Defining the problem. *J Burn Care Res* 2006; 27: 508–514.
- Su CW, Alizadeh K, Boddie A, et al. The problem scar. *Clin Plast Surg* 1998; 25: 451–465.
- Hantash BM, Bedi VP, Sudireddy V, et al. Laser-induced trans-epidermal elimination of dermal content by fractional photothermolysis. *J Biomed Opt* 2006; 11(4): 041115.
- Bedi VP, Chan KF, Sink RK, et al. The effects of pulse energy variations on the dimensions of microscopic thermal treatment zones in nonablative fractional resurfacing. *Lasers Surg Med* 2007; 39(2): 145–155.
- Hantash BM, Bedi VP, Chan KF, et al. Ex vivo histological characterization of a novel ablative fractional resurfacing device. *Lasers Surg Med* 2007; 39(2): 87–95.
- Hantash BM, Bedi VP, Kapadia B, et al. In vivo histological evaluation of a novel ablative fractional resurfacing device. *Lasers Surg Med* 2007; 39(2): 96–107.
- Manstein D, Herron G, Sink R, et al. Fractional photothermolysis: a new concept for cutaneous remodeling using microscopic patterns of thermal injury. *Lasers Surg Med* 2004; 34: 426–438.
- Tannous Z. Fractional resurfacing. *Clin Derm* 2007; 25: 480–486.
- Laubach HJ, Tannous Z, Anderson RR, et al. Skin responses to fractional photothermolysis. *Lasers Surg Med* 2006; 38: 142–149.
- Qu L, Liu A, Zhou L, et al. Clinical and molecular effects on mature burn scars after treatment with a fractional CO₂ laser. *Lasers Surg Med* 2012; 44: 517–524.
- Grunewald S, Bodendorf M, Illes M, et al. In vivo wound healing and dermal matrix remodeling in response to fractionated CO₂ laser intervention: Clinicopathological correlation in non-facial skin. *Int J Hyperthermia* 2011; 27(8): 811–818.
- Helbig D, Bodendorf M, Grunewald S, et al. Immunohistochemical investigation of the wound healing response to fractional photothermolysis. *J Biomed Opt* 2009; 14(6): 064044.
- Kroonen L, Shumaker PR, Kwan JM, et al. Treatment of split-thickness skin graft-related forearm scar contractures with a carbon dioxide laser protocol: 3 case reports. *J Hand Surg Am* 2013; 38: 2164–2168.
- Schwartz RJ, Burns AJ, Rohrich RJ, et al. Long-term assessment of CO₂ facial laser resurfacing: aesthetic results and complications. *Plast Reconstr Surg* 1999; 103: 592–601.
- Ross EV, Grossman MC, Duke D, et al. Long-term results after CO₂ laser skin resurfacing: a comparison of scanned and pulsed systems. *J Am Acad Dermatol* 1997; 37: 709–718.
- Fitzpatrick RE. CO₂ laser resurfacing. *Dermatol Clin* 2001; 19: 443–451, viii.
- Duke D, Khatri K, Grevelink JM, et al. Comparative clinical trial of 2 carbon dioxide resurfacing lasers with varying pulse durations: 100 microseconds vs 1 millisecond. *Arch Dermatol* 1998; 134: 1240–1246.
- Apfelberg DB and Smoller B. UltraPulse carbon dioxide laser with CPG scanner for deepithelialization: clinical and histologic study. *Plast Reconstr Surg* 1997; 99: 2089–2094.
- Trelles MA, Rigau J, Mellor TK, et al. A clinical and histological comparison of flashscanning versus pulsed technology in carbon dioxide laser facial skin resurfacing. *Dermatol Surg* 1998; 24: 43–49.
- Taub AF. Fractionated delivery systems for difficult to treat clinical applications: acne scarring, melasma, atrophic scarring, striae distensae, and deep rhytides. *J Drugs Dermatol* 2007; 6: 1120–1128.
- Alster TS and Tanzi EL. Hypertrophic scars and keloids: etiology and management. *Am J Clin Dermatol* 2003; 4: 235–243.
- Submission guidelines. Available at: <https://uk.sagepub.com/en-gb/eur/scars-burns-healing/journal202486#submission-guidelines> (last checked 19 March 2016).