

# Varying presentations and favourable outcomes of COVID-19 infection in children and young adults with sickle cell disease: an additional case series with comparisons to published cases

Patients with sickle cell disease (SCD) are theoretically at greater risk for serious illness from COVID-19 due to the underlying pathophysiology of chronic inflammation with an increased risk of thrombosis, especially at the time of a vaso-occlusive event.<sup>1</sup> Individuals living with SCD are also considered to be immunocompromised due to autoinfarction of their spleen or surgical splenectomy, often as a result of red-cell splenic sequestration.<sup>2</sup> In addition, patients with SCD often have comorbidities and secondary organ dysfunction that can put them at risk of significant morbidity and/or mortality from the severe acute respiratory coronavirus 2 (SARS-CoV-2), and its subsequent disease COVID-19. Due to the novel nature of the COVID-19 coronavirus, its overall effect on patients with SCD is not well understood. There are a total of six previous case series reported in sickle cell patients.<sup>3–9</sup> One recent article summarizes all the reported case series and calls on the need for a centralized registry.<sup>10</sup> This has been achieved by the global Secure-SCD Registry, Surveillance Epidemiology of Coronavirus (COVID-19) Under Research Exclusion (<https://covidsicklecell.org/>). In this report, we discuss a case series of COVID-19 infections in our patients, comparing our outcomes to previously reported cases.

We follow over 600 children and young adults with SCD in the Comprehensive Hemoglobinopathy Program. As of 11 May 2020 seven have tested positive for COVID-19 by polymerase chain reaction (PCR) using different assays. Although some of these seven patients may have been included in the initial characteristics of 5 700 patients reported from Northwell Health, this case series presents in-depth presentation and therapeutic results not presented in that article.<sup>11</sup> The Northwell Health Institutional Review Board approved this case series as minimal-risk research using data collected for routine clinical practice and waived the requirement for informed consent.

The majority (6/7) of the patients had sickle cell anaemia (HbSS) (Table I). Only one had HbSC disease and had obesity, which is reported as a risk factor for COVID-19.<sup>12</sup> The remaining descriptive and clinical findings in our patients are detailed in Table I, including admission, clinical course, respiratory support, antivirals, anti-inflammatory medications, and their outcomes.

As in previously reported cases, the most common symptoms in our patients were fever, acute chest syndrome (ACS), and a vaso-occlusive episode (VOE).<sup>3,4,6–9</sup>

Interestingly, only one patient was noted to have lymphopenia associated with COVID-19, which has been reported more commonly in patients without SCD.<sup>13</sup>

The patients who were febrile but did not require admission received our standard regimen for fever including an intravenous dose of ceftriaxone, followed in 24 h by an oral dose of levofloxacin at home. These patients were followed up via telephone. Patients who had a VOE received intravenous analgesics and were admitted if pain persisted.

Four patients were hospitalized for 2–10 days. One patient with psychiatric history presented with hypoxia noted at home and hallucinations. She was afebrile and her chest X-ray was clear. She did not have hypoxia while inpatient. However, due to her altered mental status and concern for thrombosis associated with COVID-19, she was started on treatment for COVID-19 and anticoagulation, pending brain MRI which was normal and she was discharged home.

The remaining three patients had ACS like many of the reported cases.<sup>3,4,7–9</sup> One patient was initially admitted for VOE and was found to be COVID-19-positive on routine surveillance. She then developed fever and ACS during the hospitalization. Two others had ACS on presentation.

Two patients with ACS received oxygen supplementation, similar to the other reported cases of ACS.<sup>3,4,6–9</sup> One required ICU stay for a high-flow nasal cannula; however none of them required intubation/mechanical ventilation. All, like in previous reports, required red-cell transfusions while the patient in the ICU also received an exchange transfusion.<sup>3,4,6,8,9</sup> They were initially treated with ceftriaxone and azithromycin as per our standard of care; this choice of antibiotics is similar to that in the previously reported cases. Once COVID-19 was confirmed, hydroxychloroquine (HCQ) was started and azithromycin was replaced with levofloxacin due to concern for prolonged corrected QT interval. Hydroxychloroquine, used as first-line therapy, was replaced with remdesivir (compassionate use, Gilead Sciences, Inc.) in the two patients with ACS due to worsening respiratory status. None of the other case series report use of remdesivir, though HCQ was used in some of the adults.<sup>4,9</sup>

Three patients with elevated inflammatory markers who met criteria for cytokine storm syndrome (CSS),<sup>14</sup> were treated with anakinra.<sup>15</sup> One patient's trend is shown in Fig 1. Two other case series discuss the use of tocilizumab; however, there are no reports of anakinra use in SCD.<sup>4,7</sup> As per our inpatient thromboprophylaxis guidelines for COVID-19,

Table 1. Clinical characteristics, laboratory findings, and treatments administered in sickle cell patients with COVID-19 infection.

Patient number	Age/gender	Sickle cell genotype	Comorbidity/splenectomy	Maintenance therapy	Initial presentation	Admission/LOS(days)	Initial CBC: WBC (k/μl)/ Hb (g/l)/ Platelets(k/μl)/ Lymphs(k/μl)/ ARC(k/μl)	Inflammatory markers		Oxygen support	Transfusion	Antibiotic Treatment	Antiviral Treatment	Anti-inflammatory Treatment	Thromboprophy/axis
								CRP(mg/l)/ ferritin (ng/ml)/ D-dimer (ng/ml)	n/a						
1	15/M	SS	Splenectomy	Exchange transfusion	Fever	N	19-4/107/215/ 2250/274	n/a		N	Had just received exchange on same day as fever	Ceftriaxone/ levofloxacin	None	None	N
2	11/F	SS	None	Hydroxy-carbamide	Fever, ACS	Y/ 10	19/53/418/ 3540/223	33/1862/ 2952		Y NC	Multiple simple transfusions	Ceftriaxone, azithromycin, levofloxacin, amoxicillin	HCC remdesvir	Anakinra	Y
3	2/M	SS	None	None	Fever, ACS	Y/ 7	14-7/90/207/ 5430/140	49-4/3655/ 8016		Y HFNC	Simple then exchange transfusion	Ceftriaxone, azithromycin, levofloxacin	HCC remdesvir	Anakinra	Y
4	18/F	SC	Obesity	None	Fever	N	8-3/102/173/ 700/69	n/a		N	None	Ceftriaxone, levofloxacin	None	None	N
5	14/F	SS	Atrial tachycardia	Hydroxy-carbamide	Fever, VOE	N	18-2/85/522/ 3940/312	n/a		N	None	Ceftriaxone, levofloxacin	None	None	N
6	20/F	SS	Hallucinations	Hydroxy-carbamide	Hypoxia, psychosis	Y/ 1	19/80/529/ 1080/290	<4/523/ 1686		N	None	Ceftriaxone, levofloxacin	HCC	Anakinra	Y
7	20/F	SS	Asthma/ obstructive sleep apnoea	Hydroxy-carbamide	VOE	Y/ 8	14-5/80/422/ 1900/197	51-8/458-3/ 1930		N	Simple transfusion	Levofloxacin	HCC	None	Y

M, male; F, female; ACS, acute chest syndrome; VOE, vaso-occlusive episode; Y, yes; N, no; WBC, white blood cell; Hb, haemoglobin; Lymphs, lymphocytes; ARC, absolute reticulocyte count; CRP, C-reactive protein; n/a, not applicable; LOS, length of stay; HCC, hydroxychloroquine; NC, nasal cannula; HFNC, high-flow nasal cannula.

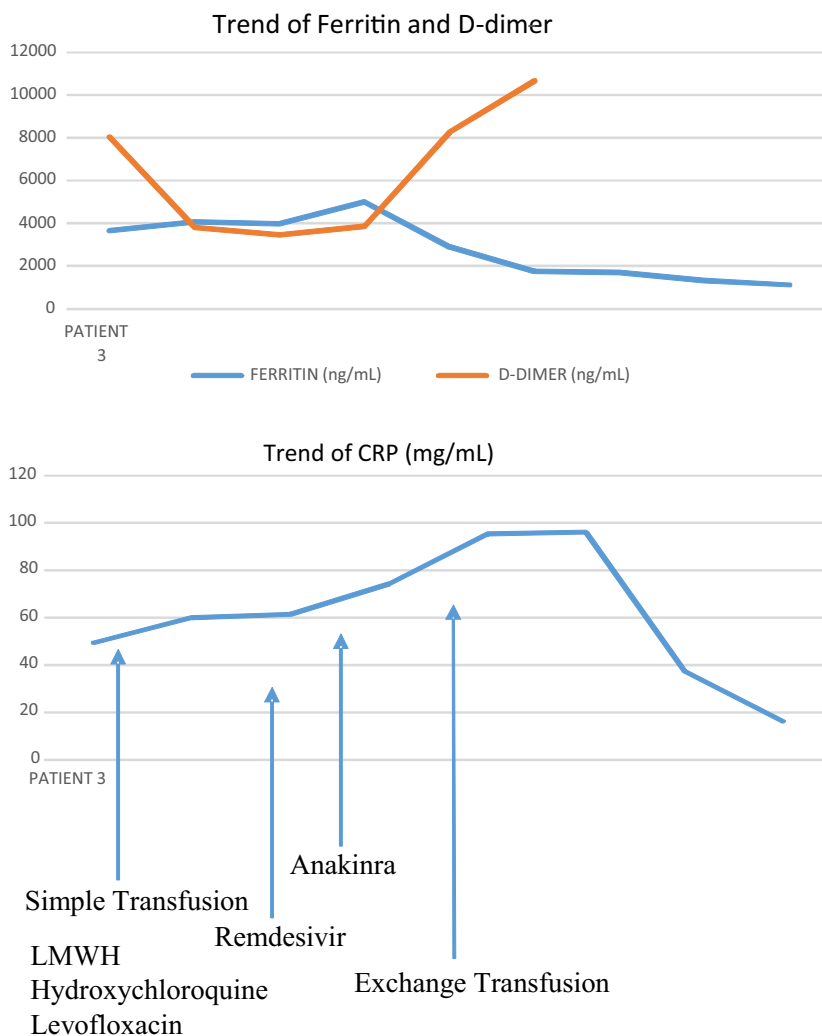


Fig 1. Trend of inflammatory markers in patient 3 during hospitalisation, in relation to treatment administered. CRP, C-reactive protein.


all admitted patients received prophylactic low-molecular-weight heparin (LMWH). The two patients who developed worsening respiratory symptoms with concern for pulmonary emboli were switched to treatment-dose LMWH but were discharged on prophylactic LMWH for an additional two weeks or until D-dimer normalized. Two previous case series report use of anticoagulation.<sup>5,8</sup>

This case series shows varying presentations and, in those who developed ACS, successful treatment of children and young adults with SCD and COVID-19 infection. Fever, ACS, and VOE were the most common presenting symptoms with ACS being the most common reason for admission. Early simple transfusion, followed by exchange transfusion in those requiring respiratory support in the ICU, made an impact on their clinical course. Antiviral therapy including both HCQ and remdesivir were used and well tolerated. Anakinra was successfully used in individuals with elevated inflammatory markers. We used prophylactic

and, in select cases, therapeutic anticoagulation and none of our patients developed evidence of thromboses. To date, most reported cases have had favourable outcomes. We believe this is due to an approach to patients with COVID-19 and SCD consisting of: attempts at the earliest possible diagnosis, use of antivirals, anti-inflammatory agents and anticoagulants, and early and aggressive transfusion for ACS.

### Acknowledgements

AAK and BA mainly wrote the manuscript. All authors reviewed and edited the manuscript. AAK, BA, SA, DB, AF, AV, CFL, GO, and KM, helped care for the patients. LW, JML, AAK, SA, and BA, developed standard operating procedures (SOPs) for patient care. We would like to acknowledge the contributions of the Northwell Health COVID-19 Research Consortium.

Abena Appiah-Kubi<sup>1,2</sup>   
 Suchitra Acharya<sup>1,2</sup>  
 Carolyn Fein Levy<sup>1,2</sup>  
 Adrianna Vlachos<sup>1,2</sup>  
 Gholamabbas Ostovar<sup>2,3</sup>  
 Kristina Murphy<sup>2,4</sup>  
 Antonella Farrell<sup>1,2</sup>  
 Donna Brower<sup>1,2</sup>  
 Jeffrey M. Lipton<sup>1,2</sup>  
 Lawrence Wolfe<sup>1,2</sup>  
 Banu Aygun<sup>1,2</sup>

<sup>1</sup>Division of Hematology/Oncology and Cellular Therapy, Cohen Children's Medical Center, Northwell Health, <sup>2</sup>Zucker School of Medicine at Hofstra/Northwell, Hempstead, <sup>3</sup>Division Infectious Diseases, Cohen Children's Medical Center, Northwell Health and <sup>4</sup>Division Pediatric Intensive Care, Cohen Children's Medical Center, Northwell Health, NY, USA.  
 E-mail: aappiah@northwell.edu

**Keywords:** sickle cell disease, children, blood transfusion

First published online 1 August 2020

doi: 10.1111/bjh.17013

## References

- Naik RP, Streiff MB, Lanzkron S. Sickle cell disease and venous thromboembolism: what the anticoagulation expert needs to know. *J Thromb Thrombolysis*. 2013;**35**(3):352–8.
- Johnston RB Jr, Newman SL, Struth AG. Increased susceptibility to infection in sickle cell disease: defects of opsonization and of splenic function. *Birth Defects Orig Artic Ser*. 1975;**11**(1):322–7.
- Hussain FA, Njoku FU, Saraf SL, Molokie RE, Gordeuk VR, Han J. COVID-19 infection in patients with sickle cell disease. *Br J Haematol*. 2020;**189**(5):851–852.
- De Luna Gonzalo, Habibi Anoosha, Deux Jean-François, Colard Martin, Pham Hung d'Alexandry d'Orengiani Anne-Laure, Schlemmer Frédéric, Joher Nizar, Kassaseya Christian, Pawlowsky Jean Michel, Ourghanlian Clément, Michel Marc, Mekontso-Dessap Armand, Bartolucci Pablo. Rapid and severe Covid-19 pneumonia with severe acute chest syndrome in a sickle cell patient successfully treated with tocilizumab. *Am J Hematol*. 2020;**95**(7):876–878.
- Heilbronner C, Berteloot L, Tremolieres P, Dupic L, De Saint Blanquat L, Lesage F et al Patients with Sickle cell disease and suspected COVID-19 in a pediatric ICU. *Br J Haematol*. 2020.
- Odievre MH, de Marcellus C, Ducou Le Pointe H, Allali S, Romain AS, Youn J et al Dramatic improvement after tocilizumab of severe COVID-19 in a child with sickle cell disease and acute chest syndrome. *Am J Hematol*. 2020.
- Nur E, Gaartman AE, van Tuijn CFJ, Tang MW, Biemond BJ. Vaso-occlusive crisis and acute chest syndrome in sickle cell disease due to 2019 novel coronavirus disease (COVID-19). *Am J Hematol*. 2020;**95**(6):725–6.
- McCloskey KA, Meenan J, Hall R, Tsitsikas DA. COVID-19 infection and sickle cell disease: a UK centre experience. *Br J Haematol*. 2020.
- Beerkens F, John M, Puliafito B, Corbett V, Edwards C, Tremblay D. COVID-19 pneumonia as a cause of acute chest syndrome in an adult sickle cell patient. *Am J Hematol*. 2020.
- Sahu KK, Siddiqui AD, Cerny J. Managing sickle cell patients with COVID-19 infection: the need to pool our collective experience. *Br J Haematol*. 2020.
- Richardson S, Hirsch JS, Narasimhan M, Crawford JM, McGinn T, Davidson KW et al Presenting characteristics, comorbidities, and outcomes among 5700 patients hospitalized with COVID-19 in the New York city area. *JAMA*. 2020.
- Kassir R. Risk of COVID-19 for patients with obesity. *Obes Rev*. 2020;**21**(6):e13034.
- Tan L, Wang Q, Zhang D, Ding J, Huang Q, Tang YQ et al Lymphopenia predicts disease severity of COVID-19: a descriptive and predictive study. *Signal Transduct Target Ther*. 2020;**5**(1):33.
- Cron RQ, Chatham WW. The Rheumatologist's role in COVID-19. *J Rheumatol*. 2020;**47**(5):639–42.
- Eloseily EM, Weiser P, Crayne CB, Haines H, Mannion ML, Stoll ML et al Benefit of Anakinra in treating pediatric secondary hemophagocytic lymphohistiocytosis. *Arthritis Rheumatol*. 2020;**72**(2):326–34.

# Clinical characteristics, management and outcome of COVID-19-associated immune thrombocytopenia: a French multicentre series

The causes of secondary immune thrombocytopenia (ITP), which account for approximately 18–20% of all adult ITP cases, include some viral infections.<sup>1,2</sup> Indeed, ITP can be triggered by or associated with many viruses including hepatitis C virus, human immunodeficiency virus, cytomegalovirus, Epstein–Barr virus and others like severe acute respiratory syndrome coronavirus-1 (SARS-CoV-1).<sup>1,3–5</sup> Among the suspected mechanisms, antibodies directed against virus glycoproteins may cross-react with platelet

surface integrins like glycoprotein IIb/IIIa (GPIIb/IIIa) or GPIb-IX-V.<sup>6</sup>

Mild thrombocytopenia has been observed in approximately 5–10% of patients with symptomatic SARS-CoV-2 infection.<sup>7</sup> Various mechanisms have been suggested, including decreased platelet production and enhanced platelet destruction, as for other viral infections.<sup>5,8</sup> Recently, a member of our network reported the first case of severe ITP associated with coronavirus disease 2019 (COVID-19).<sup>9</sup> Three