

# White opaque substance visualized by magnifying narrow-band imaging is associated with intragastric acid conditions



## Authors

Kazumi Togo<sup>1</sup>, Tetsuya Ueo<sup>1</sup>, Kenshi Yao<sup>2</sup>, Kurato Wada<sup>1</sup>, Hideho Honda<sup>1</sup>, Syotaro Inoue<sup>1</sup>, Masahide Fukuda<sup>1</sup>, Yuka Yanai<sup>1</sup>, Hirotohi Yonemasu<sup>3</sup>, Kazunari Murakami<sup>4</sup>

## Institutions

- 1 Department of Gastroenterology, Oita Red Cross Hospital, Japan
- 2 Department of Endoscopy, Fukuoka University Chikushi Hospital, Japan
- 3 Department of Pathology, Oita Red Cross Hospital, Japan
- 4 Department of Gastroenterology, Faculty of Medicine, Oita University, Japan

submitted 27.11.2017

accepted after revision 28.3.2018

## Bibliography

DOI <https://doi.org/10.1055/a-0611-4825> |

Endoscopy International Open 2018; 06: E830–E837

© Georg Thieme Verlag KG Stuttgart · New York

ISSN 2364-3722

## Corresponding author

Tetsuya Ueo, MD, PhD, Department of Gastroenterology, Oita Red Cross Hospital, Chiyo-machi, Oita 870-0033, Japan  
 Fax: +81-97-533-1207  
 ueo14@athena.ocn.ne.jp

## ABSTRACT

**Background and study aims** The presence of white opaque substance (WOS) is an endoscopic marker of intestinal metaplasia. Considering that the nature of WOS is absorbed

lipid droplets, lipase plays an important role in the lipid absorption process and is inactivated at strong acidity. WOS may only be present in a hypochlorhydria state following *Helicobacter pylori* infection, and, thus, may not be highly sensitive marker, especially in *H. pylori*-eradicated patients. We investigated the relationship between WOS and gastric acid conditions.

**Patients and methods** A total of 501 patients were retrospectively evaluated for the presence of WOS at 2 regions of interest using magnifying narrow-band imaging. The pH level of collected gastric juice was also measured. Study end points were (1) prevalence of WOS and its relationship with gastric juice pH in 3 groups: *H. pylori*-uninfected, *H. pylori*-infected, and *H. pylori*-eradicated; (2) the relationship between prevalence of WOS and gastric juice pH before and after proton pump inhibitor (PPI) administration in 29 *H. pylori*-eradicated cases.

**Results** Prevalence of WOS was 0% (0/206), 28.4% (31/109), and 3.2% (6/186) in the *H. pylori*-uninfected, *H. pylori*-infected, and *H. pylori*-eradicated groups, respectively. Mean gastric juice pH was significantly higher in WOS-positive cases than in WOS-negative cases in the *H. pylori*-infected and *H. pylori*-eradicated groups ( $P < 0.0001$ ). Mean gastric juice pH increased from 1.1 to 6.9 after PPI administration and WOS prevalence increased from 0% (0/29) to 45% (13/29) of cases.

**Conclusion** The prevalence of WOS is closely associated with the neutralization of intragastric pH.

## Introduction

*Helicobacter pylori*, when it infects the gastric mucosa, has been recognized as a major pathogen in the development of gastric cancer [1]. In particular, the presence of gastric intestinal metaplasia (IM) is thought to be an important risk in the development of gastric cancer because of its strong association with intestinal-type gastric cancer [2,3]. Appropriate surveillance of gastric IM could lead to earlier detection and treatment of gastric cancer, potentially leading to more favorable patient

survival outcomes [4]. As gastric IM shows heterogeneous patchy distribution and is not distinctly visible by conventional white-light endoscopy alone, the evaluation of gastric IM is of limited accuracy. In the Kyoto global consensus report on *H. pylori* gastritis, expert panels strongly recommend modern image-enhanced endoscopy, such as narrow-band imaging (NBI), for the accurate diagnosis of gastric IM [5].

Using magnifying NBI (M-NBI), light blue crest (LBC) has been widely accepted as an endoscopic marker of gastric IM [6]. LBC is defined as a fine, blue-white line on the crests of the

epithelial surface/gyri observable with M-NBI and histologically indicates the brush border of IM [6]. However, in a recent study, white opaque substance (WOS) observed with M-NBI was reported as another, novel, endoscopic marker of IM [7]. WOS on M-NBI was first reported by Yao et al. [8] as a substance present in the superficial part of gastric neoplasias that obscures the subepithelial microvascular architecture. According to fat (oil-red O) staining and immunohistochemical and immunoelectron microscopic studies for adipophilin, WOS in gastric epithelial neoplasia is an optical phenomenon caused by accumulated lipid droplets [9, 10]. Studies of *H. pylori* infection-associated IM of the stomach using lipid staining and light microscopy or electron microscopy showed that the epithelium in IM has the ability to absorb lipid droplets [11, 12].

Lipase plays a crucial role in the lipid digestion and absorption process and is known to be inactivated in strong acidity [13]. Therefore, we assume that the presence of absorbed lipid droplets as WOS in IM may represent a hypochlorhydria state caused by atrophic gastritis due to *H. pylori* infection and may not be a consistent phenomenon because it is influenced by acid recovery in *H. pylori*-eradicated patients. In other words, WOS may not be sufficiently sensitive as an endoscopic marker of IM in patients with recovered acid secretion after *H. pylori* eradication, an issue of critical importance that requires resolution. The Japanese government approved eradication treatment for patients with *H. pylori*-associated chronic gastritis under the National Health Insurance System from February 2013, and the number of patients who have received *H. pylori* eradication therapy is increasing in Japan. Moreover, the incidence of gastric cancer after *H. pylori* eradication has been increasing, especially in patients who have had observed IM in background mucosa [14]. Using routine screening endoscopy, accurate diagnosis of IM as a precancerous lesion in patients is required, including in those who have had *H. pylori* eradicated.

In this study, we aimed to clarify the clinical significance of the presence of WOS and its limitations in the changing gastric acid conditions in various chronic gastritis states secondary to *H. pylori* infection.

## Methods

### Study design and participants

This study was approved by the institutional review board of Oita Red Cross Hospital (IRB no. 190) and conducted according to the Declaration of Helsinki. All patients provided their written informed consent.

We retrospectively extracted 582 patients who underwent both upper gastrointestinal (GI) screening endoscopy with magnifying NBI and intragastric pH assessment at Oita Red Cross Hospital between April 2014 and July 2016. The data of fasting gastric juice used in this study were originally collected in our previous study on investigation of endoscopic findings that can predict gastric acid condition [15].

Subjects were excluded if they had following exclusion criteria: (1) patients who had a history of gastric resection; (2) with severe organ failure; (3) current intake of antiacid agents (within 5 d prior to the endoscopic examination); (4) patients

within 6 mo of prior *H. pylori* eradication; (5) patients with an unclear *H. pylori* status or suggestive of spontaneous *H. pylori* eradication and; (6) endoscopic images insufficient for assessment. After 81 patients were excluded, a total of 501 patients were included in this study.

### Endoscopic procedure and pH measurement of fasting gastric juice

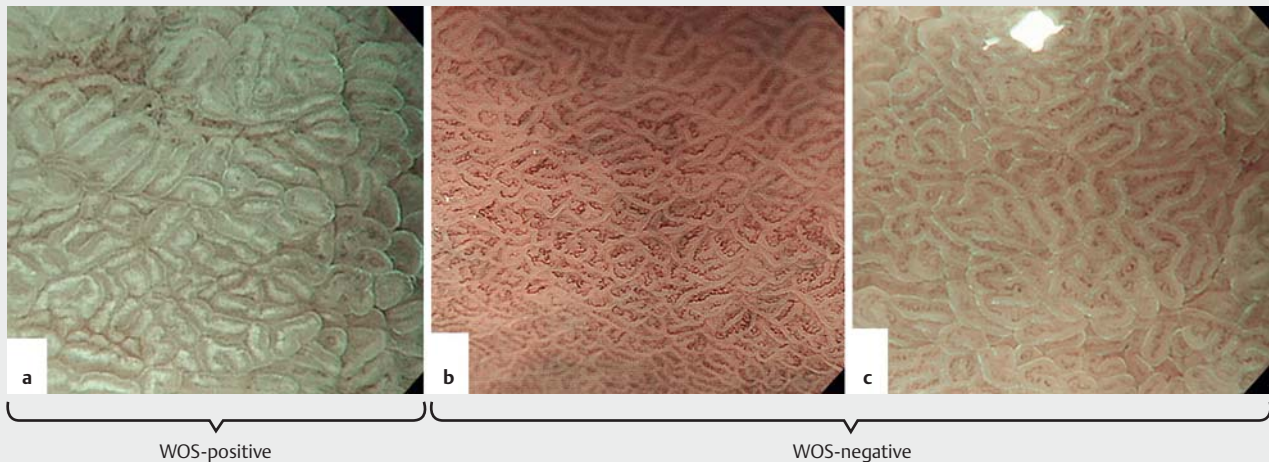
A high-resolution magnifying upper GI endoscope (GIF-Q240Z; Olympus, Tokyo, Japan) or a high-definition magnifying upper GI endoscope (GIF-H260Z, Olympus) and an electronic endoscopy system (EVIS LUCERA Spectrum, Olympus) were used. A soft black hood (MAJ-1989 for the GIF-Q240Z, MAJ-1990 for the GIF-H260Z; Olympus) was mounted at the tip of the endoscope to enable the endoscopist to fix a consistent focal distance between the tip of the endoscope and the gastric mucosa. Measurement of the pH of fasting gastric juice and M-NBI examinations were carried out by endoscopists K.T., T.U., K.W., H.H., S.I., M.F., and Y.Y.

Endoscopic study was performed following an overnight fast of 12 h or more. To avoid contamination affecting the accuracy of pH measurements, premedication (such as mucolytic or deforming agents) was not administered, except for local pharyngeal anesthesia with 8% lidocaine pump spray. Following endoscope insertion into the stomach, gastric juice pooled in the stomach was aspirated and collected endoscopically according to a previously described technique [16]. The pH of the collected sample was immediately measured using a 14-step pH test strip (pH 1–14; AS ONE Co., Osaka, Japan). Following this, the observer evaluated the presence or absence of WOS at 2 regions of interest using M-NBI. The observer then recorded the results on a digital filing system (NEXUS; Fujifilm Medical Co., Tokyo, Japan), and the images were subsequently double-checked by an experienced M-NBI endoscopist (T.U.).

### Definitions of WOS

The 2 regions of interest identified for assessment of presence of WOS were a 2×2 cm area at the lesser curvature of the antrum, 2 cm oral to the pylorus ring, and a 2×2 cm area at the lesser curvature of the gastric corpus, 4 cm oral to the angulus according to a previous report [17].

We defined the region of interest as WOS-positive when M-NBI findings showed a white substance obscuring the subepithelial capillaries of the intervening parts between crypt openings regardless of the degree or distribution and regardless of LBC coexistence (► Fig. 1a). A normal mucosa or LBC-positive but WOS-negative mucosa was defined as WOS-negative (► Fig. 1b and ► Fig. 1c). We divided the cases into WOS-negative (WOS-0), for which WOS was negative at both the pyloric gland area and the fundic gland area, WOS-pyloric (WOS-P), for which WOS was positive at the pyloric gland area only, WOS-fundic (WOS-F), for which WOS was positive at the fundic gland area only, and WOS-pyloric plus fundic (WOS-P+F), for which WOS was positive at both the pyloric gland area and the fundic gland area.



► **Fig. 1** Definition of WOS-positive or WOS-negative. **a** WOS was defined as positive when a white substance was observed by M-NBI that obscured the subepithelial capillaries of the intervening part between crypt openings in the region of interest, regardless of LBC coexistence. **b** Normal mucosa. **c** LBC positive but WOS-negative mucosa was defined as WOS-negative.

## Definitions of *H. pylori* status

To detect *H. pylori* infection, the following tests were used: serum Ig G antibody against *H. pylori*,  $^{13}\text{C}$ -urea breath test (UBT), urine antibody and stool antigen against *H. pylori*, and histological examination. A positive result for any test was diagnosed as “*H. pylori*-infected.” A negative result for least 1 test, without endoscopic atrophy, was diagnosed as “*H. pylori*-uninfected.” When a UBT yielded negative results with a history of eradication therapy, a diagnosis of “*H. pylori*-eradicated” was given. Subjects with a negative result for at least 2 of the tests, with endoscopic atrophy and no previous history of *H. pylori* eradication suggestive of spontaneous eradication, were excluded from the study.

## Proton pump inhibitor administration in 29 *H. pylori*-eradicated cases with gastric epithelial neoplasia

We assumed that WOS would not be highly sensitive as an endoscopic marker for IM in patients after *H. pylori* eradication, especially in cases with acid recovery. To clarify this, we investigated the relationship between the presence of WOS and the pH level of fasting gastric juice before and after proton pump inhibitor (PPI) administration in 29 *H. pylori*-eradicated cases with gastric epithelial neoplasia. Of these cases, 9 adenomas and 20 differentiated adenocarcinomas were detected at least 6 mo after successful *H. pylori* eradication, and these patients received endoscopic resection of neoplasia. For the treatment of gastric ulcer after endoscopic resection, we administered PPIs. In all 29 cases, we measured fasting gastric juice pH and observed for WOS before and after PPI administration (mean 21 d) according to the aforementioned procedure.

## End points

The end points of the study were (1) the prevalence of WOS and the relationship between the presence of WOS and fasting gastric juice pH level in 3 groups (*H. pylori*-uninfected, *H. pylori*-infected, and *H. pylori*-eradicated); (2) the relationship between the presence of WOS and fasting gastric juice pH level before and after PPI administration in 29 *H. pylori*-eradicated cases.

## Statistical analysis

Continuous variables were expressed as mean  $\pm$  standard deviation (SD) or 95% confidence interval (CI). For parametric variables, Student's t-test was used to compare the means between 2 groups; otherwise, a Wilcoxon's rank-sum test was used to compare the means of the groups. The chi-squared test or Fisher's exact test was used for comparisons of prevalence among the groups. McNemar's test was used to compare the prevalence of WOS before and after PPI administration in the 29 *H. pylori*-eradicated cases. A 2-sided p-value of less than 0.05 was considered statistically significant. Statistical analyses were performed using JMP-9 software (SAS Institute, Cary, NC).

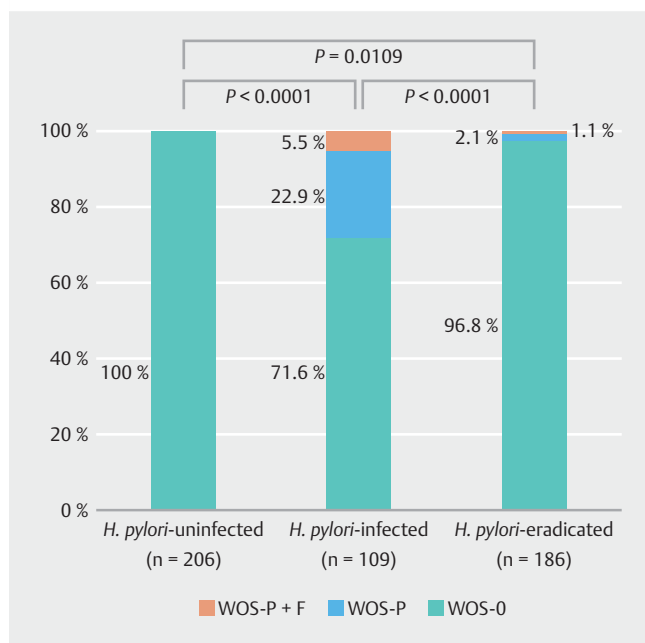
## Results

### Clinical features of patients divided into 3 groups by *H. pylori* status

► **Table 1** shows the characteristics of patients by dividing into 3 groups by *H. pylori* status (*H. pylori*-uninfected, *H. pylori*-infected, and *H. pylori*-eradicated). Among 501 patients included in this study, the mean  $\pm$  SD age of the patients was  $57.2 \pm 13.4$  y. The male to female ratio was 303:198. Of the 501 patients, 206 (41.1%) were *H. pylori*-uninfected, 109 (21.8%) were *H. pylori*-infected, and 189 (37.1%) were *H. pylori*-eradicated. The mean period (mo) after *H. pylori* eradication in subjects was 36 mo (range: 7–180 mo).

► **Table 1** Clinical characteristics of patients divided into 3 *H. pylori* status.

	<i>H. pylori</i> -uninfected (n = 206)	<i>H. pylori</i> -infected (n = 109)	<i>H. pylori</i> -eradicated (n = 186)	Total (n = 501)
Mean age ± SD (y)	49.0 ± 10.5	62.0 ± 13.1	64.4 ± 11.7	57.2 ± 13.4
Male/female, n	109/97	74/35	120/66	303/198
Gastric mucosal atrophy none/positive atrophy (closed or open type)	205/1	4/105	15/171	224/277
▪ Closed type atrophy, n (%)	1 (0.5)	30 (27.5)	96 (51.6)	127 (25.3)
▪ Open type atrophy, n (%)	0 (0)	75 (68.8)	75 (40.3)	150 (30.0)
Current or previous history of gastric tumor, n (%)	0 (0)	17 (15.6)	52 (27.9)	69 (13.7)



► **Fig. 2** Prevalence of WOS in *H. pylori*-uninfected, *H. pylori*-infected, and *H. pylori*-eradicated groups.

According to the Kimura-Takemoto classification system for degree of gastritis [18], 224 (44.7%) had no atrophy, 127 (25.3%) had closed-type atrophic gastritis, and 150 (30.0%) had open-type atrophic gastritis. Between the *H. pylori*-infected group and the *H. pylori*-eradicated group, there was no significant difference in the presence of atrophy ( $P=0.2179$ ). The presence of atrophy was 96.3% (closed type: 27.5%+open type: 68.8%) in the *H. pylori*-infected group and was 91.9% (closed type: 51.6%+open type: 40.3%) in the *H. pylori*-eradicated group.

Sixty-nine (13.7%) patients had a history of treatment of gastric epithelial neoplasia. Between the *H. pylori*-infected group and the *H. pylori*-eradicated group, history of treatment of gastric epithelial neoplasia was significantly higher in the *H. pylori*-eradicated group (27.9%) compared to the *H. pylori*-infected group (15.6%) ( $P=0.0158$ ).

### The prevalence of WOS in *H. pylori*-uninfected, *H. pylori*-infected, and *H. pylori*-eradicated groups

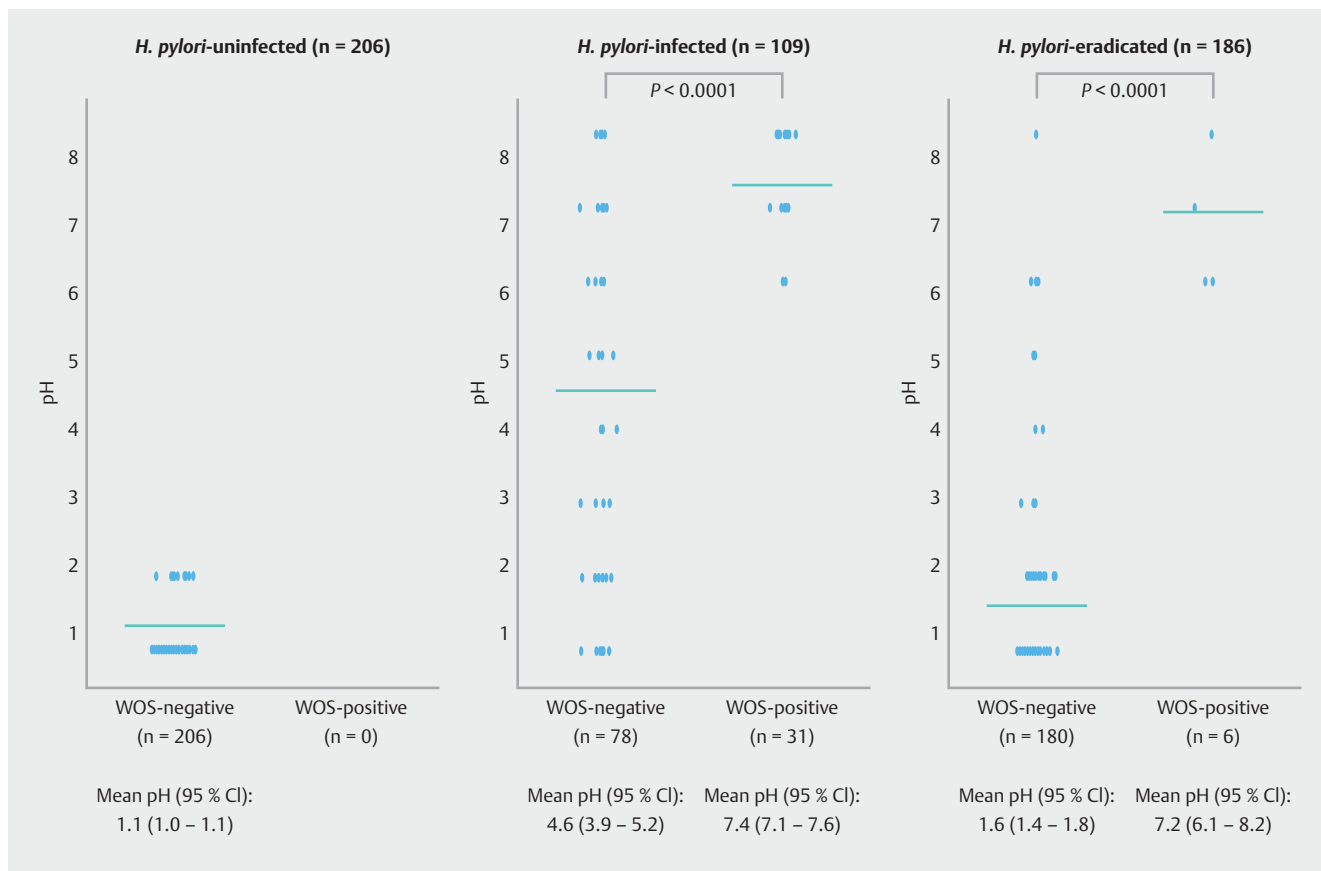
Prevalence of WOS was 0% (0/206) in the *H. pylori*-uninfected group, 28.4% (31/109) in the *H. pylori*-infected group, and 3.2% (6/186) in the *H. pylori*-eradicated group (► **Fig. 2**). A statistically significant difference in the prevalence of WOS was observed between the *H. pylori*-uninfected and *H. pylori*-infected groups ( $P<0.0001$ ) between the *H. pylori*-infected and *H. pylori*-eradicated groups ( $P<0.0001$ ) and between the *H. pylori*-uninfected and *H. pylori*-eradicated groups ( $P=0.0109$ ). The prevalence of WOS-P and WOS-P+F was 22.9% and 5.5%, respectively, in the *H. pylori*-infected group and 2.1% and 1.1%, respectively, in the *H. pylori*-eradicated group. There were no WOS-F cases.

### Relationship between the presence of WOS and pH level of fasting gastric juice in *H. pylori*-uninfected, *H. pylori*-infected, and *H. pylori*-eradicated groups

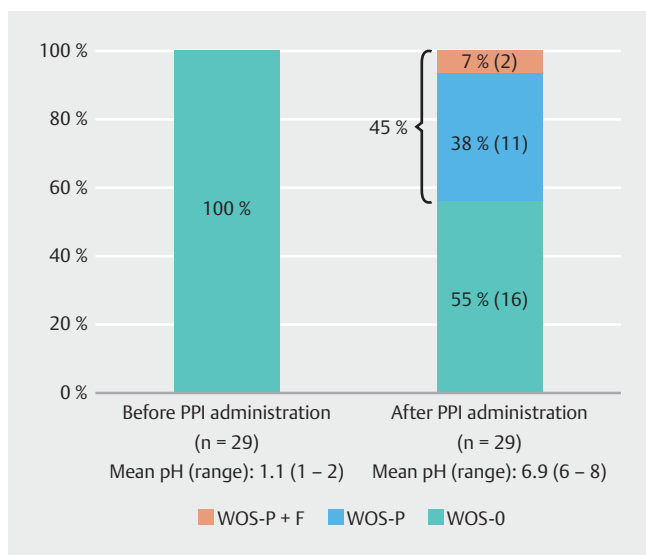
In the *H. pylori*-uninfected group, all cases were WOS-negative and the fasting gastric juice pH levels showed strong acidity (mean pH: 1.1, 95% CI: 1.0–1.1). In the *H. pylori*-infected group, mean pH level (95% CI) of fasting gastric juice in the WOS-positive cases was significantly higher than that of the in WOS-negative cases (mean pH: 7.4 [7.1–7.6] vs. 4.6 [3.9–5.2],  $P<0.0001$ ). Similar to the *H. pylori*-infected group, the mean pH level of fasting gastric juice in the *H. pylori*-eradicated group was also significantly higher in WOS-positive cases than WOS-negative cases (mean pH: 7.2 [6.1–8.2] vs. 1.6 [1.4–1.8],  $P<0.0001$ ). We observed a few WOS-positive cases in the *H. pylori*-eradicated group, comprising 3.2% ( $n=6$ ) of the total, and all of these fasting gastric juices demonstrated a neutral pH level (mean pH: 7.2, range: 6–8) (► **Fig. 3**).

### Relationship between the presence of WOS and pH level of fasting gastric juice before and after PPI administration in 29 *H. pylori*-eradicated cases with gastric epithelial neoplasia

We investigated the relationship between the presence of WOS and fasting gastric juice pH before and after PPI administration in 29 *H. pylori*-eradicated cases with gastric tumor to clarify that presence of WOS may not be a highly sensitive endoscopic



► **Fig. 3** Relationship between the presence of WOS and fasting gastric juice pH level in *H. pylori*-uninfected, *H. pylori*-infected, and *H. pylori*-eradicated groups.



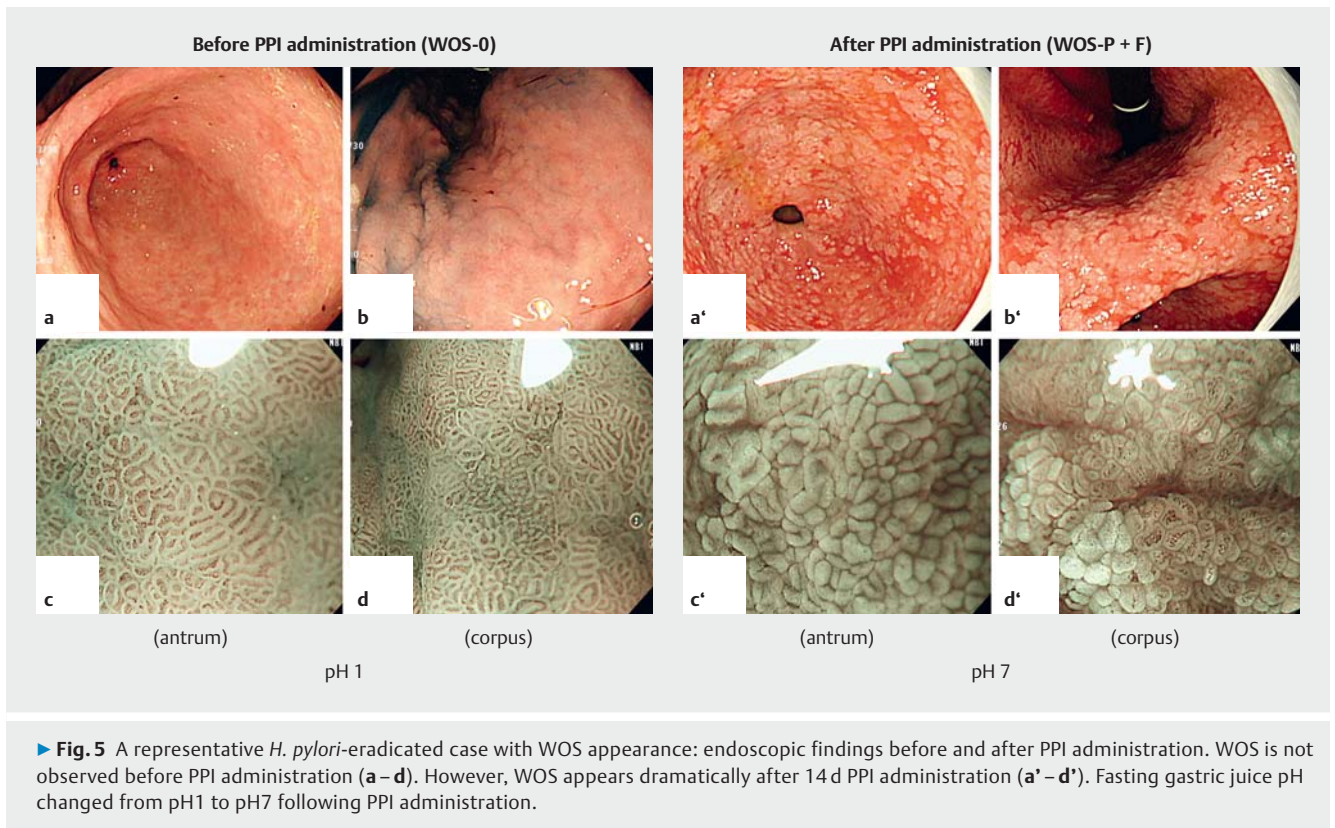
► **Fig. 4** Relationship between the presence of WOS and fasting gastric juice pH before and after PPI administration in 29 *H. pylori*-eradicated cases with gastric epithelial neoplasia.

marker of IM in patients after *H. pylori* eradication, especially in cases with acid recovery. The mean fasting gastric juice pH level in these 29 cases increased from 1.1 before PPI administration to 6.9 after. WOS positivity increased from 0% (0/29) before PPI administration to 45% (13/29) after (► **Fig. 4**). Of the 13 cases in which WOS appeared after PPI administration, the prevalence of WOS-P and WOS-P + F was 11/13 and 2/13, respectively (► **Fig. 4** and ► **Fig. 5**). These findings suggested that the presence of WOS is not highly sensitive as an endoscopic marker for IM in patients after *H. pylori* eradication, especially in patients with acid recovery.

## Discussion

In this study, we clarified the clinical significance of WOS as an optical marker for IM and its limitations in the changing gastric acid conditions in various *H. pylori* states. The presence of WOS in IM was thought to be closely associated with a hypochlorhydria state in atrophic gastric mucosa caused by *H. pylori* infection. However, WOS may not be highly sensitive as an endoscopic marker for IM in patients with acid recovery after *H. pylori* eradication.

The study results demonstrated that the presence of WOS in IM was closely associated with a hypochlorhydria state caused by *H. pylori* infection. WOS, as observed by M-NBI, was most fre-



► **Fig. 5** A representative *H. pylori*-eradicated case with WOS appearance: endoscopic findings before and after PPI administration. WOS is not observed before PPI administration (a–d). However, WOS appears dramatically after 14 d PPI administration (a'–d'). Fasting gastric juice pH changed from pH1 to pH7 following PPI administration.

quently found in the *H. pylori*-infected group (28.4%), infrequently observed in *H. pylori*-eradicated cases (3.2%), and not found at all in *H. pylori*-uninfected cases. In addition, there was a close relationship between the presence of WOS and fasting gastric juice pH level. Among the 295 *H. pylori*-infected and *H. pylori*-eradicated cases, fasting gastric juice pH level was significantly higher in WOS-positive cases (mean pH 7.4 and 7.2, respectively) than in WOS-negative cases (mean pH 4.6 and 1.6, respectively). Interestingly, All of WOS-positive cases in the *H. pylori*-eradicated group (3.2% of the total) showed neutral fasting gastric juice pH levels (mean pH 7.2, range 6–8), even after successful *H. pylori* eradication. From these findings, we concluded that a WOS-positive state was closely associated with neutralization of intragastric pH in *H. pylori*-infected and *H. pylori*-eradicated cases.

As the degree of mucosal atrophy progresses, acidity in the stomach is neutralized to a pH level of approximately 7.0 [19]. In contrast, *H. pylori* eradication therapy contributes to the normalization of gastric juice pH owing to a recovery of acid secretion, not only in the intact stomach but also in the remaining stomach after gastrectomy [20,21]. However, some patients with profound hypochlorhydria may not recover because of progression to an irreversible stage [22]. It is well known that chronic gastric acid hypochlorhydria and achlorhydria are important risk factors for the development of gastric cancer [23, 24]. Therefore, endoscopic investigations that allow speculation of gastric acid conditions are highly desirable. The mechanism of WOS expression suggests that presence of WOS could be a marker representing neutralization of intragastric pH due

to *H. pylori* infection. Accordingly, WOS might be an important marker for predicting high risk for the development of gastric cancer.

Furthermore, the study results demonstrate the limitation of WOS as a marker for IM. That is, WOS might not be highly sensitive as an endoscopic marker for IM in patients after *H. pylori* eradication with acid recovery. Between the *H. pylori*-infected group and the *H. pylori*-eradicated group, there was no significant difference in the presence of atrophy by Kimura-Takemoto classification system ( $P=0.2179$ ). The presence of atrophy was 96.3% in the *H. pylori*-infected group and was 91.9% in the *H. pylori*-eradicated group. On the other hand, treatment history of gastric neoplasia was significantly higher in the *H. pylori*-eradicated group (27.9%) compared to the *H. pylori*-infected group (15.6%) ( $P=0.0158$ ). However, WOS was significantly lower (3.3%) in the *H. pylori*-eradicated group compared to the *H. pylori*-infected group (28.4%) in spite of there being no significant difference on the presence of atrophy representative of a surrogate marker of IM. In addition, we investigated the relationship between the presence of WOS and fasting gastric juice pH level before and after PPI administration in 29 *H. pylori*-eradicated cases with gastric epithelial neoplasias. Although we could not observe any WOS in these *H. pylori*-eradicated cases with acid recovery, WOS dramatically appeared in 45% of these cases following neutralization of intragastric pH with PPI administration. From these findings, we concluded that the presence of WOS is not a consistent phenomenon. Therefore, in our routine screening endoscopy, we should pay attention for the evaluation of IM by WOS findings if a patient has a history of *H. pylori* eradica-

tion. If WOS is not detected, the existence of histological IM cannot be completely excluded. If WOS is detected in patients even after *H. pylori* eradication, not only is the existence of histologic IM suggested, but also that acid secretion has not yet recovered. In other words, such patients may have a high risk for developing gastric cancer despite the eradication of *H. pylori*, since chronic gastric acid hypochlorhydria and achlorhydria are important risk factors for the development of gastric cancer [23, 24].

Kanemitsu et al., [7] recently demonstrated that the presence of WOS, as observed by M-NBI as a novel endoscopic parameter for the histological diagnosis of IM, had a sensitivity and specificity of 50% and 100%, respectively. However, in patients with *H. pylori* eradication, diagnosing IM using WOS findings alone may not be sufficiently sensitive. Our results suggested that WOS was not highly sensitive despite histological IM because WOS is affected by some of the intragastric environment. Ohtsu et al. [25] revealed that the oral ingestion of foods containing fats increased the prevalence of WOS in gastric epithelial neoplasia. We believe that the intragastric pH environment is also an important factor, with the activation of lipase, including pancreatic, lingual and gastric types, increasing the prevalence of WOS. It may be necessary to clarify how the combination of antacid and emulsified fat foods contribute to the emergence of WOS.

The study had several limitations. First, it was retrospective and conducted at a single center. Second, gastric acid conditions were only evaluated by fasting gastric juice pH level. Although pH measurement of fasting gastric juice is one of reliable information for gastric acid condition, it is not an ideal method for evaluation of acid secretion itself. Third, we did not study the relationship of other optical markers such as LBC with histological IM, regardless of *H. pylori* eradication status. Finally, the patients included in this study received endoscopy for mainly screening purposes, so we could not examine IM histologically. A further well-designed prospective study with histologic examination is expected to clarify these issues.

In conclusion, the results of this study suggest that the presence of WOS in *H. pylori*-infected gastritis is closely associated with a neutralization of intragastric pH due to *H. pylori* infection but is not a highly sensitive endoscopic marker of IM in patients after *H. pylori* eradication.

## Acknowledgements

This work was supported by the Central Research Institute for Endoscopy, Fukuoka University.

## Competing interests

None

## References

- [1] Uemura N, Okamoto S, Yamamoto S et al. *Helicobacter pylori* infection and the development of gastric cancer. *N Engl J Med* 2001; 345: 784–789
- [2] Shichijo S, Hirata Y, Sakitani K et al. Distribution of intestinal metaplasia as a predictor of gastric cancer development. *J Gastroenterol Hepatol* 2015; 30: 1260–1264
- [3] Correa P. Chronic gastritis as a cancer precursor. *Scand J Gastroenterol Suppl* 1984; 104: 131–136
- [4] De Vries AC, van Grieken NC, Looman CW et al. Gastric cancer risk in patients with premalignant gastric lesions: a nationwide cohort study in the Netherlands. *Gastroenterology* 2008; 134: 945–952
- [5] Sugano K, Tack J, Kuipers EJ et al. Kyoto global consensus report on *Helicobacter pylori* gastritis. *Gut* 2015; 64: 1353–1367
- [6] Uedo N, Ishihara R, Iishi H et al. A new method of diagnosing gastric intestinal metaplasia: narrow-band imaging with magnifying endoscopy. *Endoscopy* 2006; 38: 819–824
- [7] Kanemitsu T, Yao K, Nagahama T et al. Extending magnifying NBI diagnosis of intestinal metaplasia in the stomach: the white opaque substance marker. *Endoscopy* 2017; 49: 529–535
- [8] Yao K, Iwashita A, Tanabe H et al. White opaque substance within superficial elevated gastric neoplasia as visualized by magnification endoscopy with narrow-band imaging: a new optical sign for differentiating between adenoma and carcinoma. *Gastrointest Endosc* 2008; 68: 574–580
- [9] Yao K, Iwashita A, Nambu M et al. Nature of white opaque substance in gastric epithelial neoplasia as visualized by magnifying endoscopy with narrow-band imaging. *Dig Endosc* 2012; 24: 419–425
- [10] Ueo T, Yonemasu H, Yada N et al. White opaque substance represents an intracytoplasmic accumulation of lipid droplets: immunohistochemical and immunoelectron microscopic investigation of 26 cases. *Dig Endosc* 2013; 25: 147–155
- [11] Rubin W, Ross LL, Jeffries GH et al. Some physiologic properties of heterotopic intestinal epithelium. Its role in transporting lipid into the gastric mucosa. *Lab Invest* 1967; 16: 813–827
- [12] Siurala M, Tarpila S. Absorptive function of intestinal metaplasia of the stomach. *Scand J Gastroenterol* 1968; 3: 76–79
- [13] Borgstrom B, Brockman HL. *Lipases*. Amsterdam: Elsevier; 1984
- [14] Chen HN, Wang Z, Li X et al. *Helicobacter pylori* eradication cannot reduce the risk of gastric cancer in patients with intestinal metaplasia and dysplasia: evidence from a meta-analysis. *Gastric Cancer* 2016; 19: 166–175
- [15] Ueo T, Yanai Y, Ishida T. [Presence of hematin represents lower intragastric pH level]. *Gastroenterol Endosc* 2015; 57: 2054
- [16] Segawa K, Nakazawa S, Tsukamoto Y et al. Estimate of gastric acid output by evaluation of fasting gastric juice collected endoscopically. *Hepatogastroenterology* 1991; 38: 79–82
- [17] Fukuta N, Ida K, Kato T et al. Endoscopic diagnosis of gastric intestinal metaplasia: a prospective multicenter study. *Dig Endosc* 2013; 25: 526–534
- [18] Kimura K, Takemoto T. An endoscopic recognition of the atrophic border and its significance in chronic gastritis. *Endoscopy* 1969; 3: 87–97
- [19] Feldman M, Cryer B, Sammer D et al. Influence of *H. pylori* infection on meal-stimulated gastric acid secretion and gastroesophageal acid reflux. *Am J Physiol* 1999; 277: 1159–1164
- [20] Taguchi Y, Kaito M, Gabazza EC et al. *Helicobacter pylori* inhibits the secretory activity of gastric parietal cells in patients with chronic gastritis. An ultrastructural study. *Scand J Gastroenterol* 1997; 32: 656–663

- [21] Kato S, Matsukura N, Matsuda N et al. Normalization of pH level and gastric mucosa after eradication of *H. pylori* in the remnant stomach. *J Gastroenterol Hepatol* 2008; 23: 258–261
- [22] Iijima K, Sekine H, Koike T et al. Long-term effect of *Helicobacter pylori* eradication on the reversibility of acid secretion in profound hypochlorhydria. *Aliment Pharmacol Ther* 2004; 19: 1181–1188
- [23] Svendsen JH, Dahl C, Svendsen LB et al. Gastric cancer risk in achlorhydric patients. A long-term follow-up study. *Scand J Gastroenterol* 1986; 21: 16–20
- [24] Argent RH, Thomas RJ, Aviles-Jimenez F et al. Toxigenic *Helicobacter pylori* infection precedes gastric hypochlorhydria in cancer relatives, and *H. pylori* virulence evolves in these families. *Clin Cancer Res* 2008; 14: 2227–2235
- [25] Ohtsu K, Yao K, Matsunaga K et al. Lipid is absorbed in the stomach by epithelial neoplasms (adenomas and early cancers): a novel functional endoscopy technique. *Endosc Int Open* 2015; 3: E318–E322