

Concordant Occipital and Supraorbital Neurostimulation Therapy for Hemiplegic Migraine; Initial Experience; A Case Series

Ken L. Reed, MD*[‡]; Kelly R. Will, MD[†]; Frank Conidi, MD[‡]; Robert Bulger, MD[§]

Introduction: Hemiplegic migraine is a particularly severe form of the disease that often evolves to a debilitating chronic illness that is resistant to commonly available therapies. Peripheral neurostimulation has been found to be a beneficial therapy for some patients among several diagnostic classes of migraine, but its potential has not been specifically evaluated for hemiplegic migraine.

Materials and Methods: Four patients with hemiplegic migraine were treated with concordant, combined occipital and supraorbital neurostimulation over periods ranging 6–92 months. The clinical indicators followed included assessments of headache frequency and severity, frequency of hemiplegic episodes, functional impairment, medication usage, and patient satisfaction.

Results: All reported a positive therapeutic response, as their average headache frequency decreased by 92% (30 to 2.5 headache days/month); Visual Analog Score by 44% (9.5 to 5.3); frequency of hemiplegic episodes by 96% (7.5 to 0.25 hemiplegic episodes/month); headache medication usage by 96% (6 to 0.25 daily medications); and Migraine Disability Assessment score by 98% (249 to 6). All were satisfied and would recommend the therapy, and all preferred combined occipital–supraorbital neurostimulation to occipital neurostimulation alone.

Conclusions: Concordant combined occipital and supraorbital neurostimulation may provide effective therapy for both the pain and motor aura in some patients with hemiplegic migraine.

Keywords: Chronic migraine, combined occipital and supraorbital nerve stimulation, hemiplegic migraine, migraine, occipital nerve stimulation

Conflict of Interest: Dr. Reed has served as a paid consultant for St. Jude Medical and is a co-investigator in St. Jude Medical's studies evaluating occipital nerve stimulation for migraine headaches. Dr. Will has served as a paid consultant for St. Jude Medical. No advice, direction, or assistance (financial or otherwise) was received for this study. Drs. Reed, Bulger, and Will report no conflicts other than stated above. Dr. Conidi reports no conflicts.

INTRODUCTION

Hemiplegic migraine (HM) is a rare but particularly severe form of migraine that is distinguished by its associated motor aura. The International Classification of Headache Disorders II (ICHD II) recognizes two subtypes, familial HM and sporadic HM, which are similar clinically and differ only in familial associations (1). Though uncommon, it is the most debilitating form of the disease and often progresses to an incapacitating situation resistant to medical management (2–4). Recognition of the magnitude of its impact on society has galvanized a search for more effective therapies, an end to which guidance is provided by evidence that HM has mechanisms and therapies in common with other migraine types (2,5,6). On the basis of these common features we felt that other documented migraine therapies, including implanted peripheral neurostimulation (PNS), might also benefit HM.

PNS therapy for headache (HA) may be divided into two categories according to paresthesia concordancy, where a concordant paresthesia is defined as one that optimally covers the anatomic area of perceived pain (7,8). Examples of the “concordant paresthesia” category include the application of occipital nerve stimulation (ONS) to occipital neuralgia, supraorbital nerve stimulation (SONS) to supraorbital neuralgia, and combined occipital and supraorbital

neurostimulation (ON-SONS) to patients with holocephalic pain due chronic migraine. Typifying the “non-concordant paresthesia” category is the application of ONS to any migraine pain perceived over the distant fronto-temporal (trigeminal) region. There is some preliminary evidence that suggests a higher success rate for implants that produce a concordant paresthesia (Tables 1 and 2) (7).

Address correspondence to: Ken Reed, MD, Reed Migraine Centers, 11970 N Central Expy; Suite 510, Dallas, TX 75243, USA. Email: klreed1@swbell.net

* Interventional Pain Management and Internal Medicine, Reed Migraine Centers, Dallas, TX, USA;

† Interventional Pain Management, Texas Institute of Surgery, Dallas, TX, USA;

‡ Department of Neurology, Florida State University College of Medicine, West Palm Beach, FL, USA; and

§ Interventional Pain Management, Department of Anesthesiology, Presbyterian Hospital of Dallas, Dallas, TX, USA

For more information on author guidelines, an explanation of our peer review process, and conflict of interest informed consent policies, please go to <http://www.wiley.com/bw/submit.asp?ref=1094-7159&site=1>

This is an open access article under the terms of the Creative Commons Attribution-NonCommercial-NoDerivs License, which permits use and distribution in any medium, provided the original work is properly cited, the use is non-commercial and no modifications or adaptations are made.

Table 1. Summary of Primary Headache Diagnostic Categories Treated with Non-concordant Neurostimulation.

Report	Dx	Stim	No perms	No responders	Resp rate
Cluster Treated with ONS Alone					
Dodick (9)	CI	ONS	1	1	100%
Burns (10,11)	CI	ONS	20	9	45%
Magis (12)	CI	ONS	14	12	85%
Trentman (13)	CI	ONS	5	3	60%
Schwedt (14)	CI	ONS	8	5	60%
de Quintana (15)	CI	ONS	4	4	100%
Fontaine (16)	CI	ONS	13	10	77%
Mueller (17)	CI	ONS	10	4	40%
					64% avg
Chronic Migraine Treated with ONS Alone					
Saper (Medtronic) (18)	CM	ONS	51	?	39%
Silberstein; Dodick (St. Jude) (19,20)	CM	ONS	157	20	48%
Lipton (Boston Scientific) (21)	CM	ONS	132	?	?
Paemeliere (22)	CM	ONS	8	5	63%
Brewer (23)	CM	ONS	12	5	42%
Palmisani (24)	CM	ONS	17	9	53%
					47% avg

**Summary: 51% avg for all non-concordant studies (CM & CI)
47% avg for all CM studies (excludes Lipton)**

The Medtronic study used a VAS improvement of 30% as the test for positive response, rather than the historical standard of 50%. The statistics from the St. Jude Study Group's reports (Silberstein (20); Dodick (19)) come from the Dodick (19) report. Table 1 is an update on a table from a previous report of our group (7).
CI, cluster; CM, chronic migraine; HC, hemicrania continua.

Table 2. Summary of All Primary Headache Categories Treated with Concordant Neurostimulation.

Report	Dx	Stim	No perm	No responders	Resp rate
Occipitally Focused Primary HA Treated with ONS Alone					
Popeney, Aló (25)	TM	ONS	25	25	100%
Oh (26)	TM	ONS	10	9	90%
Matharu (27)	CM	ONS	8	8	100%
					98% avg
Frontal Primary HA Treated with Trigeminal Stim Alone					
Narouze (28)	CI	SON	1	1	100%
Vaisman (29)	CI	SON	5	5	100%
Simopoulos (30)	CM	AT	1	1	100%
					100% avg
Hemicephalic/Holocephalic Primary HA Treated with Combined Stim					
Reed (31)	CM	ON-SON	7	7	100%
Deshpande (32)	CM	ON-ATN	1	1	100%
Hahn (33)	CM	ON-SON	14	10	70%
Mammis (34)	CI	ON-SON-ION	1	1	100%
Zach (35)	CM	ON-ATN	1	1	100%
					83% avg
Mixed Regional/Hemicephalic/Holocephalic Primary HA Treated with Mixed Concordant Stim					
Verrills (36)	CM	ON; SON; ON-SON/ION	60	7	68%
					68% avg

**Summary: 82% avg response for all concordant studies
81% avg response for CM studies**

The Popeney and Oh reports on transformed migraine were expressly on patient groups whereby the pain was solely or primarily focused over the occipital region.

Unless otherwise specified all success rates indicate > 50% improvement in VAS or HA freq.

Table 2 is an update of a table from a previous report from our group (7).

TM, transformed migraine; CEH, cervicogenic headache; IC2H, intractable C-2 Headaches; AC, Arnold-Chiari; CM, chronic migraine; CNP, cervical neuropathic pain; TNP, trigeminal neuropathic pain; AFP, atypical facial pain; PHN, post herpetic neuralgia; SON, supraorbital nerve; ATN, auriculotemporal nerve; ION, infraorbital nerve; ON, occipital nerve.

Based upon these considerations, we felt that concordant combined ON-SONS may have potential as a therapy for HM. While previous studies have documented PNS efficacy across a wide range of primary HA diagnostic categories, including two papers that reported resolution of hemiplegia as an associated finding, this is the first to specifically consider its potential as a therapy for HM (31,32).

MATERIALS AND METHODS

As our center does not have a formal ethics review committee, we note that the procedures involved in the evaluation and treatment of all patients, including full oral and written informed consent, were part of the normal procedures applied to all patients in the physicians' offices. Further, all aspects of patient care specifically conformed to the ethical principles for human subjects as outlined in the Declaration of Helsinki.

Between 2004 and 2013 five patients suffering from debilitating, chronic HM were referred to our facility for evaluation for implantable PNS. All had been under the care of experienced neurology headache specialists, who for each patient had documented an extensive diagnostic evaluation, including laboratory and imaging studies to rule out other causes of chronic head pain. No genetic testing was undertaken for the recognized gene mutations associated with familial HM; however, the family histories of all the patients were specifically negative for HM (37). All diagnoses conformed to ICHD II criteria for HM (1).

Following a full clinical evaluation, each patient underwent a five- to seven-day period of trial stimulation. Those reporting a positive response (>50% imp in pain severity by a visual analog scale [VAS] and/or headache frequency [HA days/mo]) were offered a permanent implant. Over the seven-year period between the first and last HM patients, our clinical approach to trial stimulation for all PNS patients evolved. As such, the first HM patient had initially only a trial, then permanent, ONS implanted; whereupon, as the response was inadequate, a SONS was added two months later and a full therapeutic response achieved. The second HM patient was evaluated during a period where we included two phases during the trial period for comparison—one that provided only ONS, and the other, combined ON-SONS, and per his preference the combined system was permanently implanted. Thereafter, our approach for all patients undergoing a PNS trial for head pain has been to deliberately position leads according to where the patient reported pain and in a manner so as to optimize paresthesia concordancy. As both remaining patients were experiencing holocephalic pain, each had combined ON-SONS systems trialed and then permanently implanted.

The operative procedures have been described in our previous reports (31,38). Essentially, in the permanent procedure lead terminal arrays were positioned subcutaneously over both the supraorbital and occipital nerves (Fig. 1), whereupon the lead bodies were passed subcutaneously and connected to an implantable pulse generator (IPG). The IPGs in the first two patients were implanted in their upper gluteal regions. Seeking to ease tension on the leads and thus help rectify problems with lead migration, the IPGs in the subsequent three patients were implanted in the upper chest wall. Systems used included either an Eon with quadripolar leads (St. Jude Medical Inc., Plano, TX, USA), or a Precision Spectra with octopolar leads (Boston Scientific, Valencia, CA, USA). Postoperatively, the patients were evaluated on a regular basis for approximately two months and intermittently thereafter.

Based on chart reviews and clinical evaluations the following pre-implant clinical scales were assessed—headache frequency (HA

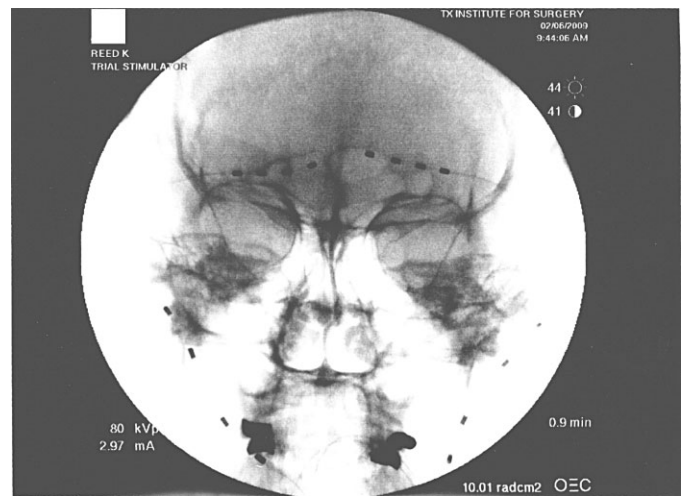


Figure 1. Radiograph demonstrating positions of occipital and supraorbital quadripolar neurostimulator leads.

days/month) and severity (VAS), frequency of hemiplegia (hemiplegic episodes/month), headache medication usage (number of different HA medications/day), and functional impairment (Migraine Disability Assessment [MIDAS] score). The self-administered MIDAS score is the most frequently used disability instrument in migraine research, and its reliability and validity have been extensively documented (39–41). At the conclusion of the study the patients were interviewed by the authors, either in person or by telephone, where in addition to the same pre-implant scales, the questionnaires included queries as to which programs were preferred (ones that provided solely an occipital paresthesia or those that provided a paresthesia over both the supraorbital and occipital regions); whether or not they would recommend the therapy to others; and their overall assessment of response.

CASE REPORTS

Case 1

In September 2006 a 49-year-old woman presented with daily incapacitating HAs. They began as a teenager and two years prior to presentation progressed to severe daily, unilateral throbbing HAs interspersed with fleeting, knifelike pains in her eye and jaw. Flashing lights and transient paresis of her left arm were a common prodrome; significant visual loss occurred 50% of the time; and photophobia and phonophobia were common. Her neurological examination was normal, and a full diagnostic evaluation, including magnetic resonance imaging (MRI) and CT scans, was unremarkable, whereby HM was diagnosed. Medical management, which included at least nine abortive and six prophylactic medications, ultimately failed, as the HAs became incapacitating to the point of full disability (MIDAS 255), and she was forced to resign her corporate executive position. In September 2006 bilateral occipital leads were placed with moderate but on the whole, inadequate relief. With the addition of supraorbital leads in October 2006, the HAs and all neurologic symptoms, including the hemiparesis, resolved. In March 2007 an occipital lead migrated and was repositioned. In May 2014 she reported being near HA free off all daily medications. Over the immediately preceding two months she experienced HAs requiring medication only three times, and none involved hemiplegia. She had returned to full time employment and was enjoying a normal, active lifestyle (MIDAS 7).

Case 2

A 50-year-old gentleman presented in August 2011 with debilitating HAs. They developed three years previously and progressed to daily, severe left-sided HAs, which were heralded by confusion and agitation and accompanied by a left hemiplegia two to three times weekly, occasional grand mal type seizures, and prolonged (up to two days) post-HA somnolence. A full diagnostic evaluation by experienced neurologists, including an MRI scan, revealed no other causes of head pain, and HM was diagnosed. An electroencephalogram (EEG) was positive and anti-seizure medications prescribed. Despite an extended course of medical management, which included at least seven preventatives, the problem progressed to the point of complete incapacity (MIDAS 270), as he had to sell his several businesses and became virtually bedbound. In October 2011, a combined ON-SONS was implanted, which resulted in near complete resolution of both the HA and the hemiplegia. In August 2013 a partial recurrence of symptoms necessitated repositioning the leads, whereupon the HAs again promptly resolved. At the follow-up evaluation in July 2014 he was near HA free while off of all daily medications. Indeed, over the preceding two months he experienced HM on only two occasions—both of which occurred when his IPG battery depleted on trips where he forgot to bring along his external charger. Otherwise, he was completely HA and hemiplegia free and had resumed a normal lifestyle, which included all family activities and the management of two companies (MIDAS 12).

Case 3

A 52-year-old woman with HM was referred in August 2013 for evaluation for an implanted PNS. The HAs began 15 years previously, and 3 years prior to presentation acutely progressed to incapacitating migraines. Associated findings that uniformly began at the onset of the HA included dysarthria, intermittent aphasia, and profound weakness of the left arm and leg, along with a distinct pins and needles sensation of these extremities and dense numbness limited to the hand and foot. Grand mal type seizures were occasionally associated. The HM lasted 20 min on average, and afterward she would be somnolent the rest of the day. An EEG, MRI, and MRA were normal. An extended course of medical management, which included at least nine abortives and ten preventative medications, as well as regional nerve blocks, ultimately failed. In 2013 she responded to a combined ON-SONS, and eight months post implant she was completely HA and hemiplegia free (0 HA days/month and 0 episodes hemiplegia/month) while off all headache medications, and had returned to a normal, fully active lifestyle, which included regular swimming, volunteer work, and taking vacations with her family (MIDAS 0).

Case 4

A 35-year-old woman developed HAs in her mid-twenties. In 2009 they progressed to severe, near daily, left-sided HAs. Right-sided weakness (two to three times a week), visual changes, and occasionally a foul odor heralded the onset, whereupon she became bed bound for the duration (commonly one to two hours), followed by prolonged somnolence for up to a day. In 2011 she came under the care of experienced neurology HA specialists, whereby a full evaluation, including MRI scan, CT angiogram, EEG and a lumbar puncture were unremarkable, and a diagnosis of HM was made. An extended course of medical management, which included at least 12 abortive and 7 preventative medications, ultimately proved unsuccessful. At presentation she was markedly impaired (MIDAS 270) due daily severe HM, despite taking ten different HA medications daily. In 2013 she responded to a combined ON-SONS and six months later reported very good improvement (30 → 8 HA days/mo) with resumption of a near normal lifestyle (MIDAS 3) on only one daily HA (topiramate). While feeling generally weak, she had experienced no hemiplegic episodes over the immediately preceding two months.

RESULTS

The results of the survey are summarized in Tables 3 and 4. Five patients satisfied the diagnostic criteria for HM, of whom all went on to a positive trial, followed by permanent implant. While all five reported an excellent response at their first postoperative office visit, one was lost to follow-up when she returned to her home in Puerto Rico. The remaining four completed the full study period. For these four patients, the median patient age was 50 years (range 41–60), and the median headache duration was 15 years (range 3–30). All suffered from frequent (avg 30 HA days/month), severe (avg VAS 9.5) migraines with profound motor auras (avg 7.5 hemiplegic episodes/mo), which resulted in complete incapacitation (avg MIDAS 249). Two had grand-mal type seizures (one with positive EEG findings and one negative), and three reported prolonged post-headache somnolence (up to one to two days). Family histories were all negative for HM. Preimplant, the average numbers of failed migraine abortive and preventative medications were 8 (range 3–12) and 7 (range 5–8) respectively, and at presentation the average number of different headache medications being taken daily was 6 (range 4–10).

At the final evaluation, the remaining four participants had been with their systems for an average of 35 months (range 6 to 92) and reported an average 92% improvement in HA frequency (30 to 2.5 HA days/month); a 44% improvement in intensity (VAS 9.5 to 5.3);

Table 3. Patient Characteristics Prior to Implant.

Pt	Gen	Age	HA duration (yrs)	Preventatives (no)	HA sev (VAS)	HA freq (HA day/mo)	Neuro symptoms
1	F	49	>30	5	10	30	Hem, FL, Sc, LOC
2	M	50	3	7	10	30	Hem, Dys, Ap, PN, Nm, Sz, PS, LOC, PCn
3	F	52	15	6	8	30	Hem, FD, Dys, PN, FL, Sz, PS, PvR
4	F	35	10	8	10	30	Hem, FD, Dys, UBv, FO, PS

All visual and tactile sensory symptoms were unilateral and began at onset of HA or preceded the HA by less than 1 hour. All had symptoms ipsilateral to HA, except Pt 4, who had a left sided HA but right hemiplegia and other neuro symptoms. Preventatives—number of preventative medications tried and failed over pre-implant. Hem, hemiplegia; FD, facial droop; AP, aphasia; Dys, dysarthria; UBv, unilateral blurred vision; FL, flickering lights; PN, pins & needles; Nm, numbness; FO, foul odor; Sz, seizures; PS, prolonged post HA somnolence; LOC, loss of consciousness; PCn, prodrome confusion; PvR, prodrome vertigo.

Table 4. Clinical Outcome Scales.

Pt	HA day/mo			VAS			Hemiplegia/mo			MIDAS			No daily medications		
	Pre	Post	% Imp	Pre	Post	% Imp	Pre	Post	% Imp	Pre	Post	% Imp	Pre	Post	% Imp
1	30	1		10	8		4	0		270	5		4	0	
2	30	1		10	5		10	1		270	2		4	0	
3	30	0		8	0		8	0		270	5		10	0	
4	30	8		10	8		8	0		250	10		7	1	
Avg	30	2.5	92%	9.5	5.3	44%	7.5	0.25	96%	249	6	98%	6	0.25	96%

Hemiplegia/Mo—number of migraine-associated hemiplegic episodes/mo.

The first 2 patients received St. Jude Eon systems with quadripolar leads. The last 2 received Boston Scientific Precision Spectra systems with octopolar leads. Our impression was that both systems produced equivalent therapeutic results.

and near complete resolution of their motor auras (0–1 hemiplegic episode/mo) with resultant commensurate functional improvement (>98% improvement in MIDAS). Three no longer required any routine daily headache medications, and the other was down to only 1 daily med. They all used their stimulator continuously and employed only combined ON-SONS stimulation programs, as ONS alone was inadequate. Each was pleased with the results and would recommend the procedure. The two patients with documented grand mal type seizures reported no further seizures following their PNS implants.

The first two patients received St. Jude Eon systems with quadripolar lead, and the last three received Boston Scientific Precision Spectra systems with octopolar leads. Our impression was that both systems produced equivalent therapeutic results.

Adverse events included lead migrations in the first two patients, noting resumption of a full therapeutic response upon repositioning of the leads.

DISCUSSION

Hemiplegic migraine remains a burden to the patient and society, as it is commonly resistant to medical management, which noting some debate over the use of triptans, otherwise follows the general approach as to other migraine types (2). As the motor auras are often the most debilitating aspect of the illness, their management has received particular attention; however, given the rarity of HM (prevalence 0.005%), the reports are anecdotal and include four case series involving treatment with either intranasal ketamine, verapamil, or a combination of lamotrigine and sodium valproate (2,42–45). The lamotrigine/valproate series reported a decrease in the frequency of hemiplegic episodes in a family of three patients, including one who went from 12 hemiplegic episodes/mo to complete resolution (0 hemiplegic episodes/mo) (42).

Recently, PNS has been offered as a potential treatment, and since 2006 there have been two case reports of motor auras responding to combined neurostimulation (31,32). In our series all four patients, pre-implant were suffering from frequent hemiplegic episodes (avg 7.5 hemiplegic episodes/mo). Post-implant all described virtual resolution of the episodes at their first post-permanent office visit, and this response continued. At their final evaluations, three of the four patients were completely hemiplegia free over the immediately preceding two months and the other reported only two episodes over the same period (avg 0.25 hemiplegic episodes/month). But, even in that case the episodes occurred only when he twice left town without his recharger, and the battery depleted. Viewed differently, over the two months immediately preceding their last

evaluation, all four patients were completely hemiplegia free so long as their implanted systems were functioning and on.

In addition to its clinical importance, any responsiveness of motor auras to PNS would suggest a potential mechanistic role for the cerebral cortex in PNS therapeutic action. This thesis should be considered within the context of our current understanding of the functional neuroanatomy related to potential mechanisms of PNS action, as well as migraine pathogenesis. With respect to the PNS mechanisms, interest has largely centered on two regions—the trigemino-cervical complex (TCC) and higher CNS centers. The caudal trigeminal nucleus and portions of the upper three cervical dorsal horns form the TCC. Nociceptive afferents from both the trigeminal nerve and the occipital nerves partially converge on the same second order neurons in the TCC and thus to a final common pathway to higher centers for cephalic nociception and modulation (46–49). These findings were originally intended as evidence for the TCC being the anatomic substrate underlying the well-accepted clinical phenomena of headache pain referral; for example, the common clinical observation of pain initially localized over the occiput, e.g., occipital neuralgia, yet over time spreads to the frontal regions (48,49). In 2003 however Popeney and Aló assigned potential mechanistic value to the TCC as regards PNS, when they suggested that TCC convergence might help explain why a paresthesia perceived over the C2-3 distribution may be mechanistically related to pain relief perceived over the distant trigeminal network (25).

More recent evidence, however, suggests than any putative mechanistic role for the TCC be reconsidered. First, Bartsch and Goadsby's work, which is often cited as foundational for a TCC site of PNS action, actually found only nociceptive specific neurons in the TCC (corresponding to A_d and C fiber input) (47–49). They specifically found no low threshold mechanoreceptors that would correlate to fibers responsible for vibratory sensation (A_β afferents) (49). Now, while it is generally accepted that cervical A_β afferents do synapse in various dorsal lamina of the cervical cord, we can find no direct empiric evidence for their convergence with trigeminal nociceptive afferents. In other words, while there is empiric evidence for trigeminal nociceptive and occipital nociceptive fiber convergence, there is none for trigeminal nociceptive and occipital non-nociceptive (vibratory sensation) convergence. This is not to rule out the possibility of such convergence; rather, it is to indicate the want of direct evidence.

Further, TCC convergence cannot explain the reports documenting a therapeutic response to trigeminal stimulation alone for pain perceived over a trigeminal region, e.g., SONS for supraorbital pain (28–30,36,50–57). The reason for this is that while trigeminal nociceptive afferents do synapse in the caudal trigeminal nucleus, the

trigeminal A_β fibers do not; rather, they synapse in the distinct principal trigeminal nucleus (58). Thus, a TCC convergence mechanism is problematic, as the fibers simply do not synapse in the same TCC nuclei.

Additionally, recent clinical findings also challenge a role for the TCC. Magis found increased nociceptive-specific blink reflexes in a study on ONS and cluster headaches as clinical evidence against a TCC role in PNS therapeutic action (59). Therefore, when considering the available experimental findings, we suggest that the mechanistic role for the TCC as currently formulated be reconsidered.

On the other hand, there is mounting evidence supporting a mechanistic role for higher CNS centers. In 2003 Matharu presented positron emission tomography (PET) scan evidence for such a role for some of these centers, including the cuneus, pulvinar, and anterior cingulate cortex (27). Others have since reported similar or consistent PET and functional MRI findings (59,60). Notably, however, none have posited a role for the somatosensory cortex, which is interesting as it is the one anatomic locus that is accepted as a site of nociceptive and non-nociceptive convergence. As an illustrative example, a patient with occipital neuralgia treated with an ONS experiences both pain and ONS-induced vibratory sensation over the same region of the occiput, which indicates that the corresponding occipital region of the sensory homunculus is involved in both sensations; that is, both occipital nociceptive and non-nociceptive afferents (vibratory sense) converge on the same region of the cortex.

With respect to migraine pathogenesis, it is now understood that the cortex plays a central role, as it is the locus for cortical spreading depression (CSD), which is generally accepted as the physiologic substrate to the clinical auras (visual, motor, etc.) that precede the actual headache (61). CSD is a wave of cortical cellular depolarization followed by prolonged quiescence, which typically begins at the visual cortex and then propagates rostrally over the sensorimotor cortical areas. Animal studies have demonstrated CSD activation of meningeal nociceptors and then central trigeminovascular neurons in the spinal trigeminal nucleus, which is one of the presumed mechanistic pathways related to migraine (61–63). The cortex is therefore central to the genesis of both the pain and hemiplegia due HM.

Could PNS-related stimulation of the cortex in some fashion effectively block the spreading depression wave front? There is indeed some early experimental evidence for this, as in 2010 Kovacs presented functional MRI findings in a patient treated with ONS that demonstrated depression of the motor (M1), sensory (S1 & S2), and visual (V1) cortical areas, which are exactly the same cortical regions involved with CSD (60).

Thus, the currently accepted model for CSD indicates that the cortex is functionally integral to the generation of both the pain and the motor auras of HM. As CSD is viewed causally as the immediate precursor to the motor aura, then any therapy that impacts the motor aura would suggest that the cortex be included as possibly mechanistically significant. In that regard, our findings of dramatic responses of the motor auras in all of these patients are consistent with the CSD model. As the evidence is indeed early, these suggestions stand as speculations, yet ones that can be tested by appropriate controlled studies, likely involving neuroimaging techniques.

A final aspect of our study that deserves attention is that of paresthesia concordancy; in this case the application of combined ON-SONS to holoccephalic pain due HM, a therapeutic approach that relates to the potential relationship between paresthesia concordancy and clinical outcome. Preceding this report, five others have described similar positive results with concordant, combined

PNS (three on ON-SONS; two on ON-Auriculotemporal Stimulation) (31–33,35,36). Support for this approach is provided by direct comparisons of the concordant and non-concordant paresthesia groupings of extant outcome studies, which are summarized in Tables 1 and 2 (updated tables from an earlier report of ours) (7). Taken together, the reports on ONS for CM (non-concordant paresthesia) average to a 46% response rate, while those on ON-SONS therapy (concordant paresthesia) to 81%. The difference is highlighted when the results of the benchmark Boston Scientific, St. Jude, and Medtronic controlled studies on non-concordant ONS for CM are scrutinized, as they all actually found limited or no response. The Boston Scientific team found no significant therapeutic response, and Medtronic's reported 39% response rate was based only on a 30% improvement in the VAS as the definition of responder vs. the historical standard of >50% improvement (18,21). The St. Jude study failed to demonstrate significant improvement in its primary endpoint (VAS) but did find a 48% response rate applying the historical 50% standard (19,20). This difference in response rates supports an approach for a concordant paresthesia, and evidence adduced in this report is consistent with that database, as all of our patients were treated with concordant, combined ON-SONS, noting further that they preferred programs that provided both occipital and supraorbital stimulation against those that provided occipital stimulation alone.

Limitations of our study include the small sample size, the lack of a diary, lack of genetic testing, and an open-label, non-randomized structure. While a placebo effect cannot be completely excluded, given the uniform dramatic responses across all patients and for the duration of their implants, we feel that there is likely minimal placebo effect.

CONCLUSIONS

These case reports offer preliminary evidence suggesting a potential for combined ON-SONS as a therapy for patients suffering from hemiplegic migraine. The evidence is sufficient to warrant prospective, controlled studies of sufficient power to appropriately evaluate the therapeutic potential.

Authorship Statements

Dr. Reed is the lead author and has participated in all aspects of clinical and manuscript preparation. Dr. Bulger has participated substantially in clinical development of the procedure, as well as with data acquisition, manuscript editing, and final manuscript acceptance. Dr. Will has participated substantially in clinical development of the procedure, as well as with data acquisition, manuscript editing, and final manuscript acceptance. Dr. Conidi has participated substantially with data acquisition, manuscript editing, and final manuscript acceptance.

How to Cite this Article:

Reed K.L., Will K.R., Conidi F., Bulger R. 2015. Concordant Occipital and Supraorbital Neurostimulation Therapy for Hemiplegic Migraine; Initial Experience; A Case Series. *Neuromodulation* 2015; 18: 297–304

REFERENCES

- Headache Classification Subcommittee of the International Headache S. The international classification of headache disorders: 2nd edition. *Cephalalgia* 2004;24 (Suppl. 1):9–160.
- Russell MB, Ducros A. Sporadic and familial hemiplegic migraine: pathophysiological mechanisms, clinical characteristics, diagnosis, and management. *Lancet Neurol* 2011;10:457–470.
- Thomsen LL, Eriksen MK, Roemer SF, Andersen I, Olesen J, Russell MB. A population-based study of familial hemiplegic migraine suggests revised diagnostic criteria. *Brain* 2002;125:1379–1391.
- Thomsen LL, Ostergaard E, Olesen J, Russell MB. Evidence for a separate type of migraine with aura Sporadic hemiplegic migraine. *Neurology* 2003;60:595–601.
- de Vries B, Frants RR, Ferrari MD, van den Maagdenberg AM. Molecular genetics of migraine. *Hum Genet* 2009;126:115–132.
- Moskowitz MA, Bolay H, Dalkara T. Deciphering migraine mechanisms: clues from familial hemiplegic migraine genotypes. *Ann Neurol* 2004;55:276–280.
- Reed KL. Peripheral neuromodulation and headaches: history, clinical approach, and considerations on underlying mechanisms. *Curr Pain Headache Rep* 2013;17:305–318.
- Krames E. Spinal cord stimulation: indications, mechanism of action, and efficacy. *Curr Rev Pain* 1999;3:419–426.
- Dodick DW. Occipital nerve stimulation for chronic cluster headache. *Adv Stud Med* 2003;3:5569–5571.
- Burns B, Watkins L, Goadsby PJ. Treatment of intractable chronic cluster headache by occipital nerve stimulation in 14 patients. *Neurology* 2009;72:341–345.
- Burns B, Watkins L, Goadsby PJ. Treatment of hemicrania continua by occipital nerve stimulation with a bion device: long-term follow-up of a crossover study. *Lancet Neurol* 2008;7:1001–1012.
- Magis D, Gerardy PY, Remacle JM, Schoenen J. Sustained effectiveness of occipital nerve stimulation in drug-resistant chronic cluster headache. *Headache* 2011;51:1191–1201.
- Trentman TL, Zimmerman RS, Seth N, Hentz JG, Dodick DW. Stimulation ranges, usage ranges, and paresthesia mapping during occipital nerve stimulation. *Neuromodulation* 2008;11:56–61.
- Schwedt TJ, Dodick DW, Hentz J, Trentman TL, Zimmerman RS. Occipital nerve stimulation for chronic headache—long-term safety and efficacy. *Cephalalgia* 2007;27:153–157.
- de Quintana-Schmidt C, Casajuana-Garreta E, Molet-Teixido J et al. Stimulation of the occipital nerve in the treatment of drug-resistant cluster headache. *Rev Neurol* 2010;51:19–26.
- Fontaine D, Sol JC, Raoul S et al. Treatment of refractory chronic cluster headache by chronic occipital nerve stimulation. *Cephalalgia* 2011;31:1101–1105.
- Mueller OM, Gaul C, Katsarava Z, Diener HC, Sure U, Gasser T. Occipital nerve stimulation for the treatment of chronic cluster headache—lessons learned from 18 months experience. *Cent Eur Neurosurg* 2011;72:84–89.
- Saper JR, Dodick DW, Silberstein SD et al. Occipital nerve stimulation for the treatment of intractable chronic migraine headache: ONSTIM feasibility study. *Cephalalgia* 2011;31:271–285.
- Dodick DW, Silberstein SD, Reed KL et al. Safety and efficacy of peripheral nerve stimulation of the occipital nerves for the management of chronic migraine: long-term results from a randomized, multicenter, double-blinded, controlled study. *Cephalalgia* 2014; pii: 0333102414543331; [e-pub ahead of print].
- Silberstein S, Dodick DW, Reed KL et al. Safety and efficacy of peripheral nerve stimulation of the occipital nerves for the management of chronic migraine: results from a randomized, multicenter, double-blinded, controlled study. *Cephalalgia* 2012;32:1165–1179.
- Lipton RB, Goadsby PJ, Cady RK et al. PRISM study: occipital nerve stimulation for treatment-refractory migraine (p abs). *Cephalalgia* 2009;29 (Suppl. 1):30.
- Paemeliere K, Van Buyten JP, Van Buynder M et al. Phenotype of patients responsive to occipital nerve stimulation for refractory head pain. *Cephalalgia* 2010;30:662–673.
- Brewer AC, Trentman TL, Ivancic MG et al. Long-term outcome in occipital nerve stimulation patients with medically intractable primary headache disorders. *Neuromodulation* 2012;16:557–564.
- Palmisani S, Al-Kaisy A, Arcioni R et al. A six year retrospective review of occipital nerve stimulation practice—controversies and challenges of an emerging technique for treating refractory headache syndromes. *J Headache Pain* 2013;14:1–10.
- Popeney CA, Aló KM. Peripheral neurostimulation for the treatment of chronic, disabling transformed migraine. *Headache* 2003;43:369–375.
- Oh MY, Ortega J, Bellotte JB, Whiting DM, Aló K. Peripheral nerve stimulation for the treatment of occipital neuralgia and transformed migraine using a c1-2-3 subcutaneous paddle style electrode: a technical report. *Neuromodulation* 2004;7:103–112.
- Matharu MS, Bartsch T, Ward N, Frackowiak RS, Weiner RL, Goadsby PJ. Central neuromodulation in chronic migraine patients with suboccipital stimulators: a PET study. *Brain* 2004;127:220–230.
- Narouze SN, Kapural L. Supraorbital nerve Electric stimulation for the treatment of Intractable chronic cluster headache: a case report. *Headache* 2007;47:1100–1102.
- Vaisman J, Markley H, Ordia J, Deer T. The treatment of medically intractable trigeminal autonomic cephalalgia with supraorbital/supratrochlear stimulation: a retrospective case series. *Neuromodulation* 2012;15:374–380.
- Simopoulos T, Bajwa Z, Lantz G, Lee S, Burstein R. Implanted auriculotemporal nerve stimulator for the treatment of refractory chronic migraine. *Headache* 2010;50:1064–1069.
- Reed KL, Black SB, Banta CJ 2nd, Will KR. Combined occipital and supraorbital neurostimulation for the treatment of chronic migraine headaches: initial experience. *Cephalalgia* 2010;30:260–271.
- Deshpande KK, Winger KL. Feasibility of combined epicranial temporal and occipital neurostimulation: treatment of a challenging case of headache. *Pain Physician* 2011;14:37–44.
- Hann S, Sharan A. Dual occipital and supraorbital nerve stimulation for chronic migraine: a single-center experience, review of literature, and surgical considerations. *Neurosurg Focus* 2013;35:E9.
- Mammis A, Gudesblatt M, Mogilner AY. Peripheral neurostimulation for the treatment of refractory cluster headache, long-term follow-up: case report. *Neuromodulation* 2011;14:432–435, discussion 435.
- Zach KJ, Trentman TL, Zimmerman RS, Dodick D. Refractory headaches treated with bilateral occipital and temporal region stimulation. *Medical Devices* 2014;7:55–59.
- Verrills P, Rose R, Mitchell B, Vivian D, Barnard A. Peripheral nerve field stimulation for chronic headache: 60 cases and long-term follow-up. *Neuromodulation* 2014;17:54–59.
- Thomsen LL, Kirchmann M, Bjornsson A et al. The genetic spectrum of a population-based sample of familial hemiplegic migraine. *Brain* 2007;130:346–356.
- Weiner RL, Reed KL. Peripheral neurostimulation for control of intractable occipital neuralgia. *Neuromodulation* 1999;2:217–221.
- Blumenfeld A, Varon S, Wilcox T et al. Disability, HRQoL and resource use among chronic and episodic migraineurs: results from the International Burden of Migraine Study (IBMS). *Cephalalgia* 2011;31:301–315.
- Lipton RB, Stewart WF, Diamond S, Diamond ML, Reed M. Prevalence and burden of migraine in the United States: data from the American Migraine Study II. *Headache* 2001;41:646–657.
- Stewart WF, Lipton RB, Whyte J. An international study to assess reliability of the Migraine Disability Assessment (MIDAS) score. *Neurology* 1999;53:988–994.
- Pelzer N, Stam AH, Carpay JA et al. Familial hemiplegic migraine treated by sodium valproate and lamotrigine. *Cephalalgia* 2014;34:708–711.
- Yu W, Horowitz SH. Treatment of sporadic hemiplegic migraine with calcium-channel blocker verapamil. *Neurology* 2003;60:120–121.
- Lamp C, Katsarava Z, Diener H, Limmroth V. Lamotrigine reduces migraine aura and migraine attacks in patients with migraine with aura. *J Neurol Neurosurg Psychiatry* 2005;76:1730–1732.
- Thomsen LL, Eriksen MK, Romer SF et al. An epidemiological survey of hemiplegic migraine. *Cephalalgia* 2002;22:361–375.
- Bartsch T, Goadsby PJ. Anatomy and physiology of pain referral patterns in primary and cervicogenic headache disorders. *Headache* 2005;2:42–48.
- Bartsch T, Goadsby PJ. The trigeminocephalic complex and migraine: current concepts and synthesis. *Curr Pain Headache Rep* 2003;7:371–376.
- Bartsch T, Goadsby PJ. Increased responses in trigeminocephalic nociceptive neurons to cervical input after stimulation of the dura mater. *Brain* 2003;126:1801–1813.
- Bartsch T, Goadsby PJ. Stimulation of the greater occipital nerve induces increased central excitability of dural afferent input. *Brain* 2002;125:1496–1509.
- Amin S, Buvanendran A, Park KS, Kroin JS, Moric M. Peripheral nerve stimulator for the treatment of supraorbital neuralgia: a retrospective case series. *Cephalalgia* 2008;28:355–359.
- Dunteman E. Peripheral nerve stimulation for unremitting ophthalmic postherpetic neuralgia. *Neuromodulation* 2002;5:279–290.
- Johnson MD, Burchiel KJ. Peripheral stimulation for treatment of trigeminal postherpetic neuralgia and trigeminal postherpetic pain: a pilot study. *Neurosurgery* 2004;55:135–142.
- Kouroukli I, Neofytos D, Panaretou V et al. Peripheral subcutaneous stimulation for the treatment of intractable postherpetic neuralgia: two case reports and literature review. *Pain Pract* 2009;9:225–229.
- Slavin KV, Colpan ME, Munawar N, Wess C, Nersesyan H. Trigeminal and occipital peripheral nerve stimulation for craniofacial pain: a single-institution experience and review of the literature. *Neurosurg Focus* 2006;21:E5.
- Stidd DA, Wuollet A, Bowden K et al. Peripheral nerve stimulation for trigeminal neuropathic pain. *Pain Physician* 2012;15:27–33.
- Upadhyay SP, Rana SP, Mishra S, Bhatnagar S. Successful treatment of an intractable postherpetic neuralgia (PHN) using peripheral nerve field stimulation (PNFS). *Am J Hosp Palliat Care* 2010;27:59–62.
- Yakovlev AE, Resch BE. Treatment of chronic intractable atypical facial pain using peripheral subcutaneous field stimulation. *Neuromodulation* 2010;13:137–140.
- Cheng HT. Spinal cord mechanisms of chronic pain and clinical implications. *Curr Pain Headache Rep* 2010;14:213–220.
- Magis D, Bruno MA, Fumal A et al. Central modulation in cluster headache patients treated with occipital nerve stimulation: an FDG-PET study. *BMC Neurol* 2011;11:25.
- Kovacs S, Peeters R, De Ridder D, Plazier M, Menovsky T, Sunaert S. Central effects of occipital nerve electrical stimulation studied by functional magnetic resonance imaging. *Neuromodulation* 2011;14:46–55, discussion 56–47.
- Zhang X, Levy D, Kainz V, Nosedá R, Jakubowski M, Burstein R. Activation of central trigeminovascular neurons by cortical spreading depression. *Ann Neurol* 2011;69:855–865.
- Dreier JP. The role of spreading depression, spreading depolarization and spreading ischemia in neurological disease. *Nat Med* 2011;17:439–447.
- Leo L, Gherardini L, Barone V et al. Increased susceptibility to cortical spreading depression in the mouse model of familial hemiplegic migraine type 2. *PLoS Genet* 2011;7:e1002129.

COMMENTS

I would like to thank the authors for their work and also for their effort to provide further understanding of the underlying migraine pathogenesis mechanisms and treatment with peripheral neurostimulation.

Over the past few years there is emerging evidence supporting the application of combined occipital and supraorbital peripheral neurostimulation in the treatment of intractable primary headaches. Although the authors as well as many others realize the therapeutic potential, for the most part it is provided via case studies or series with all the limitations of these types of manuscripts.

We hope that this case series will further energize and encourage investigators to provide more concrete evidence via prospective randomized multi-center studies.

Ioannis Skaribas, MD
Houston, TX, USA

The authors' approach to treatment of hemiplegic migraines with a combination of supraorbital and occipital nerve stimulation makes sense—as the matter of fact, one has to wonder if the large migraine studies have failed or underperformed because the stimulation was limited to occipital nerves only. However, if one follows the logic of true concordant stimulation, then it becomes unclear why both sides are stimulated even in patients with strictly unilateral symptoms.

With hemiplegic migraine being a relatively rare condition, it would be unlikely to see large-scale studies dealing with this specific indication; therefore, the authors' series becomes very important in individual patient selection. It would be interesting to see if similarly uniformly positive results have been observed by other high-volume PNS / migraine centers—and the only way to confirm the effectiveness of this approach (short of having a multi-year worldwide study that nobody would want to sponsor) would be to have a registry or some other depository of clinical cases that can be prospectively analyzed by independent reviewers.

It appears that just as with other ONS applications, patients with hemiplegic migraines suffer from electrode migrations (50% in this series). This would hopefully be resolved once dedicated ONS / PNS electrodes are available.

Konstantin Slavin, MD
Chicago, IL, USA
Jamil Rzaev, MD, PhD
Novosibirsk, Russia

The authors provide us with their experience of combined PNS for pain control in patients with hemiplegic migraine and a literature review on this subject. It would be useful to compare the results

of this study with other cases of combined neuromodulation in the author's practice to clarify the criteria for this type of neuromodulation technique as an up-front procedure to avoid a second implantation procedure.

Serge Rasskazoff, MD
Flint, MI, USA

This manuscript describes the use of peripheral nerve stimulation (PNS), specifically combined occipital nerve stimulation and supraorbital nerve stimulation, in patients suffering from hemiplegic migraines. This is a rare disorder in which patients experience migraine headaches associated with transient motor weakness. The purpose of the study was first, to assess the effectiveness of peripheral nerve stimulation on this disorder; second, to assess whether it was important for the neurostimulation paresthesia to actually overlap with the painful areas as experienced by the patients (paresthesia concordancy); and third, to assess whether the motor symptoms responded to neurostimulation, and whether this response provided insight on the pathophysiology of this disorder. Five patients were included in this study, and four patients were available for the entire study period. Combined occipital and supraorbital stimulation improved headache intensity (44%), headache frequency (92%), headache medication usage, motor auras, and overall function. All the patients were satisfied with the therapy. Occipital nerve stimulation alone was much less helpful than combined stimulation of both nerves. Lead migration occurred in two patients.

Hemiplegic migraines are fairly rare, and the size of the group in this study is small. But the evidence here suggests that combined supraorbital and occipital nerve stimulation is more effective than occipital nerve stimulation alone. This is probably the most useful conclusion from this study, from a practical standpoint. Physicians typically endeavor to achieve the best results using the simplest and most straightforward of the available treatment options. So there would be the understandable desire to implant the simplest neurostimulation system that works effectively. Those who perform cranial PNS are familiar with the potential complications that can occur with complex systems. This study reports a 40% revision rate (2/5 patients). Nevertheless, the patients seemed to benefit more from the more complex, combined supraorbital and occipital systems, and the patients were satisfied with their therapy. Moving forward, the treatment of hemiplegic migraine can include combined supraorbital and occipital nerve stimulation a treatment option, despite the increased risks of complications.

Christopher Winfree, MD
New York, NY, USA

Comments not included in the Early View version of this paper.