

# Aesthetic rehabilitation with multiple loop connectors

ASHISH KALRA, MAHESH E. GOWDA, KAMAL VERMA

## Abstract

Patients with a missing tooth along with diastema have limited treatment options to restore the edentulous space. The use of a conventional fixed partial denture (FPD) to replace the missing tooth may result in too wide anterior teeth leading to poor esthetics. The diastema resulting from the missing central incisors can be managed with implant-supported prosthesis or FPD with loop connectors. An old lady reported with chief complaints of missing upper anterior teeth due to trauma. Her past dental history revealed that she was having generalized spacing between her upper anterior teeth. Considering her esthetic requirement of maintaining the diastema between 12, 11, 22, and 21, the treatment option of 06 units porcelain fused to metal FPD from canine to canine with intermittent loop connectors between 21, 22, 11, 12 was planned. Connectors basically link different parts of FPDs. The modified FPD with loop connectors enhanced the natural appearance of the restoration, maintained the diastemas and the proper emergence profile, and preserve the remaining tooth structure of abutment teeth. This clinical report discussed a method for fabrication of a modified FPD with loop connectors to restore the wide span created by missing central incisors.

**Keywords:** Loop, diastema, connector, edentulous space, fixed partial denture, spacing

## Introduction

Patients with a missing tooth along with diastema have limited treatment options to restore the edentulous space. The use of a conventional fixed partial denture (FPD) to replace the missing tooth may result in too wide anterior teeth, an over-contoured emergence profile, which in turn causes poor esthetics. The diastema resulting from the missing central incisors can be managed with implant-supported prosthesis or FPD with loop connectors.<sup>[1-3]</sup> However, severe diastema and multiple missing teeth with long span may create esthetic problems. Maximum esthetic results may be obtained if the natural anatomic forms of teeth are protected and the diastema are maintained with minimal over-contouring of the adjacent teeth.<sup>[4]</sup> Implant-supported prostheses may be used in the oral rehabilitation of partially edentulous patients but may be expensive and time consuming for patients with requirements of many favorable local and medical factors for

successful treatment option.<sup>[5,6]</sup> This clinical report describes a technique to fabricate a 06 unit FPD with a modified palatal loop connector to provide maximum esthetic and functional correction for a patient with diastema between lateral and central incisor and missing central incisors.

## Case Report


A 35-year-old lady reported with chief complaints of missing upper anterior teeth due to trauma. The maxillary laterals incisors and canines on both sides had endodontic treatment post trauma but had good periodontal support. Her past dental history revealed that she was having generalized spacing between her upper anterior teeth and her medical history was non-contributory. Clinical and radiological examination revealed the endodontically treated 12, 13, 22, 23, missing 11, 2, less amount of bone available in upper anterior region and traumatic bite because of supra eruption of lower anterior teeth [Figures 1 and 2]. The treatment options included an implant-supported prosthesis, FPD with loop connectors, resin bonded FPD. Considering her availability of bone and esthetic requirement of maintaining the diastema between 12, 11, 22, and 21, the treatment option of 06 units porcelain fused to metal FPD from canine to canine with intermittent loop connectors between 21, 22, 11, 12 was planned.

The following clinical and lab procedures were carried out for her oral rehabilitation:

Teeth preparation for porcelain fused to metal was done on 12, 13, 22 and 23. Maxillary anterior FPD with loop connectors may cause occlusal interferences because of limited interocclusal space. In this patient, enameloplasty of lower anterior teeth was done to regain the interocclusal space and to prevent the interferences. The shoulder

*Division of Prosthodontics, Army Dental Centre, R and R Delhi Cantt, New Delhi, India*

**Correspondence:** Dr. Ashish Kalra, PG Resident, Division of Prosthodontics, Army Dental Centre, R and R Delhi Cantt, New Delhi, India. E-mail: doc\_ashish47@rediffmail.com

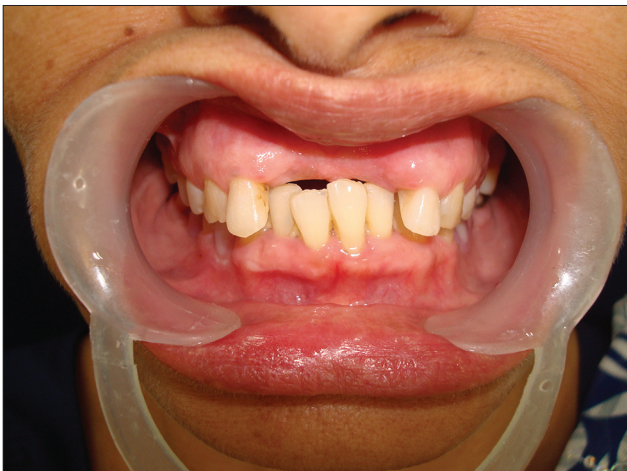Access this article online	
Quick Response Code:	Website: <a href="http://www.contemplindent.org">www.contemplindent.org</a>
	DOI: 10.4103/0976-237X.111632

finish lines of the preparation were kept equigingival in order to enhance the esthetics as it prevents the color of the metal from showing thorough translucent enamel.<sup>[7]</sup> Final impressions were made with two stage double mix putty light body rubber base impression material (Aquasil, Dentsply) [Figure 3] and poured in Type IV dental stone (Bego stone; BEGO, Bremen, Germany). Master casts were retrieved and die cutting was done. A quick-setting rigid poly vinylsiloxane interocclusal registration material was used to record the maxillomandibular relationship. The provisional FPD was fabricated and cemented using non-eugenol cement [Figure 4]. Casts were mounted on a semi-adjustable articulator (Hanau H2) using a face-bow transfer. A 0.5 mm thick wax sheet was placed on the edentulous ridge to create a space to allow convenient access for oral hygiene. Patterns of the modified FPD with loop connectors were fabricated by using blue inlay wax indirectly on the cast, adjusted for optimal occlusal contacts, and contoured to final shape, and form [Figure 5]. The patterns were invested with a phosphate-bonded investment (Bellawest, BEGO) and cast in a base metal alloy (Wiron 99; BEGO). After confirming the metal try in, the porcelain (Vita, Germany) was fired

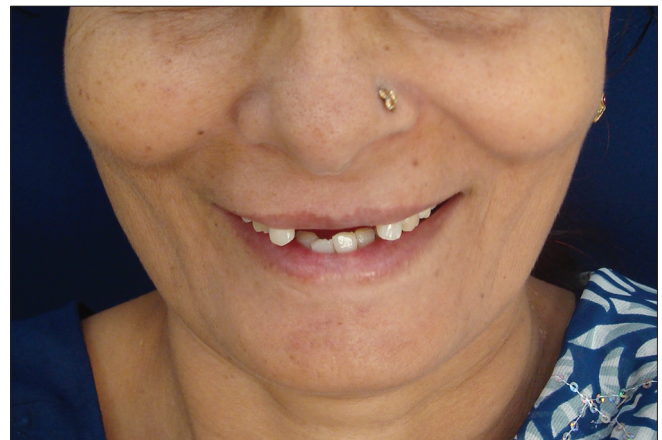according to the manufacturer's recommendations. Pontics were contoured with a fine-grained bur maintaining the diastemas and evaluated for esthetics and residual ridge adaptation [Figure 6]. The occlusion was evaluated and adjusted where necessary. After glazing and polishing, the intaglio surface of the retainers was sandblasted using airborne-particle abraded with 50- $\mu$ m aluminum oxide. Try in was done and interferences if any were removed. The surfaces of abutment teeth were steam cleaned and the restorations were cemented with Glass ionomer cement (GIC) Type I luting cement [Figures 7 and 8]. This prosthesis design may decrease access for plaque removal because palatal connectors are over-contoured by design. The patient was instructed to maintain the proper oral hygiene. Use of dental floss (Superfloss; Oral B, UK) and interdental brush (Interdental; Oral B) were recommended. The patient was evaluated after 1 week to assess the oral hygiene status.

## Discussion

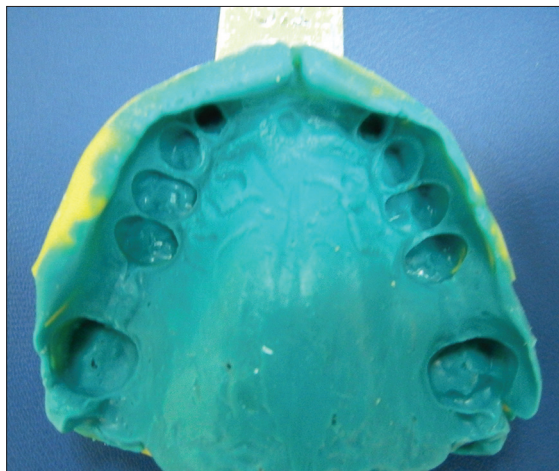Connectors basically link different parts of FPD (i.e., pontic and retainers). Thus constitute an important part of FPD.



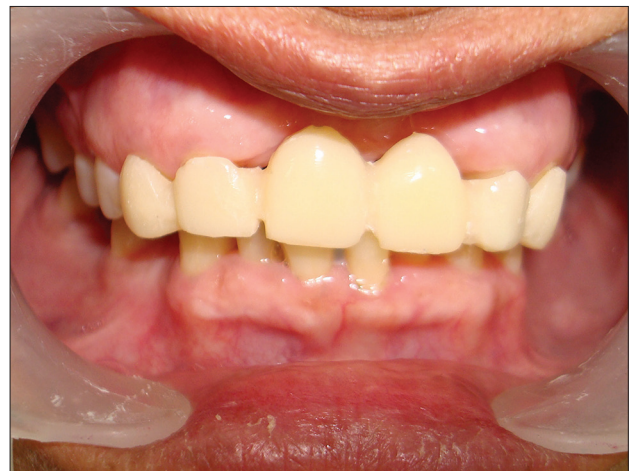**Figure 1:** Preoperative picture showing missing teeth



**Figure 2:** Extraoral picture showing missing teeth

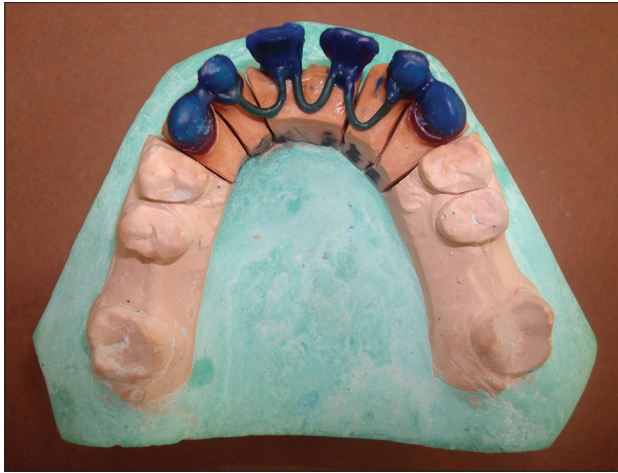

**Figure 3:** The final impression of the prepared teeth

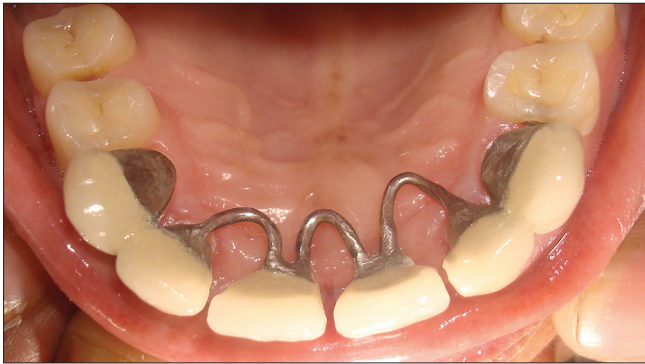

**Figure 4:** The cemented provisional crown





**Figure 5:** The wax up for 06 units bridge with loop connectors



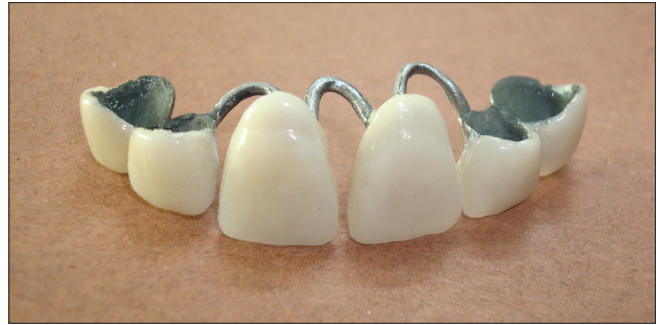**Figure 7:** The FPD cemented in mouth

Their designing determines the health of periodontal ligament under FPD. They may be either rigid or non-rigid. The presence of the missing central incisors with a wide span is a difficult esthetic problem to resolve with conventional FPDs. The modified FPD with loop connectors enhance the natural appearance of the restoration, maintain the diastemas and the proper emergence profile, and preserve the remaining tooth structure of abutment teeth. However, this type of prosthesis requires additional laboratory procedures. In addition, the prosthesis design may cause difficulty in maintenance and may affect in phonetics especially linguopalatal sounds. However keeping the connectors round and small in size will not affect the phonetics.

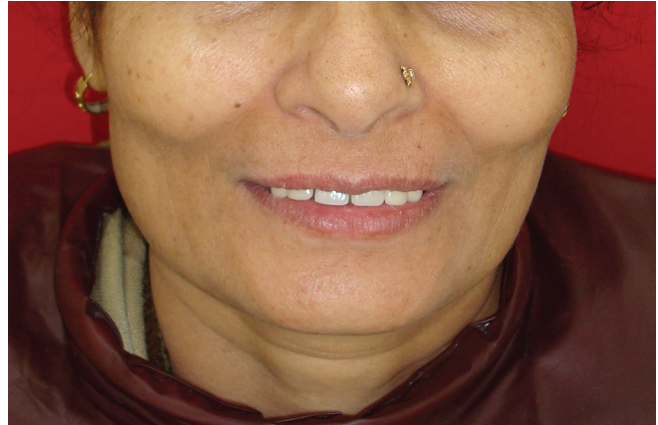Photoelastic analysis has revealed that within the connector, the highest stress was found at the gingival region of the connector and the lowest in the middle of the connector.<sup>[8,9]</sup> Also, connector geometry affects the strength of ceramic materials.<sup>[10,11]</sup> Therefore, smoother, less angled and more round connectors should be kept for lower stress levels.<sup>[12]</sup>

## Summary

This clinical report discussed a method for fabrication of a



**Figure 6:** The final prosthesis



**Figure 8:** The FPD cemented in mouth

modified FPD with loop connectors to restore the wide span created by missing central incisors. The full coverage PFM crowns were fabricated for abutments to preserve them. This prosthesis resulted in an esthetic result and required minimal adjustments.

## References

1. Miller TE. Implications of congenitally missing teeth: Orthodontic and restorative procedures in the adult patient. *J Prosthet Dent* 1995;73:115-22.
2. Melsen B. Current controversies in orthodontics. Chicago: Quintessence; 1991. p. 254-6.
3. Moyers RE. Handbook of Orthodontics. 4<sup>th</sup> ed. St. Louis: Mosby; 1988. p. 348-60.
4. Bello A, Jarvis RH. A review of esthetic alternatives for the restoration of anterior teeth. *J Prosthet Dent* 1997;78:437-40.
5. Olson JW, Shernoff AF, Tarlow JL, Colwell JA, Scheetz JP, Bingham SF. Dental endosseous implant assessments in a type 2 diabetic population: A prospective study. *Int J Oral Maxillofac Implants* 2000;15:811-8.
6. August M, Chung K, Chang Y, Glowacki J. Influence of estrogen status on endosseous implant osseointegration. *J Oral Maxillofac Surg* 2001;59:1285-9.
7. Eshleman JR, Janus CE, Jones CR. Tooth preparation designs for resin-bonded fixed partial dentures related to enamel thickness. *J Prosthet Dent* 1988;60:18-22.
8. Kou W, Kou S, Liu H, Sjögren G. Numerical modeling of the fracture process in a three-unit all-ceramic fixed partial denture. *Dent Mater* 2007;23:1042-9.
9. Oh W, Götzen N, Anusavice KJ. Influence of connector design on fracture probability of ceramic fixed-partial dentures. *J Dent Res*

- 2002;81:623-7.
10. Kamposiora P, Papavasiliou G, Bayne SC, Felton DA. Stress concentration in all-ceramic posterior fixed partial dentures. *Quintessence Int* 1996;27:701-6.
  11. Fischer H, Weber M, Marx R. Lifetime prediction of all-ceramic bridges by computational methods. *J Dent Res* 2003;82:238-42.
  12. Plengsombut K, Brewer JD, Monaco EA Jr, Davis EL. Effect of two connector designs on the fracture resistance of all-ceramic

core materials for fixed dental prostheses. *J Prosthet Dent* 2009;101:166-73.

**How to cite this article:** Kalra A, Gowda ME, Verma K. Aesthetic rehabilitation with multiple loop connectors. *Contemp Clin Dent* 2013;4:112-5.

**Source of Support:** Nil. **Conflict of Interest:** None declared.

#### Announcement

##### iPhone App



Download  
**iPhone, iPad  
application**

FREE

A free application to browse and search the journal's content is now available for iPhone/iPad. The application provides "Table of Contents" of the latest issues, which are stored on the device for future offline browsing. Internet connection is required to access the back issues and search facility. The application is Compatible with iPhone, iPod touch, and iPad and Requires iOS 3.1 or later. The application can be downloaded from <http://itunes.apple.com/us/app/medknow-journals/id458064375?ls=1&mt=8>. For suggestions and comments do write back to us.