

# Total laparoscopic duodenum-preserving pancreatic head resection for solid pseudopapillary neoplasm of pancreas

## A case report

Bin Liang, MD, Yuanyuan Chen, MD, Mengyang Li, MD, Xiaofeng Dong, MD, Siyang Yao, MD, Tianqi Liu, MD, PhD\*

### Abstract

**Rationale:** There is controversy regarding the optimal surgical approach for pancreatic lesions in the head of the pancreas. Duodenum-preserving pancreatic head resection compared with pancreaticoduodenectomy is technically more challenging, but preserves more functional pancreatic tissue.

**Patient concerns:** A 25-year-old woman was admitted to our department on May 10, 2017. Computed tomographic's saw a 2.0 × 2.1-cm lesion located in the head of pancreas and its diagnosis was nonfunctional neuroendocrine tumors? The magnetic resonance cholangiopancreatography scan demonstrated a solitary 1.6 × 1.7-cm lesion located in the head of pancreas, and its diagnosis was tumor. The patient's condition was good and symptomless, without any disease history. Physical examination and routine blood investigations were normal. All pancreatic malignant tumor biological markers were negative.

**Diagnoses:** Solid pseudopapillary neoplasm of pancreas.

**Interventions:** Total laparoscopic head pancreatectomy with Roux-Y pancreaticojejunostomy was performed.

**Outcomes:** The recovery was smooth after surgery. At the end of 20 months follow-up, she was well and showed no signs of recurrence.

**Lessons:** The anatomy of the operation is clearer and easier than open surgery because of the magnification effect of laparoscopy. Total laparoscopic head pancreatectomy is safe, effective, and feasible for solid pseudopapillary neoplasm of pancreas, and it should be equally applicable to some other pancreatic cystic neoplasms and neuro-endocrine tumors.

**Abbreviations:** PCN = pancreatic cystic neoplasms, PNETs = pancreatic neuro-endocrine tumors, POPF = postoperative pancreatic fistulas, SPN = solid pseudopapillary neoplasm.

**Keywords:** laparoscopic pancreatectomy, pancreas, solid pseudopapillary neoplasm

## 1. Introduction

Organ-sparing pancreatic resection is important in prophylactic surgery for cystic neoplasms. There is controversy regarding the

Editor: N/A.

Written informed consent was obtained from the patient for publication of this case report and accompanying images. Ethical approval was given by the Medical Ethics Committee of the People's Hospital Of Guangxi Zhuang Autonomous Region with the following reference number: Science-2017-05.

The authors have no conflicts of interest to disclose.

Supplemental Digital Content is available for this article.

Department of Hepatobiliary Surgery, the People's Hospital of Guangxi Zhuang Autonomous Region, Nanning, China.

\* Correspondence: Tianqi Liu, Department of Hepatobiliary Surgery, the People's Hospital of Guangxi Zhuang Autonomous Region, 6 Taoyuan Road, Nanning, Guangxi Zhuang Autonomous Region, 530021, China (e-mail: gxjrq@163.com).

Copyright © 2019 the Author(s). Published by Wolters Kluwer Health, Inc. This is an open access article distributed under the terms of the Creative Commons Attribution-Non Commercial License 4.0 (CCBY-NC), where it is permissible to download, share, remix, transform, and buildup the work provided it is properly cited. The work cannot be used commercially without permission from the journal.

Medicine (2019) 98:21(e15823)

Received: 28 December 2018 / Received in final form: 14 April 2019 / Accepted: 29 April 2019

<http://dx.doi.org/10.1097/MD.00000000000015823>

optimal surgical approach for pancreatic lesions in the head of the pancreas.<sup>[1]</sup> Duodenum-preserving pancreatic head resection compared with pancreaticoduodenectomy is technically more challenging, but preserves more functional pancreatic tissue. Because of the prophylactic nature of the surgery and long survival of patients with benign and borderline malignant lesions, surgeons need to stratify greater importance to surgical morbidity and sparing pancreatic parenchyma.<sup>[2]</sup> In the present case, we would like to show a total laparoscopic head pancreatectomy for solid pseudopapillary neoplasm (SPN) of pancreas.

## 2. Case report

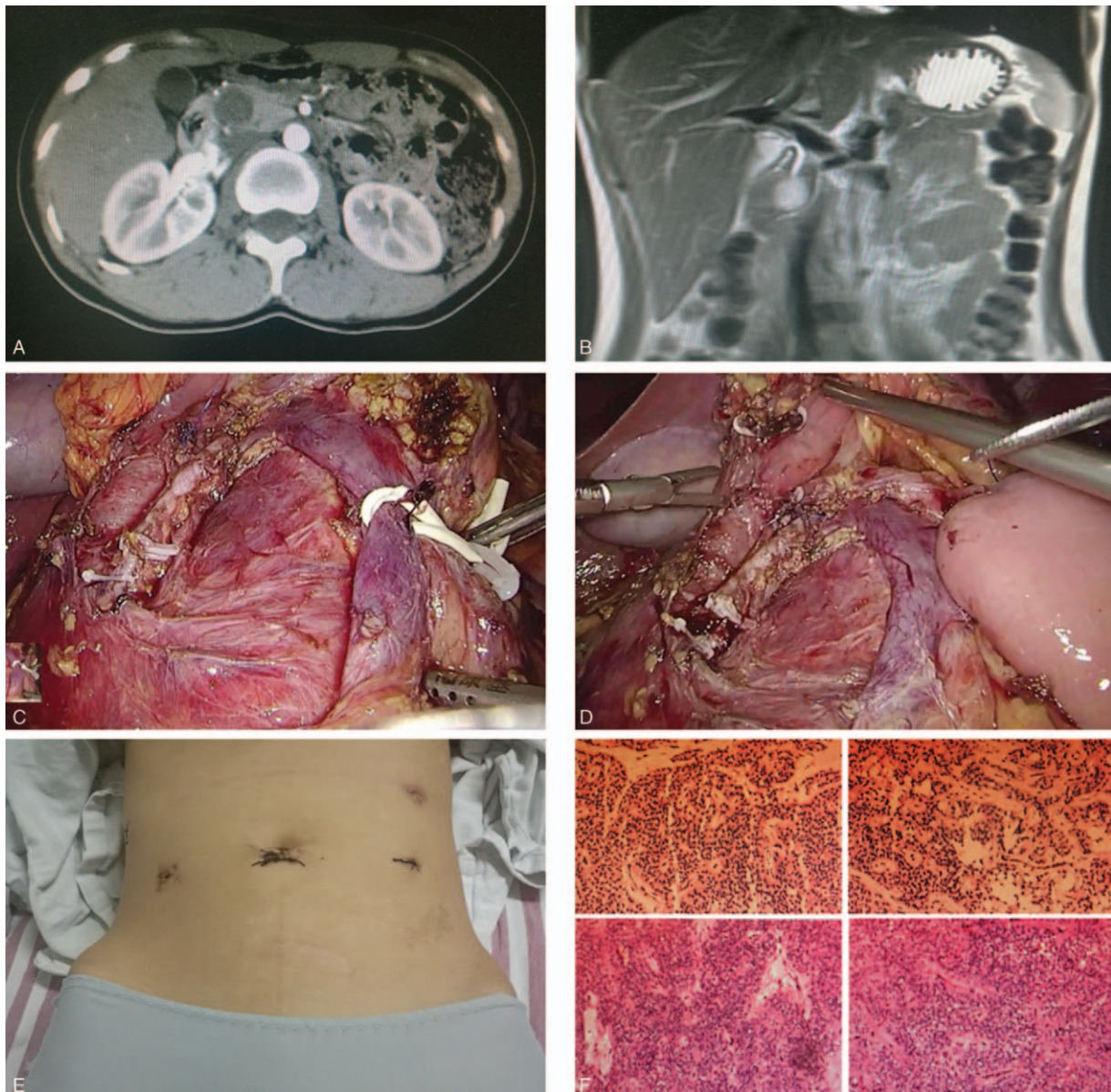
On May 10, 2017, a 25-year-old woman came to our hospital for a further treatment of 1 tumor of pancreatic head found by ultrasonic inspection in 1 other hospital. On June 13, 2017, she was admitted to our department. Our computed tomographic's saw a 2.0 × 2.1-cm lesion located in the head of pancreas and its diagnosis was nonfunctional neuroendocrine tumors. The magnetic resonance cholangiopancreatography scan demonstrated a solitary 1.6 × 1.7-cm lesion located in the head of pancreas, and its diagnosis was tumor. The patient's condition was good and symptomless, without any disease history. Physical examination and routine blood investigations were normal. All pancreatic malignant tumor markers were negative. On July 2,

2017, a total laparoscopic duodenum and common bile duct-preserving pancreatic head resection were performed (Fig. 1; with operation video in the supplementary file, <http://links.lww.com/MD/D6>). The patient was placed in a supine position. After successful pneumoperitoneum with CO<sub>2</sub> gas insufflated until the abdominal cavity pressure reached 10 to 12 mm Hg and 4 trocars were placed, a high-definition laparoscopy was inserted. The proposed line of parenchymal incision was circumferentially scored with a sewing a stitch, maintaining an approximate 10 mm margin away from the tumor. The tumor was sharply excised by ultrasonic knife. The diagnosis of intraoperative frozen pathology was SPN. Roux-Y pancreaticojejunostomy was done, and a drain was left nearby pancreaticointestinal anastomosis. The blood loss was 150 mL. The patient's recovery was smooth after surgery. Postoperative pathology confirmed the diagnosis of SPN

with a negative margin. At the end of 20 months follow-up, she was well and showed no signs of recurrence.

### 3. Discussion

We treat the pancreatic cystic neoplasms (PCN) according to our consensus guidelines.<sup>[3-6]</sup> Parenchyma-sparing techniques might be an option, but prospective multicenter studies need to follow.<sup>[7]</sup> In selected patients, parenchyma-sparing pancreatotomy for presumed noninvasive intraductal papillary and mucinous neoplasms in experienced hands is highly feasible and avoids inappropriate standard resections. Early morbidity is greater than that after standard resections but counterbalanced by preservation of pancreatic endocrine/exocrine functions and a low rate of reoperation for tumor recurrence.<sup>[2]</sup> Pancreatic



**Figure 1.** Computed tomographic scans showing the lesion (A). Magnetic resonance cholangiopancreatography showing the lesion (B). Laparoscopic head pancreatotomy with Roux-Y Pancreaticojejunostomy (C, D, E). Solid pseudopapillary neoplasm of pancreas was confirmed by pathological examination with a negative margin (F).

enucleation and head pancreatectomy are feasible techniques for selected patients, but the indications are limited. Morbidity after these resections is high with the major cause being the development of postoperative pancreatic fistulas (POPF).<sup>[8]</sup> A systematic review showed that total pancreatic head resection conserving duodenum and common bile duct has higher procedure-related biliary and duodenal complications compared to total head resection including the periampullary segment of duodenum and the intrapancreatic common bile duct.<sup>[9]</sup> Surgeons, who are requested to treat patients with benign tumors, using standard oncological resections, face the challenge of sacrificing pancreatic and extra-pancreatic tissue. Tumor enucleation, pancreatic middle segment resection, and local duodenum-preserving pancreatic head resections are surgical procedures increasingly used as alternative treatment modalities compared to classical pancreatic resections. The use of local resection procedures for PCN and pancreatic neuro-endocrine tumors (PNETs) is associated with an improvement of procedure-related morbidity when compared to classical pancreatoduodenectomy. The procedure-related advantages are 90-day mortality below 1% and a low level of POPF B+C rates. Most importantly, the long-term benefits of the use of local surgical procedures are the preservation of the endocrine and exocrine pancreatic functions. The decision-making for PCN and PNETs should be guided by the low surgical risk and the preservation of pancreatic metabolic functions when undergoing a limited, local, tissue-sparing procedure.<sup>[10]</sup> Local resection combined with pancreaticojejunostomy is an option to avoid extensive resection of the pancreatic parenchyma but is still associated with a high incidence of pancreatic fistula which is comparable to that after enucleation.<sup>[11]</sup>

#### 4. Conclusion

The present case showed that the anatomy of the operation is clearer and easier than open surgery because of the magnification effect of laparoscopy. Total laparoscopic duodenum-preserving pancreatic head resection is safe, effective, feasible for SPN, and it should be equally applicable to some other PCN or PNETs. Further clinical investigation is eagerly awaited to confirm our conclusion.

#### Author contributions

**Conceptualization:** Tianqi Liu.

**Data curation:** Yuanyuan Chen, Mengyang Li, Xiaofeng Dong, Siyang Yao, Tianqi Liu.

**Formal analysis:** Bin Liang, Yuanyuan Chen, Mengyang Li, Xiaofeng Dong, Siyang Yao, Tianqi Liu.

**Investigation:** Yuanyuan Chen.

**Resources:** Tianqi Liu.

**Writing – original draft:** Bin Liang.

**Writing – review & editing:** Tianqi Liu.

#### References

- [1] Kang MJ, Jang JY, Kim SW. Surgical resection of pancreatic head cancer: What is the optimal extent of surgery? *Cancer Lett* 2016;382:259–65.
- [2] Sauvanet A, Gaujoux S, Blanc B, et al. Parenchyma-Sparing Pancreatectomy for Presumed Noninvasive Intraductal Papillary Mucinous Neoplasms of the Pancreas. *Ann Surg* 2014;260:364–71.
- [3] Vege SS, Ziring B, Jain R, et al. American Gastroenterological Association institute guideline on the diagnosis and management of asymptomatic neoplastic pancreatic cysts. *Gastroenterology* 2015;148:819–22.
- [4] Pancreatic Surgery Group of Surgery Branch of Chinese Medical association Guideline for the diagnosis and treatment of pancreatic cystic diseases (2015 edition). *Chin J Dig Surg* 2015;14:689–93.
- [5] European Study Group on Cystic Tumours of the Pancreas European evidence-based guidelines on pancreatic cystic neoplasms. *Gut* 2018;67:789–804.
- [6] Tanaka M, Fernandez-Del Castillo C, Kamisawa T, et al. Revisions of international consensus Fukuoka guidelines for the management of IPMN of the pancreas. *Pancreatol* 2017;17:738–53.
- [7] Honselmann KC, Krauss T, Geserick S, et al. Cystic lesions of the pancreas-is radical surgery really warranted? *Langenbecks Arch Surg* 2016;401:449–56.
- [8] Wolk S, Distler M, Kersting S, et al. Evaluation of central pancreatectomy and pancreatic enucleation as pancreatic resections—A comparison. *Int J Surg* 2015;22:118–24.
- [9] Beger HG, Mayer B, Rau BM. Parenchyma-Sparing, Limited Pancreatic Head Resection for Benign Tumors and Low-Risk Periampullary Cancer—a Systematic Review. *J Gastrointest Surg* 2016;20:206–17.
- [10] Beger HG. Benign tumors of the pancreas-radical surgery versus parenchyma-sparing local resection—the challenge facing surgeons. *J Gastrointest Surg* 2018;22:562–6.
- [11] Wroński M, Cebulski W, Krasnodębski IW, et al. Parenchyma-Sparing Pancreatic Resections: With or Without a Pancreaticojejunostomy? *Hepatogastroenterology* 2014;61:1113–7.