



Horner's syndrome following an epidural blood patch

Saowarat Snidvongs¹ • Seema Shah²

¹Pain Fellow and Specialist Registrar in Anaesthesia, Boyle's Department of Anaesthesia, St Bartholomew's Hospital, London EC1A 7BE, UK

²Specialist Registrar in Anaesthesia, Boyle's Department of Anaesthesia, St Bartholomew's Hospital, London EC1A 7BE, UK

Correspondence to: Saowarat Snidvongs. E-mail: saz@lookrai.demon.co.uk

DECLARATIONS

Competing interests

None declared

Funding

The article processing fee will be met by: Vivek Mehta, Pain and Anaesthesia Research Centre, St Bartholomew's Hospital, West Smithfield, London EC1A 7BE

Ethical approval

Written informed consent was obtained from the patient or next of kin

Guarantor

Saowarat Snidvongs

Contributorship

Both authors contributed equally to the preparation and approval of the final manuscript

Acknowledgments

None

We report a case of Horner's syndrome, which developed following a therapeutic blood patch for post-dural puncture headache.

Introduction

A young patient with post-dural puncture headache (PDPH) following inadvertent dural puncture with a Tuohy needle developed Horner's syndrome following a therapeutic blood patch at the thoracic level. Other causes for Horner's syndrome such as carotid artery dissection and brainstem lesion were excluded with magnetic resonance imaging.

Case presentation

A 30-year-old woman presented for an elective nephrectomy and consented to epidural analgesia for postoperative pain relief. She had a past medical history of duplex kidney and previous partial nephrectomy following recurrent urinary tract infections from pelviureteric junction obstruction. Epidural insertion at the mid-thoracic level prior to surgery resulted in inadvertent dural puncture with a Tuohy needle.

On the second postoperative day, she developed bilateral frontal headaches that worsened when sitting forward, tinnitus, nausea and vomiting. A diagnosis of PDPH was made and treatment initiated with caffeine, oral analgesia and increased fluid intake. Although the patient subsequently failed to respond to conservative management, she developed wound sepsis, which the microbiology team felt would preclude an epidural blood patch due to the risk of neuraxial infectious complications. Computer tomography

imaging revealed no space-occupying lesion in the brain, and a diagnosis of meningitis was excluded on the basis of a normal lumbar puncture. An autoimmune screen was negative.

The pain management team carried out a therapeutic epidural blood patch on the eighth postoperative day, after complete resolution of the sepsis. The patient was placed in the left lateral position and the epidural space located using a 16G Tuohy needle and loss of resistance to air technique. Correct placement of the needle in the epidural space was visually confirmed using C-arm fluoroscopy (Figure 1), prior to injection of twenty millilitres of sterile autologous blood.

The following morning the patient reported no further headaches, but stated that her right pupil was smaller than the left, and that her right eyelid was starting to droop. A neurologist reviewed her and made a diagnosis of Horner's syndrome (miosis, ptosis and enophthalmos). Magnetic resonance imaging of her neck and brain revealed no brainstem lesion or carotid artery dissection.

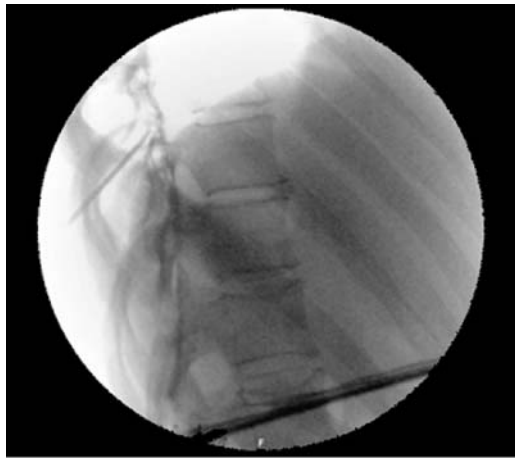Over the next two days her right pupil was starting to resume normal size and the patient was discharged home. During a telephone follow-up six weeks later, she reported that she had returned to work full-time and the headaches had not recurred.

Discussion

The diagnosis of PDPH is a clinical one, based on a typical history of a postural headache following dural puncture. The Headache Classification Committee of the International Headache Society defines PDPH as bilateral headaches that develop within seven days of after a lumbar

Reviewer
Geoffrey Knox

Figure 1
Fluoroscopic image showing radio-opaque contrast spread into the epidural space



puncture and disappears within fourteen days.¹ The headache worsens within fifteen minutes of resuming the upright position, and disappears or improves within thirty minutes of resuming the recumbent position. The exact pathophysiology of PDPH remains unclear, but is thought to be due to a persistent leak of cerebrospinal fluid (CSF) from the subarachnoid space as a result of the dural puncture, resulting in a fall in both CSF volume and pressure.² The reduced CSF volume may cause gravitational traction on pain-sensitive intracranial structures, resulting in the postural headaches, and may cause direct activation of adenosine receptors, which further stretch these structures in addition to causing cerebral vasodilatation.³ Approximately 1–2% of epidural blocks result in unintentional dural puncture, with headaches occurring in 30–70% of these cases.⁴

Following the inadvertent dural puncture, the patient was monitored for characteristic features of PDPH, and when this was diagnosed a number of treatment modalities were offered, including an epidural blood patch. A recent Cochrane review concluded that there were too few trials to support or refute the use of prophylactic blood patching, whereas a therapeutic epidural blood patch showed benefit over conservative treatment.⁵ One study examining the timing of blood patching concluded that the success rate

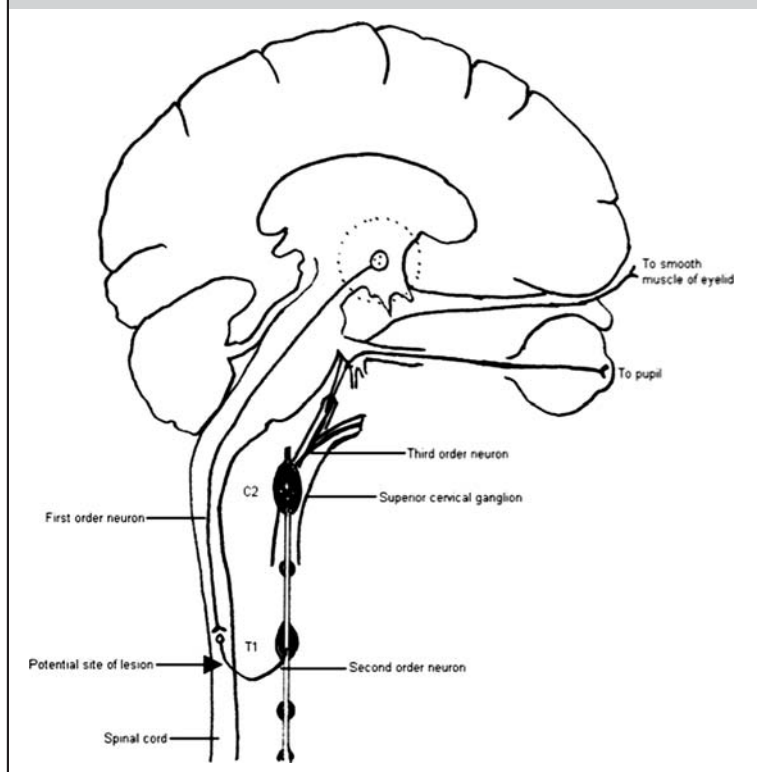
was lower if performed within the first twenty-four hours of the dural puncture, possibly due to a higher rate of CSF leakage interfering with blood clotting.⁶ As this patient had developed postoperative sepsis, the blood patch was postponed; an advisory committee has recommended that alternatives to neuraxial techniques should be considered in all patients at high risk of infectious complications.⁷

There are currently very few systematic reviews or meta-analyses to assess the evidence for the management of PDPH. Conservative, non-invasive management options include bed rest, hydration, prone positioning, the use of abdominal binders, and analgesics.⁸ No analgesic agent has been shown to be superior over the other in treating PDPH, although they do provide symptomatic relief. One randomized controlled trial has shown the benefits of oral caffeine versus placebo.⁹

Horner's syndrome, or oculosympathetic paresis, is a lesion along the sympathetic pathway supplying the head and neck; signs include a unilateral pupillary constriction, slight relative ptosis and enophthalmos, injected conjunctival vessels, and ipsilateral loss of sweating if the lesion is proximal to the superior cervical ganglion. It may be congenital or iatrogenic, or the result of pathology in the head, neck or surrounding structures. A MEDLINE literature search has revealed a number of published case reports of Horner's syndrome following epidural analgesia, with a 0.4–2.5% incidence in the labour population.¹⁰ More cases have been reported following thoracic than lumbar epidural analgesia, and with high sensory blockade. There may be a higher incidence following unintended subdural or paravertebral block. Horner's syndrome has also been reported following internal jugular vein cannulation, possibly due to excessive rotation of the head, direct blunt trauma to the cervical plexus, or local haematoma formation causing disruption of the sympathetic chain.

In this case report, fluoroscopic images prior to injection of blood into the epidural space demonstrated that two millilitres of radio-opaque contrast had spread to several spinal segments both superiorly and inferior. As twenty millilitres of autologous blood was subsequently injected, it is possible that there may have been inadvertent subdural or dural spread of blood through the previous puncture site, or high cephalad epidural spread with mass effect. The patient did not

Figure 2
The oculosympathetic pathway, showing the proposed site of the lesion causing Horner's syndrome



have signs of anhidrosis but presented with miosis, ptosis and enophthalmos; this could be caused by disruption of the oculosympathetic pathways where the second order neurons exit the spinal cord (C8/T1) on their way to the superior cervical ganglia, distal to the superficial cervical ganglion (Figure 2). It has been demonstrated in some patients that the preganglionic sympathetic outflow tract receives fibres from as low as T9.

Horner's syndrome may be diagnosed pharmacologically with cocaine, followed by hydroxyamphetamine to localize the lesion. If the oculosympathetic pathway is intact, topical cocaine into the eye will cause mydriasis via noradrenaline reuptake inhibition; this will not occur if a lesion is present. Topical hydroxyamphetamine causes release of endogenous noradrenaline from presynaptic vesicles, resulting in mydriasis of the lesion is

preganglionic (first or second order neuron), and no dilatation if the lesion is postganglionic (third order neuron).

There is no known treatment for Horner's syndrome caused by epidural blood patching. However, the signs and symptoms in the patient did begin to resolve within days, presumably as the blood in the epidural space was absorbed. Pharmacological testing was not required in this instance.

The case report was discussed at the local morbidity and mortality meeting. It was felt that a smaller gauge Tuohy needle should be used to reduce the risk of PDPH, and that the blood patch could have been attempted at a lower site (lumbar instead or thoracic) with a smaller volume of blood to reduce the risk of developing Horner's syndrome.

References

- 1 Headache Classification Subcommittee of the International Headache Society. The International Classification of Headache Disorders: 2nd edition. *Cephalalgia* 2004;24:9–160
- 2 Grant R, Condon B, Hart I, *et al*. Changes in intracranial CSF volume after lumbar and their relationship to post-LP headache. *J Neurol Neurosurg Psychiatry* 1991;54:440–2
- 3 Ahmed SV, Jayawarna C, Jude E. Post lumbar puncture headache: diagnosis and management. *Postgrad Med J* 2006;82:713–6
- 4 Okell RW, Sprigge JS. Unintentional dural puncture. A survey of recognition and management. *Anaesthesia* 1987;42:1110–3
- 5 Boonmak P, Boonmak S. Epidural blood patching for preventing and treating post-dural puncture headache. *Cochrane Database Syst Rev* 2001;20:CD001791
- 6 Berrettini WH, Simmons-Alling S, Nurnberger JI Jr. Epidural blood patch does not prevent headache after lumbar puncture. *Lancet* 1987;1:856–7
- 7 American Society of Anesthesiologists Task Force on infectious complications associated with neuraxial techniques. Practice advisory for the prevention, diagnosis, and management of infectious complications associated with neuraxial techniques: a report by the American Society of Anesthesiologists Task Force on infectious complications associated with neuraxial techniques. *Anesthesiology* 2010;112:530–45
- 8 Kotur PF. Evidence based management of post dural puncture headache. *Indian J Anaesth* 2006;50:307–8
- 9 Camann WR, Murray RS, Mushlin PS, *et al*. Effects of oral caffeine on postdural puncture headache. A double-blind, placebo-controlled trial. *Anesth Analg* 1990;70:181–4
- 10 Turnbull DK, Shepherd DB. Post-dural puncture headache: pathogenesis, prevention and treatment. *Br J Anaesth* 2003;91:718–29

© 2012 Royal Society of Medicine Press

This is an open-access article distributed under the terms of the Creative Commons Attribution License (<http://creativecommons.org/licenses/by-nc/2.0/>), which permits non-commercial use, distribution and reproduction in any medium, provided the original work is properly cited.