

# Preliminary Outcome of Individualized Abdominoperineal Excision for Locally Advanced Low Rectal Cancer

Yi Zheng, Jia-Gang Han, Zhen-Jun Wang, Zhi-Gang Gao, Guang-Hui Wei, Zhi-Wei Zhai, Bao-Cheng Zhao

Department of General Surgery, Beijing Chaoyang Hospital, Capital Medical University, Beijing 100020, China

## Abstract

**Background:** The introduction of individualized abdominoperineal excision (APE) may minimize operative trauma and reduce the rate of complications. The purpose of this study was to evaluate the safety and efficacy of individualized APE for low rectal cancer.

**Methods:** Fifty-six patients who underwent individualized APE from June 2011 to June 2015 were evaluated retrospectively in Beijing Chaoyang Hospital, Capital Medical University. The main outcome measures were circumferential resection margin (CRM) involvement, intraoperative perforation, postoperative complications, and local recurrence. Statistical analysis was performed using SPSS version 16.0.

**Results:** Fifty (89%) patients received preoperative chemoradiotherapy: 51 (91%) patients were treated with the sacrococcyx preserved; 27 (48%) patients with the levator ani muscle partially preserved bilaterally; 20 (36%) patients with the levator ani muscle partially preserved unilaterally and the muscle on the opposite side totally preserved; 7 (13%) patients with intact levator ani muscle and part of the ischioanal fat bilaterally dissected; and 2 (4%) patients with part of the ischioanal fat and intact levator ani muscle dissected unilaterally and the muscle on the opposite side partially preserved. The most common complications included sexual dysfunction (12%), perineal wound complications (13%), urinary retention (7%), and chronic perineal pain (5%). A positive CRM was demonstrated in 3 (5%) patients, and intraoperative perforations occurred in 2 (4%) patients. On multiple logistic regression analysis, longer operative time ( $P = 0.032$ ) and more intraoperative blood loss ( $P = 0.006$ ) were significantly associated with perineal procedure-related complications. The local recurrence was 4% at a median follow-up of 53 months (range: 30–74 months).

**Conclusion:** With preoperative chemoradiotherapy, individualized APE may be a relatively safe and feasible approach for low rectal cancer with acceptable oncological outcomes.

**Key words:** Abdominoperineal Excision; Complications; Individualized; Low Rectal Cancer; Recurrence

## INTRODUCTION

Extralevator abdominoperineal excision (ELAPE) has been shown to lead to fewer episodes of bowel perforation and fewer positive circumferential resection margins (CRMs) when compared with conventional abdominoperineal excision (APE) because it achieves a specimen of a more cylindrical shape.<sup>[1-6]</sup> Recently, the occurrence and implications of perineal symptoms following ELAPE have been gradually realized; they occur partly because of the wider excision and the presence of more tissue around low rectal tumors when compared with conventional APE.

Although the rate of perineal wound infections has been reduced with the aid of flaps,<sup>[6]</sup> several studies have reported that ELAPE may increase postoperative perineal morbidity such as chronic perineal pain, perineal wound infection, urinary retention, perineal herniation, and sexual

dysfunction.<sup>[2-4,7-9]</sup> In particular, chronic pain may be related to the coccygectomy, damage to the pudendal nerve, the wider excision of the levator ani muscles, and/or the suturing of the biological mesh close to the pelvic wall.<sup>[4,9]</sup>

To preserve the normal tissue, achieve local radical excision, and minimize the operative trauma of the perineal wound as well as minimize the damage to the nerves supplying the genital organs, we hypothesized that preserving part of the levator ani muscle or sacrococcyx, according to preoperative

**Address for correspondence:** Dr. Jia-Gang Han,  
Department of General Surgery, Beijing Chaoyang Hospital,  
Capital Medical University, Beijing 100020, China  
E-Mail: hjg211@163.com

This is an open access journal, and articles are distributed under the terms of the Creative Commons Attribution-NonCommercial-ShareAlike 4.0 License, which allows others to remix, tweak, and build upon the work non-commercially, as long as appropriate credit is given and the new creations are licensed under the identical terms.

**For reprints contact:** reprints@medknow.com

© 2018 Chinese Medical Journal | Produced by Wolters Kluwer - Medknow

**Received:** 08-03-2018 **Edited by:** Yuan-Yuan Ji  
**How to cite this article:** Zheng Y, Han JG, Wang ZJ, Gao ZG, Wei GH, Zhai ZW, Zhao BC. Preliminary Outcome of Individualized Abdominoperineal Excision for Locally Advanced Low Rectal Cancer. Chin Med J 2018;131:1268-74.

### Access this article online

#### Quick Response Code:



**Website:**  
www.cmj.org

**DOI:**  
10.4103/0366-6999.232810

pelvic magnetic resonance imaging (MRI), may lower the perineal morbidity. We have previously described the concept of individualized APE, which is also called the individualized technique.<sup>[4]</sup> The purpose of this study was to evaluate the safety and efficacy of individualized APE for locally advanced low rectal cancer.

## METHODS

### Ethical approval

The study was conducted in accordance with the *Declaration of Helsinki* and was approved by the local Ethics Committee of Beijing Chaoyang Hospital (No. 2011-ke-143). Informed written consent was obtained from all patients before their enrollment in this study.

### Patients

From June 2011 to June 2015, 446 patients with rectal cancer underwent surgical resection in our center. Of these patients, a total of 58 consecutive patients with locally advanced low rectal cancer underwent individualized APE. After exclusions (two patients lost to follow-up), 56 patients were included in the analysis [Figure 1]. The operations were performed mainly by two of the authors (Wang ZJ and Han JG), in cooperation with an experienced blinded pathologist. The patients underwent digital rectal examination and MRI for staging of rectal cancer once the diagnosis had been confirmed. Patients with clinical staging of T3 N1–N2 or T4 tumors were recommended to receive neoadjuvant chemoradiotherapy. Preoperative radiotherapy was given with 50 Gy in 25 fractions (five fractions per week),<sup>[10]</sup> concomitant with capecitabine 825 mg/m<sup>2</sup> twice daily on treatment days. Two cycles of consolidation chemotherapy with CapeOX were planned 1 week after radiotherapy. Capecitabine was administered orally at a dose of 850 mg/m<sup>2</sup> twice daily for 14 days, followed by 7 days of rest. Oxaliplatin was given every 3 weeks at a dose of 130 mg/m<sup>2</sup>. Surgery was planned 2 weeks after completion of two cycles of CapeOX. For patients who received neoadjuvant therapy, we performed colonoscopy and MRI afterward to restage these patients, and the extent of surgery was based on the MRI findings.

### Surgical technique

We expected all patients to undergo laparoscopic operation. However, some patients underwent laparotomy for various reasons (e.g. elderly patients, comorbidities, and patient choice). The abdominal procedure was performed according to the description provided by Holm *et al.*<sup>[1,11]</sup> The mobilization was stopped at the upper border of the coccyx posteriorly, below the autonomic nerves laterally, and just below the level of the seminal vesicles or cervix anteriorly. An end colostomy was formed, the abdomen was closed, and the patient was turned over into the prone jackknife position.

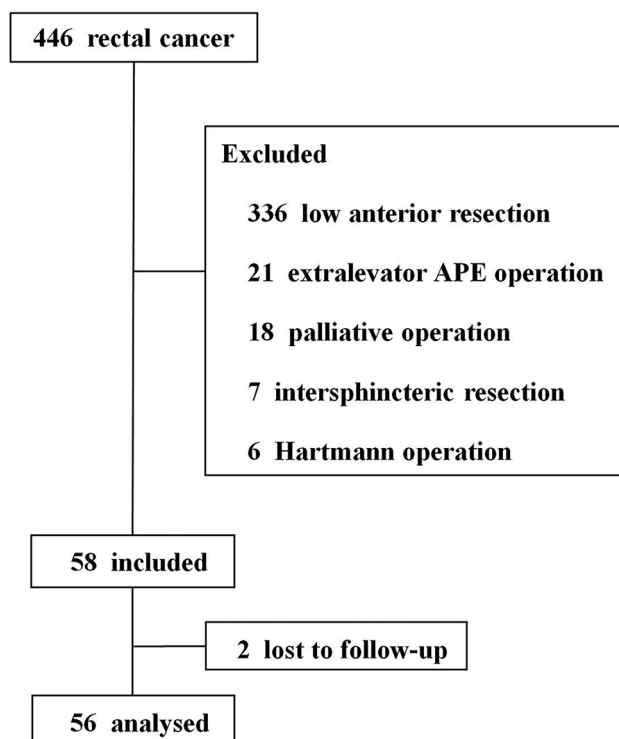
For the perineal phase, a teardrop-shaped incision was made close to the anus, after the anus had been closed with a purse-string suture. The subsequent procedure was performed according to our previous report.<sup>[4]</sup> To consider

the depth of tumor invasion: (1) in those rectal tumors not involving the ischioanal fat or levator ani muscle (T3), the dissection plane may continue close to the outside of the external anal sphincter and the inferior aspect of the levator ani muscles, leaving 1 cm of the levator ani muscles on the pelvic sidewall to keep the terminal branches of the pudendal nerve intact [Figure 2a]. (2) If the tumor has involved the ischioanal fat or levator ani muscle or penetrated through the external anal sphincter (T4), the dissection should include part of the ischioanal fat and the intact external sphincter to attain negative CRM; the pelvic autonomic nerves were preserved carefully during dissection [Figure 2c and 2d].

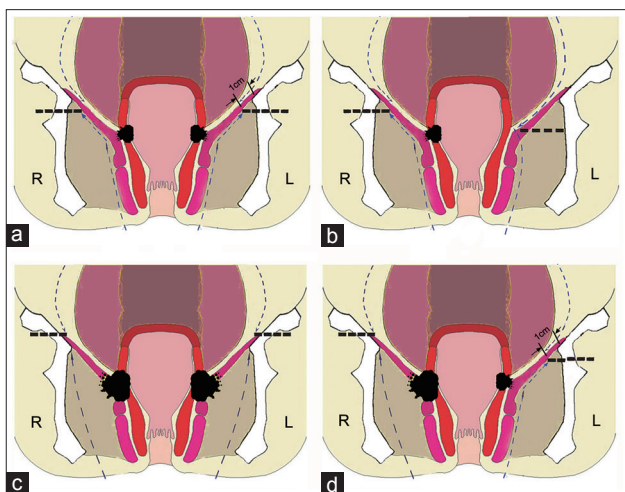
To consider the circumferential extension of the tumor: (1) If the tumor has only penetrated into one side of the levator ani muscle, the levator ani muscle contralateral to the tumor may be left [Figure 2b] and (2) if the tumor is located in the anterior wall or does not penetrate the posterior wall, the coccyx is not removed, to reduce the incidence of chronic perineal pain.

After the specimen was removed, pelvic reconstruction was performed using biological mesh (human acellular dermal matrix, Ruinuo; Qingyuanweiye Bio-Tissue Engineering, Ltd., Beijing, China), according to our previous study,<sup>[9,12]</sup> or a primary closure.

Data regarding patient demographics, disease characteristics, and treatment were collected. All complications, including perineal, urinary, and sexual complications, occurring postoperatively were recorded. A visual analog scale (VAS; a score of 1–10) was used to evaluate the perineal pain severity at 3, 6, and 12 months postoperatively. A VAS score  $\geq 4$  was



**Figure 1:** Flow chart of the study on individualized APE patients of locally advanced low rectal cancer. APE: abdominoperineal excision.



**Figure 2:** Individualized APE technique. (a) Tumor not involves the ischioanal fat or levator ani muscle (T3), leave 1 cm of the levator ani muscles on the pelvic sidewall; (b) tumor locates at one side (T3), levator ani muscle on the other side may be left; (c) tumor penetrates into the levator ani muscle (T4) bilaterally, dissection should include the fat of the ischioanal fossa and the intact levator ani muscle bilaterally; (d) tumor penetrates into the levator ani muscle (T4) unilaterally, part of the ischioanal fat and intact levator ani muscle should be dissected unilaterally. APE: Abdominoperineal excision.

considered positive. Pain that lasted for more than 3 months was defined as chronic perineal pain. The International Index of Erectile Function-5 was used to assess the sexual function of male patients pre and 6 months postoperatively.<sup>[13]</sup> Sexual function of female patients was evaluated using the Female Sexual Function Index.<sup>[14]</sup>

### Follow-up

Follow-up was arranged every 3 months for 2 years and every 6 months thereafter. In addition, data from the last available follow-up visit were included in the analyses. Chest X-ray, abdominal computed tomography (CT), and pelvic CT were repeated annually to detect local or distant recurrence. Colonoscopy was performed 1 year after the operation and was to be repeated every 3 years if no lesion was found. Colonoscopy was performed at 3–6 months if no complete visualization of the colon had been achieved preoperatively.

### Statistical analysis

Statistical analysis was performed using the Statistical Package for the Social Sciences (version 16.0; SPSS Inc., Chicago, IL, USA). Continuous variables (e.g. age, intraoperative blood loss, and operative time) were presented as the median (range) or mean  $\pm$  standard deviation (SD). Differences between groups were compared using Chi-square analysis or Fisher's exact test for categorical data. Continuous variables were compared using the Student's *t*-test or Mann-Whitney *U*-test. Potential risk factors for perineal procedure-related complications were analyzed with univariate analysis. Variables with  $P < 0.05$  on univariate analysis were entered into a multivariable model (multiple logistic regression analysis) to identify any variables predictive of perineal procedure-related complications. All

*P* values reported were two sided, with values of  $< 0.05$  considered statistically significant.

## RESULTS

### Patient characteristics

Fifty-six patients were included in the analysis. Fifty (89.3%) patients received preoperative chemoradiotherapy. The median distance between the lower margin of the tumor and the anal verge was 3 cm. The median operative time overall was 223 min. Thirty-six (64%) patients underwent a perineal biological mesh repair and 20 (36%) underwent primary closure. Thirty-eight patients underwent a laparoscopic procedure and 18 underwent an open procedure. The overall CRM positivity rate was 5% ( $n = 3$ ). The incidence of intraoperative perforation was 4% ( $n = 2$ ), and both perforations were located anterolaterally. During the study, 27 (48%) patients were treated with the levator ani muscle partially preserved bilaterally; 20 (36%) patients with the levator ani muscle partially preserved unilaterally and the muscle on the opposite side totally preserved; 7 (13%) patients with intact levator ani muscle and part of the ischioanal fat bilaterally dissected; 2 (4%) patients with part of the ischioanal fat and intact levator ani muscle dissected unilaterally and the muscle on the opposite side partially preserved; and 51 (91%) patients with the sacrococcyx preserved.

### Complications

Perineal procedure-related complications were defined as chronic perineal pain, sexual dysfunction, urinary retention, and perineal wound complications including infection, seroma, hernia, wound dehiscence, and chronic sinus. Comparison of patients with perineal procedure-related complications versus those with no complications showed the following variables to be associated with complications: higher body mass index (BMI) ( $P = 0.022$ ), longer operative time ( $P = 0.019$ ), and more intraoperative blood loss ( $P = 0.001$ ). Patients' age, gender, smoking, alcohol consumption, diabetes mellitus, blood glucose level, concentration of albumin, neoadjuvant chemoradiotherapy, pathological stage, laparoscopic technique, CRM, bowel perforation, coccygectomy, and pelvic floor reconstruction technique did not influence the rate of perineal procedure-related complications [Table 1].

Multivariable analysis showed longer operative time ( $P = 0.032$ ) and more intraoperative blood loss ( $P = 0.006$ ) to be significantly associated with perineal procedure-related complications. BMI was not an independent risk factor in the multivariable analysis [Table 2].

There were no documented postoperative deaths. The postsurgical complications are shown in Table 3. In total, 16 (29%) patients developed postoperative complications. Among the 3 (5%) patients with chronic perineal pain at 12 months postoperatively, none required pain relief. The rate of sexual dysfunction was 12% (5/41). Four (7%) patients had urinary retention, which resolved during hospitalization.

**Table 1: Patient characteristics in relation to perineal procedure-related complications in individualized APE patients**

Variables	Perineal procedure-related complications (n = 14)	No perineal procedure-related complications (n = 42)	Statistics	P
Age (years)	59.7 ± 11.9	58.5 ± 7.9	-0.435*	0.665
Male/female, n	8/6	27/15	0.229†	0.633
BMI (kg/m <sup>2</sup> )	29.4 ± 3.6	27.3 ± 2.5	-2.359*	0.022
Smoking, n (%)	4 (29)	10 (24)	0.000†	1.000
Alcohol consumption, n (%)	4 (29)	11 (26)	0.000†	1.000
Diabetes mellitus, n (%)	6 (43)	16 (38)	0.100†	0.752
Hypertension, n (%)	6 (43)	19 (45)	0.024†	0.877
Albumin (g/L)	36.5 ± 3.5	38.0 ± 4.1	1.306*	0.197
Hemoglobin (g/L)	129 (79–143)	119 (76–154)	-1.268‡	0.205
Distance form anal verge (cm)	4.0 (2.0–4.0)	3.0 (1.0–5.0)	-0.736‡	0.461
Neoadjuvant chemoradiotherapy, n (%)	13 (93)	37 (88)	0.000†	1.000
Pathological tumor (T) category, n (%)			2.885†	0.089
T0–T2	4 (29)	23 (55)		
T3–T4	10 (71)	19 (45)		
Pathological node (N) category, n (%)			0.027†	0.871
N0	4 (29)	15 (36)		
N1–N2	10 (71)	27 (64)		
Laparoscopic/open technique, n	7/7	31/11	1.747†	0.186
Total operative time (min)	260 (200–320)	220 (180–300)	-2.349‡	0.019
Intraoperative blood loss (ml)	175 (100–350)	100 (40–300)	-3.425‡	0.001
Pelvic floor reconstruction, n (%)			3.733†	0.053
Biologic mesh	6 (43)	30 (71)		
Primary closure	8 (57)	12 (29)		
Positive CRM, n (%)	2 (14)	1 (2)	Fisher	0.151
CRM (mm)	5.5 (0.5–20.0)	6.0 (0.8–14.0)	-0.086‡	0.931
Bowel perforation, n (%)	2 (14)	0	Fisher	0.059
Coccygectomy, n (%)	2 (14)	3 (7)	0.073†	0.787

Values were shown as mean ± SD, median (range), or n (%). \*Student's *t*-test; †Chi-square analysis; ‡Mann-Whitney *U*-test; Perineal procedure-related complications are chronic perineal pain, sexual dysfunction urinary retention and perineal wound complications. APE: Abdominoperineal excision; BMI: Body mass index; CRM: Circumferential resection margin; SD: Standard deviation.

**Table 2: Multiple logistic regression analyses of potential predictors of perineal procedure-related complications in individualized APE patients**

Variables	OR (95% CI)	P
BMI (kg/m <sup>2</sup> )	1.226 (0.945–1.591)	0.126
Total operative time (min)	1.028 (1.002–1.054)	0.032
Intraoperative blood loss (ml)	1.022 (1.006–1.038)	0.006

Perineal procedure-related complications are chronic perineal pain, sexual dysfunction urinary retention and perineal wound complications. APE: Abdominoperineal excision; BMI: Body mass index, OR: Odds ratio; CI: Confidence interval.

Three patients with perineal wound infection recovered well with minimal discomfort and achieved early discharge. One patient who underwent primary closure of the pelvic floor defect developed a chronic presacral sinus.

The postoperative complications were similar between patients who underwent biological mesh repair and primary closure. The abdominal wound infection rate was significantly lower in the laparoscopic surgery group than in the open surgery group ( $P = 0.014$ ). There were trends toward decreased sexual dysfunction ( $P = 0.050$ ) and overall perineal wound complications ( $P = 0.052$ )

in the laparoscopic group, but these differences were not statistically significant [Table 3].

### Oncologic results

The local recurrence rate was 4% at a median follow-up of 53 months (range: 30–74 months), and 4 (7%) patients had lung metastasis at 32 months postoperatively. No patients died of tumor recurrence or metastasis.

### DISCUSSION

Although ELAPE has been shown to be oncologically superior to APE in many studies, it carries a considerable risk of perineal wound complications. West *et al.*<sup>[2]</sup> reported more perineal wound complications, such as wound infection, breakdown, and sinus, following ELAPE than following standard APE, and increased wound infection has been considered the main disadvantage of ELAPE. Other studies have also suggested that ELAPE results in a high rate of perineal wound complications, chronic perineal pain, urogenital problems, or sexual dysfunction.<sup>[4,7,12,15]</sup> Further improvements to the technique may seek to reduce complications.

Recent studies of pelvic anatomy have reported that the clear identification of pelvic anatomical landmarks may be useful

**Table 3: Postoperative complications of individualized APE patients, n**

Complications	n	Perineal reconstruction (N = 56)		Statistics	P	Surgical technique (N = 56)		Statistics	P
		Biological mesh (n = 36)	Primary closure (n = 20)			Laparoscopic (n = 38)	Open (n = 18)		
		Chronic perineal pain (12 months postoperative)	3			1	2		
Sexual dysfunction	5/41	2/22	3/19	0.031*	0.861*	1/28	4/13	3.856*	0.050
Urinary retention	4	2	2	0.006*	0.938*	1	3	1.820*	0.177
Perineal wound complications	7	6	1	0.711*	0.399*	2	5	3.789*	0.052
Infection	3	2	1	0.000*	1.000*	1	2	Fisher	0.239
Seroma	3	3	0	0.501*	0.479*	1	2	Fisher	0.239
Hernia	0	0	0	–	–	0	0	–	–
Wound dehiscence	0	0	0	–	–	0	0	–	–
Chronic sinus	1	1	0	Fisher	1.000	0	1	Fisher	0.321
Abdominal wound infection	4	1	3	Fisher	0.246	0	4	6.052*	0.014
Urinary system infection	2	1	1	Fisher	1.000	1	1	Fisher	0.544
Pulmonary infection	1	0	1	Fisher	0.357	1	0	Fisher	1.000
Deep venous thrombosis	0	0	0	–	–	0	0	–	–
Postoperative ileus	3	2	1	0.000*	1.000*	2	1	Fisher	1.000

\*Chi-square analysis. APE: Abdominoperineal excision; –: Not applicable.

for both the successful achievement of negative CRMs and the preservation of urogenital function during ELAPE.<sup>[16,17]</sup> A preoperative (MRI) staging system was shown to predict the planes of surgical excision required for low rectal cancer<sup>[18,19]</sup> and has been proven within the MERCURY II study.<sup>[20]</sup> This may help to reduce margin positivity and to improve outcome in patients with low rectal cancer.<sup>[21]</sup> Given that the precise tumor stage and location vary among patients who receive ELAPE, we suggested preserving the normal pelvic tissue near anatomical landmarks, according to the patients' individualized tumor condition as based on preoperative MRI and digital examination; this procedure was named individualized APE. The individualized APE is aimed at the reduction of perineal wound complications and preservation of urogenital function while not compromising cancer control. A finite element model suggested that ELAPE of the dissection plane close to the rectum on one side was able to reduce the stress on the nonlevator ani tissue on both sides, especially on the side with the levator ani partly preserved, which may reduce the perineal hernia rate.<sup>[22]</sup>

It has been suggested that preservation of the pudendal nerve during surgical procedures may be important for postoperative sexual and urinary function,<sup>[23]</sup> and that injury to the pudendal nerve may cause sexual and bladder dysfunction.<sup>[24]</sup> However, the end branches of the pudendal nerves are close to the lateral excision plane and may be damaged at the pelvic sidewall during the perineal procedure of ELAPE. We recommended preservation of part of the levator ani muscles near the pelvic sidewall in our previous study,<sup>[4]</sup> and it has also been reported that, with adequate neoadjuvant chemoradiotherapy, a levator-sparing excision of the rectum resulted in a safe option with low 3-year rates of local recurrence, morbidity, and perioperative complications.<sup>[25]</sup> It has also been mentioned that leaving a small part of the levator ani muscles at the pelvic sidewall

may facilitate suturing of the biological mesh.<sup>[26]</sup> In our study, part of the levator ani muscle near the pelvic sidewall was preserved according to the depth of tumor invasion and the circumferential extension of the tumor on preoperative MRI assessment. The preservation of part of the levator ani muscle near the pelvic sidewall was shown not to increase the CRM involvement, perforation rate, and local recurrence with the relatively high rate (89%) of neoadjuvant chemoradiotherapy in this study. The rate of sexual dysfunction was only 18% and that of urinary retention was only 10% in this trial; these rates were much lower than in our previous study.<sup>[4]</sup> We propose that individualized APE should become the technique of choice for low rectal cancer without increasing the risk of urogenital dysfunction in patients receiving adequate preoperative chemoradiotherapy. However, longer follow-up is needed in the future to confirm these results.

During the perineal procedure, it has been recommended to enter the peritoneal cavity by disarticulation of the coccyx with division of Waldeyer's fascia, as described by Holm *et al.*,<sup>[1]</sup> which provides more room in which to excise the specimen safely. However, several studies have demonstrated that chronic perineal pain is significantly related to coccygectomy.<sup>[15,27-29]</sup> Furthermore, chronic perineal pain was one of the most common complications following ELAPE. Our previous study reported that 51% of the patients experienced chronic perineal pain with several requiring pain-relieving drugs.<sup>[4]</sup> To reduce the postoperative incidence of chronic perineal pain, we suggest that it is possible to preserve the coccyx during the ELAPE procedure for anterior rectal tumors and these T3 tumors. The sacrococcyx was preserved in 51 (91%) patients and the incidence of chronic perineal pain was only 5% at 12 months postoperatively in our study, which supports the notion that resection of the coccyx should not be routine but performed only if indicated on the basis of surgical exposure or oncological principles.

The dissection in the anterior plane during the perineal phase of the ELAPE is potentially most dangerous because of the close relationship between the anterior rectal wall and the prostate or posterior vaginal wall.<sup>[30]</sup> During the anterior dissection, the neurovascular bundle (NVB) derived from the inferior hypogastric plexus run anterolaterally on each side of the prostate or vagina and can easily be damaged.<sup>[22,23]</sup> Injury to these branches may result in urinary dysfunction and sexual impotence.<sup>[16,17]</sup> For anteriorly located penetrating tumors, it may be necessary to include part of the posterior vaginal wall or prostate in the dissection, and sometimes even to sacrifice the NVB on one side, to be able to achieve a negative CRM.<sup>[30]</sup> For posteriorly located tumors, the anterior dissection should be performed close to the rectal wall to protect the NVB. The decision regarding the procedure should be made in advance and based on the preoperative MRI staging and digital examination.<sup>[30]</sup>

In our previous study, perineal wound complications, especially wound breakdown, were significantly less frequent in the biological mesh group than in the primary closure group.<sup>[12]</sup> Another study also suggested that biological mesh-assisted perineal reconstruction was a promising technique to improve wound healing after ELAPE.<sup>[31]</sup> Therefore, use of biological mesh may be an ideal technique because it provides a shorter operating time and more rapid early mobilization and lacks donor site morbidity. In this study, there was no significant difference in postoperative perineal wound complications or perineal procedure-related complications. We assume that the minimal trauma during the perineal procedure of individualized APE may reduce the rate of perineal wound complications and, furthermore, offset the difference between the biological mesh group and the primary closure group.

Operative time and intraoperative blood loss were identified as important predictors of perineal procedure-related complications following individualized APE in our multivariable analyses. The significance of added complications related to longer operative time and more intraoperative blood loss has been previously documented.<sup>[32,33]</sup> Several other risk factors for perineal wound complications after APE have been reported such as patients' nutritional status, smoking, alcohol consumption, diabetes mellitus, neoadjuvant chemotherapy, intraoperative perforation, and pelvic floor reconstruction technique.<sup>[31-35]</sup> In our series, these factors had no impact on the risk of perineal procedure-related complications. The sample size in this study may not have been large enough to detect these influences. The differences between individual APE and conventional APE might have influenced the risk factors. Furthermore, the high percentage of neoadjuvant chemoradiotherapy (89%) and the low percentage of intraoperative perforation (4%) might also have influenced the statistical analysis.

The main aim of individualized APE is not only to decrease perineal wound complications and spare normal tissue around tumor but also to achieve the required oncological outcomes. If the tumor involves the ischioanal fat, the dissection should

include part of the ischioanal fat and the intact external sphincter to attain negative CRM, although this condition is rare in patients who undergo preoperative chemoradiotherapy.

This study has limitations. A major limitation of the study was the fact that this is not a comparative study but a case series. The second limitation was its small sample size. Continued long-term follow-up and larger sample size will be necessary to evaluate the true outcomes of the technique. Furthermore, a few patients with T3 stage tumors did not receive preoperative chemoradiotherapy.

In conclusion, our team suggests that it is feasible to perform individualized APE for low rectal tumors in patients given adequate preoperative chemoradiotherapy. In the context of precise preoperative MRI staging and digital examination, individualized APE has the potential to reduce the risk of wound complications and urogenital dysfunction. Furthermore, individualized APE is a relatively safe approach with acceptable rates of CRM involvement and intraoperative perforations. Operative time and intraoperative blood loss were independently associated with perineal procedure-related complications following individualized APE. Longer follow-up is needed in the future to confirm the results for recurrence and survival. Given the relatively small number of patients in our study, however, further research into the subject should be recommended.

### Financial support and sponsorship

This study was funded by grants from National High Technology Research and Development Program 863 (No. 2015AA033602), National Natural Science Foundation of China (No. 81541101), The Capital Health Research and Development of Special Fund (No. Z121107001012131, No. 2014-4-2033), Beijing Chaoyang Hospital 1351 Personnel Training Program (No. CYXZ-2017-09), and the Basic and Clinical Cooperation Project of Capital Medical University (No. 15JL03).

### Conflicts of interest

There are no conflicts of interest.

### REFERENCES

1. Holm T, Ljung A, Häggmark T, Jurell G, Lagergren J. Extended abdominoperineal resection with gluteus maximus flap reconstruction of the pelvic floor for rectal cancer. *Br J Surg* 2007;94:232-8. doi: 10.1002/bjs.5489.
2. West NP, Anderin C, Smith KJ, Holm T, Quirke P; European Extralevator Abdominoperineal Excision Study Group, *et al.* Multicentre experience with extralevator abdominoperineal excision for low rectal cancer. *Br J Surg* 2010;97:588-99. doi: 10.1002/bjs.6916.
3. Welsch T, Mategakis V, Contin P, Kulu Y, Büchler MW, Ulrich A, *et al.* Results of extralevator abdominoperineal resection for low rectal cancer including quality of life and long-term wound complications. *Int J Colorectal Dis* 2013;28:503-10. doi: 10.1007/s00384-012-1611-7.
4. Han JG, Wang ZJ, Wei GH, Gao ZG, Yang Y, Zhao BC, *et al.* Randomized clinical trial of conventional versus cylindrical abdominoperineal resection for locally advanced lower rectal cancer. *Am J Surg* 2012;204:274-82. doi: 10.1016/j.amjsurg.2012.05.001.
5. Palmer G, Anderin C, Martling A, Holm T. Local control and survival

- after extralevator abdominoperineal excision for locally advanced or low rectal cancer. *Colorectal Dis* 2014;16:527-32. doi: 10.1111/codi.12610.
6. Stelzner S, Hellmich G, Sims A, Kittner T, Puffer E, Zimmer J, *et al.* Long-term outcome of extralevator abdominoperineal excision (ELAPE) for low rectal cancer. *Int J Colorectal Dis* 2016;31:1729-37. doi: 10.1007/s00384-016-2637-z.
  7. Prytz M, Angenete E, Bock D, Haglind E. Extralevator abdominoperineal excision for low rectal cancer – extensive surgery to be used with discretion based on 3-year local recurrence results: A registry-based, observational national cohort study. *Ann Surg* 2016;263:516-21. doi: 10.1097/SLA.0000000000001237.
  8. Asplund D, Prytz M, Bock D, Haglind E, Angenete E. Persistent perineal morbidity is common following abdominoperineal excision for rectal cancer. *Int J Colorectal Dis* 2015;30:1563-70. doi: 10.1007/s00384-015-2328-1.
  9. Han JG, Wang ZJ, Gao ZG, Xu HM, Yang ZH, Jin ML, *et al.* Pelvic floor reconstruction using human acellular dermal matrix after cylindrical abdominoperineal resection. *Dis Colon Rectum* 2010;53:219-23. doi: 10.1007/DCR.0b013e3181b715b5.
  10. Klenova A, Parvanova V, Georgiev R, Gesheva N. Preoperative radiotherapy in rectal cancer: Treatment results of three different dose regimens. *J BUON* 2006;11:161-6.
  11. Shihab OC, Heald RJ, Holm T, How PD, Brown G, Quirke P, *et al.* A pictorial description of extralevator abdominoperineal excision for low rectal cancer. *Colorectal Dis* 2012;14:e655-60. doi: 10.1111/j.1463-1318.2012.03181.x.
  12. Han JG, Wang ZJ, Qian Q, Dai Y, Zhang ZQ, Yang JS, *et al.* A prospective multicenter clinical study of extralevator abdominoperineal resection for locally advanced low rectal cancer. *Dis Colon Rectum* 2014;57:1333-40. doi: 10.1097/DCR.0000000000000235.
  13. Rosen RC, Riley A, Wagner G, Osterloh IH, Kirkpatrick J, Mishra A, *et al.* The international index of erectile function (IIEF): A multidimensional scale for assessment of erectile dysfunction. *Urology* 1997;49:822-30. doi: 10.1016/S0090-4295(97)00238-0.
  14. Rosen R, Brown C, Heiman J, Leiblum S, Meston C, Shabsigh R, *et al.* The Female Sexual Function Index (FSFI): A multidimensional self-report instrument for the assessment of female sexual function. *J Sex Marital Ther* 2000;26:191-208. doi: 10.1080/009262300278597.
  15. Wang YL, Dai Y, Jiang JB, Yuan HY, Hu SY. Application of laparoscopic extralevator abdominoperineal excision in locally advanced low rectal cancer. *Chin Med J* 2015;128:1340-5. doi: 10.4103/0366-6999.156779.
  16. Stelzner S, Holm T, Moran BJ, Heald RJ, Witzigmann H, Zorenkov D, *et al.* Deep pelvic anatomy revisited for a description of crucial steps in extralevator abdominoperineal excision for rectal cancer. *Dis Colon Rectum* 2011;54:947-57. doi: 10.1097/DCR.0b013e31821c4bac.
  17. Açar Hİ, Kuzu MA. Perineal and pelvic anatomy of extralevator abdominoperineal excision for rectal cancer: Cadaveric dissection. *Dis Colon Rectum* 2011;54:1179-83. doi: 10.1097/DCR.0b013e318224256c.
  18. Shihab OC, Heald RJ, Rullier E, Brown G, Holm T, Quirke P, *et al.* Defining the surgical planes on MRI improves surgery for cancer of the low rectum. *Lancet Oncol* 2009;10:1207-11. doi: 10.1016/S1470-2045(09)70084-1.
  19. Shihab OC, How P, West N, George C, Patel U, Quirke P, *et al.* Can a novel MRI staging system for low rectal cancer aid surgical planning? *Dis Colon Rectum* 2011;54:1260-4. doi: 10.1097/DCR.0b013e31822abd78.
  20. Battersby NJ, How P, Moran B, Stelzner S, West NP, Branagan G, *et al.* Prospective validation of a low rectal cancer magnetic resonance imaging staging system and development of a local recurrence risk stratification model: The MERCURY II study. *Ann Surg* 2016;263:751-60. doi: 10.1097/SLA.0000000000001193.
  21. Pai A, Eftaiha SM, Melich G, Park JJ, Lin PK, Prasad LM, *et al.* Robotic site adjusted levator transection for carcinoma of the rectum: A modification of the existing cylindrical abdominoperineal resection for eccentrically located tumors. *World J Surg* 2017;41:590-5. doi: 10.1007/s00268-016-3735-3.
  22. Wang J, Wang W, Liu J, Chen Y, Yu J, Zhao P, *et al.* Finite element analysis of the effects of two kinds of individual extralevator abdominalperineal excision on female pelvic floor (In Chinese). *Natl Med J China* 2016;96:629-33. doi: 10.3760/cma.j.issn.0376-2491.2016.08.010.
  23. Huang JC, Deletis V, Vodusek DB, Abbott R. Preservation of pudendal afferents in sacral rhizotomies. *Neurosurgery* 1997;41:411-5. doi: 10.1097/00006123-199708000-00015.
  24. Fegiz G, Trenti A, Bezzi M, Ambrogi V, Papini Papi M, Tucci G, *et al.* Sexual and bladder dysfunctions following surgery for rectal carcinoma. *Ital J Surg Sci* 1986;16:103-9.
  25. Ramsay G, Parnaby C, Mackay C, Hanlon P, Ong S, Loudon M, *et al.* Analysis of outcome using a levator sparing technique of abdominoperineal excision of rectum and anus. Cylindrical ELAPE is not necessary in all patients. *Eur J Surg Oncol* 2013;39:1219-24. doi: 10.1016/j.ejso.2013.08.004.
  26. Ghinea R, White I, Benjamin B, Kidron D, Shpitz B, Avital S, *et al.* Laparoscopic-assisted extralevator abdominoperineal excision using a parastomal prophylactic mesh and a biological mesh for pelvic floor reconstruction. *Tech Coloproctol* 2015;19:317-8. doi: 10.1007/s10151-015-1280-y.
  27. Jensen KK, Rashid L, Pilsgaard B, Møller P, Wille-Jørgensen P. Pelvic floor reconstruction with a biological mesh after extralevator abdominoperineal excision leads to few perineal hernias and acceptable wound complication rates with minor movement limitations: Single-centre experience including clinical examination and interview. *Colorectal Dis* 2014;16:192-7. doi: 10.1111/codi.12492.
  28. Peacock O, Simpson JA, Tou SI, Hurst NG, Speake WJ, Tierney GM, *et al.* Outcomes after biological mesh reconstruction of the pelvic floor following extra-levator abdominoperineal excision of rectum (APER). *Tech Coloproctol* 2014;18:571-7. doi: 10.1007/s10151-013-1107-7.
  29. Zhang X, Wang Z, Liang J, Zhou Z. Transabdominal extralevator abdominoperineal excision (eLAPE) performed by laparoscopic approach with no position change. *J Laparoendosc Adv Surg Tech A* 2015;25:202-6. doi: 10.1089/lap.2014.0413.
  30. Holm T. Controversies in abdominoperineal excision. *Surg Oncol Clin N Am* 2014;23:93-111. doi: 10.1016/j.soc.2013.09.005.
  31. Peacock O, Pandya H, Sharp T, Hurst NG, Speake WJ, Tierney GM, *et al.* Biological mesh reconstruction of perineal wounds following enhanced abdominoperineal excision of rectum (APER). *Int J Colorectal Dis* 2012;27:475-82. doi: 10.1007/s00384-011-1325-2.
  32. Matsuda K, Hotta T, Takifuji K, Yokoyama S, Higashiguchi T, Tominaga T, *et al.* Long-term comorbidity of diabetes mellitus is a risk factor for perineal wound complications after an abdominoperineal resection. *Langenbecks Arch Surg* 2009;394:65-70. doi: 10.1007/s00423-008-0381-8.
  33. Artioukh DY, Smith RA, Gokul K. Risk factors for impaired healing of the perineal wound after abdominoperineal resection of rectum for carcinoma. *Colorectal Dis* 2007;9:362-7. doi: 10.1111/j.1463-1318.2006.01159.x.
  34. Althumairi AA, Canner JK, Gearhart SL, Safar B, Sacks J, Efron JE, *et al.* Predictors of perineal wound complications and prolonged time to perineal wound healing after abdominoperineal resection. *World J Surg* 2016;40:1755-62. doi: 10.1007/s00268-016-3450-0.
  35. Musters GD, Sloothaak DA, Roodbeen S, van Geloven AA, Bemelman WA, Tanis PJ, *et al.* Perineal wound healing after abdominoperineal resection for rectal cancer: A two-centre experience in the era of intensified oncological treatment. *Int J Colorectal Dis* 2014;29:1151-7. doi: 10.1007/s00384-014-1967-y.

# 个体化腹会阴联合切除术治疗低位进展期直肠癌的初步结果

## 摘要

**背景：**个体化腹会阴联合切除术（APE）可能减少手术创伤和降低并发症。本研究的目的是探索个体化APE手术治疗低位直肠癌的安全性和有效性。

**方法：**本研究纳入2011年6月至2015年6月在首都医科大学附属北京朝阳医院接受个体化APE手术的直肠癌病人56例。主要观察术中环周切缘、术中肠穿孔、术后并发症和局部复发率。统计学方法采用SPSS16.0软件包。

**结果：**50例（89%）病人接受了新辅助放化疗。51例（91%）保留了尾骨，27例（48%）保留了双侧部分肛提肌，20例（36%）保留一侧部分肛提肌和对侧全部肛提肌，7例（13%）切除全部肛提肌和部分坐骨直肠窝脂肪，2例（4%）保留一侧部分肛提肌同时切除对侧全部肛提肌和部分坐骨直肠窝脂肪。常见的并发症有性功能障碍（12%），会阴伤口并发症（13%），尿潴留（7%）和慢性会阴疼痛（5%）。3例病人（5%）环周切缘阳性，2例（4%）术中肠穿孔。多因素回归分析发现，手术时间延长（ $P=0.032$ ）和术中失血量增加（ $P=0.006$ ）与会阴操作相关并发症密切相关。平均随访53个月（30-74个月），局部复发率为4%。

**结论：**在新辅助放化疗的前提下，个体化APE手术治疗低位进展期直肠癌是安全和有效的。