

Glenoidplasty With Posterior Labral Reattachment for Posterosuperior Glenoid Impingement

Geoffroy Nourissat,^{*†} MD, PhD, Julien Provost,[†] MD, Marie Vigan,[†] PhD, and Claire Cammas,[†] MD
Investigation performed at Clinique Maussins Nollet, Ramsay Générale de Santé, Paris, France

Background: Posterosuperior glenoid impingement (PSGI), also known as shoulder internal impingement, is a cause of shoulder pain in athletes involved in overhead-throwing sports. PSGI is a condition mostly treated by rehabilitation. Surgery is indicated after unsatisfactory nonoperative management. However, with most of the surgical techniques proposed, the shoulder remains persistently painful during sport activity.

Hypothesis: We aimed to evaluate the efficiency of adding posterior labral reattachment to glenoidplasty as a surgical treatment for PSGI. Our hypothesis was that posterior labral reattachment would have a positive effect on shoulder pain. To our knowledge, this combined procedure has not been previously described.

Study Design: Case series; Level of evidence, 4.

Methods: We retrospectively reviewed 11 male patients with PSGI treated with glenoidplasty and posterior labral reattachment at a single institution during a 7-year period and with a minimum 30-month follow-up after surgery. Most patients were recreational athletes, with 5 of them practicing at the national level and 1 being a professional athlete. Patients completed an online questionnaire consisting of the Simple Shoulder Test (SST), the Kerlan-Jobe Orthopaedic Clinic (KJOC) shoulder and elbow questionnaire, and a specific PSGI survey. Pre- and postoperative shoulder pain were analyzed using the paired *t* test, with significance set at $P < .05$.

Results: All 11 patients investigated sought surgery because of persistent shoulder pain while practicing their sport. The patients underwent glenoidplasty and posterior labral fixation, and data for 9 patients were available for analysis (mean age, 29 years; range, 24-42 years). At a minimum 30-month follow-up, most patients (77.8%) showed decreased pain, and 8 patients were able to return to their previous sports activities, with 7 returning at the same or higher level. There was 1 patient who had to change sports because of a lack of force, while a second patient temporarily changed sport and then returned to his sport but at an inferior level. Pre- and postoperative pain differed significantly ($P < .05$). Surgery did not impair daily life in all patients.

Conclusion: Glenoidplasty associated with posterior labral reattachment significantly diminished shoulder pain in athletes involved in throwing sports. Most patients were able to return to their previous sport at the same or higher level. Posterior labral fixation may improve the benefit of glenoidplasty by decreasing pain.

Keywords: shoulder pain; posterosuperior glenoid impingement; surgery; labral reattachment; sport; overhead-throwing athletes; glenoidplasty; debridement; arthroscopic treatment

*Address correspondence to Geoffroy Nourissat, MD, PhD, Clinique Maussins Nollet, Ramsay Générale de Santé, 67 Rue de Romainville, 75019 Paris, France (email: gnourissat@wanadoo.fr).

†Clinique Maussins Nollet, Ramsay Générale de Santé, Paris, France. Final revision submitted July 23, 2019; accepted August 6, 2019.

The authors declared that there are no conflicts of interest in the authorship and publication of this contribution. AOSSM checks author disclosures against the Open Payments Database (OPD). AOSSM has not conducted an independent investigation on the OPD and disclaims any liability or responsibility relating thereto.

Ethical approval for this study was obtained from the ethics committee of Clinique Maussins Nollet.

The Orthopaedic Journal of Sports Medicine, 8(3), 2325967120907892
 DOI: 10.1177/2325967120907892
 © The Author(s) 2020

Posterosuperior glenoid impingement (PSGI), also known as shoulder internal impingement,⁶ is a condition in athletes involved in overhead-throwing sports.⁷ Internal impingement of the shoulder is characterized by excessive or repetitive contact of the greater tuberosity of the humeral head with the posterosuperior aspect of the glenoid when the arm is abducted and externally rotated.^{2,13} Impingement of the soft tissues between the bony structures can result in articular-sided rotator cuff tears and posterosuperior labral lesions.⁵ Nonoperative treatment includes physical therapy to reduce impingement between the glenoid rim and supraspinatus tendon. Physical therapy emphasizes posterior capsular stretching and strengthening of internal rotation.³ In our practice, nonoperative treatment is an effective solution, and most athletes show

improvement with this treatment. PSGI usually requires surgical intervention when nonoperative treatment has failed and the patient continues to suffer from persistent pain. Several technical procedures have been described. Most authors advocate for debridement of partial-thickness rotator cuff and labral tears,^{9,10} and some also perform glenoidplasty (removing the posterior-superior glenoid spur).⁸ In some cases, repair of an associated anterior Bankart lesion is also performed.⁴ To our knowledge, re-fixation of the posterosuperior labrum is not routinely performed after glenoidplasty. Many patients continue to have symptoms after the surgical treatment of PSGI.^{4,5} We aimed to confirm our hypothesis that adding posterior labral reattachment to glenoidplasty is more effective than glenoidplasty alone in reducing shoulder pain in athletes with PSGI.

METHODS

This retrospective study investigated 11 patients with PSGI and failure of nonoperative treatment to alleviate pain who then underwent a surgical procedure involving conventional glenoidplasty (described by Lévine et al⁸), followed by posterior labral reattachment. All patients were practicing overhead sports (tennis, badminton, handball, or volleyball). Most patients were recreational athletes, with 5 of them competing at the national level; 1 patient was a professional athlete who also had a full-thickness rotator cuff tear. Posterosuperior labral damage could be repaired, even if some tears had to be resected. Patients underwent surgery between September 2011 and March 2016. All patients were operated on by the same surgeon (G.N.). The minimum follow-up was 30 months (mean follow-up, 53 months; range, 30-70 months). All patients gave their consent to participate and agreed to complete the online questionnaire about the surgical procedure, which consisted of questions regarding postoperative global satisfaction, shoulder pain and mobility, and impact on daily and sports activities. There were 2 specific shoulder questionnaires that were also completed by the patients: the Simple Shoulder Test (SST) and the Kerlan-Jobe Orthopaedic Clinic (KJOC) shoulder and elbow questionnaire.¹ Pre- and postoperative shoulder pain were graded from 0 to 15 (maximum pain to no pain). The effect on daily life and sports activity was graded from 0 to 4 (no impairment in daily life/sport activity to severe).

Surgical Technique

Patients received general and local anesthesia. The procedure was performed with patients in the beach-chair position and was standardized in 6 surgical steps: shoulder static exploration, abduction-external rotation dynamic testing, posterior labral release, glenoidplasty, labral fixation, and management of rotator cuff tears.

Step 1: Static Exploration. Shoulder static exploration was conducted through the posterior portal for a standard

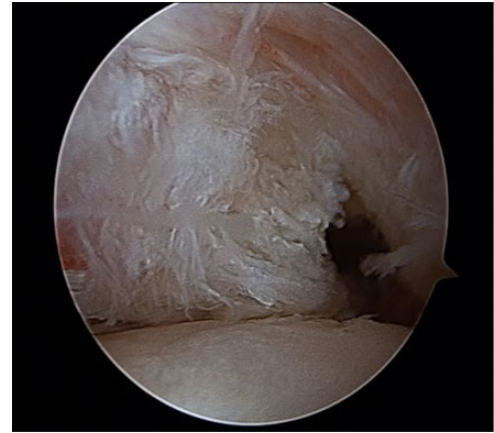


Figure 1. Partial tear of the deep supraspinatus tendon insertion.

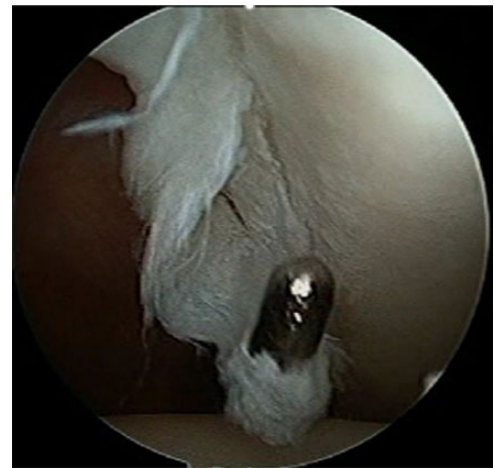

Figure 2. Patient 1: Posterior labral lesion (flap).

arthroscopic diagnosis. All glenohumeral joints were explored: the long head of the biceps tendon, superior labrum, rotator cuff, and cartilage surfaces. Specific attention was paid to anterior labral lesions and humeral avulsions of the glenohumeral ligament to avoid any incomplete repair.

In our experience, most supraspinatus tendon partial tears are located at the anterior aspect of the tendon. All patients had lesions of the posterosuperior labrum and at least a partial tear of the deep supraspinatus tendon insertion (Figures 1 and 2).

On the glenoid side, posterosuperior labral wear affected the integrity of the labrum in 7 patients: 4 of them had fraying, and 3 of them were detached. In 2 patients, a labral flap was found (Figure 2), which was resected, retaining as much of the native labrum as possible. There were 3 patients who showed an osteophyte of the posterosuperior glenoid.

On the supraspinatus insertion, a delamination lesion of the tendon representing less than 50% of its thickness

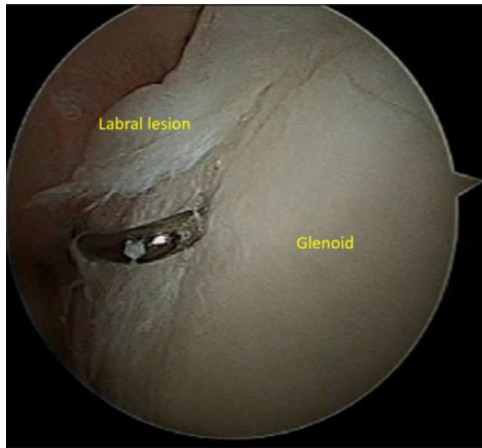


Figure 3. Patient 1: Lesion assessment.

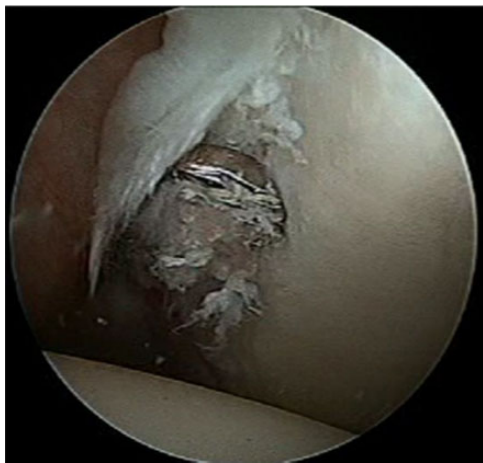

Figure 4. Patient 1: Mechanical release of the labral lesion.

(Ellman type II) was found in 8 of 9 patients. Also, 3 of them had a small partial intra-articular tear at the tendon junction between infraspinatus and supraspinatus. Further, 1 patient, a former national tennis player, had a full-thickness tear of the supraspinatus tendon.

A second portal was created in the rotator interval to check 2 important elements using a probe (Figure 3): superior labral anterior to posterior (SLAP) tears and anterior or posterior Bankart lesions. Only 1 patient presented with an anterior Bankart lesion that required repair.

Step 2: Dynamic Exploration. In this step, the patient's arm was placed in abduction–extension–external rotation to reveal PSGI and confirm the diagnosis of supraspinatus tendon impingement on the glenoid rim.

Step 3: Posterior Labral Release. A scope was introduced through the anterior portal, and the posterior labrum was released off the glenoid through a posterior portal using a rasper 1 cm medial to the cartilage surface. No other portal was necessary. The location and size of the posterior glenoid spur were evaluated by palpation with a hook (Figure 4).

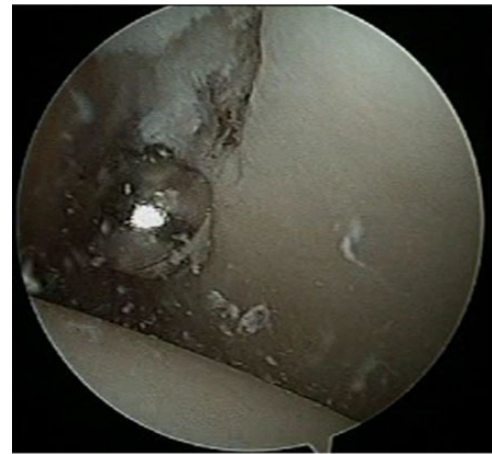


Figure 5. Patient 1: Glenoidplasty performed with a motorized shaver to enhance biological healing.

Step 4: Glenoidplasty. Glenoidplasty (Figures 5 and 6) involved a 5.5-mm motorized shaver (bone and soft tissue cutter) introduced through the same posterior portal. Any labral flap was removed with the shaver. The shaver was then introduced below the labrum. The impinging part of the glenoid was carefully removed, taking caution not to damage the labrum and cartilage. A healthy bleeding bony surface can enhance biological healing of the labrum. In our study, the bone removed was always less than 5 mm between 9 and 11 o'clock. However, the exact amount of bone removal needed to treat impingement remains unclear. All additional spurs were completely removed.

Step 5: Posterior Labral Reattachment. For labral reattachment, a LUPINE Loop Anchor (with 2 Orthocord sutures; DePuy Mitek) was introduced in the middle of the glenoidplasty site, near the articular cartilage margin. With a clever hook passed through the labrum, a mattress suture was used to repair the detached labrum to the abraded glenoid (Figures 6-8). For larger labral tears, 2 anchors were used to increase contact between the labrum and glenoid. Anchors were not placed too close to the insertion of the long head of the biceps tendon to respect its vascularization and integrity. In our experience, no patient has complained or needed revision surgery for SLAP tears or biceps tendon disorders.

Step 6: Management of Rotator Cuff Tears. Most patients had a partial articular supraspinatus tendon tear. It was difficult to assess precisely the thickness of the tears preoperatively. Thus, arthroscopic exploration provided further information for tear management. None of the partial rotator cuff lesions had more than 50% tearing of the tendon thickness; thus, simple debridement was performed. There was 1 patient with a full-thickness tear of the rotator cuff who underwent debridement, subacromial exploration, and single-row Mason-Allen repair by use of an absorbable suture anchor. In this case, subacromial decompression was performed to increase the subacromial space during tendon healing.

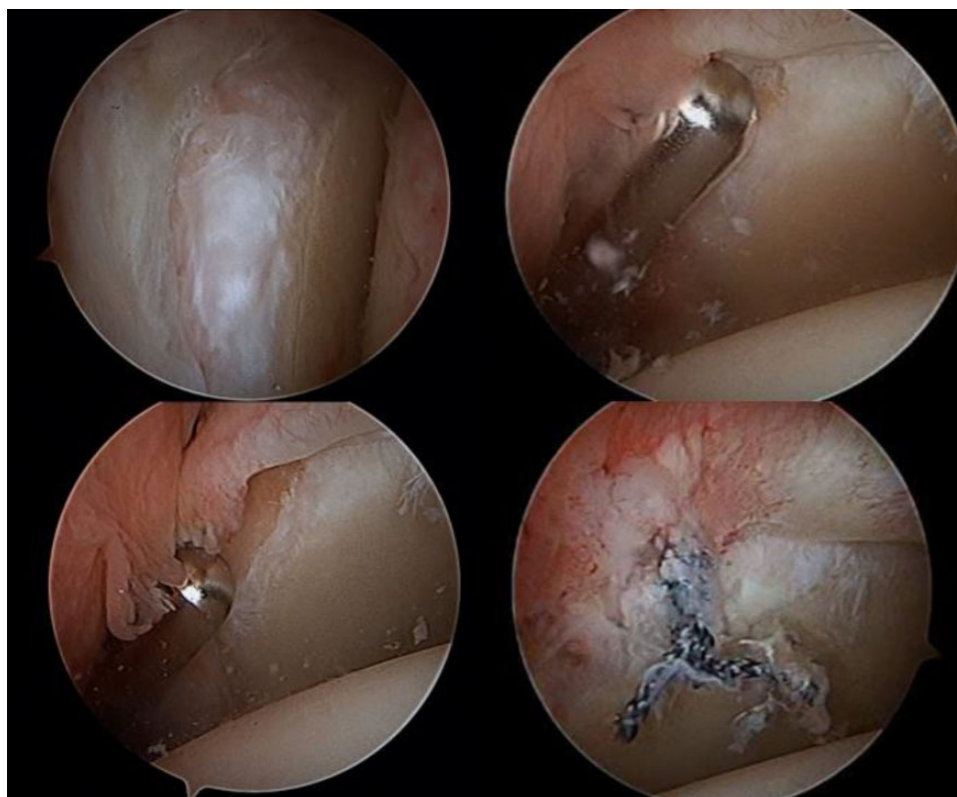


Figure 6. Patient 2: Spur evaluation and removal with a motorized shaver.

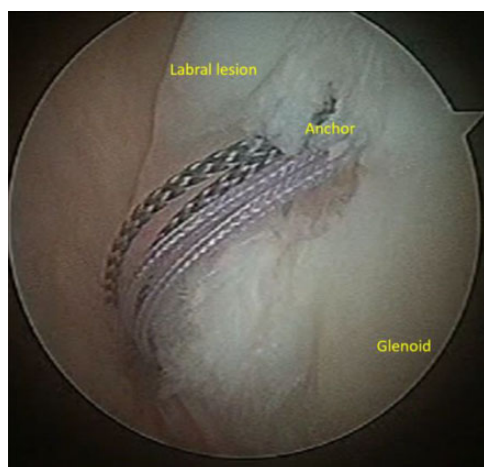


Figure 7. Patient 1: LUPINE Loop Anchor fixation.

Statistical Analysis

Pre- and postoperative shoulder pain were compared using the paired Student *t* test. $P < .05$ was considered statistically significant.

RESULTS

At the last follow-up in 2018, 9 of 11 patients completed our survey. The mean follow-up was 53 months (range, 30-70

months) (Table 1). The mean age at the time of surgery was 29 years (range, 24-42 years). All patients were involved in overhead-throwing sports (tennis, $n = 3$; badminton, $n = 4$; volleyball, $n = 1$; handball, $n = 1$; volleyball + tennis, $n = 1$), and all underwent surgery by the same surgeon. Of the 9 patients, 7 were satisfied or very satisfied with the surgical procedure. No patients had complications at 3-week and 3-month follow-up; only the patient with rotator cuff repair suffered from capsulitis. At 30 months postoperatively, he still had a 20° impairment in external rotation but has been able to play tennis at the same level by adapting his serve.

Pre- and postoperative shoulder pain were graded in 8 patients (0, maximum pain; 15, no pain). All results are reported in Table 2. The Student *t* test revealed a significant difference in pre- and postoperative pain ($P < .05$) (Figure 9). Only 1 patient (patient 7) continued to have pain but also underwent rotator cuff repair; this could explain the greater postoperative pain. Therefore, for most patients, the surgical procedure diminished shoulder pain (Table 2).

No patient experienced impairment in daily life or professional activity (see the Appendix). For 77.8% of the patients, the inconvenience during sport activity was ≤ 1 (0, normal; 4, maximal impairment). There was 1 patient who experienced discomfort at night.

At final follow-up (mean, 53 months; range, 30-70 months postsurgery), all patients were able to perform overhead movements with their shoulder (see the Appendix). The clinical examination was performed by the same

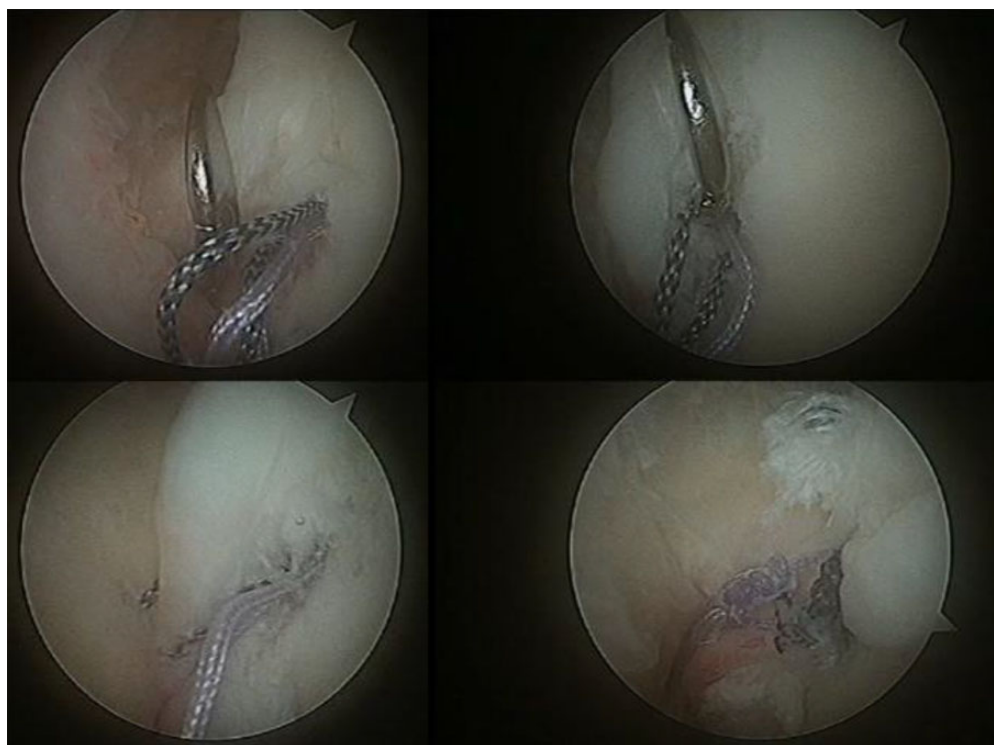


Figure 8. Patient 1: Labral reattachment (using sutures).

TABLE 1
Patient Demographics

Patient	Age at Final Follow-up, y	Follow-up, mo	Profession	Sport	Level	Rotator Cuff Tear	Posterior Labral Lesion	Anterior Labral Lesion
1	32	39	Teacher	Volleyball	Recreational	Partial on articular side	Flap	No
2	33	40	Insurance counselor	Badminton	Recreational + competitive	Partial on articular side	Disinserted	No
3	29	59	No profession	Badminton	Recreational + competitive	Partial on articular side	Wear	No
4	32	53	Informatician	Badminton	Recreational + competitive	Partial on articular side	Flap	No
5	34	62	Consultant	Handball	Recreational + competitive	Partial on articular side	Wear	No
6	31	70	Research manager	Badminton	Recreational + competitive	Partial on articular side	Disinserted	No
7	44	30	Consultant	Tennis	Former professional	Complete	Disinserted	No
8	30	60	Student	Tennis	Recreational + competitive	Partial on articular side	Wear	Yes
9	39	65	Marketing	Tennis + volleyball	Recreational	Partial on articular side	Wear	No

TABLE 2
Pain Scores^a

Pain	Patient 1	Patient 2	Patient 3	Patient 4	Patient 5	Patient 6	Patient 7	Patient 8
Preoperative	3	3	7.5	7.5	4.5	6	4.5	4.5
Postoperative	13	13	10	15	14	13	2	14

^aPain scale: 0 represents maximum pain and 15 represents no pain.

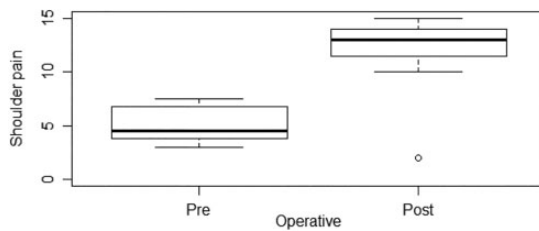


Figure 9. Boxplot comparison between pre- and postoperative pain.

surgeon. All patients had the same mobility on the surgical side as the normal side in anterior elevation. Moreover, we obtained positive results in external rotation with the elbow at the side and the elbow at 90°. There were 2 patients who still had a 20° impairment during this movement. All patients had equal internal rotation except 1 patient. Consequently, patients were able to correctly move their shoulder in daily life. No clinical instability was detected in any patient.

A total of 8 of 9 patients rated their strength as equal or greater to their preinjury strength. Also, 2 patients had a subjective sensation of abnormal joint mobility of the shoulder.

At final follow-up, 8 patients (88.9%) were able to return to the same sport: 4 at the same level (50.0%), 3 at a higher level (37.5%), and 1 (12.5%) at a lower level (see the Appendix). Approximately 55% had a KJOC score higher than 81. A KJOC score above 81.3 indicates with 95.1% accuracy that a patient has returned to play.¹ The mean KJOC score was 75 of 100 (range, 18-100). The athletes who stopped practicing their sport had KJOC scores of 30 and 18. However, the athlete with the worst outcome recently started practicing overhead-throwing sports again but at a lower level (see the Appendix). Even the patient with a rotator cuff tear was able to practice the same sport at the same level. There was 1 patient who changed his sport to swimming. Another patient recently stopped for degenerative acromioclavicular pain.

DISCUSSION

Currently, despite a large variety of surgical procedures, patients suffer persistent shoulder pain during sport activity after the surgical treatment of PSGI.¹¹ At our institution, 11 patients underwent posterior labral reattachment with glenoidplasty for PSGI. Data for 9 patients were available for analysis. Pre- and postoperative pain significantly differed. At a minimum 30-month follow-up, all but 1 patient suffered less pain. Moreover, the surgical procedure did not impair daily life and, for the majority of patients, the capacity to return to their previous sport. The percentage of patients who returned to their previous sport was 88.9% (8/9), with 77.8% returning at the same or higher level (Table 3). Therefore, posterior labral reattachment was able to improve the benefit of glenoidplasty by decreasing pain.

From the literature, we note a variety of surgical techniques (Table 3). The efficiency of surgery on athletes' pain varies depending on the study. Lévine et al⁸ showed 8 of 26 professional athletes with residual pain during sport (30.8%), and Meister et al⁹ showed 8 of 18 with persistent pain after surgery (44.4%). In the study by Sonnery-Cottet et al,¹² 91% of patients continued to experience pain during sport, despite their ability to return to playing tennis.

To our knowledge, this is the first study to detail both pre- and postoperative pain. Most studies do not report preoperative data so they are unable to analyze the benefits of surgery on shoulder pain. Moreover, residual shoulder pain in 1 patient (patient 7) did not affect his daily life. Shoulder pain score and impairment in daily life are perhaps not associated, but we lack data to prove this hypothesis.

In our study, 77.8% of patients were able to return to their previous sport at the same or higher level. This result was higher than that found in other studies, but this improvement may not be significant. A mean of 48% of patients in the literature were able to return to their previous sport. This difference can possibly be explained by the fact that our cohort was small and our patients were mostly

TABLE 3
Comparison of Studies

Author (Year)	Patients, n	Ability to Return to Previous Level in Same Sport, n (%)	Mean Follow-up, mo	Surgical Procedure
Meister et al ⁹ (1999)	18	10 (55.6)	75.6	Debridement of rotator cuff and labral tears
Payne et al ¹⁰ (1997)	29	Unknown, but 13 (44.8) were able to return to previous sport	24	Arthroscopic debridement of tears
Sonnery-Cottet et al ¹² (2002)	22	Unknown, but 22 (100) were able to return to previous sport	45.7	Arthroscopic debridement of supraspinatus tendon and glenoid lesions
Lévine et al ⁸ (2012)	22	18 (81.8)	47	Arthroscopic debridement of tendinous and labral lesions + abrasion of bony posterior rim or glenoidplasty
Current study	9	7 (77.8)	53	Arthroscopic debridement of supraspinatus tendon and glenoid lesions + glenoidplasty + posterior labral fixation

recreational athletes; their sport practice is thus less demanding.

We found no association between postoperative shoulder pain and return to sports activity. For example, patient 7 had the worst postoperative shoulder pain but was able to return to his previous sport with slight impairment. However, patients 1 and 5 had good results for postoperative pain but were unable to return to their previous sport. We used the Wilcoxon test to analyze the correlation between returning to sports activity and shoulder pain. The analysis found nonsignificant results. Postoperative shoulder pain did not affect the capacity to return to sport.

To our knowledge, this is the first monocentric study to report these results. Moreover, surgery for this shoulder disorder is infrequent and is usually treated by physical therapy.

Apart from our small number of patients, other limitations include the subjective measure of clinical outcomes performed by only 1 examiner and the absence of a comparison between different treatment groups. In fact, further comparative investigations are needed to confirm the benefit of posterior labral fixation during glenoidplasty for PSGI.

CONCLUSION

PSGI is a condition mostly treated by rehabilitation. Surgery results reported in the literature have demonstrated imperfect clinical outcomes. In our study, the addition of posterior labral fixation to glenoidplasty demonstrated an efficient reduction of shoulder pain and good functional outcomes. Our conclusions suggest that glenoidplasty and associated posterior labral fixation should be considered as a surgical procedure for this condition.

REFERENCES

1. Alberta F, ElAttrache NS, Bissell S, et al. The development and validation of a functional assessment tool for the upper extremity in the overhead athlete. *Am J Sports Med.* 2010;38(5):903-911.
2. Burkhart SS, Morgan CD, Kibler WB. The disabled throwing shoulder: spectrum of pathology. Part I: pathoanatomy and biomechanics. *Arthroscopy.* 2003;19(4):404-420.
3. Constant CR, Murley AH. A clinical method of functional assessment of the shoulder. *Clin Orthop Relat Res.* 1987;214:160-164.
4. Corpus KT, Camp CL, Dines DM, Altchek DW, Dines JS. Evaluation and treatment of internal impingement of the shoulder in overhead athletes. *World J Orthop.* 2016;7(12):776-784.
5. Fessa CK, Peduto A, Linklater J, Tirman P. Posterosuperior glenoid internal impingement of the shoulder in the overhead athlete: pathogenesis, clinical features and MR imaging findings. *J Med Imaging Radiat Oncol.* 2015;59(2):182-187.
6. Heyworth BE, Williams RJ. Internal impingement of the shoulder. *Am J Sports Med.* 2009;37(5):1024-1037.
7. Jobe CM. Posterior superior glenoid impingement: expanded spectrum. *Arthroscopy.* 1995;11(5):530-536.
8. Lévine C, Garret J, Grosclaude S, Borel F, Walch G. Surgical technique arthroscopic posterior glenoidplasty for posterosuperior glenoid impingement in throwing athletes. *Clin Orthop Relat Res.* 2012; 470(6):1571-1578.
9. Meister K, Andrews JR, Batts J, Wilk K, Baumgarten T. Symptomatic thrower's exostosis: arthroscopic evaluation and treatment. *Am J Sports Med.* 1999;27(2):133-136. Erratum in: *Am J Sports Med.* 1999;27(3):379.
10. Payne LZ, Altchek DW, Craig EV, Warren RF. Arthroscopic treatment of partial rotator cuff tears in young athletes: a preliminary report. *Am J Sports Med.* 1997;25(3):299-305.
11. Riand N, Boulahia A, Walch G. [Posterosuperior impingement of the shoulder in the athlete: results of arthroscopic debridement in 75 patients]. *Rev Chir Orthop Reparatrice Appar Mot.* 2002;88(1):19-27.
12. Sonnery-Cottet B, Edwards TB, Noel E, Walch G. Results of arthroscopic treatment of posterosuperior glenoid impingement in tennis players. *Am J Sports Med.* 2002;30(2):227-232.
13. Walch G, Liotard JP, Boileau P, Noël E. [Postero-superior glenoid impingement: another shoulder impingement]. *Rev Chir Orthop Reparatrice Appar Mot.* 1991;77(8):571-574.

APPENDIX

TABLE A1
Results of Online Questionnaire^a

Question	Patient 1	Patient 2	Patient 3	Patient 4	Patient 5	Patient 6	Patient 7	Patient 8	Patient 9
What is your subjective opinion on the results of surgery?	Disappointed	Very satisfied	Very satisfied	Very satisfied	Disappointed	Very satisfied	Satisfied	Very satisfied	Satisfied
Did you have any complications after surgery?	No	No	No	No	No	No	Yes, capsulitis	No	No
Postoperative pain: How would you grade your shoulder pain, if 0 represents the maximum pain and 15 no pain?	13	13	10	15	14	13	2	14	15

(continued)

TABLE A1 (continued)

Question	Patient 1	Patient 2	Patient 3	Patient 4	Patient 5	Patient 6	Patient 7	Patient 8	Patient 9
Activity: Do you feel any impairment in professional activity or daily life? (grade 0-4)	0	0	0	0	0	0	0	0	0
Do you feel any impairment in sport activity? (grade 0-4)	3	0	0	0	4	0	1	0	0
Do you feel any impairment at night?	No	No	No	No	Yes	No	No	No	No
What level do you reach for during activity (belt, chest, neck, head, or overhead)?	Overhead	Overhead	Overhead	Overhead	Overhead	Overhead	Overhead	Overhead	Overhead
Mobility: Do you have the same mobility as before surgery or compared to the other side if normal in the following position?									
Anterior elevation	Yes	Yes	Yes	Yes	Yes	Yes	Yes	Yes	Yes
External rotation with the elbow at the side	Yes	Yes	Yes	No	Yes	Yes	No	Yes	Yes
Internal rotation with the hand on the back	Yes	Yes	Yes	Yes	Yes	Yes	No	Yes	Yes
Stability: Do you feel any instability of your shoulder or abnormal joint mobility?	No	No	No	No	Yes	No	No	No	Yes
SST score	10	12	12	12	9	12	12	12	10
Strength: How do you qualify the strength of your shoulder: less, same, or more than preoperatively or compared with the other side if normal?	Same strength	Same strength	More strength	More strength	Less strength	Same strength	Same strength	More strength	More strength
Sport practice: Did you return to the same sport after surgery?	No, then yes at last follow-up	Yes	Yes	Yes	No	Yes	Yes	Yes	Yes
If yes, how do you qualify your level: inferior, same, or superior to preoperatively? If not, which sport do you practice?	Inferior level; practiced biking (temporarily)	Same level	Higher level	Higher level	Different sport (swimming)	Same level	Same level	Higher level	Same level; recently stopped for acromioclavicular pain
KJOC score	18	100	100	74	30	100	87	100	61

^aKJOC, Kerlan-Jobe Orthopaedic Clinic; SST, Simple Shoulder Test.