

Hepatitis C mixed cryoglobulinemia with undetectable viral load: A case series



Virginia Kartha, MD,^a Luisa Franco, MD,^b Susan Coventry, MD,^{c,d} Kenneth McLeish, MD,^b
Dawn J. Caster, MD,^b and Courtney R. Schadt, MD^a
Louisville, Kentucky

Key words: hepatitis C mixed cryoglobulinemia vasculitis; undetectable viral load.

INTRODUCTION

Mixed cryoglobulinemic vasculitis is caused by circulating cold-precipitable immunoglobulins, or cryoglobulins, composed of monoclonal (type II) or polyclonal (type III) IgM directed against a polyclonal IgG. It causes palpable purpura and has long been associated with hepatitis C virus (HCV) infection. The initial theory regarding the new antiviral medications, which have been so successful in treating hepatitis C, was that once the HCV was treated, the mixed cryoglobulinemic vasculitis would also resolve. Although initial studies confirmed this theory, later studies found that the vasculitis is persistent in some patients despite successful HCV treatment. Vasculitis occurred within months after treatment of HCV infection in most cases in the literature, but we present 3 cases of mixed cryoglobulinemic vasculitis months to years after successful HCV treatment and negative viral load and a review of the current literature.

REPORT OF CASES

Case 1

A 54-year-old man with history of hepatitis C treated with peginterferon α -2a, ribavirin, and telaprevir with undetectable viral load since 2012, presented in February 2016 with a rash on his legs for 6 weeks. He presented with a similar rash annually for about 4 years, which was diagnosed as vasculitis and successfully treated with prednisone each time. Physical examination showed erythematous nonblanching papules and patches on his lower

Abbreviations used:

DAA: direct-acting antiretrovirals
HCV: hepatitis C virus
LCV: leukocytoclastic vasculitis

legs and medial thighs (Fig 1). Punch biopsy results were consistent with leukocytoclastic vasculitis (LCV), and direct immunofluorescence showed an IgM-mediated vascular inflammatory process. Laboratory values showed positive rheumatoid factor and cryoglobulins. His HCV viral load was undetectable. He was given 2 prednisone tapers followed by 2 infusions of 1 g of rituximab separated by 2 weeks with gradual improvement. Four months after his last rituximab infusion, the patient had another flare of cutaneous vasculitis and was treated with a prednisone taper and 2 additional rituximab infusions. His skin remained clear at last follow-up.

Case 2

A 51-year-old white man with a 1-year history of LCV presented with positive type II cryoglobulins and HCV viral load of 1.9 million IU/mL in December 2009. Over the next 2 years, he was admitted for renal failure multiple times owing to cryoglobulinemia, treated with plasmapheresis, intravenous immunoglobulin, and rituximab. His HCV was treated with peginterferon α -2a and ribavirin twice, with telaprevir added on the second round, completed in 2012.

From the Departments of Dermatology,^a Medicine (Division of Nephrology),^b and Pathology,^c University of Louisville and Norton Children's Hospital.^d

Funding sources: None.

Conflicts of interest: Dr Caster receives research support from Mallinckrodt pharmaceuticals and support from the National Institutes of Health 1K08DK102542-01A1. The rest of the authors have no conflicts to disclose.

Correspondence to: Virginia Kartha, MD, University of Louisville, Department of Dermatology, 3810 Springhurst Boulevard, Louisville, Kentucky 40059. E-mail: Virginia.kartha@gmail.com.

JAAD Case Reports 2018;4:684-7.
2352-5126

© 2018 by the American Academy of Dermatology, Inc. Published by Elsevier, Inc. This is an open access article under the CC BY-NC-ND license (<http://creativecommons.org/licenses/by-nc-nd/4.0/>).

<https://doi.org/10.1016/j.jidcr.2018.04.004>

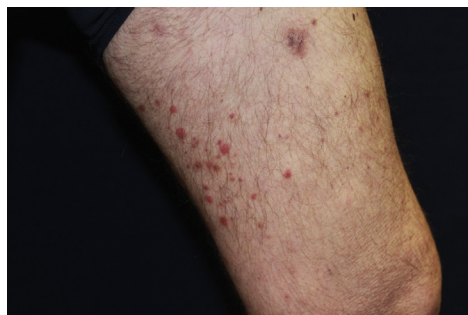

Fig 1. Mixed cryoglobulinemic vasculitis. Patient 1: physical examination found erythematous nonblanching papules and patches on lower legs and medial thighs.

All subsequent measurements of HCV viral load showed undetectable levels. However, he continued to have admissions for acute kidney injury, fevers, and rash associated with positive serum cryoglobulins whenever attempts were made to reduce plasmapheresis treatments to fewer than once a week. He was started on cyclophosphamide and corticosteroids in June 2013 in addition to continuation of weekly plasmapheresis, in an attempt to reduce cryoglobulin production. He was subsequently treated with azathioprine, cyclophosphamide, mycophenolate mofetil, and finally rituximab in 2015. This treatment led to a brief remission of symptoms, but rituximab was required again after a relapse in May 2016. Rituximab has improved clinical symptoms, but the patient remains plasmapheresis dependent.

Case 3

A 60-year-old white woman with a history of LCV manifested as livedo reticularis, mixed cryoglobulinemia (MC), and HCV treated with ribavirin and peginterferon α -2a presented in 2015 with livedo reticularis, increased creatinine, and proteinuria. Her HCV viral load had been undetectable since treatment was completed in 2009 and remained undetectable during this acute flare of MC. A kidney biopsy found membranoproliferative glomerulonephritis with features suggestive of cryoglobulinemic glomerulonephritis (Fig 2). Kidney electron micrograph showed granular to coarsely granular subendothelial and mesangial deposits, suggestive but not diagnostic for cryoglobulinemia (Fig 3). She was treated with corticosteroids and 4 doses of 500 mg of rituximab weekly, after which the rash resolved, and rheumatoid factor, complement levels, and urine protein returned to normal. Ten months later, she remained asymptomatic, and laboratory evaluation for cryoglobulinemia was negative (See Table 1 for a

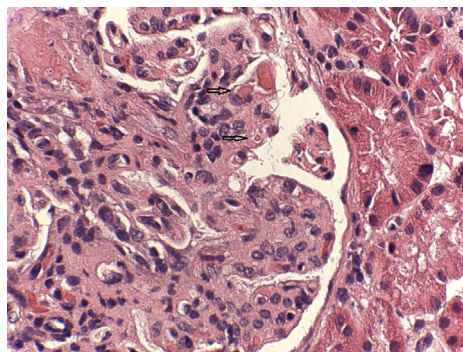


Fig 2. Cryoglobulinemic glomerulonephritis. Patient 3: kidney biopsy found membranoproliferative glomerulonephritis with cryoglobulin plugs/hyaline thrombi (arrows), suggestive of cryoglobulinemic glomerulonephritis. (Hematoxylin-eosin stain; original magnification: $\times 60$.)

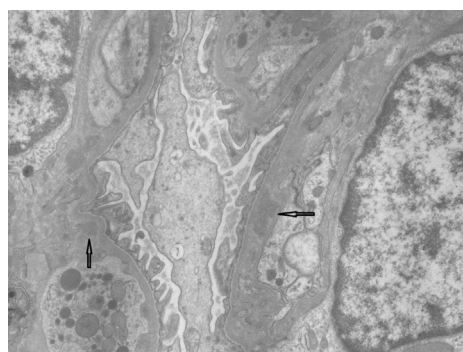


Fig 3. Cryoglobulinemia. Patient 3: electron microscopy. Kidney electron micrograph shows granular to coarsely granular subendothelial and mesangial deposits (arrows) suggestive of but not diagnostic for cryoglobulinemia.

summary of these cases in addition to a summary of cases in the literature.).

DISCUSSION

With the advent of direct-acting antiretrovirals (DAA) for hepatitis C infection, many patients who would have otherwise had chronic hepatitis C and the long-term sequela have had sustained viral response and clinical remission of disease. Direct-acting antiretrovirals are molecules that target specific nonstructural proteins of the virus and result in disruption of viral replication and infection. The first DAAs for hepatitis C were protease inhibitors, telaprevir and boceprevir, usually used in conjunction with peginterferon and ribavirin.¹ These are rarely used now because of the introduction of more potent and better-tolerated DAAs, which can be used without interferon, and, in many cases, ribavirin.

MC is an autoimmune disorder associated with hepatitis C that has significant morbidity and mortality.² Historically, renal involvement is found to be the

Table I. Three presented cases and review of cases from the literature

Patient	Age, sex	Skin disease	HCV treatment	Sustained viral response	MC treatment	Time between SVR and persistent MC
Case 1	54, M	Yes, LCV	Peginterferon α -2a, ribavirin, telaprevir	Yes	Corticosteroids, rituximab	4 y
Case 2	51, M	Yes, LCV	Peginterferon α -2a, ribavirin, telaprevir	Yes	Plasmapheresis, IVIg, rituximab, cyclophosphamide, azathioprine, mycophenolate mofetil	4 y, still persistent despite weekly plasmapheresis
Case 3	60, F	Yes, livedo reticularis, LCV	Ribavirin and peginterferon α -2a	Yes	Rituximab, azathioprine, plasmapheresis, corticosteroids	6 y
Sollima et al, ⁵ case 1	73, F	Purpura	Ombitasvir, paritaprevir, ritonavir and dasabuvir	Yes	Peginterferon/ribavirin and rituximab or rituximab alone	<12 wk
Sollima et al, ⁵ case 2	72, F	Purpura, skin ulcers	Ombitasvir, paritaprevir, ritonavir and dasabuvir	Yes	Peginterferon/ribavirin and rituximab or rituximab alone	<12 wk
Sollima et al, ⁵ case 3	58, F	Purpura	Sofosbuvir, ribavirin	Yes	Peginterferon/ribavirin and rituximab or rituximab alone	<12 wk
Sollima et al, ⁵ case 5	46, M	None listed	Sofosbuvir, daclatasvir	Yes	Peginterferon/ribavirin and rituximab or rituximab alone	<12 wk
Sollima et al, ⁵ case 6	54, M	Purpura	Sofosbuvir, ribavirin	Yes	Peginterferon/ribavirin and rituximab or rituximab alone	20 wk
Sollima et al, ⁵ case 7	71, M	Purpura, skin ulcers	Sofosbuvir, daclatasvir	Yes	Peginterferon/ribavirin and rituximab or rituximab alone	<12 wk
Levine et al, ⁶ case 1	49, M	Lower extremity ulcerations	Peginterferon α -2a and ribavirin	Yes	Rituximab	4 mo
Levine et al, ⁶ case 2	48, M	Rare intermittent crops of inflammatory purpura	IFN- α monotherapy	Yes	None listed	18 mo
Levine et al, ⁶ case 3	52, F	Lower extremity purpura	Peginterferon α -2a and ribavirin	Yes	Prednisone, rituximab, dialysis and plasmapheresis	1 y
Levine et al, ⁶ case 4	52, F	LCV	IFN and ribavirin	Yes	None listed	Time not given
Ghosn et al, ⁷ case 1	81, F	LCV on abdomen and lower extremities	Simeprevir	Yes	Prednisone, plasma exchange, rituximab	4-10 mo
Ghosn et al, ⁷ case 2	24, F	Rash on lower extremities, abdomen, buttocks	Ribavirin, peginterferon α -2a, and sofosbuvir	Yes	Prednisone, rituximab	1 y

Sollima's fourth patient did not have recurrence of MC vasculitis so was not included in the table.
 IFN, Interferon; IVIg, intravenous immunoglobulin; SVR, sustained viral response.

leading cause of mortality. Other poor prognostic factors include age greater than 60 years, intestinal ischemia, pulmonary hemorrhage, and high cryocrit levels. Mortality has also been linked to lymphoma, cardiovascular disease, hepatocellular carcinoma, and liver disease.²

Initial studies regarding MC and newer treatment modalities showed that response to antivirals was associated with significantly reduced mortality risk.² Gragnani et al³ reported in 2015 that MC was a negative prognostic factor of virologic response to pegylated interferon plus ribavirin treatment but that those who cleared HCV had persistent resolution or improvement of the MC syndrome. In 2016, Gragnani et al⁴ reported a 100% rate of clinical response of MC vasculitis with successful treatment of hepatitis C with DAA. However, recent articles report persistent MC vasculitis despite eradication of the hepatitis C virus.⁵⁻⁷ Most of the cases in the literature occurred within months of treatment of HCV, so the presented cases are notable because of the length of time between clearance of HCV and MC vasculitis (4 to 6 years, see Table 1). Case 2 is also notable in that the patient's disease was severe and recalcitrant to any treatments, including plasmapheresis, intravenous immunoglobulin, rituximab, cyclophosphamide, azathioprine, and mycophenolate mofetil.

It is unclear why some patients with MC vasculitis have resolution of symptoms with successful treatment of hepatitis C and some do not. Sollima et al⁵ suggested several hypotheses including greater severity and more advanced stage of MC vasculitis, delayed clearance of circulating cryoglobulins compared with HCV clearance, or incomplete suppression of B-cell clonal proliferation driving cryoglobulin production. Delayed clearance of circulating cryoglobulins seems unlikely in our presented cases given the length of time between undetectable viral load and presentation of recurrent MC vasculitis (4 years in cases 1 and 2, 6 years in case 3). Patients 1 and 3 both had resolution of cryoglobulinemia and clinical symptoms with multiple courses of rituximab, suggesting a B-cell process; however, patient 3 continues to suffer from MC vasculitis despite multiple courses of rituximab and other immunosuppressants.

There are several other possible explanations for persistent MC. Consider HIV, in which there is a reservoir of the virus in tissue despite an undetectable viral load. A recent study evaluated pathologic tissues at autopsy from patients with antiretroviral-treated HIV with undetectable viral load, and showed that HIV DNA was present in 48 of 87 brain

tissues and 82 of 142 nonbrain tissues, including spleen, lung, lymph nodes, liver, aorta, and kidney. No patients were completely free of tissue HIV.⁸ Although the phenomenon of reactivation of infection does not occur with HCV as it does with HIV, it is possible that such a reservoir, in tissue or in the B cells themselves, could be periodically activating the immune system and causing production of cryoglobulins. There could also be persistent but inactive circulating viral particles despite sustained viral response, causing such a reaction. Conversely, the virus may be completely cleared, but the immune system may have been primed in some way by the HCV to continuously or episodically produce cryoglobulins.

It is important for practitioners to keep in mind that undetectable viral load and sustained viral response after successful hepatitis C treatment does not rule out MC vasculitis, even 6 years later. Given the evidence that successful treatment may reduce morbidity and mortality of MC vasculitis, treatment of HCV with DAAs is still important to these patients' care; however, further monitoring and treatment of MC vasculitis is indicated if clinical symptoms persist.

REFERENCES

- Poordad F, Dieterich D. Treating hepatitis C: current standard of care and emerging direct-acting antiviral agents. *J Viral Hepatitis*. 2012;19(7):1365-2893.
- Landau D, Scerra S, Sene D, Resche-Rigon M, Saadoun D, Cacoub P. Causes and predictive factors of mortality in a cohort of patients with hepatitis C virus-related cryoglobulinemic vasculitis treated with antiviral therapy. *J Rheumatol*. 2010;37:3. <https://doi.org/10.3899/jrheum.090790>.
- Gragnani L, Fognani E, Piluso A, et al. Long-term effect of HCV eradication in patients with mixed cryoglobulinemia: a prospective, controlled, open-label, cohort study. *Hepatology*. 2015;61(4):1145-1153.
- Gragnani L, Visentini M, Fognani E, et al. Prospective study of guideline-tailored therapy with direct-acting antivirals for hepatitis C virus-associated mixed cryoglobulinemia. *Hepatology*. 2016;64(5):1473-1482.
- Sollima S, Milazzo L, Peri AM, Torre A, Antinori S, Galli M. Persistent mixed cryoglobulinaemia vasculitis despite hepatitis C virus eradication after interferon-free antiviral therapy. *Rheumatology*. 2016;55:2084-2085.
- Levine JW, Gota C, Fessler BJ, Calabrese LH, Cooper SM. Persistent cryoglobulinemic vasculitis following successful treatment of hepatitis C virus. *J Rheumatol*. 2005;32(6):1164-1167.
- Ghosn M, Palmer MB, Najem CE, Haddad D, Merkel PA, Hogan JJ. New-onset hepatitis C virus-associated glomerulonephritis following sustained virologic response with direct-acting antiviral therapy. *Clin Nephrol*. 2016;87(5):261-266.
- Lamers SL, Rose R, Maidji E, et al. HIV DNA is frequently present with pathologic tissues evaluated at autopsy from combined antiretroviral therapy-treated patients with undetectable viral load. *J Virol*. 2016;90(20):8968-8983.