

# Intermuscular pterygoid-temporal abscess following inferior alveolar nerve block anesthesia—A computer tomography based navigated surgical intervention: Case report and review

## Access this article online

### Website:

www.amsjournal.com

### DOI:

10.4103/2231-0746.133090

### Quick Response Code:



Jürgen Wallner, Knut Ernst Reinbacher, Mauro Pau, Matthias Feichtinger

Department of Maxillofacial Surgery, Medical University of Graz, Graz, Austria

### Address for correspondence:

Dr. Jürgen Wallner, Department of Oral and Maxillofacial Surgery,  
Medical University of Graz, Auenbruggerplatz 5, A-8010 Graz, Austria.

E-mail: juergenwallner@msn.com

## ABSTRACT

Inferior alveolar nerve block (IANB) anesthesia is a common local anesthetic procedure. Although IANB anesthesia is known for its safety, complications can still occur. Today immediately or delayed occurring disorders following IANB anesthesia and their treatment are well-recognized. We present a case of a patient who developed a symptomatic abscess in the pterygoid region as a result of several inferior alveolar nerve injections. Clinical symptoms included diffuse pain, reduced mouth opening and jaw's hypomobility and were persistent under a first step conservative treatment. Since image-based navigated interventions have gained in importance and are used for various procedures a navigated surgical intervention was initiated as a second step therapy. Thus precise, atraumatic surgical intervention was performed by an optical tracking system in a difficult anatomical region. A symptomatic abscess was treated by a computed tomography-based navigated surgical intervention at our department. Advantages and disadvantages of this treatment strategy are evaluated.

**Keywords:** Abscess, complication, computed tomography-based navigated surgical intervention, inferior alveolar nerve block anesthesia

## INTRODUCTION

Local anesthetics are considered to be safe medications with low incidence of complications.<sup>[1]</sup> Although inferior alveolar nerve block (IANB) anesthesia is known for its safety, complications can still occur.<sup>[2]</sup> Above all pain is the most common complication after local anesthesia.<sup>[3]</sup> Immediately or delayed occurring disorders such as trismus, sensory deficit, needle breakage, facial nerve palsy, neurologic deficit, abscess formation and others following IANB anesthesia are described in the literature in certain reports.<sup>[2,4-10]</sup> A conservative therapy is prescribed as a first step by the application of heat, stretching the muscle, prescription of analgesics, antibiotics or muscle relaxants. If there is no response to therapy differential diagnosis must be

expanded to avoid possible serious complications (deep space infection, surface ulceration etc.).<sup>[6,11,12]</sup> Although the incidence of serious or even life-threatening complications following IANB anesthesia is considered to be low, their possible occurrence warrants caution.<sup>[13]</sup> In this case, the patient did not respond to the initiated conservative therapy we thought of an interventional and simultaneously atraumatic treatment as a second step.

Since image-based navigated interventions are used for various procedures such as multimodal image fusion, abdominal biopsy, nerve root infiltration etc., and offer several advantages (e.g. 3D imaging, operation planning and image guidance)<sup>[14-17]</sup> we thought about an image-based navigated surgical intervention in a difficult anatomical region as a second step therapy.

This case report features a symptomatic pterygoid abscess that may have resulted from several inferior alveolar nerve injections and was treated by a computed tomography (CT)-based navigated surgical intervention.

## CASE REPORT

The present case report is about a 35-year-old man in good general condition referred to our out-patient clinic from a local dentist. He had noticed reduced mouth opening, increasing restriction in the jaw's latero- and protrusion movement, a right deviation during mouth-opening and diffuse pain in the right lower jaw since 2 months [Figure 1]. He had been given IANB anesthesia of 2% lidocaine with epinephrine 3-4 times by his dentist as a part of routine restoration (root canal treatment for tooth 46) 2-3 months ago. The anesthetic effect subsided normally. On clinical examination, neither lymphadenopathy nor enoral swelling was detected. Furthermore, the white blood cell count was inconspicuous. An already existing fat saturated 2T-weighted magnetic resonance imaging (MRI) performed at a local hospital showed a 2 cm × 1.7 cm × 2.4 cm sharp defined hypointense mass of 7 mm diameter and an intense contrast enhancement lateral to the right lateral pterygoid muscle and medial to the right temporal muscle [Figure 2]. Although the right temporal muscle appeared slightly edematous in the MRI, bony structures of the jaw were not affected by the expansive process and seemed inconspicuous.

Furthermore antibiotic treatment had been prescribed initially followed by a local incision and drainage; both met with only little success. Clinical symptoms (reduced mouth opening, jaw's hypomobility, diffuse pain etc.) did not decrease.

Since symptoms were nearly unchanged under conservative treatment we thought about a surgical exploration to identify the nature and the exact location of the radiologically seen lesion.

### Preoperative concept and data acquisition

Due to the difficult close relationship of the lesion to the inferior alveolar nerve, the lingual as also the buccal nerve and its unclear defined anatomical location between the temporal muscle and the lateral pterygoid muscle an interventional treatment by a navigated surgical excision in general anesthesia is a reliable solution to explore the expansive process by missing clear clinical points of reference and reducing the risk of an iatrogenic injury. For virtual operation access planning and intraoperative navigation we used a commercially available passive optical tracking system<sup>[18]</sup> which is also used for multimodal image fusion techniques (positron emission tomography/CT etc.) or control of resection margins in the head and neck cancer surgery.<sup>[16,17,19]</sup> The optical navigation system is based on the three infrared light diodes, an infrared position sensor camera and a dynamic reference frame, which is attached to the patient (as a body fixed patient-to-image navigation reference tool). A passive navigation probe (marker tool) can be used to determine the actual surgeon's position by tipping on the operation field. Through infrared light signal reflection by the passive navigation probe the correct marker's position is displayed on the workstation's monitor. Thus direct intraoperative and interactive visualization to ensure high navigation accuracy is provided. Infrared-optical tracking requires a direct visual contact between the reference

frame and the camera ("line of sight" principle). Furthermore this technique improves the operator's flexibility because this tracking method works wireless.<sup>[16]</sup>

In our case, the navigated surgical intervention was planned on CT-planes and digital imaging and communications in medicine (DICOM) CT-datasets, because CT-imaging is known as one of the reference imaging modalities for treatment planning.<sup>[20]</sup> A high-resolution planning CT (Imatron Electron Beam Tomography, Siemens, Forchheim, Germany, slice thickness 3 mm) with an individual dental splint (used as a reference tool for a patient-to-image registration) was performed at our department. The CT described the lesion as a clear reason for the mouth opening restriction and the jaws' reduced latero- and protrusion movement caused by an expansive intermuscular process. The performed CT-data sets (standard DICOM files) were preoperatively transferred to the navigation workstation (StealthStation TREON plus, Louisville, USA) and were reconstructed in a three-plane view (coronal, axial and sagittal) by the navigation system's software (StealthMerge™, Medtronic, Louisville, USA). Thus the lesion was visualized as a clear anatomical target on the system's navigation monitor in a multiplanar (axial, coronal and sagittal) image formation [Figures 3 and 4].

### Surgical intervention

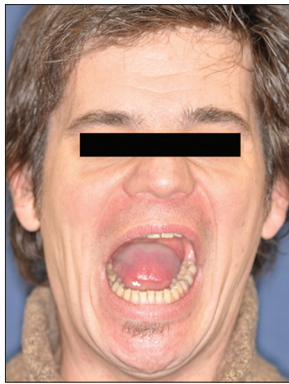After intubation a dynamic reference frame was fixed with screws on the patient's skull [Figure 5] in visual contact with the three infrared cameras of the navigation workstation ("line of sight"). Thus a patient-to-image registration was aimed by using the dental splint as reference tool between the patient and the reconstructed CT-scans displayed on the navigation-system's monitor to exclude any occurring navigation inaccuracy. Furthermore the navigation probe was calibrated for intraoperative CT-tracking and direct visualization on the workstation's monitor by touching the operation field [Figures 6 and 7].

Intraoperatively the surgical approach was performed as a sharp 3.5 cm lasting enoral incision vertical to the right ascending mandibular ramus. Then a subperiosteal preparation was done carefully along the ascending mandibular ramus up to the lingula to protect the vascular and nerve bundle in this area. The right lateral pterygoid muscle was spread under CT-based navigation and the inferior alveolar nerve was depicted carefully.

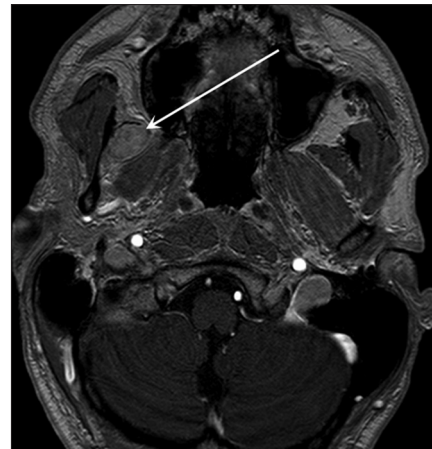In between the two muscles a macroscopic capsulated expansion was bluntly enucleated. It partly appeared as a compact nodular lesion that was surrounded by muscular structure within a scarred intergrowth of the lateral pterygoid muscle. Under direct visual control using the navigation probe [Figure 8] the described lesion and the surrounding capsulated structure could be excised completely as one specimen [Figure 9].

### Histological report

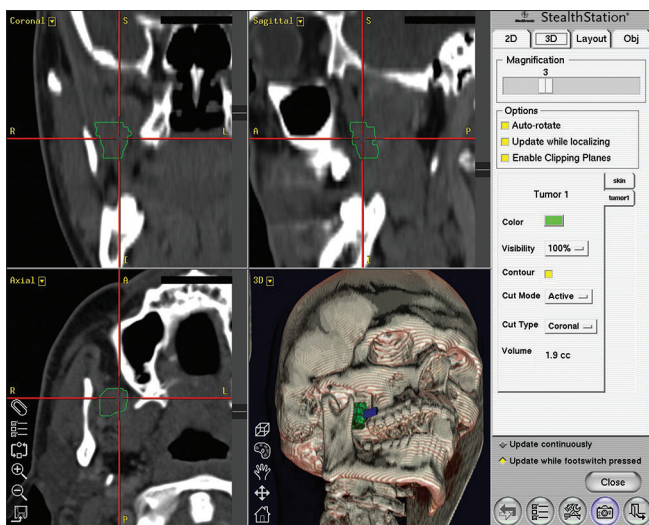
Postoperatively the microscopic examination (after hematoxylin and eosin staining) confirmed scar tissue and granulation-like partly destroyed muscular structures consistent with an inflammatory genesis. As for exclusion of fibromatosis antibody-based immunohistochemical examination against beta-catenin showed no nuclear expression. Furthermore no malignancy was found.



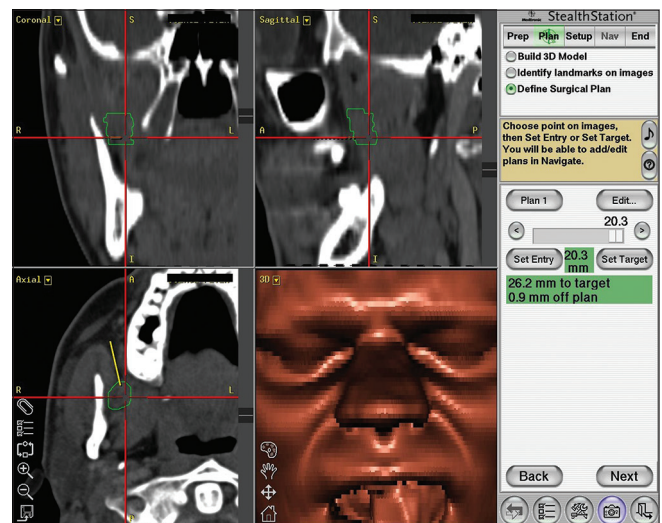
**Figure 1:** On clinical examination reduced mouth opening, increasing restriction in the jaw's latero- and protrusion movement, a right deviation while opening and diffuse pain in the right lower jaw had been noticed since 2 months following inferior alveolar nerve block anesthesia



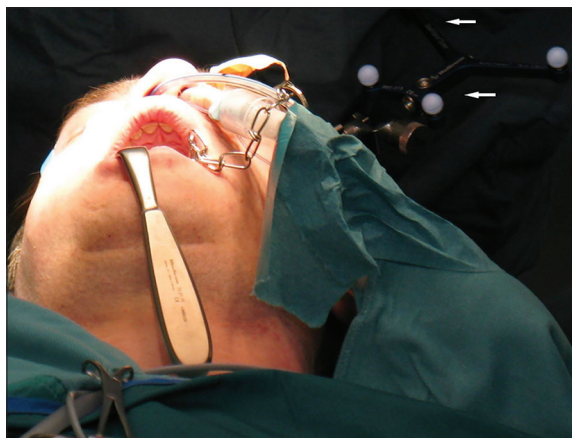
**Figure 2:** Magnetic resonance imaging-scan; a 2 cm × 1.7 cm × 2.4 cm sharp defined hypointense suspect mass of 7 mm diameter was detected lateral to the right lateral pterygoid muscle and medial to the right temporal muscle



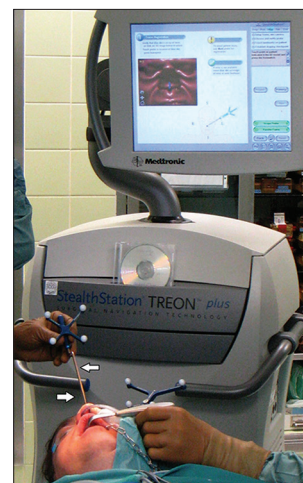**Figure 3:** Reconstruction of high resolution computed tomography-data sets (digital imaging and communications in medicine files) on the navigation workstation (StealthStation TREON plus, Louisville, USA). Reconstruction was depicted in a three-plane view (coronal, axial and sagittal) by the navigation system's software (StealthMerge™, Medtronic and Louisville, USA). The lesion was visualized as a clear anatomical target for virtual operation access planning



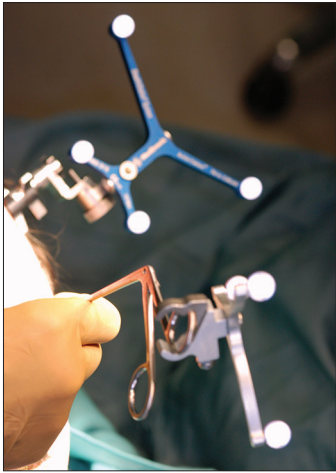
**Figure 4:** Preoperative surgical operation access planning in a three plane view on the navigation workstation



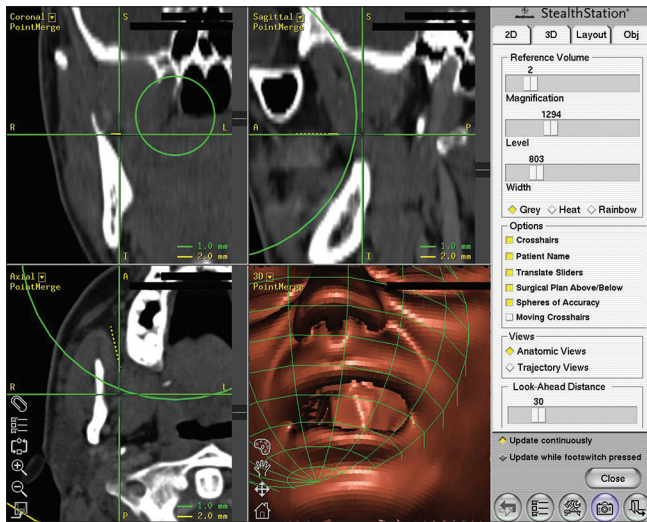
**Figure 5:** Dynamic reference frame fixed with screws on the patient's skull in contact with the navigation workstation ("line of sight")



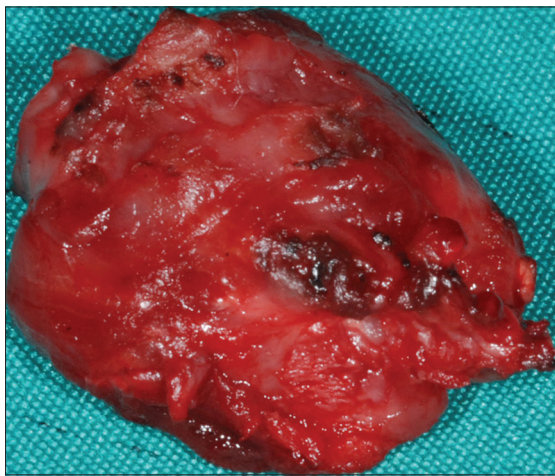
**Figure 6:** Navigation workstation. The navigation probe was calibrated for intraoperative computed tomography-tracking and direct visualization on the workstation's monitor by touching the operation field



**Figure 7:** Navigation probe (front) and reference frame fixed on the patient's skull (back)



**Figure 8:** Intraoperative navigation; simultaneous, multiplanar (coronal, axial and sagittal) view of the marked lesion



**Figure 9:** The lesion and the surrounding capsulated structure could be excised completely as one specimen under direct visual control using the navigation system

### Postoperative procedure

No considerable problem other than swelling and hematoma occurred intra- or postoperatively. Hematoma did not require drainage. The patient reported minimal postoperative pain. Mouth opening improved during postoperative follow-up and additional physiological training. Periodically antiseptic drainages and antibiotic treatment were performed. Although our patient was in an excellent general condition after surgical treatment he was followed-up in close-meshed clinical controls at our out-patient department. Jaw mobility and mouth opening without restriction as also the complete loss of clinical infection signs were detected 4 months after surgical intervention. A postoperative performed MRI confirmed the total removal of the lesion and showed inconspicuous anatomical structures.

## DISCUSSION

It's estimated that each week more than 6 million dental anesthetic cartridges are administered in the U.S.<sup>[3]</sup> Still, IANB anesthesia is considered to be a safe and well-known method.<sup>[2]</sup> Harn and Durham surveyed 9587 patients after they had received conventional IANB anesthesia and reported that 0.54% experienced post-injection complications.<sup>[21]</sup> An abscess formation may present first as progressive inability to open the mouth, diffuse pain or persistent hypomobility of the jaw. Abscess formation following IANB anesthesia is a rare complication, but is still reported in different anatomical regions in certain cases.<sup>[12-14]</sup> Maglione *et al.* reported about a masseteric mycotic abscess as a consequence of dental procedures.<sup>[12]</sup> A study by Dojcinovic *et al.* found an infracondylar abscess formation following a local dental injection.<sup>[22]</sup> Kitay *et al.* even reported about a lateral pharyngeal abscess as a life-threatening complication after IANB anesthesia.<sup>[13]</sup> The authors found that adequate treatment planning is necessary to administer the correct therapy.<sup>[12,13,22]</sup> The presence of long lasting trismus, pain and facial edema occurring after IANB anesthesia has to be carefully considered to diagnose and/or prevent a possible deep space infection.<sup>[12]</sup> The authors agree that the presence of trismus, facial edema and pain related to dental treatment has to be systematically evaluated.<sup>[12,13]</sup> Differential diagnosis should be expanded if only insufficient response to conservative therapy (superficial heat, analgesics, antibiotics, local incision etc.) is detected and a second step treatment should be initiated to avoid a further progression of symptoms.<sup>[3,11]</sup>

Nearly 10% of oro-facial infections arise from cutaneous, oro-pharyngeal or as in this case iatrogenic problems.<sup>[22]</sup> In our case, a syringe induced encapsulated inflammatory process may have caused progressive mouth opening restriction, diffuse pain and jaw deviation. According to the literature an occurring myospasm and resulting mouth opening restriction is more likely after several IANBs.<sup>[23]</sup> Furthermore higher concentrations of anesthetics are more harmful to muscle tissue.<sup>[24]</sup> Both happened in our case because of supplemental injections to provide adequate anesthesia.

A CT-based navigated surgical intervention offers several advantages: Navigation systems allow image based precise virtual preoperative planning, direct interactive visualization, 3D-imaging resulting in less traumatic and accurate surgery which is helpful when dealing with tiny lesions which are difficult to reach with conventional surgery procedures.<sup>[14,15]</sup>

Disadvantages are when using optical-based systems the possible occurring susceptibility of interference induced through light reflexes on metallic surfaces, the necessity of direct visualization (“line in sight”) between instruments and infrared cameras, the system’s registration error, the time required for set up (in our case about 20 min) and the system’s availability in terms of costs. Furthermore, knowledge about imaging, a preoperative CT-scan (CT-slices of < 3 mm to achieve adequate accuracy) and system’s registration methods are necessary for a successful and safe system’s application.<sup>[16,25-28]</sup> These are acceptable limitations if the navigation system leads to a successful surgical treatment.

## CONCLUSION

Abscess formation as a consequence of alveolar nerve anesthesia is rare, but still can occur. Persistent clinical symptoms (myospasm, reduced mouth opening, pain, edema etc.) have to be handled with caution. If no response to therapy is detected diagnosis and treatment strategy should be expanded, to avoid serious complications. If treatment is limited to non-surgical therapy a surgical intervention should be contemplated and should be planned based on adequate imaging modalities. An image-based navigated surgical intervention can be an important and helpful part in an accurate successful treatment planning and an atraumatic performance of a serious occurring complication following IANB anesthesia.

## REFERENCES

- Haas DA. Localized complications from local anesthesia. *J Calif Dent Assoc* 1998;26:677-82.
- Choi EH, Seo JY, Jung BY, Park W. Diplopia after inferior alveolar nerve block anesthesia: Report of 2 cases and literature review. *Oral Surg Oral Med Oral Pathol Oral Radiol Endod* 2009;107:e21-4.
- Malamed S. *Handbook of Local Anesthesia*. 5<sup>th</sup> ed. St. Louis: C.V Mosby Co.; 2004. p. 202, 285-92, 303.
- Shenkman Z, Findler M, Lossos A, Barak S, Katz J. Permanent neurologic deficit after inferior alveolar nerve block: A case report. *Int J Oral Maxillofac Surg* 1996;25:381-2.
- Ethunandan M, Tran AL, Anand R, Bowden J, Seal MT, Brennan PA. Needle breakage following inferior alveolar nerve block: Implications and management. *Br Dent J* 2007;202:395-7.
- Torrente-Castells E, Gargallo-Albiol J, Rodríguez-Baeza A, Berini-Aytés L, Gay-Escoda C. Necrosis of the skin of the chin: A possible complication of inferior alveolar nerve block injection. *J Am Dent Assoc* 2008;139:1625-30.
- Chevalier V, Arbab-Chirani R, Tea SH, Roux M. Facial palsy after inferior alveolar nerve block: Case report and review of the literature. *Int J Oral Maxillofac Surg* 2010;39:1139-42.
- Smyth J, Marley J. An unusual delayed complication of inferior alveolar nerve block. *Br J Oral Maxillofac Surg* 2010;48:51-2.
- Augello M, von Jackowski J, Grätz KW, Jacobsen C. Needle breakage during local anesthesia in the oral cavity – A retrospective of the last 50 years with guidelines for treatment and prevention. *Clin Oral Investig* 2011;15:3-8.
- Tzermpos FH, Cocos A, Klefogiannis M, Zarakas M, Iatrou I. Transient delayed facial nerve palsy after inferior alveolar nerve block anesthesia. *Anesth Prog* 2012;59:22-7.
- Wright EF. Medial pterygoid trismus (myospasm) following inferior alveolar nerve block: Case report and literature review. *Gen Dent* 2011;59:64-7.
- Maglione M, Angerame D, Costantinides F, Visintini E. Buccal-masseteric mycotic abscess as a consequence of dental procedures. *Minerva Stomatol* 2006;55:647-54.
- Kitay D, Ferraro N, Sonis ST. Lateral pharyngeal space abscess as a consequence of regional anesthesia. *J Am Dent Assoc* 1991;122:56-9.
- Vannier MW, Marsh JL. Three-dimensional imaging, surgical planning and image-guided therapy. *Radiol Clin North Am* 1996;34:545-63.
- Holzknacht N, Helmberger T, Schoepf UJ, Ertl-Wagner B, Kulinna C, Stäbler A, et al. Evaluation of an electromagnetic virtual target system (CT-guide) for CT-guided interventions. *Rofo* 2001;173:612-8.
- Bale R, Widmann G. Navigated CT-guided interventions. *Minim Invasive Ther Allied Technol* 2007;16:196-204.
- Feichtinger M, Aigner RM, Santler G, Kärcher H. Case report: Fusion of positron emission tomography (PET) and computed tomography (CT) images for image-guided endoscopic navigation in maxillofacial surgery: Clinical application of a new technique. *J Craniomaxillofac Surg* 2007;35:322-8.
- Smith KR, Frank KJ, Bucholz RD. The NeuroStation – A highly accurate, minimally invasive solution to frameless stereotactic neurosurgery. *Comput Med Imaging Graph* 1994;18:247-56.
- Feichtinger M, Pau M, Zemmann W, Aigner RM, Kärcher H. Intraoperative control of resection margins in advanced head and neck cancer using a 3D-navigation system based on PET/CT image fusion. *J Craniomaxillofac Surg* 2010;38:589-94.
- Daisne JF, Duprez T, Weynand B, Lonnew M, Hamoir M, Reyckler H, et al. Tumor volume in pharyngolaryngeal squamous cell carcinoma: Comparison at CT, MR imaging and FDG PET and validation with surgical specimen. *Radiology* 2004;233:93-100.
- Harn SD, Durham TM. Incidence of lingual nerve trauma and postinjection complications in conventional mandibular block anesthesia. *J Am Dent Assoc* 1990;121:519-23.
- Dojcinovic I, Hugentobler M, Richter M. Infracondylar abscess formation: A rare complication of local anesthesia. *Rev Stomatol Chir Maxillofac* 2006;107:366-9.
- Madan GA, Madan SG, Madan AD. Failure of inferior alveolar nerve block: Exploring the alternatives. *J Am Dent Assoc* 2002;133:843-6.
- Zink W, Graf BM. The toxicity of local anesthetics: The place of ropivacaine and levobupivacaine. *Curr Opin Anaesthesiol* 2008;21:645-50.
- Bucholz RD, Ho HW, Rubin JP. Variables affecting the accuracy of stereotactic localization using computerized tomography. *J Neurosurg* 1993;79:667-73.
- Maciunas RJ, Galloway RL Jr, Latimer JW. The application accuracy of stereotactic frames. *Neurosurgery* 1994;35:682-94.
- Dorward NL, Alberti O, Palmer JD, Kitchen ND, Thomas DG. Accuracy of true frameless stereotaxy: *In vivo* measurement and laboratory phantom studies. Technical note. *J Neurosurg* 1999;90:160-8.
- Bale RJ, Laimer I, Martin A, Schlager A, Mayr C, Rieger M, et al. Frameless stereotactic cannulation of the foramen ovale for ablative treatment of trigeminal neuralgia. *Neurosurgery* 2006;59:ONS394-401.

**Cite this article as:** Wallner J, Reinbacher KE, Pau M, Feichtinger M. Intermuscular pterygoid-temporal abscess following inferior alveolar nerve block anesthesia-A computer tomography based navigated surgical intervention: Case report and review. *Ann Maxillofac Surg* 2014;4:110-4.

**Source of Support:** Nil, **Conflict of Interest:** None declared.