

CASE REPORT

Bilateral cataract surgery in a Japanese macaque (*Macaca fuscata*): A case report

Yukihiro Miwa^{1,2}  | Hiroyuki Komatsu¹ | Ari Shinojima² | Ayako Oda³ |
Mao Inagaki¹ | Kensuke Usami¹ | Minori Akasaka¹ | Yoshitaka Kobayashi¹ 

¹Animal Eye Care–Tokyo Animal Eye Clinic, Tokyo, Japan

²Laboratory of Photobiology, Department of Ophthalmology, Keio University School of Medicine, Tokyo, Japan

³Veterinary Anesthesiology Consultant, Tokyo, Japan

Correspondence

Yukihiro Miwa, Animal Eye care–Tokyo Animal Eye Clinic, 1-12-12 Kaminoge, Setagaya Ku, Tokyo 158-0093, Japan.
Email: yukihiro226@gmail.com

Abstract

A 7.5-year-old intact male Japanese macaque was presented for evaluation of vision loss. After a complete ophthalmic examination, the patient was diagnosed with hypermature cataract in both eyes. After the cataract surgery, it was able to locate food and walk in a straight line.

KEYWORDS

cataract surgery, intraocular lens implantation, Japanese macaque, *Macaca fuscata*, phacoemulsification, vision loss

1 | INTRODUCTION

The Japanese macaque, a native species that is widely spread in Japan, lives in the most northern area of all non-human primates.¹ They live in groups and are highly social.² Non-human primates, including Japanese macaques, have maculae and fovea similar to humans and subsequently have higher visual acuity than other mammals.³ Therefore, deterioration of their vision is directly related to deterioration in the quality of life.

The Animal Eye Care–Tokyo Animal Eye Clinic (TAEC) was consulted regarding a Japanese macaque with visual impairment belonging to a circus group that used it in traditional Japanese performing art. It was unable not only to perform, but also to locate food or walk in a straight line due to vision loss. Furthermore, it appeared to be withdrawn from the other animals. After a complete ophthalmic examination, the diagnosis was hypermature cataract affecting both eyes.

Currently, there are several scientific reports on cataract surgery in non-human primates.^{4–8} However, there

are no reports of cataract surgery in Japanese macaques. This is the first such case report.

2 | CASE REPORT

2.1 | Clinical history

A 7.5-year-old intact male Japanese macaque, weighing 8.3 kg, presented at TAEC for the evaluation of vision loss. In June 2017, the owner noticed that its right eye appeared partially cloudy white (Figure 1A). By September 2018, the owner confirmed that the right eye was completely cloudy white (Figure 1B). However, at that point, there was no change in its behavior. In January 2020, its left eye also became cloudy (Figure 1C) and the owner confirmed that its behavior had become abnormal. At presentation, it showed no menace response. The patient had difficulty navigating and eating. Although this macaque was a member of a circus group, it was unable to perform due to vision loss. The veterinary doctor

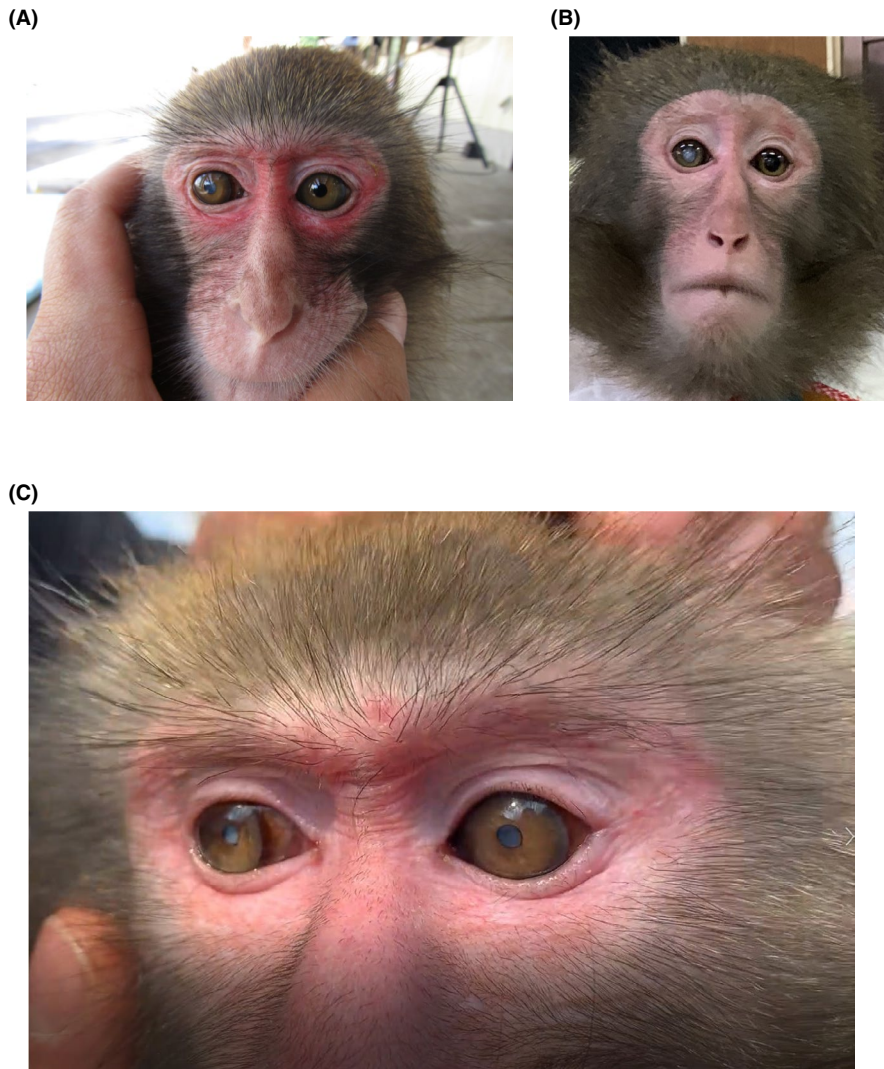


FIGURE 1 Ocular appearance of the patient. (A) Mild cataract is observed OD. (B) Progression of OD cataract is observed. (C) Note that immature cataract is found OS. OD, right eye; OS, left eye

reported that the physical examination performed prior to the TAEC visit showed no obvious abnormalities other than visual impairment.

2.2 | Ophthalmic examination

Ophthalmic examination revealed a negative menace response in both eyes (OU), positive dazzle reflex OU, positive direct and indirect pupillary light reflex in the right eye (OD), and weak direct and indirect pupillary light reflex in the left eye (OS). Relative afferent pupillary defect (Marcus Gunn pupil) was negative. The anterior segment OU was observed using Slit-Lamp Biomicroscope (BQ-900 LED; Haag-Streit AG). No corneal abnormalities were found, but the lens was strongly opacified OU (Figure 2A, B). No obvious anterior chamber flare was seen OU. The measured intraocular pressure using the TONOVET-Plus tonometer (Icare Finland) was 28 mmHg for OD and 21 mmHg for OS.

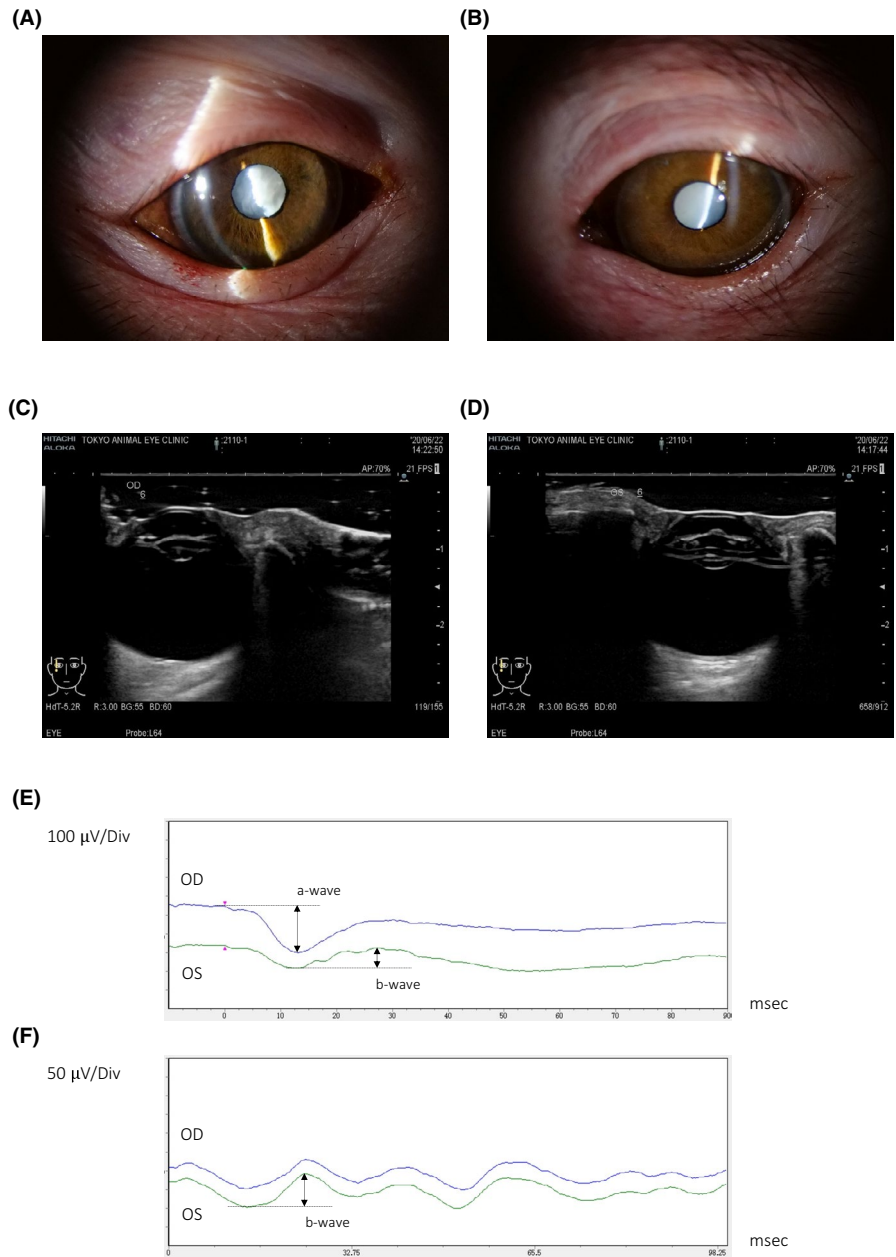
2.3 | Ocular ultrasonography

Ocular ultrasonography was performed under general anesthesia using the ARIETTA 60 device (Aloka Corporation) with a high-frequency linear probe (5–18 MHz, L64 linear probe, Aloka Corporation) revealing globe axial lengths measuring 20.3 mm (OD) and 19.8 mm (OS), anterior chamber depths of 3.8 mm (OD) and 3.5 mm (OS), and lens thicknesses of 3.4 mm (OD) and 4.6 mm (OS), with thinning and sub-luxation of the lens OD (Figure 2C). However, there was no obvious lens dislocation or thinning OS (Figure 2D). There were no posterior segment abnormalities OU. Based on ultrasonography results, we calculated the power of the IOL to be used intraoperatively.

2.4 | Electoretinography

Electoretinography (ERG; LE-100; Tomey) was performed under general anesthesia after dilation of the

FIGURE 2 Preoperative examination. Slit-lamp images of OD (A) and OS (B). Note that wrinkles are seen involving the anterior lens capsule OD. Ultrasound images of OD (C) and OS (D). Note that thinning and sub-luxation of the lens are seen OD. (E) and (F) The upper graph shows single flash ERG, and the lower graph shows 30 Hz flicker ERG. Note that ERG shows no obvious abnormalities. ERG, Electroretinography



pupil using a solution of 0.5% tropicamide and 0.5% phenylephrine (Mydrin-P, Santen Pharmaceutical). ERG was performed immediately before cataract surgery without dark adaptation to check for obvious retinal degeneration. Single flash ERG (Figure 2E) and 30 Hz flicker ERG (Figure 2F) were performed with light intensities of $20,000 \text{ cd/m}^2 \times 10 \text{ ms}$ and $3,000 \text{ cd/m}^2 \times 1 \text{ ms}$, respectively. Flicker ERG was recorded with a 25 cd/m^2 background stimulus. Due to the lack of dark adaptation, it was difficult to make a direct comparison with the ERG results in another reported non-human primate study.⁹ However, no obvious findings were suggesting retinal degeneration.¹⁰ The amplitude of the a-wave of the Single flash ERG was $250 \mu\text{V}$ OD and $122 \mu\text{V}$

OS. The amplitude of the b-wave of the single flash ERG was $173 \mu\text{V}$ OD and $109 \mu\text{V}$ OS. The amplitude of the 30 Hz flicker ERG was $68 \mu\text{V}$ OD and $75 \mu\text{V}$ OS.

2.5 | Complete blood count and serum biochemistry profile

Blood tests performed before the surgery showed an increase in white blood cell count ($32,700/\mu\text{l}$), but all other items were within the normal range. Since there were no obvious symptoms of bacterial infection, the cause of the elevated white blood cell count could be lens-induced uveitis or stress.

2.6 | Anesthesia

General anesthesia was performed by a board-certified veterinary anesthesiologist (Veterinary Anesthesiology Consultant). The patient was restrained by its trainer; then, a mixture of ketamine 5 mg/kg (Ketalar, Daiichi Sankyo) and medetomidine 0.03 mg/kg (Atipame, Kyoritsu Seiyaku, Co) was injected intramuscularly into the back of the thigh as pre-anesthetic medication. The patient became heavily sedated within 5 min of injection. While the patient was receiving oxygen supplementation with a facemask, a 24-gauge intravenous catheter (Surflo F&F, Terumo) was placed into the saphenous vein. After ERG and ocular ultrasonography were performed as previously described, midazolam 0.2 mg/kg (Dormicum Injection, Maruishi Pharmaceutical Co) was administered intravenously and endotracheal intubation was performed with an endotracheal tube (3-Fr, Fuji Systems).¹¹ After confirmation of bilateral airflow with chest auscultation and seal with inflation of endotracheal tube cuff, anesthesia was maintained using isoflurane (Animal isoflurane, MSD Animal Health). The patient was mechanically ventilated (Fabius Plus, Dräger Japan) to keep end-tidal carbon dioxide concentration (EtCO₂) around 40 mmHg inside the surgical room. A TOF Watch (MSD) was used to monitor perioperative neuromuscular blockade with train-of-four (TOF). Intravenous rocuronium 0.6 mg/kg/h (ESLAX, MSD) was administered continuously for paralysis of the extraocular muscles. The patient was administered lactated Ringer's solution at 2 ml/kg/h intravenously and kept warm using a heating pad throughout the surgery. Oscillometric blood pressure, electrocardiography, SpO₂, body temperature, pulse rate, respiratory rate, and EtCO₂ were monitored under anesthesia (Fabius Plus, Dräger Japan). Forty-five minutes after the start of anesthesia induction, the patient became severely hypotensive (mean arterial pressure less than 60 mmHg) most likely due to the vasodilatory effect of medetomidine. At this time, the patient was moved to the operating room after preoperative ERG and ultrasonography. A fluid bolus (5 ml/kg IV), a bolus of atropine 0.01 mg/kg IV (ATROPINE, NIPRO), continuous rate infusion (CRI) of dopamine (Dopamine Hydrochloride, KYOWA CritiCare Co) up to 12 mg/kg/min and intermittent IV ephedrine 0.1 mg/kg (Ephedrin "NAGAI," Nichi-iko Pharmaceutical) boluses were used to support the blood pressure. In addition, propofol (PropoFlo, Zoetis Japan) CRI at 75–100 mcg/kg/min and intermittent IV boluses of fentanyl (Fentanyl, Terumo) at 3 mcg/kg were administered to reduce the amount of isoflurane. We confirmed an increase in blood pressure 35 min after starting treatment for hypotension. The following additional drugs were administered during the perioperative period: cefazolin IV 20 mg/kg (Cefamezinα,

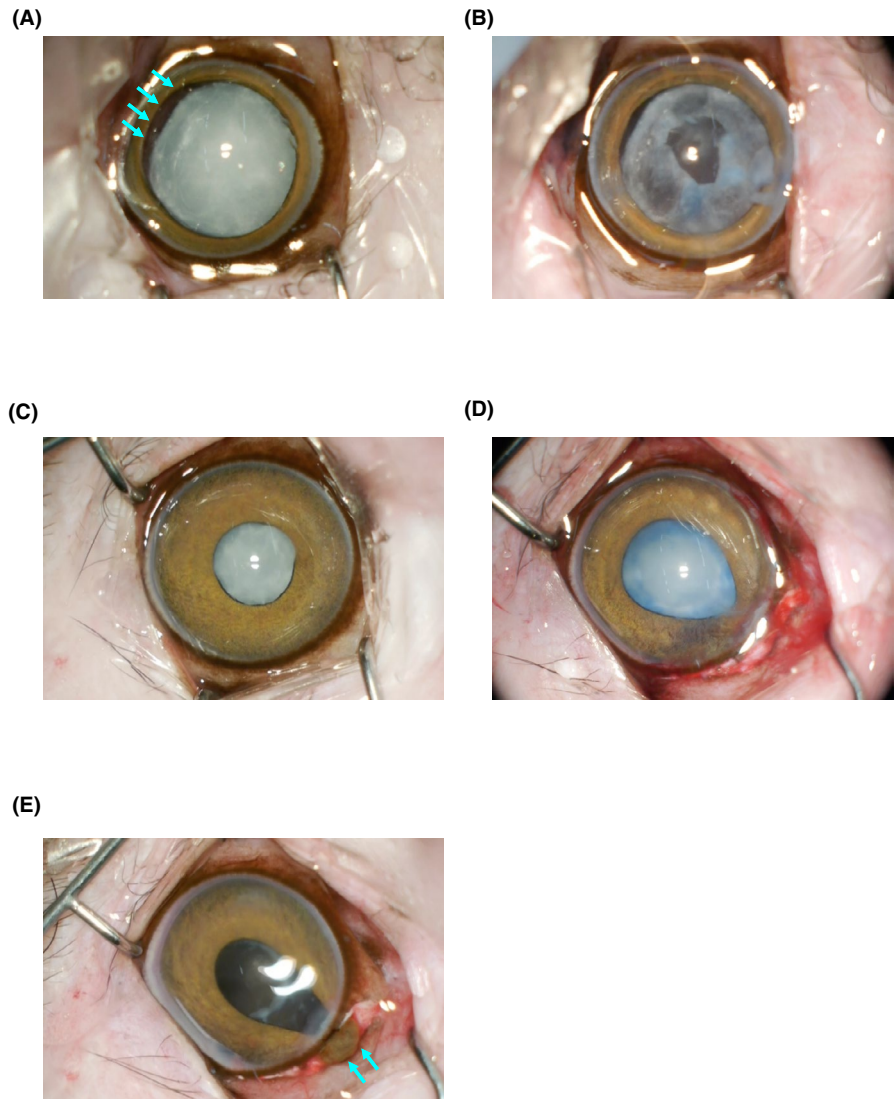
LTL Pharma) and prednisolone IV 1 mg/kg (Predonine, Shionogi). Sugammadex (BRIDION, MSD) were administered intravenously (4 mg/kg) when the surgery was completed. Isoflurane was discontinued once the TOF of >90% was confirmed. The CRIs were discontinued, and buprenorphine (Lepetan, Otsuka Pharmaceutical) at 0.01 mg/kg was administered intravenously for postoperative analgesia. The patient vomited a small amount of liquid after extubation, but the recovery was uneventful otherwise.

2.7 | Phacoemulsification

We usually prescribe antibiotics and anti-inflammatory agents a few days before cataract surgery and instill mydriatics a few times a couple of hours preoperatively. However, the owner said it was impossible to give eye drops to this patient, initially. Therefore, antibiotics (gatifloxacin, Gatiflo, Senju), anti-inflammatory agents (difluprednate, STEROP, Senju), and mydriatic eye drop (Mydrin-P, Santen Pharmaceutical) were administered several times within a short period after the introduction of anesthesia. The patient was placed in the supine position. Both eyes were washed with diluted PA-IODO Ophthalmic and Eye washing Solution (Nitten Pharmaceutical Co., Ltd). We then draped the surgical field and started the operation.

OD: Consistent with the prior ocular ultrasonographic findings, the zonule of Zinn was noted to be torn from 2 to 6 o'clock (Figure 3A). A 2-step corneal incision was performed at the 11 o'clock position using a slit knife (MSL 20, MANI Inc). Three side ports were created using a 20-gauge V-lance (MVR 20SK, MANI Inc) at 1, 7, and 9 o'clock positions over the limbus. Small amounts of Viscoat (Alcon Japan Ltd) and Healon (AMO Japan) were injected through the side port, ensuring they did not pass into the vitreous. Trypan blue staining of the anterior lens capsule was followed by continuous curvilinear capsulorhexis (CCC) using cystotome initially attempted from the main port. However, the anterior lens capsule was extremely hard, and CCC could not be performed. Even after using Scissors YAE Multi-Purpose 23 G (Inami), it was impossible to incise the anterior lens capsule. The anterior lens capsule was finally punctured using intraocular lens (IOL) scissors. We were planning to perform a 5-mm-diameter capsulorhexis, considering the size of the IOL. However, the finished capsulorhexis measured about a quarter of what was expected (Figure 3B). As the lens was completely liquefied, it was aspirated via a bimanual I/A handpiece using the phaco-machine (WhiteStar Signature, AMO Japan). Oxiglutatione ocular irrigating solution 0.0184% KIT (Senju) with 1 mg epinephrine (Bosmin Injection, Daiichi Sankyo) and 500 IU heparin

FIGURE 3 Perioperative images. (A) and (B) are OD images. (A) Note aphakic crescent is observed from 2 to 6 o'clock (arrows). (B) This is an image after aspiration of the liquefied lens. Note the small CCC made using intraocular lens scissors. (C), (D), and (E) are OS images. (C) Poor mydriasis is observed. (D) CCC was performed while expanding the pupil using viscoelastic substances. (E) Iris prolapse is seen after phacoemulsification. Arrows indicate the prolapsed iris. CCC, continuous curvilinear capsulorhexis



(Heparin Sodium, Mochida) were used as the irrigating solution. Following lens aspiration, the CCC was widened and a 26D foldable IOL (Avansee, Kowa) was inserted. The lens capsule was contracted, with the diameter of the lens capsule almost identical to the IOL. The lens capsule was polished using the bimanual I/A handpiece connected to the phaco-machine. However, polish failed because the capsule itself had become cloudy and hardened. Since the zonule of Zinn was partially torn, we considered the use of a capsular tension ring (CTR). However, we only had a canine version of the CTR and felt it was too large for a macaque; therefore, we did not use it. Since the tear of Zinn's zonule was within 120°, it was judged that the IOL could be inserted safely. The IOL was slowly expanded and placed in the correct position, holding the lens capsule with a Forceps Micro Capsulorhexis IKEDA BEAK23G (Inami) to prevent the lens capsule from falling into the vitreous. After aspiration of the viscoelastic substances, the corneal incision site was sutured using 10-0 nylon suture material (Mani, Tochigi) in a double

continuous sawtooth suture pattern. Postoperative eye drops were expected to be difficult due to the patient's disposition. Therefore, immediately after the surgery, subconjunctival dexamethasone (DECADRON, Aspen Japan) and tobramycin (TOBRACIN, Towa Pharmaceutical Co) were injected. Skiascopy was used to confirm that OD reached emmetropia.

OS: A 3-step scleral incision was performed at the 11 o'clock position using a 22.5-degree straight knife (MST22, MANI Inc), crescent knife (MCU26, MANI Inc), and slit knife. One side port was created using a 20-gauge V-lance at the 1 o'clock positions over the limbus. Even though mydriatics were topically instilled, poor mydriasis was observed (Figure 3C). After using viscoelastic substances to dilate the pupil, we were able to obtain sufficient mydriasis to perform the surgery. Viscoat and Healon were injected to maintain the anterior chamber while protecting the corneal endothelial cells. Following trypan blue staining of the anterior lens capsule, CCC was performed from the main port while expanding the pupil using viscoelastic

substances. Although the anterior lens capsule of the OS was softer than that of OD, it was still very hard. Thus, CCC was performed mainly using YAE Multi-Purpose 23 G Scissors (Figure 3D). Since the lens was mostly liquefied, it was removed with minimal phacoemulsification. Oxiglutatione ocular irrigating solution 0.0184% KIT (Senju) with 1 mg epinephrine (Bosmin Injection, Daiichi Sankyo) and 500 IU heparin (Heparin Sodium, Mochida) were used as the irrigating solution. After phacoemulsification, prolapse of the iris from the main port was seen. This was considered to be an intraoperative floppy iris syndrome (IFIS)-like phenomenon (Figure 3E).¹² Subsequently, another side port was created to reduce the anterior chamber pressure and return the prolapsed iris. After returning the iris, the lens capsule was polished with the bimanual I/A handpiece using the phaco-machine. A 26D foldable IOL was inserted and oriented in the correct position. After aspirating viscoelastic substances, the corneal incision site was sutured with 10–0 nylon suture material in a double continuous sawtooth suture pattern. Immediately after the surgery, dexamethasone and tobramycin were injected sub-conjunctively. Skiascopy was used to confirm that OS reached emmetropia.

2.8 | Outcome and follow-up

The patient was able to eat and walk straight unassisted the very next day after surgery. On examination on the third day after the surgery, intraocular inflammation was observed. Inflammation was particularly severe OS, with fibrin deposition observed (Figure 4A–D). The degree of intraocular inflammation was determined based on the degree of anterior chamber flare. Based on previous reports, the degree of anterior chamber flare seen in this patient was considered to be moderately increased.¹³ Therefore, the following eye drops were initiated on the third day: atropine (Nitten ATROPINE, Nitten Pharmaceutical Co, Ltd) every 24 h and difluprednate (STEROP, Senju) every 12 h OS, and difluprednate every 12 h OD. Frequent anti-inflammatory eye drops were recommended for the left eye, but as the patient was uncooperative, twice-daily drops were prescribed. In addition, prednisolone (PREDONINE, Shionogi) was administered systemically. The systemic prednisolone was then tapered over 4 weeks. Four weeks after surgery, minimal anterior chamber flare was observed in both eyes. Therefore, only diclofenac

sodium eye drop (DICLOD, Wakamoto Pharmaceutical Co) was used every 12 h for both eyes. The patient started performing in shows again 1.5 months after the surgery.

Ophthalmic examination of both the eyes 26 weeks after the surgery showed no inflammation, with a clear visual axis (Figure 4E, F). Despite IOP concerns initially, follow-up measurements were normal. Fundus imaging (VX-10, KOWA) and optical coherence tomography (OCT; Spectralis, Heidelberg Engineering) showed no abnormalities (Figure 4G–J). The postoperative vision was maintained.

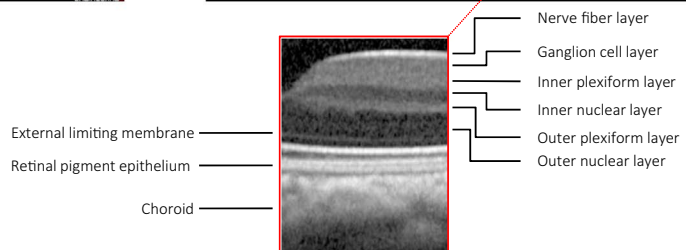
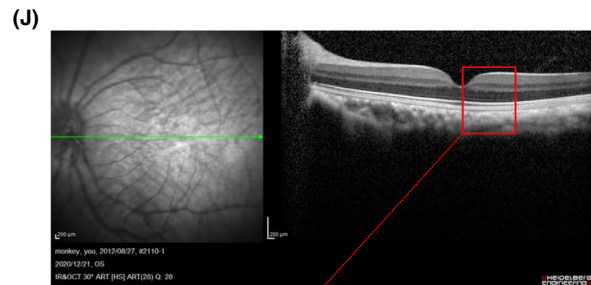
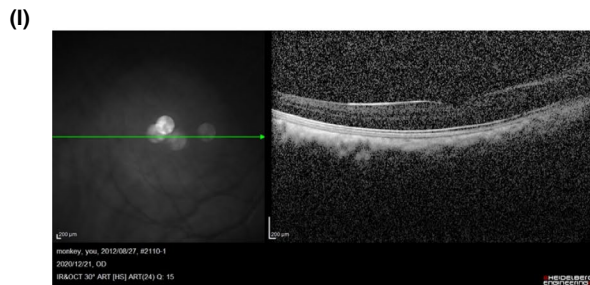
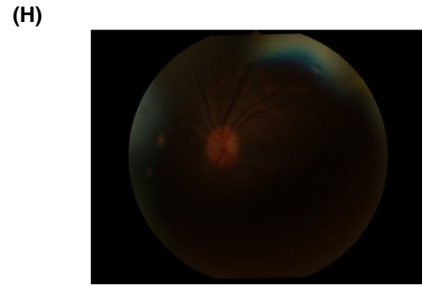
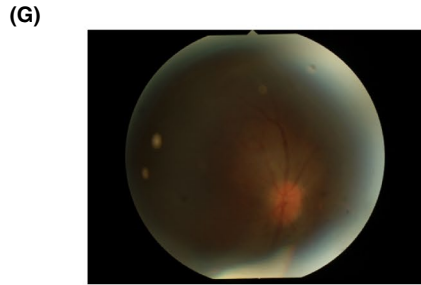
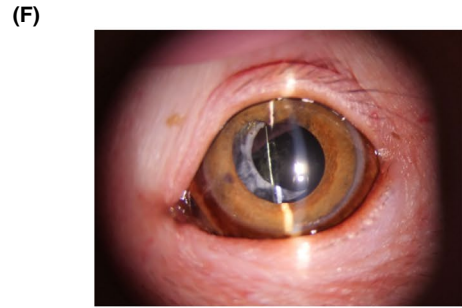
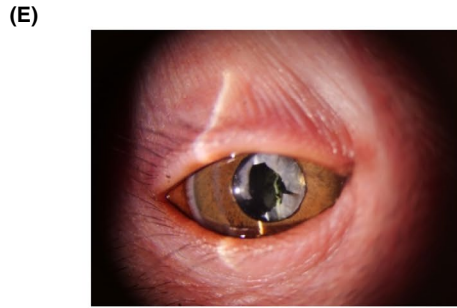
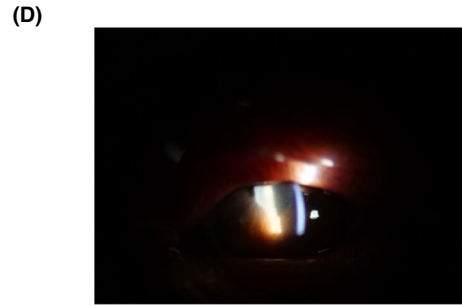
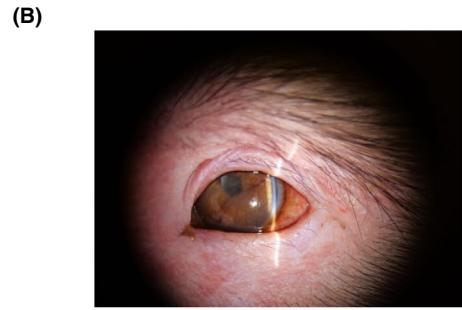
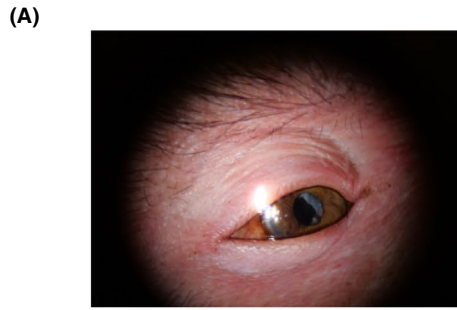
3 | DISCUSSION

Cataract is a disease that affects a wide variety of animals, causing vision loss. There have been many reports of cataract surgery in animals.^{14–23} However, there are only a few reports on cataract surgery in non-human primates. To the best of the authors' knowledge, this is the first report of successful cataract surgery on a Japanese macaque.

The right cataract of this patient was highly advanced, making the lens capsule very hard. Although no obvious anterior chamber flare was observed involving either eye on initial examination, previous lens-induced uveitis might have hardened the lens capsule. The elevated white blood cells seen in the blood tests support this possible past lens-induced uveitis. However, there was no lens capsule rupture, which has been reported as associated with cataract progression.²⁴ There have been reports of cataract-related lens capsule rupture in a variety of animals.²⁴ However, no report discusses cataracts and lens capsule rupture in Japanese macaques. We intend to elucidate more on this issue as we increase the number of cases.

As mentioned earlier, an IFIS-like phenomenon was observed in the left eye. IFIS is a phenomenon seen during human cataract surgery and is more common in patients taking Alpha-1 antagonists.¹² IFIS is characterized by three features: floppiness or billowing of the iris, progressive intraoperative miosis, and iris prolapse through the surgical incision.¹² The presence of IFIS causes impediments intraoperatively and increases the risk of intraoperative complications. It is unclear why the IFIS-like phenomenon was observed in this case. Since the patient was neither using Alpha-1 antagonists nor had any other indicators that could cause IFIS, it is speculated that the

FIGURE 4 Postoperative images. Slit lamp images of OD (A, C) and OS (B, D) which were taken on the third day after surgery. (A–D) Conjunctival hyperemia, blepharospasm, and anterior chamber flare are observed. Slit lamp images of OD (E) and OS (F) 26 weeks after surgery. Note that the visual axis is clear in both eyes. Fundus images of OD (G) and OS (H) and OCT images of OD (I) and OS (J) show no abnormalities. (I) and (J) are horizontal B-scans through the fovea with a label denoting the normal foveal depression. Note the low resolution of the OCT image OD due to the opacity of the lens capsule



IFIS-like phenomenon might be idiopathic. This phenomenon is not often seen in dogs but may be observed in Japanese macaques; thus, more cases need to be studied in the future.

Intraocular lens power was calculated based on ultrasonography results. Due to the contraction of the anterior capsule and the sub-luxation of the lens, it was difficult to completely predict the postoperative condition preoperatively. However, both eyes were nearly emmetropic after the surgery. We performed a skiascopy and confirmed that the light reflected from the fundus moved in the same direction as the light projected into the pupil. This suggested that the patient's visual acuity might be emmetropia or mild hyperopia. This was also confirmed by the fact that the patient was able to recognize cues given by distant humans and recognize nearby food postoperatively. It was possible that being emmetropic allowed the patient to return to performing, walk straight, and eat by itself. Calculating the IOL power before the surgery and using the appropriate IOL were considered essential.

We used a two-step corneal incision for the first operated eye but felt anterior chamber instability during surgery. Subsequently, a three-step scleral incision was used for the left eye. As a result, we felt that a three-step scleral incision allowed us to perform more stable cataract surgery in this patient.

As mentioned above, the lens capsule of the right eye was extremely hard, and anterior capsulotomy was performed using IOL scissors. Multiple side ports had to be opened to insert IOL scissors from various directions. In this surgery, we were able to emulsify the lens in both eyes with almost no use of ultrasound. This may be due to the advanced stage of cataract in this patient. Therefore, it would be difficult to apply the same technique in other Japanese macaque cataract surgeries. We used a non-absorbable nylon thread to close the surgical wound. This was because the patient was unable to wear an Elizabethan collar after the surgery, and we thought it would be preferable to keep the surgical wound closed for as long as possible.

The Japanese macaque is a highly social animal. Visual information is considered indispensable to their social life. The patient in this case was unable to even walk straight due to cataracts. After cataract surgery, the patient recovered enough vision to return to circus performing. We believe that this report will provide useful information for the treatment of Japanese macaques in the future, especially cataract treatment. However, only a few reports on the treatment of non-human primate cataracts are currently available. Thus, it is necessary to accumulate and study more cases and establish a standard treatment method.

ACKNOWLEDGEMENT

The authors would like to thank the staff of the TAEC for critical discussions in this study.

CONFLICT OF INTEREST

The authors declare no conflict of interest associated with this manuscript.

AUTHOR CONTRIBUTIONS

Y.M., A.S., and Y.K. mainly performed the surgery and analyzed all of the experiments with the support of H.K., M.I., K.U., and M.A. Y.M., A.S., and A.O. wrote the manuscript. All authors revised the manuscript, approved it to be published, and agreed to be accountable for all aspects of this work.



ETHICAL APPROVAL

This study was conducted in accordance with the code of ethics of the Japan Veterinary Medical Association. In addition, this study was conducted after obtaining the owner's consent by written form.

DATA AVAILABILITY STATEMENT

The data that support the findings of this study are available from the corresponding author, Y.M., upon reasonable request.

ORCID

Yukihiro Miwa  <https://orcid.org/0000-0002-5377-6772>
Yoshitaka Kobayashi  <https://orcid.org/0000-0002-6211-1174>

REFERENCES

1. Hanya G. Diet of a Japanese macaque troop in the coniferous forest of Yakushima. *Int J Primatol.* 2004;25(1):55-71. <https://doi.org/10.1023/B:IJOP.0000014645.78610.32>
2. Chaffin CL, Friedlen K, De Waal FBM. Dominance style of Japanese macaques compared with rhesus and stump-tail macaques. *Am J Primatol.* 1995;35(2):103-116. <https://doi.org/10.1002/ajp.1350350203>
3. Mikami A, Fujita K. Development of the ability to detect visual motion in infant macaque monkeys. *Dev Psychobiol.* 1992;25(5):345-354. <https://doi.org/10.1002/dev.420250505>
4. Montiani-Ferreira F, Lima L, Bacellar M, D'Ottaviano Vilani RG, Fedullo JD, Lange RR. Bilateral phacoemulsification in an orangutan (*Pongo pygmaeus*). *Vet Ophthalmol.* 2010;13(SUPPL. 1):91-99. <https://doi.org/10.1111/j.1463-5224.2010.00762.x>
5. de Faber J-THN, Pameijer JH, Schaftenaar W. Cataract surgery with foldable intraocular lens implants in captive lowland gorillas (*Gorilla gorilla gorilla*). *J Zoo Wildl Med.* 2004;35(4):520-524. <https://doi.org/10.1638/03-010>
6. Whitley RD, Jacobson ER, Lavach JD, Gelatt KN, Barrie KP. Bilateral ultrasonic phacofragmentation and aspiration cataract extraction in a spider monkey (*Ateles geoffroyi*). *J Zoo Anim Med.* 1980;11(2):58. <https://doi.org/10.2307/20094468>

7. Leiva M, Peña T, Bayón A, de León M, Morales I. Phacoemulsification considerations in nonhuman primates. *J Med Primatol.* 2012;41(5):317-324. <https://doi.org/10.1111/j.1600-0684.2012.00562.x>
8. Sritrakoon N, Karntip W, Niyom S, et al. A-scan biometry, phacoemulsification, and foldable intraocular lens implantation in a young orangutan (*Pongo pygmaeus*). *Open Vet J.* 2021;11(1):121-127. <https://doi.org/10.4314/ovj.v11i1.18>
9. Bouskila J, Javadi P, Palmour RM, Bouchard JF, Ptito M. Standardized full-field electroretinography in the green monkey (*Chlorocebus sabaeus*). *PLoS One.* 2014;9(10):1-9. <https://doi.org/10.1371/journal.pone.0111569>
10. Kinoshita J, Iwata N, Maejima T, Imaoka M, Kimotsuki T, Yasuda M. N-methyl-N-nitrosourea-induced acute alteration of retinal function and morphology in monkeys. *Investig Ophthalmol Vis Sci.* 2015;56(12):7146-7158. <https://doi.org/10.1167/iops.15-16929>
11. West G, Heard D, Caulkett N, eds. *Zoo animal and wildlife immobilization and anesthesia.* John Wiley & Sons, Inc.; 2014. <https://doi.org/10.1002/9781118792919>
12. Enright JM, Karacal H, Tsai LM. Floppy iris syndrome and cataract surgery. *Curr Opin Ophthalmol.* 2017;28(1):29-34. <https://doi.org/10.1097/ICU.0000000000000322>
13. Wiggans KT, Vernau W, Lappin MR, Thomasy SM, Maggs DJ. Diagnostic utility of aqueocentesis and aqueous humor analysis in dogs and cats with anterior uveitis. *Vet Ophthalmol.* 2014;212-220. <https://doi.org/10.1111/vop.12075>
14. Beech J, Irby N. Inherited nuclear cataracts in the Morgan horse. *J Hered.* 1985;76(5):371-372. <https://doi.org/10.1093/oxfordjournals.jhered.a110114>
15. McLaughlin SA, Whitley RD, Gilger BC. Diagnosis and treatment of lens diseases. *Vet Clin North Am Equine Pract.* 1992;8(3):575-585. [https://doi.org/10.1016/S0749-0739\(17\)30442-X](https://doi.org/10.1016/S0749-0739(17)30442-X)
16. Lorimer DW. Cataract in small animals. *Pet Focus.* 1990;2(4):55-57.
17. Maehara S, Matsumoto N, Takiyama N, et al. Surgical removal of cataract in an Asiatic black bear (*Ursus thibetanus*) by phacoemulsification and aspiration. *J Vet Med Sci.* 2020;82(6):740-744. <https://doi.org/10.1292/jvms.19-0639>
18. Gionfriddo JR. Cataracts in new world camelids (llamas, alpacas, vicuñas, and guanacos). *Vet Clin North Am Exot Anim Pract.* 2002;5(2):357-369. [https://doi.org/10.1016/s1094-9194\(01\)00006-8](https://doi.org/10.1016/s1094-9194(01)00006-8)
19. Heintz MR, Fuller GA, Woodhouse SJ, Murray A, Allard SM. Case studies of the impacts of cataract surgery on crested penguin welfare. *J Appl Anim Welf Sci.* 2019;22(4):329-341. <https://doi.org/10.1080/10888705.2018.1519436>
20. Mason IK. Cataract extraction in the tawny eagle (*Rapax bellisimus*). *Vet Rec.* 1995;136(15):396. <https://doi.org/10.1136/vr.136.15.396>
21. Seitz R, Weisse I. Operation on a congenital cataract in a Siberian tiger. *Ophthalmologica.* 1979;178(1-2):56-65. <https://doi.org/10.1159/000308807>
22. Kelly TR, Walton W, Nadelstein B, Lewbart MSGA. Phacoemulsification of bilateral cataracts in a loggerhead sea turtle (*Caretta caretta*). *Vet Rec.* 2005;156(24):774-777. <https://doi.org/10.1136/vr.156.24.774>
23. Myers G, Webb T, Corbett CR, Fout C. Phacoemulsification for removal of bilateral cataracts in a black water monitor (*Varanus salvator macromaculatus*). *J Herpetol Med Surg.* 2011;21(4):96-100. <https://doi.org/10.5818/1529-9651-21.4.96>
24. Wilkie DA, Gemensky-Metzler AJ, Colitz CMH, et al. Canine cataracts, diabetes mellitus and spontaneous lens capsule rupture: a retrospective study of 18 dogs. *Vet Ophthalmol.* 2006;9(5):328-334. <https://doi.org/10.1111/j.1463-5224.2006.00490.x>

How to cite this article: Miwa Y, Komatsu H, Shinojima A, et al. Bilateral cataract surgery in a Japanese macaque (*Macaca fuscata*): A case report. *Clin Case Rep.* 2021;9:e05112. <https://doi.org/10.1002/ccr3.5112>