

Trauma and reconstruction

## Complete urethral disruption as a complication of urethral catheterization presenting as scrotal mass: A rare case

Aaron Tigor Sihombing<sup>\*</sup>, I Nyoman Palgunadi, Dicky Stefanus

Department of Urology, Faculty of Medicine Universitas Padjadjaran, General Hospital Hasan Sadikin Bandung, Indonesia

### ARTICLE INFO

#### Keywords:

Urinary catheterization  
Urethral diseases  
Fournier gangrene

### ABSTRACT

Complete urethral disruption due to urethral catheterization is rarely documented. Only seven cases of iatrogenic complete urethral disruption were reported from 1997 to 2003. We describe a case of complete urethral disruption due to urethral catheterization in an 80-year-old male who was referred because of a scrotal mass. Physical examination showed a palpable non-fluctuation mass in the scrotum and ultrasound examination revealed an intrascrotal balloon catheter. This was an obscure case of urethral catheterization complication presenting as a scrotal mass in an octogenarian patient with Fournier's gangrene.

### Introduction

From a review of genitourinary trauma in the United States, the prevalence of urethral injury is approximately 4% of total genitourinary trauma. The most common cause of urethral injury is iatrogenic injury and as many as 65% are complete urethral disruption.<sup>1</sup> In one series of iatrogenic urethral injury, the most common site of complete urethral disruption was anterior urethra. This series reported that 3 out of 7 cases of complete urethral disruption (42%) were caused by urethral catheterization. The oldest age was 58 years old and the youngest was 7 years old.<sup>2</sup> In Indonesia, the incidence of urethral injury is unknown and not documented. Here we describe an obscure case of urethral catheterization complication presenting as a scrotal mass in an octogenarian patient with Fournier's gangrene.

### Case presentation

An 80-year-old male was consulted to the urology department from the internal medicine department because of a scrotal mass suspected to be an abscess. The patient had a history of urethral catheter replacement every 2 weeks by a rural health caregiver for 4 months due to urinary retention. Five days before admission the patient had a purulent discharge from his left scrotal wall and a fever. The urethral catheter was replaced by a rural healthcare provider one day before admission, after which he complained of pain and lump on the left scrotum. He, then, was referred to Hasan Sadikin Hospital. Upon arrival on the urology department, his blood pressure was 90/60 mmHg, heart rate was 120

beats per minute, respiratory rate 24 times per minute and body temperature was 37.5 °C. There was a lump in the left scrotum, cystic on palpation which was not fluctuating. Pus coming out from the left scrotum and a purulent fluid was seen inside the urethral catheter tube. Scrotal ultrasound examination revealed a balloon catheter in the left scrotum and a hyperechoic lesion with an acoustic shadow in the posterior urethra (Fig. 1A). A kidney ureter bladder (KUB) x-ray showed two radio opaque shadows in the pelvic area (Fig. 1B). His laboratory findings were as follows: white blood cell count 19,790 WBC/mL, hemoglobin of 7.8 g/dL, serum BUN 103.14 mg/dL, serum creatinine of 5.29 mg/dL, serum lactate 2.1, and blood glucose level of 114 mg/dL. Urinalysis showed >50/high-power field (HPF) red blood cells and >50/HPF white blood cells. The Fournier Gangrene Scoring Index (FGSI) was 18 points.

Patients received a correction of fluid and electrolyte imbalance and the third generation of cephalosporin before having an emergency necrotomy debridement. Retrograde urethrography showed contrast extravasation at the pendular area (Fig. 2A). Open vesicolithotomy was performed and two stones from the bladder and urethra were extracted. The bladder stone size was 45 × 20 × 15 mm and urethral stone size was 20 × 18 × 12 mm (Fig. 2B). A cystostomy tube was inserted for urine diversion. Incision drainage and necrotomy debridement of the scrotum were performed and a 5 cm defect on the urethral was found (Fig. 2C).

After these procedures were done, the level of consciousness was 11 (E3M6V4), white cell count 16000 WBC/mL, hemoglobin of 9.5g/dL, serum BUN 67.2mg/dL, serum creatinine decreased to 2.4 mg/dL. Two days after the operation, the patient complaining a shortness of breath.

<sup>\*</sup> Corresponding author. Jalan Pasteur No. 38, Bandung, Indonesia.

E-mail address: [aarontigor@gmail.com](mailto:aarontigor@gmail.com) (A.T. Sihombing).

<https://doi.org/10.1016/j.eucr.2020.101378>

Received 21 July 2020; Received in revised form 3 August 2020; Accepted 7 August 2020

Available online 11 August 2020

2214-4420/© 2020 The Authors.

Published by Elsevier Inc.

This is an open access article under the CC BY-NC-ND license

(<http://creativecommons.org/licenses/by-nc-nd/4.0/>).

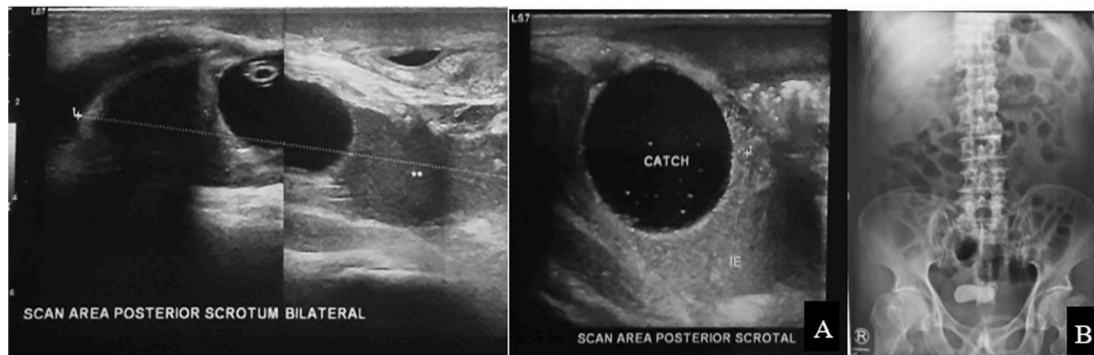


Fig. 1. A) Scrotal ultrasonography. B) Kidney Ureter Bladder (KUB) x-ray.

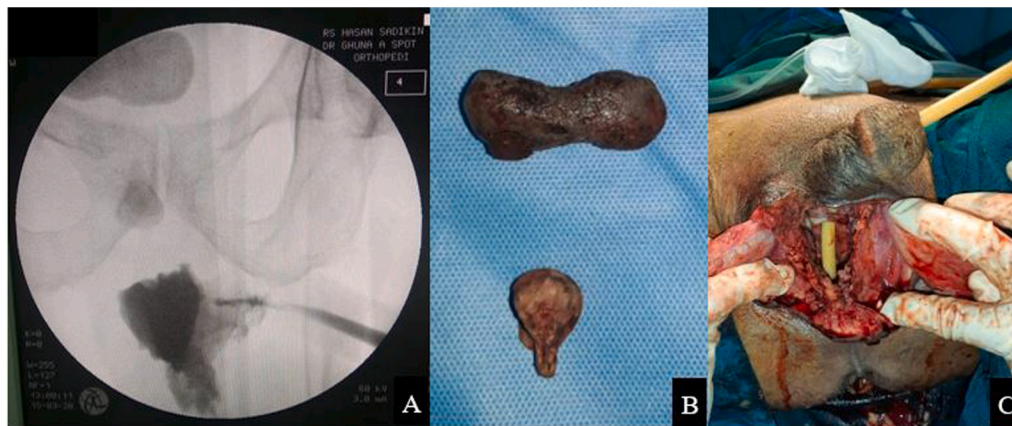

Fig. 2. A) Retrograde urethrography. B) The bladder and urethral stone. C) Evaluation of the scrotal area showed a urinary catheter that leads to the scrotal area.

He was consulted to the internal medicine department and diagnosed with hospital-acquired pneumonia. On the third day after the operation, the respiratory problem worsened, he then was intubated and moved to the intensive care unit (ICU). The patient's condition was not improved despite all attempts, the patient died due to respiratory failure.

## Discussion

Long-term indwelling urethral catheterization is one of the effective means of managing urinary retention in older people especially for patients who refused or incapable of having surgery. However iatrogenic urethral injury can occur in 3.2–6.7 per 1000 patients<sup>1,3</sup> The catheter tip may be misplaced into the urethra or periurethral tissues and leading to the false passage and urethral perforation. In our case, the patient had genital infection which indicated by fever, purulent left scrotal discharge. The infection, urethral stone, combined with aging in our patient, affecting the urethral wall to become frail, thus a false passage may easily cause complete urethral disruption.

In our patient the diagnosis of complete urethral disruption caused by false passage was obscure. This condition was similar to the patient that was reported by Parvey et al. The scrotal lump was thought to be an abscess because of the purulent discharge on the left scrotal wall. This underlines the importance of imaging in diagnosing inappropriate placement of urinary catheters.<sup>4</sup>

Unfortunately, our patient infection was severe. His Fournier Gangrene Severity Index (FGSI) was eighteen which suggesting a 75% probability of death. Our patient also had burdensome factors, such as advanced age, septic shock at presentation, and renal failure.<sup>5</sup>

## Conclusion

Urethral catheterization is a routine and one of the most commonly performed procedures. However, it must be remembered that urethral catheterization also can cause significant complications. This case reminds us that urinary catheterization can result in severe infection and a complete urethral disruption. High level of vigilance and accurate diagnosis are important in managing complications caused by urethral catheterization.

## Funding

This research did not receive any specific grant from funding agencies in the public, commercial, or not-for-profit sectors.

## Declaration of competing interest

None.

## References

- McGeady JB, Breyer BN. Current epidemiology of genitourinary trauma. *Urol Clin*. 2013;40(3):323–334. <https://doi.org/10.1016/j.ucl.2013.04.001>.
- Maheshwari PN, Shah HN. Immediate endoscopic management of complete iatrogenic anterior urethral injuries: a case series with long-term results. *BMC Urol*. 2005;5:13. <https://doi.org/10.1186/1471-2490-5-13>.
- Davis NF, Quinlan MR, Bhatt NR, et al. Incidence, cost, complications and clinical outcomes of iatrogenic urethral catheterization injuries: a prospective multi-

- institutional study. *J Urol*. 2016;196(5):1473–1477. <https://doi.org/10.1016/j.juro.2016.05.114>.
4. Parvey HR, Patel BK. Urethral complications of urinary catheterization presenting as primary scrotal masses: sonographic diagnosis. *J Clin Ultrasound*. 1998;26(5):261–264. [https://doi.org/10.1002/\(sici\)1097-0096, 199806](https://doi.org/10.1002/(sici)1097-0096, 199806).
  5. Hamdy FC, Eardley I, Catto JW, Mundy AR, Pickard R. *Oxford Textbook of Urological Surgery*. vol. 1. Oxford University Press; 2019:76–78.