



Contents lists available at ScienceDirect

Indian Pacing and Electrophysiology Journal

journal homepage: www.elsevier.com/locate/IPEJ

Non-fluoroscopic catheter ablation: A randomized trial

Leonardo Martins Pires^a, Tiago Luiz Luz Leiria^{a,*}, Marcelo Lapa Kruse^a,
Gustavo Glotz de Lima^{a,b}

^a Cardiology Institute of Rio Grande Do Sul, University Foundation of Cardiology, Porto Alegre, RS, Brazil

^b Department of Clinical Medicine, UFCSPA, Brazil

ARTICLE INFO

Article history:

Received 11 February 2019

Received in revised form

5 June 2019

Accepted 21 June 2019

Available online 22 June 2019

Keywords:

Electro-anatomical mapping

Fluoroscopy

X-rays

Electroanatomic mapping

Fluoroscopy

X-rays

ABSTRACT

Background: Catheter ablation provides curative treatment for tachyarrhythmias. Fluoroscopy, the method used for this, presents several risks. The electroanatomical mapping (MEA) presents a three-dimensional image without using X-rays, and may be adjunct to fluoroscopy.

Objectives: We evaluated the possibility of performing catheter ablation with the exclusive use of electroanatomical mapping (MEA), dispensing with fluoroscopy. We compared the total time of procedure and success rates against the technique using fluoroscopy (RX) with emission of X-rays.

Methods: Randomized, unicentric, uni-blind study of patients referred for tachyarrhythmia ablation.

Results: Twelve patients were randomized to the XR group and 11 to the EAM group. The mean age was 48.5 (± 12.6) vs 46.3 (± 16.6) (P = ns). Success occurred in 11 patients (91.7%) in the RX group and 9 (81.8%) in the MEA group (P = 0.46). The procedure time in minutes was higher in the MEA group than in the RX group (79–47–125min vs 49–30–100min; P = 0.006). The mean fluoroscopy time was 11 \pm 9 min versus zero (RX vs MEA: P < 0.001). The mean radiofrequency applications were lower in the RX group against the MEA group (6 \pm 3.5 \times 13.2 \pm 18.2 p < 0.019). There were no complications.

Conclusion: MEA opened new therapeutic possibilities for patients with arrhythmias, reducing the risk of radiation. In this study, it was possible to demonstrate that it is feasible to perform ablation only with the use of MEA, with similar success with fluoroscopy, at the expense of a longer procedure time.

Copyright © 2019, Indian Heart Rhythm Society. Production and hosting by Elsevier B.V. This is an open access article under the CC BY-NC-ND license (<http://creativecommons.org/licenses/by-nc-nd/4.0/>).

1. Introduction

In recent years, there has been rapid advancement in the technologies available for the treatment of cardiac arrhythmias. The indications for catheter ablation have expanded to include patients with complex arrhythmia, who are often refractory to other forms of therapy (pharmacological and use of implantable devices) [1,2,3].

The use of fluoroscopy with X-ray emission has been the method for locating catheters within the heart. This form of mapping has low spatial resolution and makes it difficult to perform ablation that require substrate modification, where the localization of scar and electrically active isthmuses in the ventricular or atrial myocardium becomes essential.

Exposure to X-rays can have consequences for the patient and

the medical staff. It is known that this exposure increases the incidence of problems such as dermatitis, cataract, congenital defects and neoplasias [4]. Pediatric patients are also at risk, especially with thyroid and gonads irradiation. To this end, the use of lead aprons by the assistant team, protectors of this same material for thyroid and gonads for patients, acrylic plates and special glasses, are used to block radiation and reduce these risks [5]. However, these devices can cause orthopedic problems because of their weight [6].

The use of electro-anatomical mapping (MEA) modified the percutaneous treatment of complex arrhythmias such as atrial flutter (AFL), atrial fibrillation (AF) and ventricular tachycardia (VT) [7,8]. Models currently available on the market are EnSite (NAVX)[®], Localiza[®], Clarity[®] and Carto[®] systems. This technological resource uses an electromagnetic field that creates a three-dimensional map of the cavity in which the exploratory catheter is located with millimetric precision [9]. With this feature, structures such as veins, arteries and cardiac chambers are visualized and manipulated to facilitate the localization of arrhythmogenic points, which can be treated by ablation.

* Corresponding author. Av. Princesa Isabel 395, Santana, CEP, 90620-000, Porto Alegre, RS, Brazil.

E-mail addresses: leonardomartinspires@gmail.com (L.M. Pires), tiagoluizluzleiria@gmail.com (T.L.L. Leiria).

Peer review under responsibility of Indian Heart Rhythm Society.

The exclusive use of MEA can be used to treat cardiac arrhythmias. Thus, we propose a study comparing therapeutic ablation procedures using conventional fluoroscopy image against the use of isolated MEA image in relation to success rate and procedure time.

2. Methods

Patients with arrhythmia and indication for ablation were selected at the Cardiology Institute (IC-FUC). Diagnostic electrophysiological studies, AF ablation and cases in which the two techniques could be used were excluded. The study was approved by the local Research Ethics Committee and all patients were submitted to an informed consent term.

The procedures were performed at the Laboratory of Electrophysiology of our Institution with a “C” Arm fluoroscopy equipment. Were used during the electrophysiology procedures the workstation Prucka®, Medtronic stimulator and EnSite® electroanatomical mapping system (St Jude Medical). All patients underwent intravenous sedation with propofol (100–150mcg/kg/min), midazolam (0.02–0.04 mg/kg) and fentanyl (0.5–2mcg/kg). Patients submitted to ventricular outflow tract ventricular arrhythmias did not use propofol. Right femoral veins were punctured with the introduction of three sheath introducers. In patients in the RX group, fluoroscopy with traditional technology was used, with bone images and a heart shadow as a reference for the introduction and placement of the catheters at their specific sites.

2.1. Manipulation and positioning of catheters in the exclusive electroanatomical system

A three-dimensional reconstruction of the vena cava through a multipolar exploratory catheter (His catheter) was performed for the placement of the catheters in the MEA patients, and the use of X-rays to reach the heart was not necessary at any time. The EnSite® system allows visualization of the catheters and their identification by color and spacing between the poles. Initially, the catheter to be positioned in the region of the His bundle was advanced until endocavitary signaling of the right ventricle and then repositioned with traction and torque movement to the septum until the appearance of the electrogram of the His bundle. Then, if a catheter was needed in the right atrium, it was positioned in the right atrium following the reconstruction performed by the His catheter. If a multipolar diagnostic catheter was used for the coronary sinus, it was also positioned following reconstruction by the His catheter and advanced until direct ventricular endocavitary signal was observed and then repositioned with traction, flexion and torque from the catheter to the septum, below the catheter already positioned in the His bundle, observing the endocavitary sign of the coronary sinus. Upon perceiving this endocavitary signal, the final positioning of the catheter with a slight deflection movement and introduction of the catheter through the coronary sinus was initiated. Positioning of ablation catheters in right chambers also followed the same principle. If pre-excitation was observed on the baseline electrocardiogram or during the electrophysiological study or left ventricular arrhythmia, a right femoral artery puncture was performed for the introduction of a retrograde aortic ablation catheter using the same method described previously for positioning the catheters in the interior the vessel and the left ventricle without the need for fluoroscopy. In all patients, atrial and ventricular pacing protocols were used to diagnose arrhythmias. When there was no success in these maneuvers, intravenous isoproterenol (2–10mcg/min) could also be used. If during or after the procedure there was suspicion of cardiac tamponade or valvular lesion, echocardiography would be performed promptly.

2.2. Outcomes

The outcomes measured in our study were the time of puncture (measurement of the time of entry of the patient into the room until the beginning of punctures for introduction of catheters), time of punctures (measurement of the duration of punctures for introduction of catheters), time of ablation (time after completion of the punctures until the end of the examination), total procedure time (sum of puncture time, puncture and ablation times), fluoroscopy time (total fluoroscopy time, if used in the procedure), success rates of therapeutic procedures and assessed the safety of the procedure using MEA alone.

The database was stored in the Microsoft Excel 2004 program. Assuming a pooled standard deviation of 15 min, the study would require a sample size of 9 patients for each group (i.e. a total sample size of at least 18, assuming equal group sizes), to achieve a power of 80% and a level of significance of 5% (two sided), for detecting a true difference between the test and the reference group of 20 (i.e. 80–60) minutes. Continuous data were analyzed by Student's t-test for repeated measures and comparisons between the two samples. For the analysis of the difference between the categorical variables, the chi-square test (Fischer) was used. For asymmetric variables, the Mann-Whitney test and ANCOVA were used for repeated measures. Statistical analysis was performed on SPSS (IBM Corp. Released 2013. IBM SPSS Statistics for Windows, Version 22.0, Armonk, NY: IBM Corp.). The randomization occurred at the time the procedure was scheduled (randomization pre-determined by the site www.randomizer.org) and the operator was informed at this time in which group the patient would be (MEA or RX). The analysis of the study was blinded to the statistic team.

The study was financed with funds from the Universal Announcement of CNPq 2012.

3. Results

Twelve patients in the group with fluoroscopy (RX group) and 11 patients in the group with exclusive use of MEA without fluoroscopy (MEA group) were selected. Demographic data are shown in Table 1. There was no difference in age between groups. In both groups, the female gender was predominant. Most patients in both groups were using some medication to control the arrhythmia. The most frequent indication for performing the procedure was

Table 1
Demographic data.

	Group RX N = 12	Group MEA N = 11	P
Age – years (DP)	48,5 (±12,6)	46,3 (±16,6)	ns
Gender (%)			
Female	7 (58%)	7 (63%)	ns
Medications (%)			
Beta-blocker	4 (33,3%)	3 (27,3%)	ns
Sotalol	2 (16,7%)	3 (27,3%)	ns
Amiodaron	1 (8,3%)	0	ns
Propafenon	0	1 (9%)	ns
Verapamil	3 (25%)	0	ns
No medication	2 (16,7%)	4 (36,4%)	ns
Induction (%)			
TSVP	9 (75%)	2 (18%)	<0,01
FLA paroxysmal	1 (8,3%)	0	ns
FLA permanent	0	4 (36,4%)	<0,01
ESV	1 (8,3%)	2 (18%)	ns
WPW	1 (8,3%)	3 (27,3%)	ns

Subtitle – RX = fluoroscopy; MEA = electroanatomical mapping; TSVP = paroxysmal supraventricular tachycardia; FLA = atrial flutter; ESV = ventricular extrasystole; WPW = pre-excitation syndrome.

paroxysmal supraventricular tachycardia (PSVT) with 9 cases in the RX group ($p < 0.01$) and atrial flutter (FLA) with 4 cases in the MEA group ($p < 0.01$).

On the day of the procedure, 11 patients were in sinus rhythm (RS) and 1 with pre-excitation (WPW). Of the patients in RS, one presented ventricular extrasystoles (ESV) and another presented a history of paroxysmal FLA. In the MEA group, 5 patients were in RS, 3 in FLA and 3 in WPW. Of the patients in RS, 2 had ESV and another had a history of paroxysmal FLA. Most of the patients used 3 catheters (two diagnoses and one ablation) for the examination. The 3 patients with FLA used 8 mm tip ablation catheters, while the others had 4 mm tip catheters. The RX group used a significantly lower proportion of decapolar type catheters when compared to the MEA group ($33\% \times 81\%$; $\% p < 0.026$). The mean conduction intervals were AH 98.3 ms ($DP \pm 32.7$ ms) and HV 40.6 ms (± 6.5 ms) in the RX and AH groups (excluding patients with FLA) 73.1 ms ($DP \pm 13$, 9 ms) and HV (including patients with FLA) 37.2 ms ($DP \pm 15.2$ ms) in the MEA group. The majority of patients in the RX group presented nodal reentrant tachycardia as diagnosis ($58.3\% \times 18.2\%$, $p < 0.01$). All patients with WPW had left lateral bundles with anterograde conduction. All patients with ESV had the right ventricular outflow tract as the arrhythmia focus. Isoproterenol was more commonly used in the RX group for induction of arrhythmias than in the MEA group ($50\% \times 18\%$, $p < 0.012$). The median total time of the procedures was lower in the RX group than in the MEA group (49 min \times 79 min, $p < 0.006$), as well as the mean time of porta-puncture (11.7 min \times 17 min, $p < 0.003$) and time median ablation (26.5 min \times 55 min, 0.012). Mean puncture time was similar between groups (9.1 min \times 7 min, $p = 0.169$). The mean number of radiofrequency energy applications in the RX group was lower ($6 \pm 3.5 \times 13.2 \pm 18.2$ $p < 0.019$). Immediate success (at hospital discharge) was similar between the groups - RX 11 patients and MEA 9 patients ($91.7\% \times 81.8\%$, $p = 0.46$). In the RX group the failure occurred with a patient with WPW and in the MEA group a patient with ESVSVD. One patient with FLA of the MEA group presented the arrhythmia in the left atrium and, because they did not agree to perform the transeptal puncture, no ablation was performed. Another patient in the MEA group with FLA in the right atrium presented arrhythmia reversal for RS; however, no bidirectional blockade of the ablation line was observed in the cavo-tricuspid isthmus. There were no complications during the procedures in both groups. Table 2 presents the data described.

Fluoroscopy was not used in any of the MEA cases. The mean fluoroscopy time of the RX group was 12.3 ± 8.5 min. Figs. 1 and 2 demonstrate slow pathway AV ablation in a patient with TRN. Fig. 3 shows ablation of a left lateral bundle during tachyarrhythmia.

These patients were observed for a period of 12 months after performing their procedures. Tachycardia recurred by nodal reentry two months later in one patient in the RX group. The patient was submitted to a new procedure, with new ablation of the slow pathway AV node with final resolution. There were no other recurrences in the other patients.

4. Discussion

The evolution of electrophysiology in diagnostic and therapeutic procedures has advanced significantly in recent years. The introduction of the MEA system opened new diagnostic and therapeutic possibilities for patients with complex arrhythmias. In a study of 21 pediatric patients referred for right pathway ablation, the use of fluoroscopy was reduced by 90% with concomitant use of MEA, after experience accumulated in seven cases, and was abandoned after another five new cases [10]. The use of MEA was effective in

Table 2
Procedure data.

	Group RX N = 12	Group MEA N = 11	
Rhythm (%)			
RS	11 (91,7%)	5 (45,4%)	
WPW	1 (8,3%)	3 (27,3%)	
FLA	0	3 (27,3%)	
Catheters (DP)			
Quadripolar	21	6	
-Decapolar	4	9	
Ablation 4 mm	11	7	
Ablation 8 mm	1	4	
Intervals (DP)			
AH	98,3 ($\pm 2,7$)	73,1 ($\pm 13,9$)*	0,036
HV	40,6 ($\pm 6,5$)	37,2 ($\pm 15,2$)	0,054
Arrhythmias			
TRN	7 (58,3%)	2 (18,2%)	
WPW - LE	2 (16,7%)	3 (27,3%)	
ESVSVD	1 (8,3%)	2 (18,2%)	
FLA - D	1 (8,3%)	2 (18,2%)	
FLA - E	0	1 (9,1%)	
No induction	1 (8,3%)	1 (9,1%)	
Isoproterenol (%)	6 (50%)	2 (18,2%)	0,012
N° applications			
Mean (DP)	6 ($\pm 3,5$)	13,2 ($\pm 18,2$)	0,019
Success (%)	11 (85,7%)	9 (81,8%)	ns
Times (min) (DP)			
Door-puncture	11,7 ($\pm 2,8$)	17 ($\pm 4,6$)	0,003
Puncture	9,1 ($\pm 4,2$)	7,0 ($\pm 2,7$)	0,169
Ablation	26,5 (9–81)	55 (22–130)	0,012
Total	49 (30–100)	79 (47–125)	0,006
Fluoroscopy	12,33 ($\pm 8,5$)	zero	Ns

Subtitle – RX = fluoroscopy; MEA = electroanatomic mapping; DP = standart deviation; TSVP = paroxysmal supraventricular tachycardia; FLA = flutter atrial; ESV = ventricular extrasystole; WPW = pre-excitation syndrome; FLA-D = right atrial flutter; FLA-E = leeft atrial flutter; ESVSVD = right ventricular outflow extrasystole, TRN = nodal reentrant tachycardia.

^a Atrial flutter patients excluded.

the pediatric population in another, in which it was responsible for a decrease in the exposure of children to the use of X-rays during nodal reentrant (TRN) and atrioventricular reentrant (TRAV) ablation procedures [11]. Forty pediatric patients with TRN and TRAV were divided into two groups of procedure - one using only fluoroscopy and another fluoroscopy and MEA. X-ray exposure time was lower in the group that used MEA [12] concomitantly. A group of 11 patients with an accessory bundle on the right lateral wall underwent ablation with unsuccessful fluoroscopy performed a new procedure using MEA, which was successful in all cases [13]. Nine pregnant patients with non-drug-controlled supraventricular tachycardias were submitted to ablation using MEA and a minimum of fluoroscopy time, and there were no recurrences after the procedure [14]. In the study, fluoroscopy and MEA (using two different systems - Carto[®] and the Ensite (NAVx)[®] system) were compared against fluoroscopy only in TRN, TRAV and FLA ablation in 145 patients. The use of fluoroscopy and MEA presented a shorter exposure time to radiation. However, total procedure time, short- and long-term success, complication rates, and absence of symptoms were similar between the groups [15]. Ablation of FLA with fluoroscopy against MEA and fluoroscopy was compared in a multicenter, randomized clinical trial involving 210 patients. Both techniques were effective in the treatment, but with less time of fluoroscopy and higher cost in the group that used MEA [16]. In a recent study, paroxysmal AF was performed using MEA alone and intracardiac echography in a group of 20 patients, with success in 97% of the cases and without complications [17]. In a multicenter study, it was demonstrated that it is possible to use a minimum of fluoroscopy in patients with TSVP, without prejudice to the results,



Fig. 1. Positioning of the catheters during ablation of nodal reentrant tachycardia. Left image (right anterior oblique view) shows catheter shadow with right bundle branch identification and His bundle region. It should be noted that the potential of His was identified in a region up to 1 cm in height. In the right image (left anterior oblique view), we note this fact, where we observed three levels of His, one more caudal, another intermediate and another more cranial. In part this may be due to the movement of the heart and the modification of the chest impedance during deep inspiration. However, it is important to clearly delineate this region to perform a safe application of radiofrequency. The structure in lilac is the coronary sinus. The blue spot (near the entrance of the coronary sinus) demonstrates a place where we obtained slow junctional rhythm. In red are other regions where the application of energy (15 s) did not trigger slow junctional rhythm.

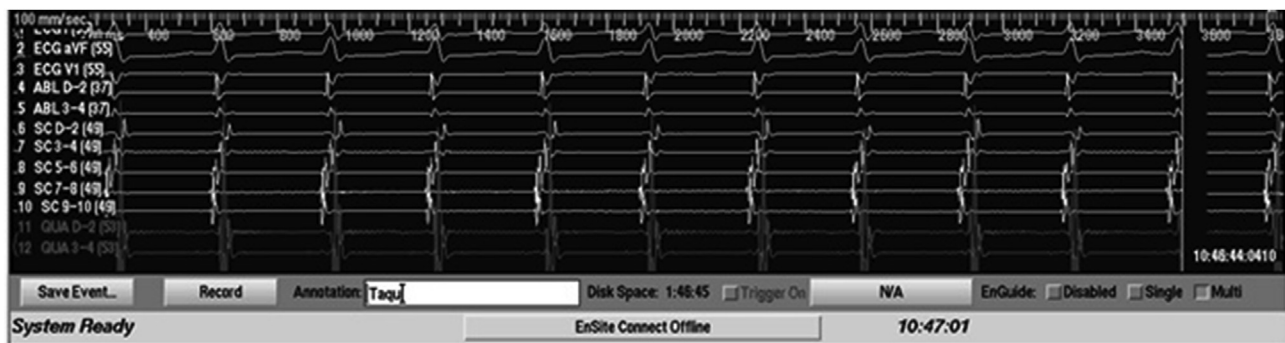

Fig. 2. Recording of supraventricular tachycardia initiated with the introduction of atrial extrastimuli at an earlier age. A VA interval <60 ms is observed during tachycardia and concentric retrograde atrial activation.

with the aid of MEA [18].

Currently, with the complexity of the arrhythmia ablation procedures, examination times are also prolonged. Therefore, the fluoroscopy time is increasing, with all the risks inherent to X-rays. The concomitant use in these MEA examinations not only helps to diagnose and treat arrhythmias, but also to reduce radiation risks in procedures that involve fluoroscopy. Although there are new technologies for the reduction of radiation during procedures in electrophysiology, not being exposed to fluoroscopy is better than being exposed.

In this study, we compared the use of fluoroscopy against the exclusive use of MEA in patients submitted to arrhythmia ablation. The results showed that it is possible to perform the procedure with satisfactory results. The success of the procedure was similar

between groups. It is observed that it was not necessary to use fluoroscopy in any of the cases of MEA and that there was no intercurrent in the patients. However, it was observed that the punch times, ablation time and total time of examination were higher in the MEA group. Carrying time was probably higher because of the time spent in monitoring patients with the EnSite mapping system boards. The ablation time may have been influenced by other variables. A higher number of decapolar catheters were observed in the MEA group, which could require a longer time to position the catheters in the cardiac cavities, increasing the time of the examination in these patients. In the RX group, there was a higher number of - TRN ablations. When the covariance analysis was performed, adjusting for catheter type variables and procedure indication, it was observed that these did not significantly influence

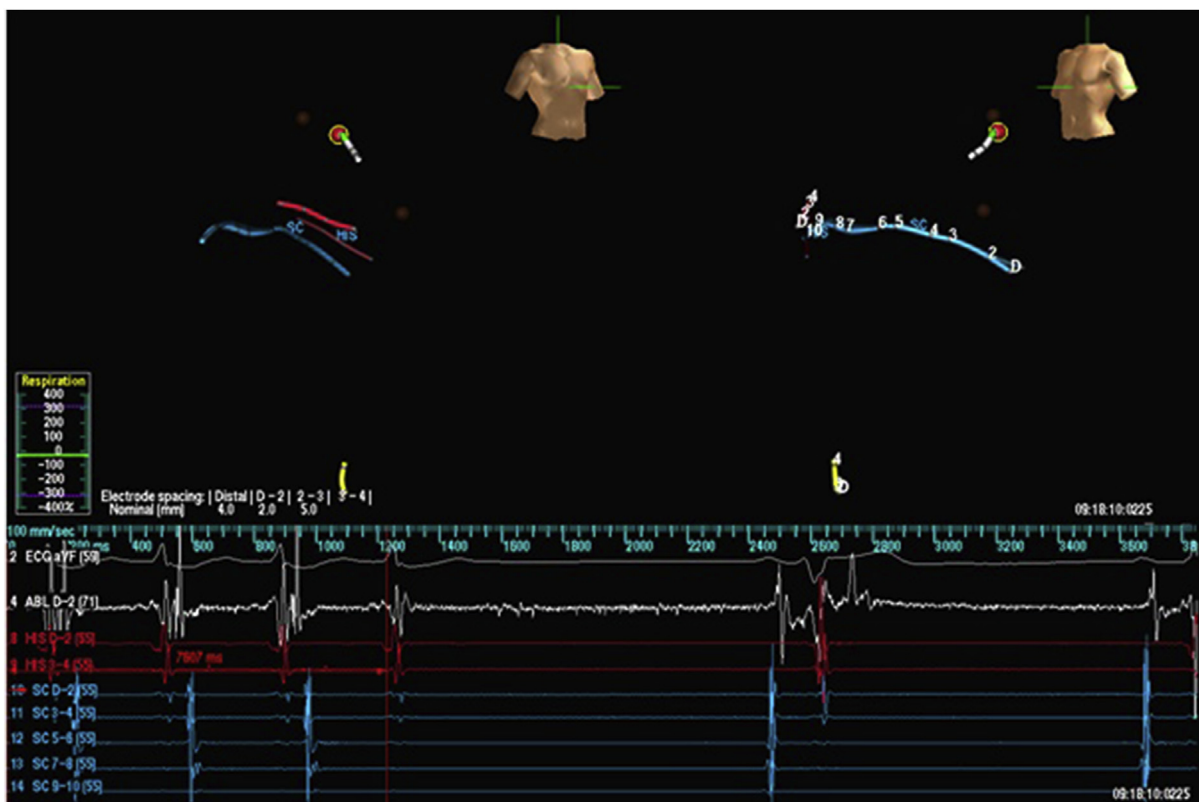


Fig. 3. Left lateral bundle ablation during tachyarrhythmia due to atrioventricular reentry. Left (right anterior oblique view) and right (left anterior oblique view) images show shade of the catheters with identification of the His bundle, coronary sinus, and ablation catheter. The ablation catheter was introduced by the aorta retrograde. In brown, two points with precocity are observed where radiofrequency energy applications were performed for 10 s, without ending the arrhythmia. The dot marked in red demonstrates the site of greater precocity of VA signal during tachyarrhythmia, observed in the endocavitary tracing below the figures. After 7.6 s of radiofrequency energy application, the arrhythmia was terminated. After this application, no further induction was possible.

Table 3

Geometric means for different aspects of the duration of the procedure, ratio of means and 95% confidence interval (95% CI) by the Student *t*-test (univariate analysis) and ANCOVA (covariance analysis), adjusting for the indication and catheter type factors.

Variável	Univariate Analysis				P	Covariance Analysis				
	MEA n = 11	RX n = 12	MEA/RX (%)	IC95%		MEA n = 11	RX n = 12	MEA/RX (%)	IC95%	P
Ablation time, min.	56.2	28.6	96.5	19.8 a 221.5	0.010	51.1	30.5	67.1	-14.1 a 225.8	0.123
Total time, min.	81.9	51.0	60.7	16.6 a 121.5	0.006	76.7	53.3	43.9	-6.7 a 121.8	0.095

Subtitle MEA: electroanatomical mapping; RX: fluoroscopy.

the ablation time of the procedures (Table 3). Probably, longer ablation times and total examination time may have been influenced by adapting to the use of the new technology.

However, our study has some limitations. This is an uni-blind study, which already has its limitations. Routine echocardiography was not performed in our hospital by budget limits. There were no suspected cases of tamponade during procedures. In the outpatient follow-up, no valvular lesions were observed on echocardiography requested by the attending physicians. As the procedures were performed on a “C” arm fluoroscopy equipment, it was not possible to calculate the cumulative radiation dose. Due to this technical limitation to measure the cumulative radiation dose, the fluoroscopy time was used as our surrogate end point. Despite these limitations, it was demonstrated that the procedure without fluoroscopy is possible to be performed, with satisfactory result and safety.

5. Conclusion

The introduction of the MEA opened new therapeutic

possibilities for patients with arrhythmias, reducing radiation risks in procedures involving fluoroscopy. It may be possible to decrease the fluoroscopic time with the aid of newer techniques during ablation procedures with increase in total procedure time and total health expenditure. However, fluoroscopic requirement may arise at any moment, though not encountered in this study.

Funding Source

The study was financed with funds from the Universal Announcement of CNPq 2012.

References

- [1] Page RL, Joglar JA, Caldwell MA, et al. ACC/AHA/HRS guideline for the management of adult patients with supraventricular tachycardia: a report of the American college of cardiology/American heart association task force on clinical practice guidelines and the heart rhythm society. *Heart Rhythm* 2015;13(4):e136–221. 2016.
- [2] Al-Khatib SM, Stevenson WG, Ackerman MJ, et al. AHA/ACC/HRS guideline for management of patients with ventricular arrhythmias and the prevention of

- sudden cardiac death. *Heart Rhythm* 2017;15(10):e190–252.
- [3] Russo AM, Stainback RF, Bailey SR, Epstein AE, Heidenreich PA. ACCF/HRS/AHA appropriate use criteria for implantable cardioverter-defibrillators and cardiac resynchronization therapy. *Heart Rhythm* 2013;10(4):e11–58.
- [4] Roguin A, Goldstein J, Bar O, Goldstein JA. Brain and neck tumors among physicians performing interventional procedures. *Am J Cardiol* 2013;111(9):1368–72.
- [5] Limacher MC, Douglas PS, Germano G, et al. Radiation safety in the practice of cardiology. *JACC (J Am Coll Cardiol)* 1998;31(4):892–913.
- [6] Birnie D, Healey JS, Krahn AD, et al. Prevalence and risk factors for cervical and lumbar spondylosis in interventional electrophysiologists. *J Cardiovasc Electrophysiol* 2011;22(9):957–60.
- [7] Gepstein L, Hayam G, Ben-Haim SA. A novel method for nonfluoroscopic catheter-based electroanatomical mapping of the heart. In vitro and in vivo accuracy results. *Circulation* 1997;95(6):1611–22.
- [8] Wittkamp F, Wever E, Derksen R, et al. Localisa: new technique for real-time 3-dimensional localization of regular intracardiac electrodes. *Circulation* 1999;99(10):1312–7.
- [9] Gepstein L, Hayam G, Shpun S, Cohen D, Ben-Haim AS. Atrial linear ablations in pigs chronic effects on atrial electrophysiology and pathology. *Circulation* 1999;100(4):419–26.
- [10] Drago F, Silvetti MS, Di Pino A, et al. Exclusion of fluoroscopy during ablation treatment of right accessory pathway in children. *J Cardiovasc Electrophysiol* 2002;13(8):778–82.
- [11] Smith G, et al. Elimination of fluoroscopy use in a pediatric electrophysiology laboratory utilizing three-dimensional mapping. *Pacing Clin Electrophysiol* 2007;30(4):510–8.
- [12] Papagiannis J, Tsoutsinos A, Kirvassilis G, et al. Nonfluoroscopic catheter navigation for radiofrequency catheter ablation of supraventricular tachycardia in children. *Pacing Clin Electrophysiol* 2006;29(9):971–8.
- [13] Chen M, Yang B, Ju W, et al. Right-Sided free wall accessory pathway refractory to conventional catheter ablation: lessons from 3-dimensional electroanatomic mapping. *J Cardiovasc Electrophysiol* 2010;21(12):1317–24.
- [14] Szumowski L, Szufiadwicz E, Orczykowski M, et al. Ablation of severe drug-resistant tachyarrhythmia during pregnancy. *J Cardiovasc Electrophysiol* 2010;21(8):877–82.
- [15] Earley MJ, Showkathali R, Alzetani M, et al. Radiofrequency ablation of arrhythmias guided by non-fluoroscopic catheter location: a prospective randomized Trial. *Eur Heart J* 2006;27(10):1223–9.
- [16] Hindricks G, Willems S, Krautzer J, et al. Effect of electroanatomically guided versus conventional catheter ablation of typical atrial flutter on the fluoroscopy time and resource use: a prospective randomized multicenter study. *J Cardiovasc Electrophysiol* 2009;20(7):734–40.
- [17] Reddy VY, Morales G, Ahmed H, et al. Catheter ablation of atrial fibrillation without the use of fluoroscopy. *Heart Rhythm* 2010;7(11):1644–53.
- [18] Casella M, Russo AD, Pelargonio G, et al. Near zero fluoroscopic exposure during catheter ablation of supraventricular arrhythmias: the NO-PARTY multicentre randomized trial. *Europace* 2016;18(10):1565–72.