

# Characterisation of two unusual cases of haemoglobin Bart's hydrops foetalis caused by $-^{SEA}$ and large novel $\alpha$ -globin gene cluster deletions

Journal of International Medical Research

49(2) 1–10

© The Author(s) 2021

Article reuse guidelines:

[sagepub.com/journals-permissions](https://sagepub.com/journals-permissions)

DOI: 10.1177/0300060521993642

[journals.sagepub.com/home/imr](https://journals.sagepub.com/home/imr)

Yunan Wang<sup>1,2,3,\*</sup>, Ying Xiong<sup>1,2,3,\*</sup>,  
Chang Liu<sup>1,2,3</sup>, Jian Lu<sup>1,2,3</sup>, Jicheng Wang<sup>1,2,3</sup>,  
DanQing Qin<sup>1,2,3</sup>, Ling Liu<sup>1,2,3</sup>, Jing Wu<sup>1,2,3</sup> ,  
Xin Zhao<sup>1,2,3</sup>, Liyuan Fang<sup>1,2,3</sup>, Li Du<sup>1,2,3,\*</sup> and  
Aihua Yin<sup>1,2,3,\*</sup> 

## Abstract

**Background:** We describe 2 unusual haemoglobin (Hb) Bart's hydrops cases that could not be explained by traditional factors.

**Case presentation:** Two families with a diagnosis or history of foetal hydrops were enrolled. A suspension-array system was used to detect the 23 most frequent mutations in southern China. Multiplex ligation-dependent probe amplification (MLPA) was used to screen for possible deletions. Precise characterisation of the breakpoints of the novel variants and uniparental disomy analysis were performed using a single nucleotide polymorphism (SNP) array. Quantitative fluorescence PCR was used to eliminate maternal cell contamination and nonpaternity. In case 1, the suspension-array system indicated a maternal heterozygous ( $-^{SEA}$ ) deletion, and the paternal sample was negative. The foetal hydrops was caused by the maternal ( $-^{SEA}$ ) deletion and a de novo  $\alpha$ -globin gene deletion ( $-^{193}$ ). In case 2, the paternal sample had a heterozygous ( $-^{SEA}$ ) deletion, and MLPA and SNP array analysis revealed a large maternal deletion ( $-^{227}$ ) that encompassed the  $\alpha$ -globin gene, which explained the history of Hb Bart's foetal hydrops.

<sup>1</sup>Medical Genetic Center, Guangdong Women and Children Hospital, Guangzhou, Guangdong, China

<sup>2</sup>Maternal and Children Metabolic-Genetic Key Laboratory, Guangdong Women and Children Hospital, Guangzhou, Guangdong, China

<sup>3</sup>Guangdong Thalassemia Diagnostic Center, Guangzhou, Guangdong, China

\*These authors contributed equally to this work.

## Corresponding author:

Aihua Yin, Medical Genetic Center, Guangdong Women and Children Hospital, No. 521-523, Xingnan Road, Panyu District, Guangzhou, Guangdong 510010, P. R. China.  
Email: [yinaihua0131@163.com](mailto:yinaihua0131@163.com)



**Conclusions:** Our cases describe 2 new  $\alpha^0$ -thalassaemia deletions and illustrate the importance of using a combination of methods to detect rare types of  $\alpha$ -thalassaemia.

### Keywords

Haemoglobin Bart's hydrops,  $\alpha$ -thalassaemia, novel deletions,  $-\text{SEA}$  deletion, SNP array, multiplex ligation-dependent probe amplification

Date received: 18 October 2020; accepted: 19 January 2021

## Introduction

Worldwide, approximately 5% of the population are carriers of thalassaemia.<sup>1</sup>  $\alpha$ -Thalassaemia ( $\alpha$ -thal) is the most common monogenetic disease in southern China.<sup>2</sup> Most  $\alpha$ -thal cases are caused by deletions of the  $\alpha$ -globin gene on the short arm of chromosome 16 (16p13.3).<sup>3</sup> Clinically, people who are heterozygous for  $\alpha$ -thal are typically asymptomatic; however, carriers of  $\alpha^0$ -thal exhibit  $\alpha$ -thal traits and have reduced levels of mean corpuscular haemoglobin (Hb) (MCH) and mean corpuscular volume (MCV).<sup>4</sup> Couples in which both carry a  $\alpha^0$ -thal gene have a 25% chance of having foetus with a thalassaemia major genotype in each pregnancy, which manifests as Hb Bart's hydrops foetalis. Most fetuses with  $\alpha$ -thal major die in utero during late pregnancy or the very early neonatal period and typically have accompanying congenital abnormalities. In addition,  $\alpha$ -thal major increases the risk of severe obstetrical complications.<sup>5-7</sup>

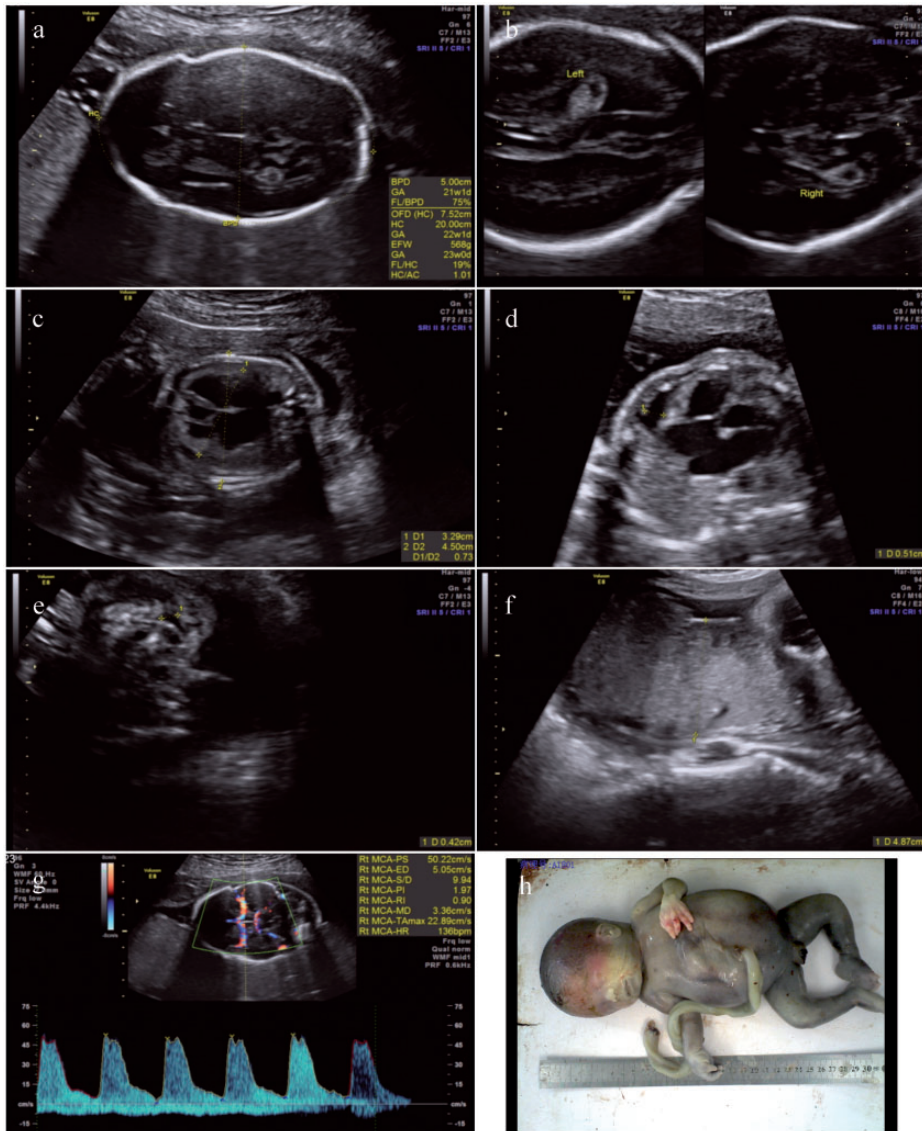
In China, the Southeast Asian ( $-\text{SEA}$ ) deletion is the major type of  $\alpha^0$ -thal, and  $-\alpha^{3.7}$  and  $-\alpha^{4.2}$  are the main types of  $\alpha^+$ -thal. Hb Constant Spring ( $\alpha\text{CS}$ ), Hb Quong Sze ( $\alpha\text{QS}$ ), and Hb Westmead ( $\alpha\text{WS}$ ) are the major mutation types.<sup>8</sup> In general, these three deletions and three mutations account for approximately 95% of  $\alpha$ -thal cases in China. Therefore, routine

DNA analysis is conducted to detect the above deletions and mutations. To date, more than 300 deletions and mutations from the  $\alpha$ -globin cluster have been reported (<http://globin.bx.psu.edu/cgi-bin/hbvar/counter>); inevitably, therefore, many less-common deletions and mutations remain undetected when conventional detection methods are used. In this report, we describe two unusual cases of Hb Bart's hydrops foetalis in Chinese families caused by the  $-\text{SEA}$  deletion and a large new  $\alpha$ -globin gene cluster deletion, which were detected using a combination of different methods.

## Case reports

### Case 1

The patient, a 22-year-old gravida 1 para 0 woman, was referred to our centre at 24<sup>+4</sup> weeks of gestation; her spouse was 26 years old. Both were of QingYuan, Guangdong, ancestry. Prenatal ultrasonography at 24 weeks of gestation indicated foetal hydrops with cardiomegaly (cardiothoracic ratio 0.73), pericardial effusion, a small amount of ascites, bilateral pleural effusion, echogenic bowel, bilateral choroid plexus cyst, thickened placenta, and elevated middle cerebral artery peak systolic velocity (50.22 cm/s, >1.55 multiples of the median)



**Figure 1.** Sonographic markers of foetal hydrops. (a) Biparietal diameter: 50 mm; (b) bilateral choroid plexus cyst; (c) cardiomegaly (cardiothoracic ratio 0.73); (d) pericardial effusion; (e) small amount of ascites; (f) placental thickness; (g) ultrasonography showing the elevated middle cerebral artery peak systolic velocity at 24 weeks of gestation (50.22 cm/s, >1.55 multiples of the median); and (h) aborted foetus with hydrops features.

(Figure 1), which was highly suspicious for a significant risk for severe anaemia.

The couple agreed to participate in our study and signed informed consent forms.

The study was approved by the Ethics Committee of Guangdong Women and Children Hospital (IRB reference number: 201811179) and complies with the CARE

case report guidelines.<sup>9</sup> We have deidentified the details such that the identity of the patient cannot be ascertained in any way.

After pretest counselling, percutaneous umbilical blood sampling was offered to the parents. Umbilical cord blood test results of TORCH (toxoplasmosis, rubella cytomegalovirus, herpes simplex, and HIV) analysis, parvovirus B19 analysis, and glucose-6-phosphate dehydrogenase deficiency (G6PD) screening were normal. Routine foetal blood examination revealed severe foetal anaemia with an Hb level of 5.9 g/dL (reference range for 24-week foetus: >10 g/dL). Hb electrophoresis analysis showed significantly elevated Hb Bart's (89.3%) and Hb Portland (5.9%) (Table 1), indicating Bart's hydrops foetalis. The pregnant woman had a rhesus positive O blood type. Results of screening for red blood cell antibodies, TORCH analysis, G6PD deficiency screening, parvovirus infection, and foeto-maternal haemorrhage detection by the Kleihauer-Betke test were all negative. The haematological data and thalassaemia genotypes of the family are summarised in Table 1. The patient had a decreased MCV (70.7 fL) and MCH (25.1 pg), and her spouse's MCV and MCH were normal.

The suspension-array system, which detects the 23 most frequent deletions and mutations in southern China, suggested that the mother had a  $^{-SEA/}$  deletion, the paternal sample was negative for both  $\alpha$ -thal and  $\beta$ -thal, and the foetal sample had a homozygous ( $^{-SEA/}$ ) deletion, which was not in accordance with Mendelian inheritance. DNA sequencing of the  $\alpha$ -globin gene of the paternal sample did not reveal any mutation. The results of gap-PCR, which detects uncommon deletion mutations ( $^{-FIL/}$ ,  $^{-THAI/}$ ,  $^{-11.1/}$ ,  $^{-27.6/}$ ,  $^{-21.9/}$ ), were negative. Other causes should be considered in the differential diagnosis of Bart's hydrops foetalis,

including uniparental disomy (UPD), non-paternity, or a de novo deletion causing  $\alpha^0$ -thal. Nonpaternity was first excluded by quantitative fluorescence PCR (QF-PCR). The karyotype of the foetus was normal (46,XX). However, single nucleotide polymorphism (SNP) array testing of the foetus, which was performed on a commercial 750K microarray chip (Affymetrix CytoScan 750K Array; Affymetrix/Thermo Fisher Scientific, Santa Clara, CA, USA), indicated a loss of 196 kb in 16p13.3. The deletion region included *HBA1* and *HBA2*, which would explain the clinical manifestation of Bart's hydrops foetalis in the absence of both  $\alpha$ -globin genes. This finding might also explain why the family samples were not consistent with Mendelian inheritance indicated by the suspension-array system. SNP array technology also excluded UPD through SNP allele pattern analysis. The 5' deletion breakpoint was located upstream of the *POLR3K* gene, and the 3' breakpoint was located downstream of the *LUC7L* gene. Compared with the references, the 5' breakpoint of the deletion was located at 85,880, and the 3' breakpoint was located between 282,157 and 293,265 (Figure 2). To the best of our knowledge, this large deletion has not been reported before. Microdeletions were not detected in the pregnant woman or her spouse, indicating that the deletion was a de novo copy number variation.

After counselling, the decision was made to terminate the pregnancy. The aborted foetus had characteristics of hydrops along with an enlarged placenta (Figure 1). Autopsy indicated foetal hydrops with cardiomegaly, pericardial effusion, ascites, bilateral pleural effusion, and bilateral choroid plexus cyst.

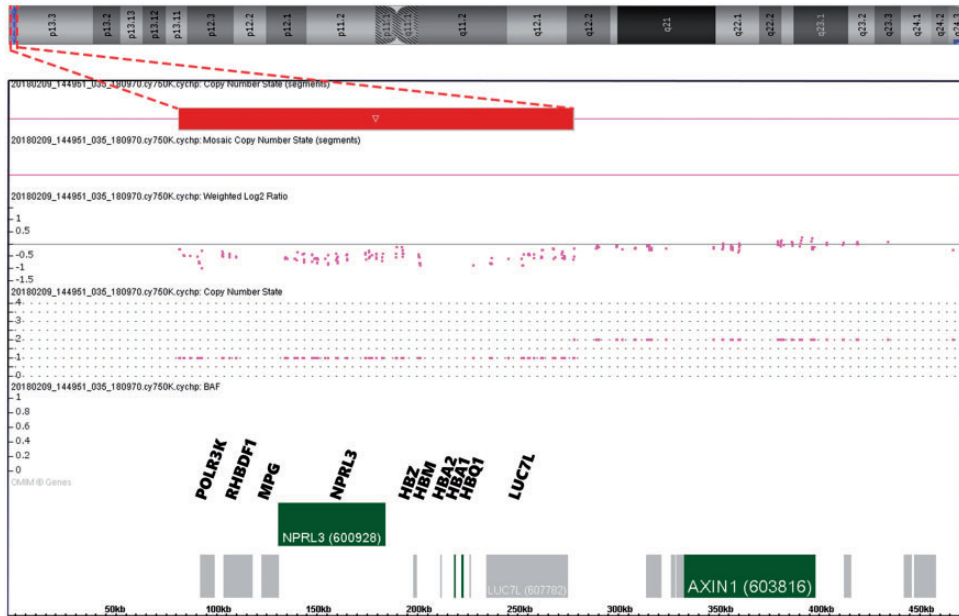
## Case 2

A couple from PanYu, Guangdong, visited our centre for high-risk screening for Down

**Table 1.** Haematological and molecular data of the 2 families under study.

Variables	Case 1			Case 2		
	Mother	Father	Foetus	Mother	Father	Foetus
Sex and age (years)	F, 22	M, 26	24 weeks of gestation	F, 31	M, 36	18 weeks of gestation
Specimen type	Peripheral blood	Peripheral blood	Umbilical cord blood	Peripheral blood	Peripheral blood	Amniotic fluid
Hb (g/dL)	11.1	13.5	5.9	10.5	12.3	—
RBC ( $10^{12}/dL$ )	3.8	4.3	2.11	3.9	4.1	—
MCV (fL)	70.7	89.9	110.3	69.8	66.7	—
MCH (pg)	25.1	29.5	27.9	25.3	25.8	—
Hb A	97.2	97.3	0	97.6	97.9	—
Hb A2	2.1	2.7	0	2.4	2.1	—
Hb F	0.7	0	0	0	0	—
Hb Bart's	0	0	89.3	0	0	—
Hb Portland	0	0	5.9	0	0	—
Hb Epsilon4	0	0	1.3	0	0	—
Hb Gower I	0	0	3.5	0	0	—
Serum ferritin (ng/mL)	130.1	145.6	ND	121.6	137.8	—
G6PD screening	Normal	Normal	Normal	Normal	Normal	Normal
$\alpha$ -Genotype	$-\text{SEA}/\beta\alpha$	$\alpha\alpha/\alpha\alpha$	$-\text{SEA}/-^{196}$	$-\text{SEA}/\beta\alpha$	$-\text{SEA}/\alpha\alpha$	$-\text{SEA}/\alpha\alpha$
$\beta$ -Genotype	$\beta N/\beta N$	$\beta N/\beta N$	$\beta N/\beta N$	$\beta N/\beta N$	$\beta N/\beta N$	$\beta N/\beta N$

Hb, haemoglobin; RBC, red blood cell count; MCV, mean corpuscular volume; MCH, mean corpuscular Hb; ND, not done; G6PD, glucose-6-phosphate dehydrogenase;  $-\text{SEA}/$ , Southeast Asian deletion.



**Figure 2.** Identification and characterisation of the novel  $-196$  deletion in case 1. SNP array analysis demonstrated that the probe distribution of the foetus was consistent with a single copy number loss in the region of 16p13.3. The deletion areas are marked as red blocks. The 5' breakpoint of the deletion was located at 85,880 (hg 19), and the 3' breakpoint was located between 282,157 and 293,265 (hg 19). The deleted region contained 10 genes, including the entire  $\alpha$ -globin gene cluster (*HBZ*, *HBM*, *HBA2*, *HBA1*, and *HBQ1*) and its regulatory region.

syndrome. The pregnant woman and her spouse were 31 and 35 years old, respectively. This was her fourth pregnancy, and all of her previous pregnancies ended with foetal hydrops and intrauterine foetal death. Because of the high prevalence of thalassaemia in Guangdong, thalassaemia major was considered first, and thalassaemia testing was provided to the couple. The resulting haematological indices and thalassaemia genotypes are summarised in Table 1. The pregnant woman and her spouse both had decreased MCV and MCH. The suspension-array system detected  $-SEA/$  deletions in the paternal sample, whereas the maternal sample was negative for both  $\alpha$ -thal and  $\beta$ -thal. Iron deficiency was excluded. These results suggested that the pregnant woman carried an

uncommon defective allele, and the couple sought further diagnosis.

The couple signed informed consent forms before participating in our study. The study was approved by the Ethics Committee of Guangdong Women and Children Hospital (IRB reference number: 201811179) and it complies with the CARE case report guidelines.<sup>9</sup> We have deidentified the details such that the identity of the patient may not be ascertained in any way.

Gap-PCR results of the pregnant woman were negative. DNA sequencing of the  $\alpha$ -globin gene revealed no mutations. Multiplex ligation-dependent probe amplification (MLPA; probe mix P140-C1 HBA; MRC Holland, Amsterdam, the Netherlands) revealed a large deletion, and the fragment included the  $\alpha$ -globin gene


cluster. As indicated in the MLPA results, the 5' breakpoint was at (hg19) chr16: 97,132, and the 3' breakpoint was located between chr16: 289,926 and 321,756. This finding may explain the  $\alpha^0$ -thal trait and the history of recurrent foetal hydrops in previous pregnancies. After pretest counseling, amniocentesis was offered to the couple, and amniocytes were collected through ultrasound-guided percutaneous amniocentesis for G-banding karyotype analysis, chromosome microarray analysis, gap-PCR detection of common deletional thalassaemia mutations, and MLPA detection of the large deletion, similar to the maternal sample. G-banding karyotype analysis revealed a normal female karyotype (46,XX). The suspension-array system indicated that the amniotic sample was negative for both  $\alpha$ -thal and  $\beta$ -thal. MLPA revealed a large deletion inherited from the mother. This deletion was further confirmed by the SNP array and encompassed an approximately 227-kb deletion at 16p13.3 that included the *POLR3K*, *RHBDF1*, *MPG*, *NPRL3*, *HBZ*, *HBM*, *HBA2*, *HBA1*, *HBQ1*, *LUC7L*, and *FAM234A* genes (Figure 3). To the best of our knowledge, this large deletion has not been reported previously. At 39<sup>+3</sup> weeks, a healthy female baby was born, with a birth weight of 3250 g. Neonatal examinations and follow-up at the age of 1 year suggested normal childhood development.

## Discussion

In Guangdong Province, the prevalence of  $\alpha$ -thal is approximately 8.53%, and the  $-\text{SEA}$  type is the most common.<sup>8</sup> Couples in which both are carriers have a 25% chance of conceiving a foetus with  $\alpha$ -thal major during each pregnancy.<sup>5,7</sup> The best strategy for controlling thalassaemia major is to screen and identify carriers and to provide the option of prenatal diagnosis to at-risk couples. In Guangdong

Province, a prenatal screening and diagnosis programme for thalassaemia has been in operation for several years. The diagnostic marker for  $\alpha$ -thal is a decreased HbA<sub>2</sub> level (<2.5%) with decreased MCV (<82 fL) or MCH (<26 pg) value.<sup>10</sup> This screening strategy plays an important role in controlling thalassaemia major. However, the screening programme does not detect every case. The two cases reported here highlight some problems that may exist in the screening strategy. First, as noted in case 1, the existence of de novo deletions might pose a diagnostic problem for the screening strategy, which focuses on maternal and paternal MCV and MCH values alone. This problem also exists in the occurrence of maternal or paternal UPD<sup>10</sup> and nonpaternity, which have been previously reported in the literature.<sup>11-14</sup> Second, the prevalence of thalassaemia is population-dependent. Thus, in our area of Guangdong Province, routine DNA analysis is restricted to three common deletions ( $-\text{SEA}/$ ,  $-\alpha3.7/$  and  $-\alpha4.2/$ ) and three common mutations ( $\alpha\text{CS}\alpha/$ ,  $\alpha\text{QS}\alpha/$ ,  $\alpha\text{WS}\alpha/$ ). To date, approximately 70 deletions involving the  $\alpha$ -globin gene have been found; therefore, many deletions might be missed when diagnoses are performed using conventional techniques. Therefore, when a diagnosis of Bart's hydrops foetalis is confirmed and cannot be explained by conventional methods, the differential diagnosis should be comprehensive. In addition, prenatal diagnosis of thalassaemia is recommended.

Differential diagnosis of Bart's hydrops foetalis includes maternal or paternal UPD, nonpaternity, and de novo deletions affecting the  $\alpha$ -globin gene cluster. Hb electrophoresis analysis was used to confirm the diagnosis of Bart's hydrops foetalis. QF-PCR with different highly polymorphic short tandem repeat markers for chromosomes 13, 18, 21, X, and Y was used to exclude nonpaternity. A SNP array was



**Figure 3.** Identification and characterisation of the novel  $\alpha$ -227 deletion in case 2. (a) SNP array analysis demonstrated that the probe distribution of the foetus was consistent with a single copy number loss in the region of 16p13.3. The deletion areas are marked as red blocks. The 5' breakpoint of the deletion was located at 85,880 (hg 19), and the 3' breakpoint was located between 312,739 and 318,501 (hg 19). The deleted region contained 11 genes, including the entire  $\alpha$ -globin gene cluster (HBZ, HBM, HBA2, HBA1, and HBQ) and its regulatory region. (b) Multiplex ligation-dependent probe amplification analysis of the  $\alpha$ -globin gene cluster in the mother and foetus. The y-axis represents the signal ratio compared with the normal control (ratio 1), and the probes on the x-axis are ordered chronologically in the 5' to 3' direction. The ratios of the deletional region reach only half of that of the control, approximately 0.5, which is consistent with one copy of the  $\alpha$ -globin cluster being present.



conducted to detect maternal or paternal UPD. Numerous diagnostic approaches are available to detect deletional thalassaemia, the most common of which is gap-PCR. However, this assay will only detect several common thalassaemia deletions with known breakpoints, and rare mutations or deletions will not be detected. MLPA can be used to identify novel  $\alpha$ -globin deletions and duplications. More precise characterisation of the breakpoint of novel variants can be achieved with high-resolution chromosome microarrays due to the high density of probes. Therefore, a combination of different methods is important when screening for  $\alpha$ -globin gene rearrangements in thalassaemias and haemoglobinopathies. Patients who exhibit an  $\alpha$ -thal trait phenotype clinically but have no mutations and patients conceiving a foetus with Hb Bart's hydrops foetalis but who only have one thalassaemia mutation detected via conventional methods should receive further molecular testing using multiple platforms, including Hb electrophoresis analysis, gap-PCR, QF-PCR, MLPA, and SNP array.

Sonographic markers can also be used to differentiate normal pregnancies from those with Hb Bart's hydrops foetalis, which plays a crucial role in the prevention of  $\alpha$ -thal major.<sup>15</sup> As shown by our two cases, if a mid-trimester anomaly scan is not provided to patients, the diagnosis is generally missed. Therefore, a prenatal anomaly ultrasonography scan should be offered to all couples in which one or both are carriers of  $\alpha^0$ -thal. In high-prevalence areas of thalassaemia, obstetricians and sonographers should be on high alert for signs of foetal anaemia, including cardiomegaly, enlarged placenta, pleural effusion, pericardial effusion, and ascites, especially focusing on the cardiothoracic ratio, which might be an early indication in the first trimester, even if screening shows that pregnancy is at low risk.

In this study, we explored two large deletions ( $-^{196}$  and  $-^{227}$ ) in chromosome 16p13.3 using a combination of different methods. Similar to the large deletions reported previously,<sup>16-18</sup> these deletions removed the entire  $\alpha$ -globin gene cluster, including the upstream  $\alpha$ -globin regulatory elements, which subsequently reduced the synthesis of the  $\alpha$ -globin chain and led to the  $\alpha^0$ -thal phenotype. To describe the exact breakpoints of the two deletions, we designed different PCR primers flanking the breakpoints provided by the SNP array or MLPA. However, because the telomere region is rich in repetitive nucleotide sequences, we were unable to design efficient PCR primers. This limitation resulted in failure to obtain sufficient specific PCR products for Sanger sequencing. The mechanism leading to this deletion remains unknown.

## Conclusion

In the cases described here, we identified a de novo  $\alpha^0$ -thal deletion and an unknown  $\alpha^0$ -thal deletion. Further use of MLPA and SNP arrays would undoubtedly allow identification more large deletions affecting the  $\alpha$ -globin gene cluster that cause  $\alpha$ -thal, which will facilitate accurate diagnoses and proper genetic counselling of at-risk couples.

## Declaration of conflicting interests


The authors declare that there is no conflict of interest.


## Funding

The authors disclosed receipt of the following financial support for the research, authorship, and/or publication of this article: This work was supported by the National Natural Science Foundation of Guangdong, China (grant no. 2016A030313787); the Science and Technology Program of Guangzhou, China (grant no. 202002030390), and the Medical Science and

Technology Research Project of Guangdong Province (grant nos. A2018260, B2019010 and A2019358). The funding body did not play a role in the design of the study, collection, analysis, or interpretation of data or writing of the manuscript.

### ORCID iDs

Jing Wu  <https://orcid.org/0000-0002-0849-9876>

Aihua Yin  <https://orcid.org/0000-0003-1669-7781>

### References

1. Piel FB and Weatherall DJ. The alpha-thalassaemias. *N Engl J Med* 2014; 371: 1908–1916.
2. Xu XM, Zhou YQ, Luo GX, et al. The prevalence and spectrum of alpha and beta thalassaemia in Guangdong Province: implications for the future health burden and population screening. *J Clin Pathol* 2004; 57: 517–522.
3. Higgs DR. The molecular basis of alpha-thalassaemia. *Cold Spring Harb Perspect Med* 2013; 3: a11718.
4. Hartevelde CL and Higgs DR. Alpha-thalassaemia. *Orphanet J Rare Dis* 2010; 5: 13.
5. Liang ST, Wong VC, So WW, et al. Homozygous alpha-thalassaemia: clinical presentation, diagnosis and management. A review of 46 cases. *Br J Obstet Gynaecol* 1985; 92: 680–684.
6. Siriratmanawong N, Pinmuang-Ngam C, Fucharoen G, et al. Prenatal diagnosis of Hb Bart's hydrops fetalis caused by a genetic compound heterozygosity for two different alpha-thalassaemia determinants. *Fetal Diagn Ther* 2007; 22: 264–268.
7. Liao C, Wei J, Li Q, et al. Nonimmune hydrops fetalis diagnosed during the second half of pregnancy in Southern China. *Fetal Diagn Ther* 2007; 22: 302–305.
8. Yin A, Li B, Luo M, et al. The prevalence and molecular spectrum of alpha- and beta-globin gene mutations in 14,332 families of Guangdong Province, China. *PLoS One* 2014; 9: e89855.
9. Gagnier JJ, Kienle G, Altman DG, et al. The CARE guidelines: consensus-based clinical case reporting guideline development. *BMJ Case Rep* 2013; 2013: bcr2013201554.
10. Liao C, Pan M, Han J, et al. Prenatal control of Hb Bart's hydrops fetalis: a two-year experience at a mainland Chinese hospital. *J Matern Fetal Neonatal Med* 2015; 28: 413–415.
11. Wattanasirichaigoon D, Promsonthi P, Chuansumrit A, et al. Maternal uniparental disomy of chromosome 16 resulting in hemoglobin Bart's hydrops fetalis. *Clin Genet* 2008; 74: 284–287.
12. Kou KO, Lee H, Lau B, et al. Two unusual cases of haemoglobin Bart's hydrops fetalis due to uniparental disomy or non-paternity. *Fetal Diagn Ther* 2014; 35: 306–308.
13. Beldjord C, Henry I, Bennani C, et al. Uniparental disomy: a novel mechanism for thalassaemia major. *Blood* 1992; 80: 287–289.
14. Kwan WY, So CH, Chan WP, et al. Re-emergence of late presentations of fetal haemoglobin Bart's disease in Hong Kong. *Hong Kong Med J* 2011; 17: 434–440.
15. Leung KY, Liao C, Li QM, et al. A new strategy for prenatal diagnosis of homozygous alpha(0)-thalassaemia. *Ultrasound Obstet Gynecol* 2006; 28: 173–177.
16. Gilad O, Dgany O, Noy-Lotan S, et al. Characterization of two unique alpha-globin gene cluster deletions causing alpha-thalassaemia in Israeli Arabs. *Hemoglobin* 2014; 38: 319–324.
17. He S, Qin Q, Huang P, et al. Characterization of a large novel alpha-globin gene cluster deletion causing alpha(0)-thalassaemia in a Chinese family. *Hemoglobin* 2017; 41: 297–299.
18. He S, Li J, Huang P, et al. Characterization of Hb Bart's hydrops fetalis caused by  $\alpha$ -(SEA) and a large novel alpha(0)-thalassaemia deletion. *Hemoglobin* 2018; 42: 61–64.