

One-by-one immediate dental implants: A papillae preservation concept for adjacent implants in a compromised periodontal case

Georges Khoury^{1,2} | Frédéric Chamieh^{1,3} | Olivier Fromentin^{4,5}

¹Department of Advanced Surgical Implantology, Service of Odontology, U.F.R. of Odontology, Rothschild Hospital, AP-HP, University Denis Diderot, Paris, France

²Private practice, Paris, France

³Private practice, Chartres, France

⁴Department of Implantology, Service of Odontology, U.F.R. of Odontology, Rothschild Hospital (AP-HP), University Denis Diderot, Paris, France

⁵Innovative Dental Materials and Interfaces Research Unit (EA4462), University Paris Descartes, Paris, France

Correspondence

Khoury Georges, U.F.R d'Odontology, 5, rue Garancière, 75006 Paris, France.
Email: dr.georges.khoury@gmail.com

Abstract

In an immediate implant placement and provisionalization strategy, the esthetic results of multiple adjacent implants can be obtained even with compromised periodontium by implementing the “one-by-one” protocol. Staged extractions of multiple adjacent teeth to maintain soft tissue architecture are a key feature of the technique described.

KEYWORDS

esthetics, fresh extraction, immediate implant placement, immediate provisionalization, multiple teeth, papilla preservation

1 | INTRODUCTION

The purpose of this report is to describe a protocol for the fixed restoration of multiple periodontically compromised adjacent failing teeth, combining immediate implant placement, papilla support, and sequential treatment. The “one-by-one” concept is intended to preserve papillae and soft tissue contours even without an interproximal bony support.

The esthetic outcomes of implant therapy have emerged as being of great importance among both clinicians and patients. Immediate implant placement (IIP) and provisionalization have been widely described as a protocol for the replacement of single failing anterior teeth, with high survival and success rates.¹⁻³ This technique allows the maintenance of gingival contours even in compromised periodontal conditions, reducing treatment time and drawbacks.

However, for anterior dental implants, esthetic outcomes are strongly related to peri-implant mucosa, bone architecture,⁴ and the surgical protocol.⁵

The papilla is an interdental soft tissue whose dimensions in implantology are considered as a function of interproximal tooth surface and contact point. It is composed of free and attached parts. On the buccal and lingual walls, the papilla is convex and keratinized, whereas under the contact point, the col is concave and not keratinized.⁶ The dimension of the papilla around teeth is linked to the dentogingival complex (DGC). This anatomic complex, described by Gargiulo et al in 1961,⁷ is about 3 mm high on the buccal and lingual sites. In the interproximal areas, the dimension of the DGC is increased (about 4.5 to 5 mm), mostly by the mechanical support of the adjacent teeth.⁸

It is well known that when an adjacent tooth support is removed, the dimensions of the interproximal dentogingival

complex suffer from collapse and reach a dimension similar to that of the unsupported facial DGC (3 mm).

However, this process greatly depends on the existing bone architecture and gingival biotype.

The normal osseous architecture follows the cementoenamel junction and is located 2 mm apically. This results in a scallop shape that is more apical on the facial and lingual aspects of the tooth and peaks at a height of about 3.5 mm more in the interproximal area. However, certain morphological variations can lead to inadequacies between the gingiva and the underlying bone. The greater the mismatch between the interproximal bone and the gingival scallop (DGC > 4.5 mm), the greater the potential for papilla loss and morphological variations.

These anatomical considerations are particularly important when replacing multiple adjacent teeth with fixed implant restorations in the anterior maxilla. Highly demanding though poorly documented,⁹ the result of immediate implantation of multiple adjacent teeth is unpredictable with respect to restoring the contour of the interimplant soft tissue.

The dynamics of the interproximal gingiva, its relationship with the underlying osseous architecture and the role of adjacent teeth support must be evaluated to minimize papilla loss.

- Adequate initial gingival architecture and biotype
- The timing of the implant placement: The purpose of IIP and non-loaded immediate provisionalization (IP) is to maintain the papilla at the time of tooth removal.
- Surgical: flapless extraction and implant placement with adequate (≥ 35 Ncm) primary stability and connective tissue graft.
- Three-dimensional implant alignment: An interimplant distance of at least 3 mm must be established. Moreover, the palatal position helps to limit vertical buccal recession.

This article highlights the possible role of immediate implant, immediate provisionalization, and sequential extraction to maintain the papilla architecture in multiple anterior adjacent extraction sites, even in the case of an impaired osseous contour. Written informed consent was obtained from the patient for this case report.

2 | CLINICAL CONSIDERATIONS

A 40-year-old woman in general good health, a nonsmoker, with two failing maxillary central incisors was referred for possible immediate implant-supported rehabilitation in 2014. The patient had a history of a trauma associated with periodontal disease and tooth mobility class III. The upper left central incisor was endodontically treated after multiple assessments of sensitivity by a general dentist (Figure 1).

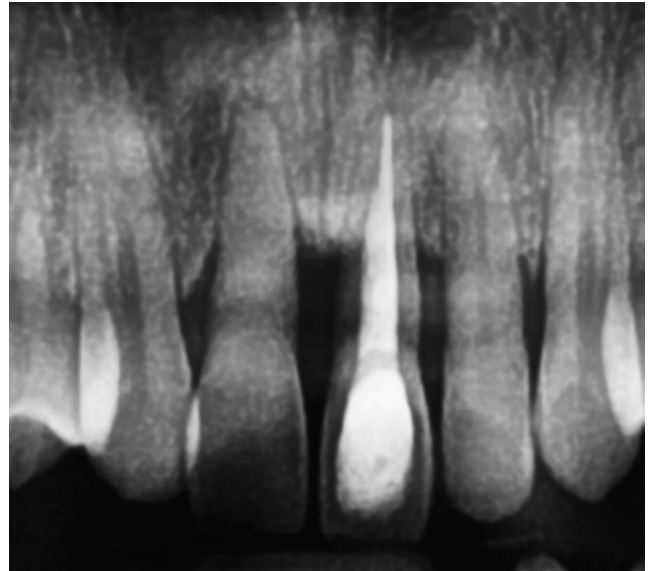


FIGURE 1 Radiographic evaluation of the failing central incisors

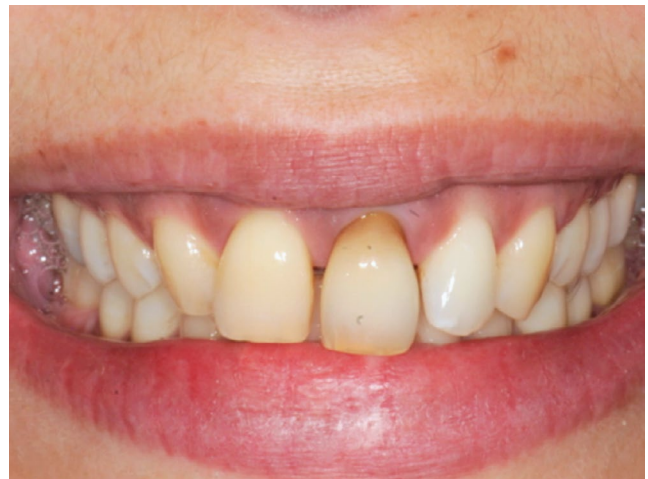

FIGURE 2 Smile line and clinical view of the failing central incisors due to a previous trauma associated with periodontal disease

Periodontal pockets were about 4 to 6 mm around both upper central incisors, without suppuration or gingival alterations. The patient complained about tooth migrations, mobility, and dyschromia. Nevertheless, she had a high esthetic demand due to a high smile line (Figure 2), and she declared her interest in a fixed prosthesis.

The initial phase consisted in scaling and root planning of the failing teeth with oral hygiene instructions. Three months later, periodontal health was assessed. No residual pocket deeper than 3 mm was highlighted, and no bleeding occurred when probing. However, tooth mobility, misposition, and dyschromia were the reasons for extraction due to the patient's esthetic demand and the difficulty of administering orthodontic treatment.

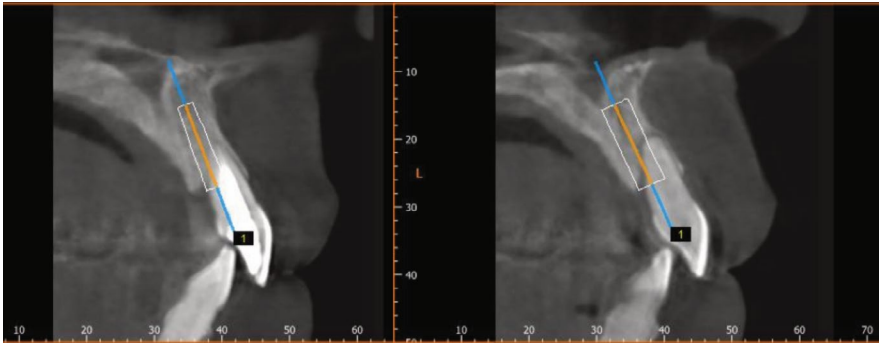


FIGURE 3 Three-dimensional examination emphasizing the thin buccal plate

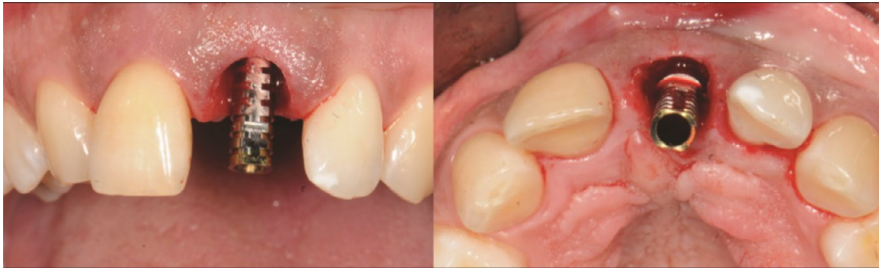

FIGURE 4 Three-dimensional implant placement for a screw-retained prosthesis of the upper left central incisor

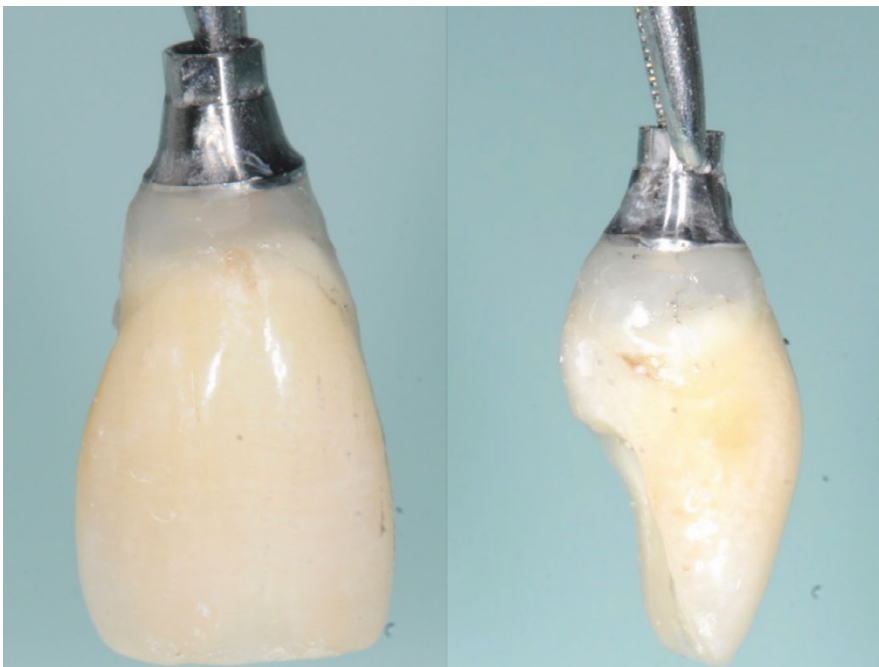

FIGURE 5 Temporary crown of upper left central incisor using the patient's tooth bonded on a temporary abutment

Prior to surgery, a clinical examination was performed to assess a thick¹¹ and scalloped biotype, with a slight recession of 1 mm on the upper left central incisor. Both teeth had an ovoid crown shape without an interproximal contact point. However, the tip of the papilla had the same coronal position as the adjacent teeth.

Three-dimensional radiographic examinations were carried out using cone beam computed tomography (CBCT). Bone volume and architecture were assessed in view to choosing the implant platform and length (Figure 3). The analysis showed a loss of interdental septum between the maxillary

incisor, without periapical lesions. The thickness of the buccal wall was less than 1 millimeter, so considered thin.

Specifically in the esthetic zone, among different treatment strategies such as extraction with socket preservation and delayed implantation or immediate implant placement without provisionalization, IIP with immediate provisionalization was recommended to avoid bone resorption and soft tissue collapse.^{2,3}

The surgical procedure was as follows. In June 2015, after local anesthesia, careful, flapless extraction of the maxillary left central incisor was performed using periostomes. The

FIGURE 6 Connective tissue graft harvested from tuberosity

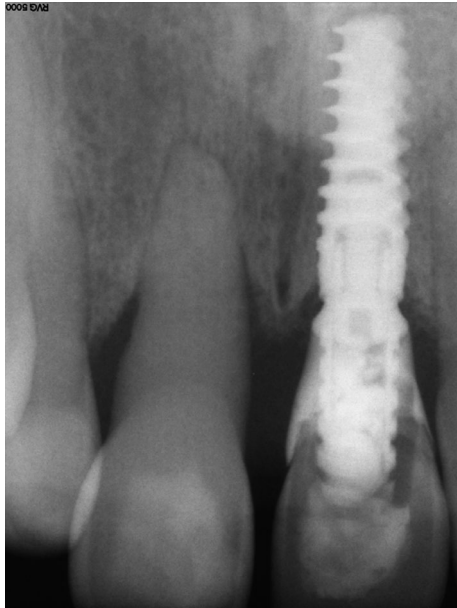
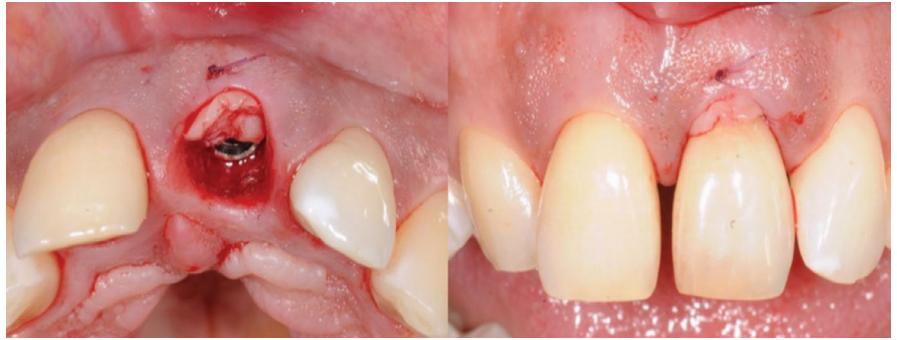

FIGURE 7 Postoperative periapical radiograph of the upper left central incisor

integrity of the labial plate was then evaluated. Implant drilling was done against the palatal wall of the socket to obtain adequate primary stability and reach an optimal three-dimensional implant position and angulation.¹² The implant was placed to allow a screw-retained prosthesis (Figure 4). Once

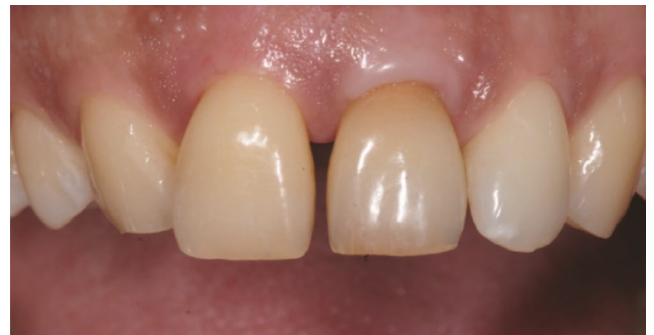

FIGURE 8 Facial view after 4 mo' healing of the upper left central implant prosthesis

the implant had been placed with an insertion torque around 35 Ncm, a provisional shell of the first tooth was fabricated using the tooth crown bonded on a temporary abutment with a fluid composite (Figure 5). In the subcritical gingival zone, the shape of the provisional shell was prepared for a gingival creeping attachment.¹³ Then, the socket with a bovine hydroxyapatite (Bio-Oss, Geistlich, Wolhusen, Switzerland) and connective tissue from the desepithelialized tuberosity were grafted at the same time (Figure 6).¹⁴ The temporary crown was finally inserted. The periapical radiograph shows the implant position and the seating of the provisional crown (Figure 7).

After a healing period of 4 months (Figure 8), the adjacent central incisor was treated with the same protocol without

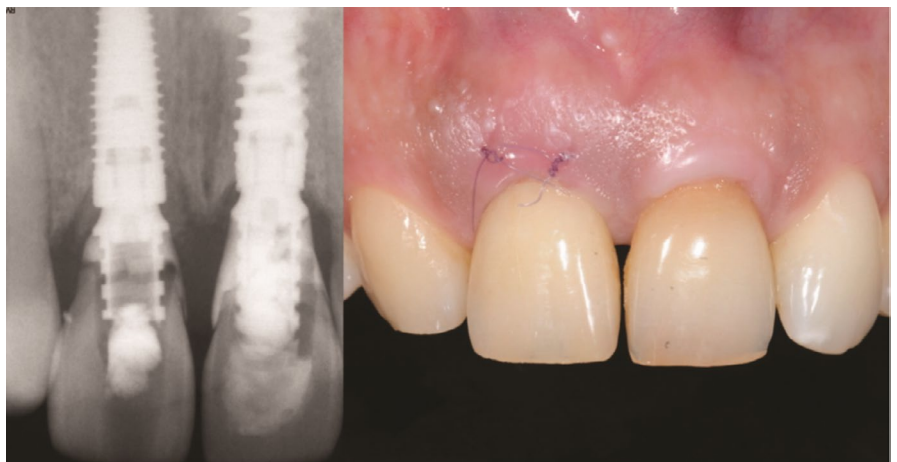


FIGURE 9 Postoperative periapical radiograph and clinical view of the upper right central incisor

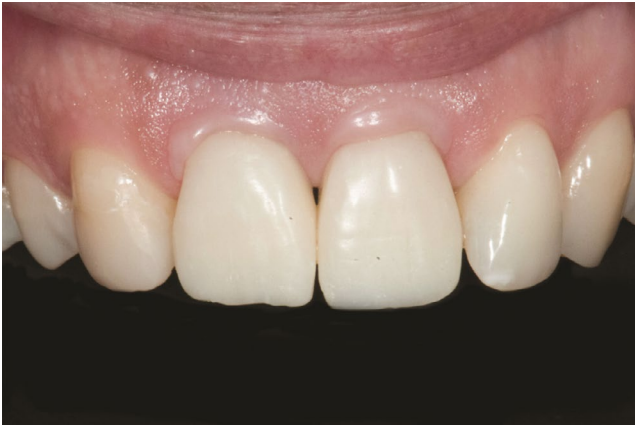

FIGURE 10 Facial view after 4 mo' healing around the new laboratory temporary prosthesis closing the diastema

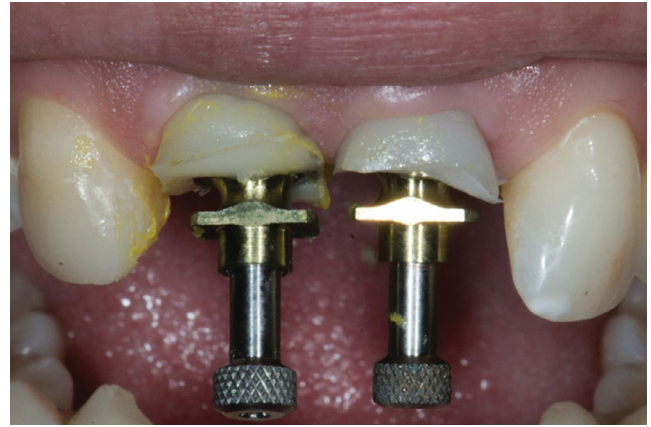

FIGURE 12 Implant impression using personalized implant copings

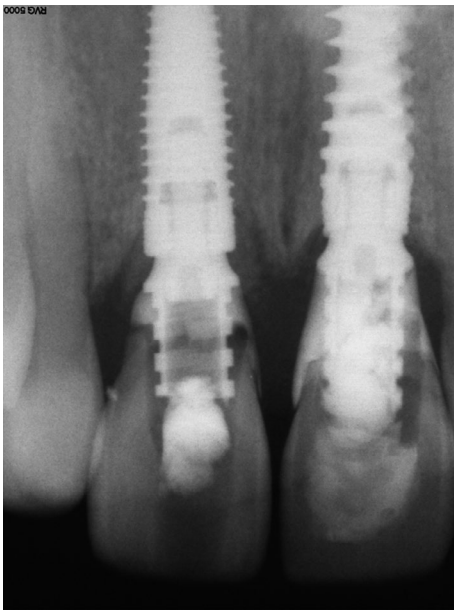


FIGURE 11 Periapical radiograph at four months, before the prosthetic phase

altering the previous restoration and soft tissue attachment (Figure 9). The bone density in the apical area determined the choice of a larger implant in its apical side to increase bone compression compared to what is achieved with osteotomes, increasing insertion torque and primary stability.

The initial diastema between both teeth was closed with new temporary crowns following a request by the patient (Figures 10 and 11).

3 | RESULTS

Four months later, an implant impression was taken for both implants at the same time with customized impression copings (Figure 12). The final screwed prosthesis was made with

hybrid zirconia ceramic crowns bonded to titanium inserts (Figure 13).

In line with what was achieved with the shape of the temporary crowns, the patient confirmed diastema closing with the final crowns.

The pink esthetic score (PES)¹⁵ evaluated before extraction at nine was preserved for both central incisors after prosthetic treatment (Figures 14 and 15).

The patient was recalled 3 years after treatment to assess the PES. Soft tissue texture had improved slightly with time and become similar to that of the adjacent teeth (Figures 16 and 17), and radiography showed that the bone level was improved (Figure 18). The preservation of the papillae and soft tissue contours remained stable even without interdental bony support. No peri-implant probing or inflammation was observed at 3 years, and a PES score of nine was obtained despite the initial periodontal bone loss.

4 | DISCUSSION

The notion of success in implant dentistry has changed over time, especially in the esthetic area.

Nowadays, the goal is to integrate an implant prosthesis undetectably in the patient's smile.

Tooth extraction induces bone and gingival remodeling, mainly by bony resorption of the buccal wall, which has been reported to occur in two phases. First, the bundle bone is resorbed after tooth removal and replaced with immature woven bone and bone resorption occurs from the outer surface of the alveolar bone.¹⁶ Neither immediate implant nor alveolar ridge preservation can prevent this phenomenon. Moreover, this resorption is enhanced when multiple adjacent teeth are involved. Histological evidence regarding the significance of interproximal blood supply to the buccal bone and its impact on bone remodeling were highlighted in animal studies.^{17,18}

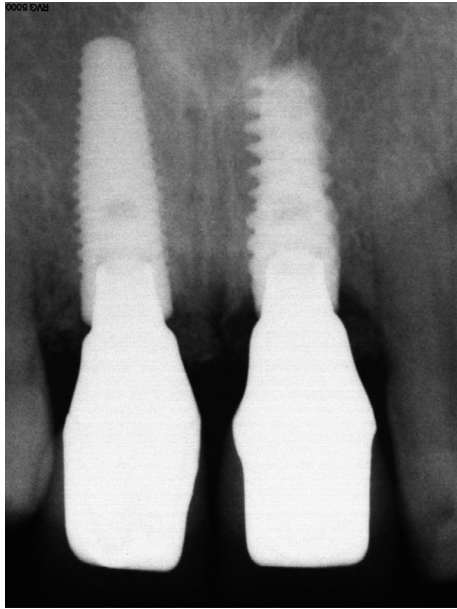


FIGURE 13 Periapical radiograph after the delivery of the final prosthesis

The papilla is a combination of the DGC associated with mechanical support from the teeth. In the presence of adjacent dentition support, the scallop of the gingival architecture is always equal in size to or larger than the scallop of the osseous architecture. Surgical papilla preservation techniques and concepts have been studied.

Flapless procedures are known to limit surgical induced gingival variations, especially with impaired bone architecture. Flapless immediate implant placement in a fresh extraction socket with immediate provisionalization is recommended to support soft tissue remodeling and restrain tissue collapse.^{2,3} The surgical elevation of the papillae induces an ischemia of the interproximal bone and is combined with remodeling and morphological variations by a burst of osteoclastic alveolar bone resorption.^{19,20} Moreover, with a long junctional epithelium, the surgical incision of this attachment leads to worsened gingival recession and impaired esthetics.

In addition, an interimplant horizontal distance of at least 3 mm is recommended.^{21,22} The aim is to reduce crestal bone loss due to the lateral component of peri-implant bone loss. If the distance between adjacent implants is less than 3 mm, the overlap of the lateral bone loss on the two fixtures will lead to a reduction in crestal bone height, which in turn may result in the absence of a complete interproximal papilla and compromised esthetics.

Finally, in the apico-coronal direction, the assumption of Tarnow et al that “a maximum of 5 mm distance from the alveolar crest to the contact point is necessary to obtain correct soft tissue esthetics in natural teeth”²³ has also been verified for implants. Choquet et al²⁴ stressed the importance of the apico-coronal position for preserving papilla and found in a retrospective study that when the distance between the

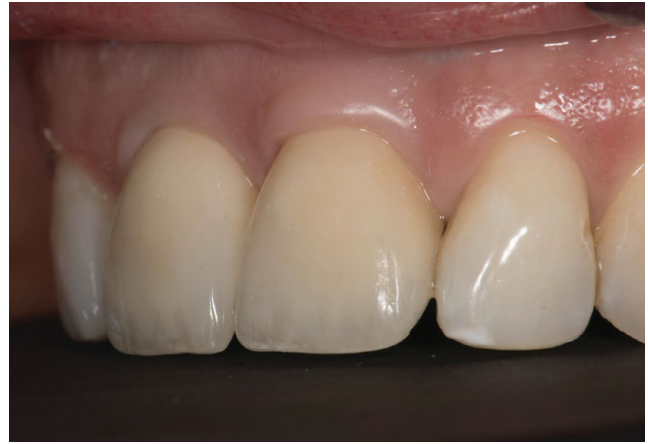

FIGURE 14 Left lateral view after the delivery of the final prosthesis

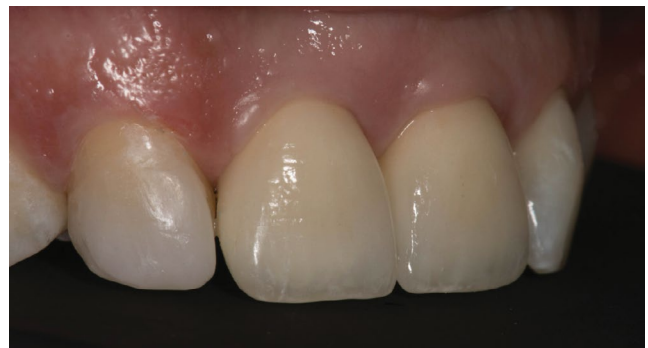

FIGURE 15 Right lateral view after the delivery of the final prosthesis

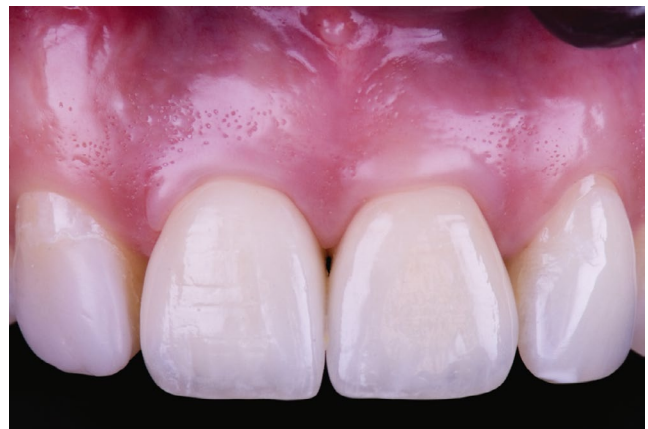

FIGURE 16 Follow-up at 3 y: facial view

contact point and the bone was 5 mm, the papilla was present in 100% of cases.

However, in this report, the papilla was present although the bone and interproximal contact point were initially absent. Moreover, this papilla between teeth 11 and 21 was preserved. This result could be explained by the mechanical and

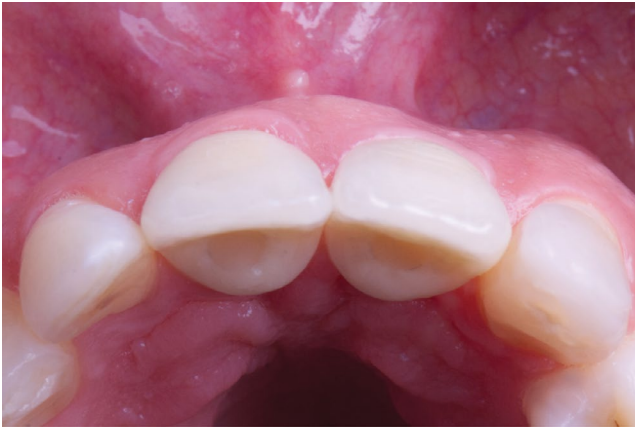

FIGURE 17 Follow-up at 3 y: occlusal view

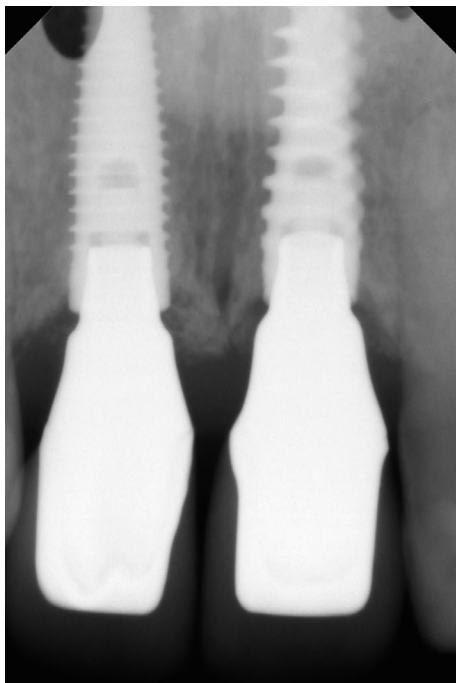


FIGURE 18 Follow-up at 3 y: periapical radiograph showing the stability of the bone level

biological support of the adjacent teeth and/or implant. In a systematic review, Rocuzzo et al²⁵ concluded that embrasure fill between an implant restoration and the adjacent tooth seems to be correlated with the integrity of the periodontal ligament of the tooth more than with the distance between the contact point and implant neck. To reduce the risk of esthetic failures, they advised assessing the interproximal probing on the adjacent teeth before implant placement. It should be pointed out that the absence of attachment disruption is another key factor for papilla preservation.

The restorative procedure had no impact on clinical parameters such as probing depth and bleeding on probing. Provisionalization is known to limit the amount of shrinkage to a mean of 0.5 mm collapse.²⁶ Clinical studies comparing

immediate versus delayed provisionalization showed a significant difference in terms of interdental space filling in the first 2 years after implant placement. This difference becomes nonsignificant after 2 years due to the regrowth of the papilla in staged protocols. These conclusions must be taken with caution, taking into account that the cases selected had only one hopeless tooth to restore, without any interproximal bone loss.

In our clinical case, the aim of alternative tooth extraction was to transform a multiple adjacent immediate implant into a single immediate implant which has proven to be more predictable.

Even with partial interdental bone loss, the “one-by-one” protocol, associated with a correct 3-dimensional implant position, socket grafting and immediate provisionalization, seems to prevent the loss of papillae. We observed a discrepancy between our outcome and the commonly accepted 5 mm between the implant col and the prosthetic contact point to predictably fill the interdental gap. One explanation might be the undisturbed long junctional epithelium on the adjacent tooth that maintains the papilla,⁸ whether or not there is bone loss. Moreover, the “re-attachment” and support of the gingiva at the provisional implant crown and the secondary one formed along the newly implant-supported crown appears crucial for optimizing the outcome.

Kourkouta et al²⁷ found in an observational cross-sectional study, that implant-implant sites did slightly “worse” in terms of soft tissue fill, compared with implant-tooth sites. In the majority of interimplant papillae, the plaque index was 1 (16%) or 2 (74%), whereas at implant-tooth sites, it was 2 (85%) or 3 (15%). The tip of the papilla between adjacent implants was placed on average 2 mm more apically compared with implant-tooth sites.

To conclude, the “one-by-one” technique could be indicated according to several criteria:

- No active or uncontrolled periodontal disease (probing pocket depths ≥ 4 mm), and bleeding on probing;
- A sufficient prosthetic space width (≥ 6 mm) and interocclusal space for a nonoccluding provisional restoration;
- Failing teeth must possess adequate gingival architecture harmonious with the adjacent teeth, even with bony deficiencies;
- Tooth failure including trauma, caries, root resorption, or endodontic or periodontal failures, with no evidence of acute infection.

5 | CONCLUSION

In dentistry nowadays, the aim of implant-supported restoration is not only to functionally restore the tooth, but also do it undetectably for the patient and their relatives.

Multiple adjacent teeth replacement is a challenging treatment in relation to hard and soft tissue morphological variations that are more considerable than for a single missing tooth. Moreover, when the periodontium is compromised, it is sometimes necessary to use prosthetic artifices to compensate tissue loss. The “one-by-one” concept is a technique for restoring multiple adjacent teeth even with interdental bone loss, using immediate implantation and provisionalization in a sequenced procedure. The mechanical support of an attached gingiva is one of the main factors of papilla preservation after tooth extraction. The distance between the implant neck and the prosthetic interdental contact point did not seem to be the key factor.

ACKNOWLEDGMENT

The authors do not have any financial interest in the companies whose materials are included in this article.

CONFLICT OF INTEREST

None declared.

AUTHOR CONTRIBUTIONS

KG: treated the patient and wrote the manuscript. CF: wrote the manuscript. FO: edited and proofread the manuscript.

REFERENCES

1. Yan Q, Xiao L-Q, Su M-Y, Mei Y, Shi B. Soft and hard tissue changes following immediate placement or immediate restoration of single-tooth implants in the esthetic zone: a systematic review and meta-analysis. *Int J Oral Maxillofac Implants*. 2016;31(6):1327-1340.
2. Del Fabbro M, Ceresoli V, Taschieri S, Ceci C, Testori T. Immediate loading of postextraction implants in the esthetic area: systematic review of the literature. *Clin Implant Dent Relat Res*. 2015;17(1):52-70.
3. De Rouck T, Collys K, Cosyn J. Single-tooth replacement in the anterior maxilla by means of immediate implantation and provisionalization: a review. *Int J Oral Maxillofac Implants*. 2008;23(5):897-904.
4. Cooper LF. Objective criteria: guiding and evaluating dental implant esthetics. *J Esthet Restor Dent*. 2008;20(3):195-205.
5. Lin G-H, Chan H-L, Wang H-L. Effects of currently available surgical and restorative interventions on reducing midfacial mucosal recession of immediately placed single-tooth implants: a systematic review. *J Periodontol*. 2014;85(1):92-102.
6. Takei HH. The interdental space. *Dent Clin North Am*. 1980;24(2):169-176.
7. Gargiulo AW, Wentz FM, Orban B. Dimensions and relations of the dentogingival junction in humans. *J Periodontol*. 1961;32(3):261-267.
8. Kois JC. Altering Gingival Levels: The restorative connection Part I: Biologic variables. *J Esthet Restor Dent*. 1994;6(1):3-7.
9. Buser D, Martin W, Belser UC. Optimizing esthetics for implant restorations in the anterior maxilla: anatomic and surgical considerations. *Int J Oral Maxillofac Implants*. 2004;19(Suppl):43-61.
10. Mankoo T. Maintenance of interdental papillae in the esthetic zone using multiple immediate adjacent implants to restore failing teeth—a report of ten cases at 2 to 7 years follow-up. *Eur J Esthet Dent*. 2008;3(4):304-322.
11. Kan JYK, Rungcharassaeng K, Umezumi K, Kois JC. Dimensions of peri-implant mucosa: an evaluation of maxillary anterior single implants in humans. *J Periodontol*. 2003;74(4):557-562.
12. Fu J-H, Lee A, Wang H-L. Influence of tissue biotype on implant esthetics. *Int J Oral Maxillofac Implants*. 2011;26(3):499-508.
13. Su H, Gonzalez-Martin O, Weisgold A, Lee E. Considerations of implant abutment and crown contour: critical contour and subcritical contour. *Int J Periodontics Restorative Dent*. 2010;30(4):335-343.
14. Noelken R, Moergel M, Pausch T, Kunkel M, Wagner W. Clinical and esthetic outcome with immediate insertion and provisionalization with or without connective tissue grafting in presence of mucogingival recessions: A retrospective analysis with follow-up between 1 and 8 years. *Clin Implant Dent Relat Res*. 2018;20(3):285-293.
15. Fürhauser R, Florescu D, Benesch T, Haas R, Mailath G, Watzek G. Evaluation of soft tissue around single-tooth implant crowns: the pink esthetic score. *Clin Oral Implants Res*. 2005;16(6):639-644.
16. Araújo MG, Lindhe J. Dimensional ridge alterations following tooth extraction. An experimental study in the dog. *J Clin Periodontol*. 2005;32(2):212-218.
17. Al-Askar M, O'Neill R, Stark PC, Griffin T, Javed F, Al-Hezaimi K. Effect of single and contiguous teeth extractions on alveolar bone remodeling: a study in dogs. *Clin Implant Dent Relat Res*. 2013;15(4):569-575.
18. Al-Hezaimi K, Levi P, Rudy R, Al-Jandan B, Al-Rasheed A. An extraction socket classification developed using analysis of bone type and blood supply to the buccal bone in monkeys. *Int J Periodontics Restorative Dent*. 2011;31(4):421-427.
19. Yaffe A, Fine N, Binderman I. Regional accelerated phenomenon in the mandible following mucoperiosteal flap surgery. *J Periodontol*. 1994;65(1):79-83.
20. Binderman I, Gadban N, Yaffe A. Cytoskeletal disease: a role in the etiology of adult periodontitis. *Oral Dis*. 2014;20(1):10-16.
21. Tarnow DP, Cho SC, Wallace SS. The effect of inter-implant distance on the height of inter-implant bone crest. *J Periodontol*. 2000;71(4):546-549.
22. Gastaldo JF, Cury PR, Sendyk WR. Effect of the vertical and horizontal distances between adjacent implants and between a tooth and an implant on the incidence of interproximal papilla. *J Periodontol*. 2004;75(9):1242-1246.
23. Tarnow DP, Magner AW, Fletcher P. The effect of the distance from the contact point to the crest of bone on the presence or absence of the interproximal dental papilla. *J Periodontol*. 1992;63(12):995-996.
24. Choquet V, Hermans M, Adriaenssens P, Daelemans P, Tarnow DP, Malevez C. Clinical and radiographic evaluation of the papilla level adjacent to single-tooth dental implants. A retrospective study in the maxillary anterior region. *J Periodontol*. 2001;72(10):1364-1371.
25. Rocuzzo M, Rocuzzo A, Ramanuskaite A. Papilla height in relation to the distance between bone crest and interproximal contact point at single-tooth implants: A systematic review. *Clin Oral Implants Res*. 2018;29(Suppl 15):50-61.

26. De Rouck T, Collys K, Wyn I, Cosyn J. Instant provisionalization of immediate single-tooth implants is essential to optimize esthetic treatment outcome. *Clin Oral Implants Res.* 2009;20(6):566-570.
27. Kourkouta S, Dedi KD, Paquette DW, Mol A. Interproximal tissue dimensions in relation to adjacent implants in the anterior maxilla: clinical observations and patient aesthetic evaluation. *Clin Oral Implants Res.* 2009;20(12):1375-1385.

How to cite this article: Khoury G, Chamieh F, Fromentin O. One-by-one immediate dental implants: A papillae preservation concept for adjacent implants in a compromised periodontal case. *Clin Case Rep.* 2020;8:2664–2672. <https://doi.org/10.1002/ccr3.2929>