

# A Case of Primary Amenorrhea with Swyer Syndrome

Pritti K. Priya, Vineet V. Mishra, Sumesh Choudhary, Jamal S. Rizvi

Department of Obstetrics and Gynaecology, G.R. Doshi and K.M. Mehta Institute of Kidney Diseases and Research Centre, Dr. HL Trivedi Institute of Transplantation Sciences, Ahmedabad, Gujarat, India

### ABSTRACT

Swyer syndrome with complete gonadal dysgenesis is associated with an absence of testicular differentiation in a phenotypic female with a 46, XY karyotype. A 14-year-old unmarried girl was referred with complaints of primary amenorrhea and nondevelopment of breast. Her built was normal. Examination of her secondary sexual characteristics revealed no breast development, absent axillary hairs, and sparse pubic hairs. External genitalia was of female type. Karyotype showed genotype of 46, XY. Magnetic resonance imaging revealed hypoplastic uterus with absent fallopian tubes and ovaries. A diagnosis of Swyer syndrome was made. Laparoscopy showed infantile uterus, normal fallopian tubes, and streak gonads. Laparoscopic removal of streak gonads was done as there is a risk of gonadoblastoma in such cases. The patient was started on hormonal replacement therapy. Swyer syndrome results mainly due to mutation in certain genes such as SRY gene, which leads to failure of development of testis.

**KEYWORDS:** *Gonadal dysgenesis, primary amenorrhea, Swyer syndrome*

## INTRODUCTION

Complete gonadal dysgenesis or Swyer syndrome was first described by Jim Swyer in 1955; since then, a number of cases were reported.<sup>[1]</sup> It is characterized by bilateral streak gonads, normally developed Mullerian structures, female-appearing external genitalia, and hypergonadotropic hypogonadism.<sup>[2]</sup> Patients usually present in adolescence with primary amenorrhea and with lack of secondary sexual characteristics. The incidence of Swyer syndrome is 1:100,000.<sup>[3]</sup> The purpose of reporting this case is its rarity and the importance of diagnosis of XY female for appropriate management as there is a high incidence of gonadal malignancies and also to counsel about fertility options.

A child born with Swyer syndrome looks like a typical female. She usually does not develop secondary sexual characteristics without hormone replacement because streak gonads are incapable of producing the sex hormones (both estrogen and androgens). Therefore, the management of puberty in complete gonadal dysgenesis is similar to other causes of ovarian failure, i.e., initiation of estrogen to induce the development of

secondary sexual characteristics and long-term combined replacement therapy with estrogen and progesterone.

## CASE REPORT

A 14-year old girl was referred to us with complaints of primary amenorrhea and no development of breast. There was no history of cyclical abdominal pain, hormonal intake, radiation exposure, chemotherapy, or any central nervous symptoms such as headache or visual disturbances. There was no past significant surgical history. She was the fourth child of a nonconsanguineous marriage. She has three elder sisters and all of them attained their menarche at the appropriate age. On general examination, she was 152 cm tall and her body mass index was 20 kg/m<sup>2</sup>. Examination of secondary sexual characteristics revealed no breast development with

**Address for correspondence:** Dr. Vineet V. Mishra, Department of Obstetrics and Gynecology, G.R. Doshi and K.M. Mehta Institute of Kidney Diseases and Research Center, Dr. HL Trivedi Institute of Transplantation Sciences, Civil Hospital Campus, Asarwa, Ahmedabad, Gujarat, India.  
E-mail: vineet.mishra.ikdrc@gmail.com

This is an open access article distributed under the terms of the Creative Commons Attribution-NonCommercial-ShareAlike 3.0 License, which allows others to remix, tweak, and build upon the work non-commercially, as long as the author is credited and the new creations are licensed under the identical terms.

**For reprints contact:** reprints@medknow.com

**How to cite this article:** Priya PK, Mishra VV, Choudhary S, Rizvi JS. A case of primary amenorrhea with Swyer syndrome. J Hum Reprod Sci 2017;10:310-2.

Access this article online	
<b>Quick Response Code:</b> 	<b>Website:</b> www.jhrsonline.org
	<b>DOI:</b> 10.4103/jhrs.JHRS_128_17

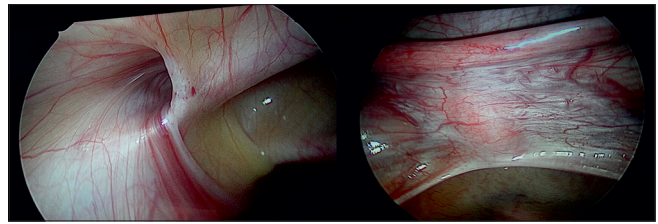
hypopigmented areola. Axillary hair was absent and pubic hairs were sparse.

Examination of the external genitalia revealed that they were of female type. Vaginal orifice was seen. After investigation, serum follicle-stimulating hormone and serum luteinizing hormone were found to be very high, 93.7 and 28.19 mIU/ml, respectively. Serum thyroid-stimulating hormone and serum prolactin were normal. Ultrasound showed a rudimentary uterus and magnetic resonance imaging revealed hypoplastic uterus with absent fallopian tubes and ovaries, without endometrial or myometrial differentiation; both the kidneys were normal. Karyotype was done which showed a genotype of 46, XY.

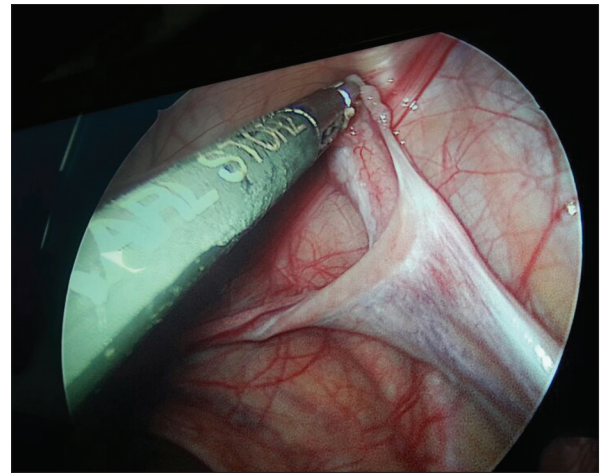
She was further subjected to diagnostic laparoscopy and the findings demonstrated a small uterus with normally present fallopian tubes [Figure 1]. Ovaries could not be visualized; fibrous bands were seen on either side which appeared to be streak gonads [Figure 2]. Inguinal canal was seen on both sides which was blind and empty. No other pelvic abnormalities were seen. Given streak gonads and genotype of XY, bilateral removal of whitish structures was done and sent for histopathology [Figure 3]. The report showed dysgenetic streak gonads with ovarian differentiation. Counseling of parents was done. She was started on hormonal replacement therapy (HRT) with conjugated estrogen only for 3 months followed by conjugated estrogen along with medroxyprogesterone acetate cyclically. Six months after the initiation of HRT, she attained menarche. The secondary sexual characteristics have shown improvement. Breast development occurred (Tanner stage II).

## DISCUSSION

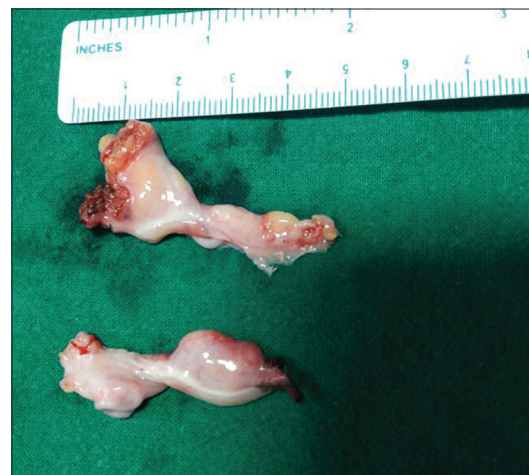Swyer syndrome is a form of pure gonadal dysgenesis. The first known step of sexual differentiation of a normal XY fetus is the development of testes. The early stages of testicular formation in the 2<sup>nd</sup> month of gestation require the action of several genes, of which the most important is SRY, the sex-determining region of the Y chromosome. Four mutations of SRY account for many cases of Swyer syndrome. In most cases, the cause is not identified or may be due to mutation of other genes in the sex differentiation pathway such as the autosomal genes DHH, MAP3K1, NR5A1, SOX9, WT1, and DAX1 on the X chromosome.<sup>[4]</sup> When such a gene is mutated, the bipotential gonads fail to differentiate into testes in an XY fetus. Without testes, no testosterone or anti-Mullerian hormone (AMH) is produced. Without testosterone, there is no virilization of external genitalia, resulting in normal female genitalia. As AMH is absent,



**Figure 1:** Laparoscopy image showing blind empty inguinal canal; hypoplastic uterus



**Figure 2:** Laparoscopy image showing fallopian tube with streak gonads (whitish fibrous band)



**Figure 3:** Specimen showing streak gonads

the Mullerian ducts develop into uterus, fallopian tube, cervix, and vagina.

People with Swyer syndrome have typical female external genitalia. The uterus and fallopian tubes are normally formed, but the gonads (ovaries or testes) are not functional; affected individuals have undeveloped clumps of tissue called streak gonads. Due to the lack of development of the gonads, Swyer syndrome is also called 46, XY complete gonadal dysgenesis. The residual gonadal tissue often becomes cancerous, so it is

usually removed surgically early in life. Adrenal gland is not affected and can produce androgens and most of these persons develop pubic hair, though it often remains sparse. The diagnosis of Swyer syndrome was made in our case because she was a normal-statured girl with primary amenorrhea with clinical features of sexual infantilism whose genotype was pure XY and the gonadal tissues are fibrous band [Figure 2].

People with Swyer syndrome are typically raised as girls and have a female gender identity. Since they do not have functional ovaries, the affected individuals usually begin HRT during adolescence to induce menstruation and development of female secondary sex characteristics such as breast enlargement and uterine growth. These patients can have a normal sexual intercourse and they need HRT for development of breast and to prevent osteoporosis. They can conceive using donor oocytes and artificial reproductive techniques.<sup>[5]</sup>

Swyer syndrome usually affects only sexual development; such cases are called isolated Swyer syndrome. However, depending on the genetic cause, Swyer syndrome may also occur along with health conditions such as nerve problems (neuropathy) or as part of a syndrome such as campomelic dysplasia, which causes severe skeletal abnormalities. Gonadoblastomas are seen in 20%–30% of women with Swyer syndrome.<sup>[6]</sup> The main differential diagnosis of Swyer syndrome is mixed gonadal dysgenesis which is more frequently seen than the former. In this condition, the gonads on histopathology will also show testicular differentiation in addition to ovarian differentiation. The genotype too is usually a mosaic pattern.

## CONCLUSION

Swyer syndrome is extremely rare and invariably causes primary amenorrhea. Genetic testing plays very important

role in the diagnosis of Swyer syndrome. Early diagnosis is of crucial importance for various reasons, including the risk of gonadal malignancy and the need for removal of the gonads, early institution of HRT for induction of puberty, improving bone mineral density, and also counseling regarding fertility options.

## Declaration of patient consent

The authors certify that they have obtained all appropriate patient consent forms. In the form the patient(s) has/have given his/her/their consent for his/her/their images and other clinical information to be reported in the journal. The patients understand that their names and initials will not be published and due efforts will be made to conceal their identity, but anonymity cannot be guaranteed.

## Financial support and sponsorship

Nil.

## Conflicts of interest

There are no conflicts of interest.

## REFERENCES

1. Héту V, Caron E, Francoeur D. Hypoplastic uterus and clitoris enlargement in swyer syndrome. *J Pediatr Adolesc Gynecol* 2010;23:e43-5.
2. Granados H, Phulwani P. Absent visualization of a hypoplastic uterus in a 16 year old with complete 46 XY gonadal dysgenesis (swyer syndrome). *Endocrinol Metab Syndr* 2013;2:1143.
3. Michala L, Goswami D, Creighton SM, Conway GS. Swyer syndrome: Presentation and outcomes. *BJOG* 2008;115:737-41.
4. Hanley NA, Hagan DM, Clement-Jones M, Ball SG, Strachan T, Salas-Cortés L, et al. SRY, SOX9, and DAX1 expression patterns during human sex determination and gonadal development. *Mech Dev* 2000;91:403-7.
5. Babre VM, Bendre K, Niyogi G. A rare case of swyer syndrome. *Int J Reprod Contracept Obstet Gynecol* 2013;2:485-7.
6. Coutin AS, Hamy A, Fondevilla M, Savigny B, Paineau J, Visset J, et al. Pure 46 XY gonadal dysgenesis. *J Gynecol Obstet Biol Reprod (Paris)* 1996;25:792-6.