



## CASE REPORT

**REVISED** **Case Report: Co-existence of sarcoidosis and Takayasu arteritis [version 2; peer review: 2 approved, 1 approved with reservations]**

Jiwan Poudel <sup>1</sup>, Ujjwol Risal <sup>1</sup>, Keshav Raj Sigdel<sup>1</sup>, Buddhi Prasad Paudyal <sup>1</sup>, Sudeep Adhikari <sup>1</sup>, Buddha Basnyat <sup>1,2</sup>

<sup>1</sup>Internal Medicine, Patan Academy of Health Sciences, Lalitpur, Nepal

<sup>2</sup>Oxford University Clinical Research Unit, Patan Academy of Health Sciences, Lalitpur, Nepal

**V2** First published: 17 Apr 2020, 5:73  
<https://doi.org/10.12688/wellcomeopenres.15837.1>  
 Latest published: 23 Jul 2020, 5:73  
<https://doi.org/10.12688/wellcomeopenres.15837.2>

**Abstract**

Takayasu arteritis is a rare systemic large vessel vasculitis affecting the aorta and its branches. Sarcoidosis, too, is an inflammatory disease. Both entities are granulomatous conditions with a questionable association in their etiopathogenesis. Only a few cases of their coexistence have been reported in the literature. To our knowledge, no such cases have been reported from Nepal. We report a Nepalese woman who presented with non-productive cough, progressive shortness of breath and chest tightness of 3 years duration. She had a history of recurrent bilateral granulomatous uveitis over the previous 3 years. Examination revealed clubbing of digits, absent pulses over the left radial, ulnar and brachial arteries, and a weak pulse over the right arm including the bilateral carotid arteries. Pulmonary function test showed restrictive pattern, a high-resolution computed tomography (HRCT) scan of the chest revealed findings suggestive of pulmonary sarcoidosis. A CT angiogram suggested large vessel vasculitis. Bronchoscopy with biopsy revealed granulomatous inflammation, negative for malignancy and tuberculosis. She was hence, diagnosed with co-existing Takayasu arteritis and sarcoidosis, and treated with Prednisolone 60 mg once daily with dramatic improvement over 4 days and was discharged stable on domiciliary oxygen. She is currently on azathioprine 50 mg, prednisolone 10 mg without the need for supplemental oxygen. This case report highlights the importance of a proper physical examination as a guide to the use of modern technology in making a correct diagnosis. Furthermore, in countries where tuberculosis is endemic, it should always come as the most important differential diagnosis of granulomatous inflammation.

**Keywords**

Sarcoidosis, takayasu arteritis, coexistence

**Open Peer Review**

**Reviewer Status** ? ✓ ✓

	Invited Reviewers		
	1	2	3
<b>version 2</b> (revision) 23 Jul 2020			✓ report
<b>version 1</b> 17 Apr 2020	? report	✓ report	

1. **Varun Dhir** , Postgraduate Institute of Medical Education and Research, Chandigarh, India
2. **Debashish Danda** , Christian Medical College, Vellore, Vellore, India
3. **Hollis E. Krug** , Veterans Affairs Medical Center, Minneapolis, USA  
University of Minnesota Medical School, Minneapolis, USA

Any reports and responses or comments on the article can be found at the end of the article.



oucrU

This article is included in the [Oxford University Clinical Research Unit \(OUCRU\) gateway](#).

**Corresponding authors:** Jiwan Poudel ([jiwanpako@gmail.com](mailto:jiwanpako@gmail.com)), Sudeep Adhikari ([sudeepadh123@gmail.com](mailto:sudeepadh123@gmail.com))

**Author roles:** **Poudel J:** Conceptualization, Data Curation, Writing – Original Draft Preparation, Writing – Review & Editing; **Risal U:** Conceptualization, Resources, Writing – Review & Editing; **Sigdel KR:** Resources, Supervision, Writing – Review & Editing; **Paudyal BP:** Resources, Supervision, Writing – Review & Editing; **Adhikari S:** Writing – Review & Editing; **Basnyat B:** Resources, Supervision, Writing – Review & Editing

**Competing interests:** No competing interests were disclosed.

**Grant information:** This work was supported by the Wellcome Trust [106680].

*The funders had no role in study design, data collection and analysis, decision to publish, or preparation of the manuscript.*

**Copyright:** © 2020 Poudel J *et al.* This is an open access article distributed under the terms of the [Creative Commons Attribution License](#), which permits unrestricted use, distribution, and reproduction in any medium, provided the original work is properly cited.

**How to cite this article:** Poudel J, Risal U, Sigdel KR *et al.* **Case Report: Co-existence of sarcoidosis and Takayasu arteritis [version 2; peer review: 2 approved, 1 approved with reservations]** Wellcome Open Research 2020, 5:73 <https://doi.org/10.12688/wellcomeopenres.15837.2>

**First published:** 17 Apr 2020, 5:73 <https://doi.org/10.12688/wellcomeopenres.15837.1>

**REVISED Amendments from Version 1**

The new version includes minor text changes that the reviewers have suggested.

**Any further responses from the reviewers can be found at the end of the article**

**Background**

Sarcoidosis is a systemic inflammatory disorder of unknown etiology characterized by non-caseating, granulomatous inflammation<sup>1</sup>. It affects young adults 20 to 40 years of age<sup>2</sup>. Takayasu arteritis (TA) is a vasculitis involving large sized arteries, mainly the aorta and its branches. It is also an inflammatory disease of unknown etiology characterized by granulomatous vasculitis<sup>3</sup>. Sarcoidosis and TA are unrelated diseases; however rare coexistence has been noted<sup>4–11</sup>. It is not clear if the coexistence is due to chance alone or if there is some common pathogenetic mechanism related to both the diseases. We report a patient from Nepal who was diagnosed with sarcoidosis and TA concomitantly, and aim to contribute to literature regarding patients with these coexisting diseases.

**Case presentation**

A 40-year-old Asian woman, non-smoker, housewife, presented in December, 2018 with progressive shortness of breath, initially only during physical exertion (i.e., walking upstairs) which later started occurring even at rest and a non-productive cough of three years duration which worsened in the ten days preceding presentation. She also complained of chest tightness during this presentation. She did not have a history suggestive of orthopnea or paroxysmal nocturnal dyspnea, swelling of her legs and/or body, fever, blood mixed sputum, chest pain or joints pain. She did not have exposure to patients with pulmonary tuberculosis. She had presented to an ophthalmologist 3 years back due to pain and redness of both eyes and was later diagnosed with bilateral granulomatous uveitis. She was treated with topical steroid for the same duration with intermittent intervals of as long as 2–3 months.

On examination, she was afebrile with a blood pressure of 130/80 mmHg in the right arm and heart rate was 80/minute. She had clubbing of her digits. Examination of peripheral pulses revealed absent pulse over the left radial and brachial arteries and feeble pulse over the right radial and brachial arteries, and bilateral carotid arteries. Carotid bruit was heard on the left side. Her oxygen saturation at room air was only 76% and required 4 liters/minute of oxygen to maintain 92% saturation (Normal >95%). Her jugular venous pressure was not raised and there was no pedal or sacral edema.

Laboratory parameters with normal ranges in parenthesis, are as follows:

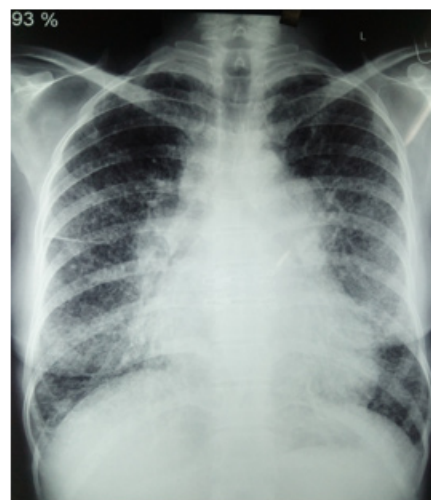Complete blood count: white cell count  $4.2 (4–10) \times 10^9/L$ ; neutrophils 78%; lymphocytes 20%; red blood cells  $4.6 (4.2–5.4) \times 10^{12}/L$ ; haemoglobin 13.3 (12–15) g/dL; platelets  $244 (150–400) \times 10^9/L$ .

Biochemistry: random blood sugar 126 (65–110) mg/dL; urea 29 (17–45) mg/dL; creatinine 0.9 (0.8–1.3) mg/dL; sodium 139 (135–145) mmol/L and potassium 4.3 (3.5–5) mmol/L.

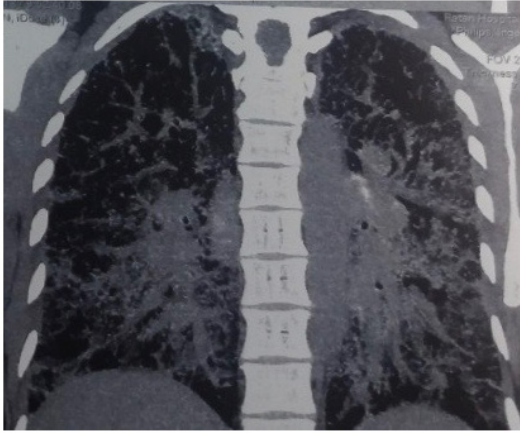
Hepatic panel: bilirubin total 0.8 (0.1–1.2) mg/dL and direct 0.5 (0–0.4) mg/dL; alanine transaminase 39 (5–30) units/L; aspartate transaminase 45 (5–30) units/L; alkaline phosphatase 103 (50–100) IU/L; albumin 2.6 (3.5–5) g/dL

Erythrocyte sedimentation rate (ESR) was elevated at 45 mm/hr and c-reactive protein (CRP) was 4 mg/L (Normal < 10 mg/L). Angiotensin converting enzyme (ACE) levels were elevated at 186 u/L (Normal < 52 u/L); rheumatoid factor and anti-nuclear antibodies by indirect immunofluorescence were negative. Sputum examination did not reveal any organisms including acid fast bacilli. Sputum analysed by gene Xpert also did not detect *Mycobacterium tuberculosis*. The electrocardiogram was normal. Echocardiography showed moderate tricuspid regurgitation with moderate pulmonary arterial hypertension with a normal systolic function.

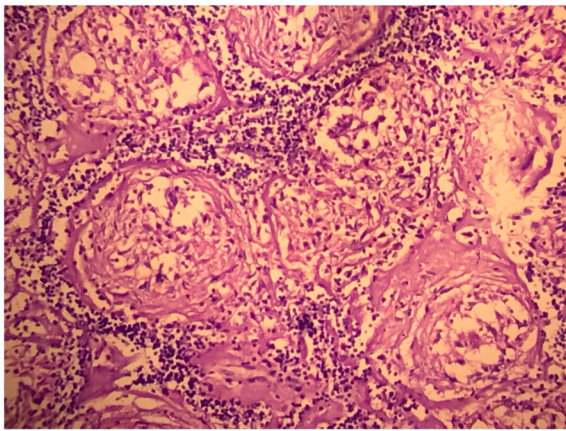
Chest X-ray (Figure 1) revealed bilateral reticulo-nodular infiltrates involving the middle and lower zones and some parts of the upper zones. No changes were noted compared to a radiograph done three years ago. The pulmonary function test showed a restrictive pattern. High resolution computed tomography (CT) of the chest (Figure 2) showed diffuse ground glass changes with interlobular septal thickening with mosaic attenuation and multiple enlarged calcified mediastinal and hilar lymph nodes (separate image of mediastinal section could not be retrieved). Bronchoscopy with trans-bronchial lung biopsy revealed non-caseating granulomatous inflammation with characteristic 'asteroid bodies' (Figure 3 and Figure 4), and was negative for malignancy and tuberculosis. Hence the diagnosis of sarcoidosis (pulmonary and ocular) was made.



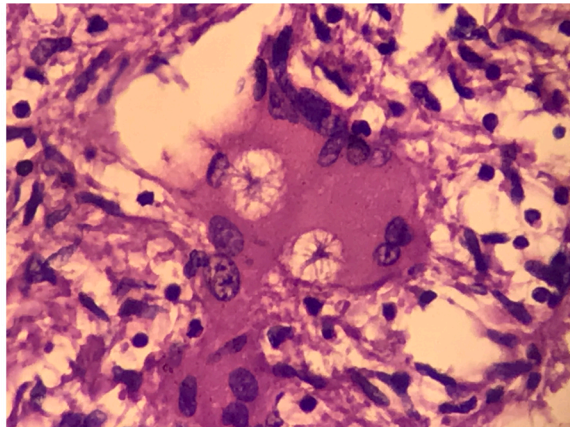
**Figure 1.** Chest X-ray showing bilateral reticulo-nodular infiltrates involving the middle and lower zones and some parts of the upper zones.



**Figure 2.** High-resolution computed tomography (HRCT) chest showing diffuse ground glass changes with interlobular septal thickening with mosaic attenuation and multiple enlarged calcified mediastinal and hilar lymph nodes.



**Figure 3.** Lung biopsy showing large non-caseating granulomas with tightly packed central area composed of epithelioid cells, multinucleated giant cells and T-lymphocytes.



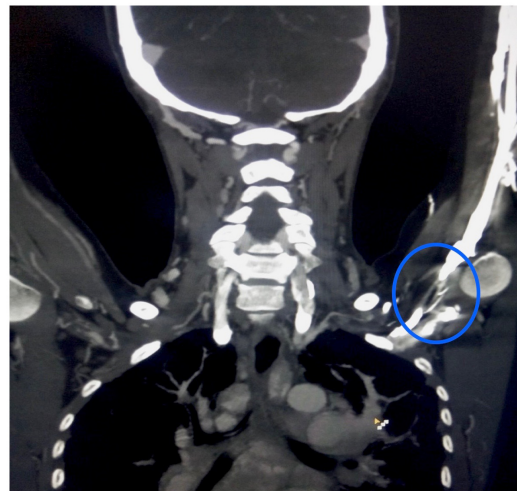
**Figure 4.** Further magnification of the granuloma revealing the characteristic 'asteroid bodies'.

The findings of abnormal pulse led us to do a CT angiogram of aorta and its branches. **Figure 5** shows stenosis of the left subclavian artery with almost complete block at the distal part as well as the proximal left axillary artery. Though images not available for the report, there was stenosis of right axillary, brachial artery and its branches, with sparing of abdominal aorta up to the lower extremities. This was suggestive of large vessel vasculitis in the upper extremities, Takayasu arteritis (Type I).

With the diagnosis of sarcoidosis with coexisting Takayasu arteritis, she was treated with prednisolone 60 mg once daily (1 mg/kg/day) along with supportive treatment including oxygen, chest physiotherapy, bone protection with calcium and vitamin D, and thromboembolism prophylaxis with daily 60 mg of subcutaneous enoxaparin. Ophthalmology examination showed bilateral granulomatous uveitis and was treated with topical prednisolone drops. She dramatically improved over 3–4 days and required only 1 liter/minute of oxygen support. Pneumococcal vaccination was administered. She was later discharged on domiciliary oxygen with a tapering prednisolone dosage.

After four weeks of discharge, while she was still on 30 mg of prednisolone, she developed blurring of vision. Ophthalmologic examination showed increased intraocular pressure with findings suggestive of Secondary glaucoma, probably steroid induced. Topical steroid was stopped and since oral steroid was to be tapered off quickly, azathioprine 50 mg/day was started as a steroid sparing immunosuppressant. Glaucoma was treated with topical timolol (0.25% twice daily) and oral acetazolamide (500 mg followed by 250 mg twice daily), and she responded well over the course of 2 weeks.

The patient is still on regular follow up (after 15 months of diagnosis) and is currently asymptomatic. She does not require oxygen and does not have symptoms of vasculitis (carotidynia,



**Figure 5.** Computed tomography (CT) aortogram showing stenosis of left subclavian artery with almost complete block at distal part and proximal left axillary artery.

headache, lightheadedness, vertigo, tingling, numbness, limb claudication, cyanosis, arthralgias and skin lesions like erythema nodosum). She is currently taking azathioprine 50 mg/day, prednisolone 10 mg/day with calcium and vitamin D supplements. She is also on regular follow up every 3 months with a pulmonologist.

## Discussion

Our patient was symptomatic with dyspnoea and cough for the 3 years prior to presentation but was not evaluated. The development of pain and redness in both eyes led her to visit an ophthalmologist who diagnosed bilateral granulomatous uveitis 3 years previous. Sarcoidosis was unfortunately missed during the initial presentation, allowing the patient to receive topical steroid therapy alone for 3 years which allowed the systemic disease to flourish. Lungs are most commonly (95%) involved in sarcoidosis<sup>12</sup>, and almost 30% have extrapulmonary manifestations<sup>13</sup> with ocular involvement in 25% of patients. Almost 5% of patients have ocular involvement on presentation. Granulomatous uveitis is the intraocular manifestation of sarcoidosis. Finally, the respiratory symptoms in the background of granulomatous uveitis led us to suspect sarcoidosis and the chest imaging (radiographic stage II-III on chest x-ray) and bronchoscopic examinations helped confirm the diagnosis. Systemic glucocorticoid treatment was started due to severe involvement of the lungs. Due to the unavailability of bronchoscopy in our center, we had to refer the patient to a different center which delayed the diagnosis by a few days.

Secondary glaucoma is a common complication in intraocular sarcoidosis as seen in our patient, which occurred due to prolonged use of topical steroid eye drops. In our patient, we stopped prednisolone drop, treated glaucoma with timolol and acetazolamide, tapered off the systemic prednisolone quickly and started her on azathioprine as a steroid-sparing agent. The initial management of sarcoidosis involves the use of systemic glucocorticoid for inducing remission. The use of immunosuppressive agents such as methotrexate<sup>14</sup>, azathioprine<sup>15</sup> and leflunomide<sup>16</sup> is reserved for cases where there is a lack of response or side effects to glucocorticoids<sup>17</sup>.

Our patient also had coexisting Takayasu arteritis which is a large vessel granulomatous vasculitis. The incidental finding of weak pulses and carotid bruits during the physical examination in a young Asian woman (in whom atherosclerotic vascular disease would be uncommon) led to the suspicion of large vessel vasculitis. CT angiography later helped to make the proper diagnosis. The diagnosis of Takayasu arteritis can be effectively made based on typical clinical findings (discrepant blood pressure, absent or feeble peripheral pulses, arterial bruits) and imaging findings of narrowing of the aorta and/or its primary branches, without the need for demonstration of granulomatous vasculitis in histopathology<sup>18</sup>. The overall treatment approach remains similar to sarcoidosis (using systemic steroid and alternative steroid sparing immunosuppressants as required).

As Nepal is an endemic region for tuberculosis, and the fact that tuberculosis can mimic findings of sarcoidosis and also of large vessel vasculitis, tuberculosis was a strong all-encompassing

diagnosis that could have explained the abnormal findings in our patient. But tuberculosis was effectively ruled out with sputum and after bronchoscopic examination. Our patient presented with respiratory symptoms which led to the diagnosis of sarcoidosis, but she also had other incidental findings not in keeping with sarcoidosis alone. Hence we entertained the possibility of another disease. Takayasu-like vasculitis has been reported to be associated with sarcoidosis, but direct association have not been established.

The coexistence of Takayasu arteritis with sarcoidosis is rare, and has been reported in a few case reports<sup>4-11</sup>. Though these two diseases are unrelated, there is a new hypothesis that some unifying immunological mechanism may be responsible for the concomitant presence of the two diseases<sup>8</sup>. Until now, both are considered to be granulomatous inflammatory conditions of unknown etiology. However, some studies have pointed various possible common immune mechanism for these two entities, including mycobacterial heat shock proteins (HSPs). These mycobacterial HSPs are thought to cross react with human HSPs due to their molecular mimicry, thereby producing an increased abnormal immune response. A meta-analysis by *Fang C. et al.*<sup>19</sup> hypothesized that some mycobacterial antigens contribute to immune-mediated granulomatous inflammation (sarcoidosis). In a study by *Aggarwal et al.*<sup>20</sup> including 36 Takayasu arteritis patients, they found enhanced humoral immune response to mycobacterial antigens compared to healthy controls. Similarly, *Kumar Chauhan et al.*<sup>21</sup> in a study of 26 patients with Takayasu's disease, found a greater proliferation of CD<sub>4</sub> T-lymphocytes in the presence of mycobacterial HSP-65 compared to controls, as well as higher levels of IgG antibodies directed against the anti-HSP-65 and anti-HSP-60. Put together, microbial involvement seems to play an important role in granulomatous inflammation. But this needs further evaluation with a larger cohort of patients with coexisting sarcoidosis and Takayasu arteritis.

## Conclusion

Sarcoidosis should be suspected in young adults who present with progressive respiratory and ocular symptoms. But large vessel vasculitis causing abnormal pulse and arterial bruits, is distinctly rare in sarcoidosis. The incidental findings of weak pulses and carotid bruits in this young woman therefore led us to the diagnosis of coexisting Takayasu arteritis. This case report highlights the importance of a proper physical examination, even as a guide to modern technology to make the correct diagnosis. The coexistence of sarcoidosis and Takayasu arteritis is rare, and needs further case report compilations to help delineate this association, if any. Importantly, in our setting, tuberculosis, the great mimicker, is rampant and always has to be ruled out in a patient with clinical features like ours.

## Consent

Written informed consent for publication of clinical details and clinical images was obtained from the patient.

## Data availability

### Underlying data

All data underlying the results are available as part of the article and no additional source data are required.

## References

1. Baughman RP, Lower EE, du Bois RM: **Sarcoidosis**. *Lancet*. 2003; **361**(9363): 1111–8. [PubMed Abstract](#) | [Publisher Full Text](#)
2. **Statement on sarcoidosis. Joint Statement of the American Thoracic Society (ATS), the European Respiratory Society (ERS) and the World Association of Sarcoidosis and Other Granulomatous Disorders (WASOG) adopted by the ATS Board of Directors and by the ERS Executive Committee, February 1999**. *Am J Respir Crit Care Med*. 1999; **160**(2): 736–55. [PubMed Abstract](#) | [Publisher Full Text](#)
3. Jennette JC, Falk RJ, Bacon PA, *et al.*: **2012 revised International Chapel Hill Consensus Conference Nomenclature of Vasculitides**. *Arthritis Rheum*. 2013; **65**(1): 1–11. [PubMed Abstract](#) | [Publisher Full Text](#)
4. Ishii A, Hoshii Y, Nakashima T, *et al.*: **Sarcoidosis with pulmonary hypertension exacerbated by Takayasu-like large vessel vasculitis**. *Pathol Int*. 2011; **61**(9): 546–50. [PubMed Abstract](#) | [Publisher Full Text](#)
5. Chapelon-Abrie C, Saadoun D, Marie I, *et al.*: **Sarcoidosis with Takayasu arteritis: a model of overlapping granulomatosis. A report of seven cases and literature review**. *Int J Rheum Dis*. 2018; **21**(3): 740–745. [PubMed Abstract](#) | [Publisher Full Text](#)
6. Hamzaoui A, Salem R, Klii R, *et al.*: **Co-existing sarcoidosis and Takayasu arteritis: report of a case**. *Int Arch Med*. 2011; **4**: 9. [PubMed Abstract](#) | [Publisher Full Text](#) | [Free Full Text](#)
7. Weiler V, Redtenbacher S, Bancher C, *et al.*: **Concurrence of sarcoidosis and aortitis: case report and review of the literature**. *Ann Rheum Dis*. 2000; **59**(11): 850–3. [PubMed Abstract](#) | [Publisher Full Text](#) | [Free Full Text](#)
8. Saha BK, Saha A: **Coexistent Takayasu Arteritis and Sarcoidosis: A case report**. *Chest*. 2019; **156**(4): A1247. [Publisher Full Text](#)
9. Rhanim A, Marc K: **[Association of sarcoidosis and Takayasu's disease: A case report]**. *Rev Pneumol Clin*. 2016; **72**(4): 255–8. [PubMed Abstract](#) | [Publisher Full Text](#)
10. Im MH, Woo JJ, An JK, *et al.*: **Takayasu Arteritis Associated with Sarcoidosis: A Case Report**. *J Korean Soc Radiol*. 2011; **65**(5): 487–90. [Publisher Full Text](#)
11. Robaday S, Hervé F, Cailleux N, *et al.*: **[Association of sarcoidosis and Takayasu's arteritis: an additional case report]**. *Rev Med Interne*. 2005; **26**(10): 816–9. [PubMed Abstract](#) | [Publisher Full Text](#)
12. Baughman RP, Teirstein AS, Judson MA, *et al.*: **Clinical characteristics of patients in a case control study of sarcoidosis**. *Am J Respir Crit Care Med*. 2001; **164**(10 Pt 1): 1885–9. [PubMed Abstract](#) | [Publisher Full Text](#)
13. Rizzato G, Tinelli C: **Unusual presentation of sarcoidosis**. *Respiration*. 2005; **72**(1): 3–6. [PubMed Abstract](#) | [Publisher Full Text](#)
14. Cremer JP, Drent M, Bast A, *et al.*: **Multinational evidence-based World Association of Sarcoidosis and Other Granulomatous Disorders recommendations for the use of methotrexate in sarcoidosis: integrating systematic literature research and expert opinion of sarcoidologists worldwide**. *Curr Opin Pulm Med*. 2013; **19**(5): 545–61. [PubMed Abstract](#) | [Publisher Full Text](#)
15. Vorselaars ADM, Wuyts WA, Vorselaars VMM, *et al.*: **Methotrexate vs azathioprine in second-line therapy of sarcoidosis**. *Chest*. 2013; **144**(3): 805–12. [PubMed Abstract](#) | [Publisher Full Text](#)
16. Sahoo DH, Bandyopadhyay D, Xu M, *et al.*: **Effectiveness and safety of leflunomide for pulmonary and extrapulmonary sarcoidosis**. *Eur Respir J*. 2011; **38**(5): 1145–50. [PubMed Abstract](#) | [Publisher Full Text](#)
17. Korsten P, Strohmayer K, Baughman RP, *et al.*: **Refractory pulmonary sarcoidosis - proposal of a definition and recommendations for the diagnostic and therapeutic approach**. *Clin Pulm Med*. 2016; **23**(2): 67–75. [PubMed Abstract](#) | [Publisher Full Text](#) | [Free Full Text](#)
18. Arend WP, Michel BA, Bloch DA, *et al.*: **The American College of Rheumatology 1990 criteria for the classification of Takayasu arteritis**. *Arthritis Rheum*. 1990; **33**(8): 1129–1134. [PubMed Abstract](#) | [Publisher Full Text](#)
19. Fang C, Huang H, Xu Z: **Immunological Evidence for the Role of Mycobacteria in Sarcoidosis: A Meta-Analysis**. *PLoS One*. 2016; **11**(8): e0154716. [PubMed Abstract](#) | [Publisher Full Text](#) | [Free Full Text](#)
20. Aggarwal A, Chag M, Sinha N, *et al.*: **Takayasu's arteritis: role of *Mycobacterium tuberculosis* and its 65 kDa heat shock protein**. *Int J Cardiol*. 1996; **55**(1): 49–55. [PubMed Abstract](#) | [Publisher Full Text](#)
21. Kumar Chauhan S, Kumar Tripathy N, Sinha N, *et al.*: **Cellular and humoral immune responses to mycobacterial heat shock protein-65 and its human homologue in Takayasu's arteritis**. *Clin Exp Immunol*. 2004; **138**(3): 547–53. [PubMed Abstract](#) | [Publisher Full Text](#) | [Free Full Text](#)

# Open Peer Review

Current Peer Review Status:



Version 2

Reviewer Report 26 August 2020

<https://doi.org/10.21956/wellcomeopenres.17770.r40058>

© 2020 Krug H. This is an open access peer review report distributed under the terms of the [Creative Commons Attribution License](#), which permits unrestricted use, distribution, and reproduction in any medium, provided the original work is properly cited.



**Hollis E. Krug** 

<sup>1</sup> Rheumatology Department, Veterans Affairs Medical Center, Minneapolis, MN, USA

<sup>2</sup> University of Minnesota Medical School, Minneapolis, MN, USA

This is a well-written report of a rare case of co-existent Takayasu's Arteritis and sarcoidosis. It would benefit from an improved Figure 2 as the one included is of poor quality. The previous diagnosis of granulomatous uveitis could have more discussion including other diseases that could affect the pulmonary and vascular system such as GPA. There is no mention of ANCA testing. The dramatic response to steroids alone supports the diagnoses of both TA and sarcoidosis. The discussion regarding the necessity of ruling out TB is important and well done as is the summary of pathophysiology of both TA and sarcoidosis. I agree with the editorial changes already suggested.

**Is the background of the case's history and progression described in sufficient detail?**

Yes

**Are enough details provided of any physical examination and diagnostic tests, treatment given and outcomes?**

Yes

**Is sufficient discussion included of the importance of the findings and their relevance to future understanding of disease processes, diagnosis or treatment?**

Yes

**Is the case presented with sufficient detail to be useful for other practitioners?**

Yes

**Competing Interests:** No competing interests were disclosed.

**Reviewer Expertise:** Gout, ankylosing spondylitis, osteoarthritis, pain.

**I confirm that I have read this submission and believe that I have an appropriate level of expertise to confirm that it is of an acceptable scientific standard.**

---

**Version 1**

Reviewer Report 15 June 2020

<https://doi.org/10.21956/wellcomeopenres.17372.r38502>

© 2020 Danda D. This is an open access peer review report distributed under the terms of the [Creative Commons Attribution License](#), which permits unrestricted use, distribution, and reproduction in any medium, provided the original work is properly cited.

**Debashish Danda** 

Department of Clinical Immunology and Rheumatology, Christian Medical College, Vellore, Vellore, Tamil Nadu, India

- Acceptable now. Clinical presentation and discussion is relevant. It is a rare association of a rare disease. Tuberculosis as differential has been discussed adequately.
- Images are provided for the readers.
- Although not an exceptional case, it may be still useful for primary and secondary care physicians. Both sarcoidosis and Takayasu are granulomatous inflammatory diseases, hence it is interesting.

**Is the background of the case's history and progression described in sufficient detail?**

Yes

**Are enough details provided of any physical examination and diagnostic tests, treatment given and outcomes?**

Yes

**Is sufficient discussion included of the importance of the findings and their relevance to future understanding of disease processes, diagnosis or treatment?**

Yes

**Is the case presented with sufficient detail to be useful for other practitioners?**

Yes

**Competing Interests:** No competing interests were disclosed.

**Reviewer Expertise:** Takayasu arteritis, Sjogren syndrome, Lupus & spondyloarthropathies



**I confirm that I have read this submission and believe that I have an appropriate level of expertise to confirm that it is of an acceptable scientific standard.**

Author Response 21 Jul 2020

**Sudeep Adhikari**, Patan Academy of Health Sciences, Lalitpur, Nepal

Thank you sir for the review.

**Competing Interests:** No competing interests were disclosed.

Reviewer Report 03 June 2020

<https://doi.org/10.21956/wellcomeopenres.17372.r38723>

© 2020 Dhir V. This is an open access peer review report distributed under the terms of the [Creative Commons Attribution License](#), which permits unrestricted use, distribution, and reproduction in any medium, provided the original work is properly cited.



**Varun Dhir** 

Department of Internal Medicine, Postgraduate Institute of Medical Education and Research, Chandigarh, Punjab and Haryana, India

This is a well written and interesting case report about the coexistence of sarcoidosis and takayasu arteritis. The images are excellent.

However, I have the following suggestions:

1. The current image 5, angiogram, the authors could get a reconstructed 3D image instead of this single coronal plane. Also in the current image, the right subclavian and the carotids are also not visualized.
2. Figure 2 is again not very good and may suggest giving separate mediastinal sections and lung sections - axial.
3. There are some minor language suggestions:
  - rather than "The coexistence of Takayasu arteritis with sarcoidosis is rare, and has been **presented** in a few case reports", it could be better as **reported**.
  - vessel vasculitis causing abnormal pulse and arterial bruits, is **not common** in sarcoidosis." replaced by **distinctly rare**.

**Is the background of the case's history and progression described in sufficient detail?**

Yes

**Are enough details provided of any physical examination and diagnostic tests, treatment**

**given and outcomes?**

Yes

**Is sufficient discussion included of the importance of the findings and their relevance to future understanding of disease processes, diagnosis or treatment?**

Yes

**Is the case presented with sufficient detail to be useful for other practitioners?**

Yes

**Competing Interests:** No competing interests were disclosed.**Reviewer Expertise:** Rheumatology and Clinical Immunology**I confirm that I have read this submission and believe that I have an appropriate level of expertise to confirm that it is of an acceptable scientific standard, however I have significant reservations, as outlined above.**

Author Response 21 Jul 2020

**Sudeep Adhikari**, Patan Academy of Health Sciences, Lalitpur, Nepal

Thank you sir for the review.

We have made changes in the manuscript as per your suggestions.

However, the images showing most of the abnormalities clearly could not be retrieved for reporting due to technical issues, and we have acknowledged that in the revised manuscript.

**Competing Interests:** none

---

## Comments on this article

**Version 1**

Reviewer Response 04 May 2020

**Debashish Danda**, Christian Medical College, Vellore, Vellore, India

This is a rare combination, though reported earlier. It is interesting and description is adequate. I have 1 comment to add.

Was there full angiography of this patient to call it Takayasu arteritis and which classification criteria of Takayasu arteritis did the patient fulfill?

I would like a note on that and if a full angio pic is available, that would be preferable. If not

available, at least explain how Takayasu arteritis was diagnosed.

If these points are mentioned, it can be accepted.

**Competing Interests:** No competing interests were disclosed.

