

Meningioma associated with acute subdural hematoma: A review of the literature

Di Vitantonio Hembra, De Paulis Danilo¹, Ricci Alessandro¹, Marzi Sara¹, Galzio Renato Juan

Department of Life, Health and Environmental Sciences (MESVA), University of L'Aquila, ¹Department of Neurosurgery, San Salvatore City Hospital, L'Aquila, Italy

E-mail: Di Vitantonio Hembra - hembra.divitantonio@gmail.com; *De Paulis Danilo - d.depaulis@alice.it; Ricci Alessandro - alex.ricci@email.it; Marzi Sara - marzi.sara@gmail.com; Galzio Renato Juan - renato.galzio@cc.univaq.it

*Corresponding author

Received: 13 September 14 Accepted: 24 September 14 Published: 30 October 14

This article may be cited as:

Hembra DV, Danilo DP, Alessandro R, Sara M, Juan GR. Meningioma associated with acute subdural hematoma: A review of the literature. *Surg Neurol Int* 2014;5:S469-71. Available FREE in open access from: <http://www.surgicalneurologyint.com/text.asp?2014/5/13/469/143724>

Copyright: © 2014 Hembra DV. This is an open-access article distributed under the terms of the Creative Commons Attribution License, which permits unrestricted use, distribution, and reproduction in any medium, provided the original author and source are credited.

Abstract

Background: Classically meningiomas present with a gradual onset of symptoms and their acute presentation with hemorrhagic events seems to be a rare event. A review of the literature shows only 18 cases of meningioma associated with acute subdural hematoma. The possible mechanisms of hemorrhage are not yet fully understood.

Case Description: We report a case of sphenoid wing meningioma associated with acute subdural hematoma, without history of trauma. The presence of meningioma was discovered during the surgery. The tumor and hematoma were removed without postoperative complications.

Conclusions: The authors have discussed the etiology of an acute subdural hemorrhage and reviewed the pertinent literature.

Key Words: Acute subdural hematoma, hemorrhage, meningioma

Access this article online

Website:

www.surgicalneurologyint.com

DOI:

10.4103/2152-7806.143724

Quick Response Code:



INTRODUCTION

Meningioma usually manifests with a gradual onset of symptoms.^[3] Therefore, the acute presentation of meningiomas with hemorrhagic events seems to be a rare event. From case history, it seems that malignant and metastatic tumors are more prone to bleed; therefore, they are the most common neoplasms that show a sudden onset.^[21]

Only 18 cases of meningioma with acute subdural hematoma have been reported.^[1,4-7, 9,11-20,22]

CASE REPORT

A 59-year-old male on prophylactic antiplatelet therapy was admitted to our institute with sudden headache

and dysphasia, accompanied by nausea and vomiting. The patient complained of the following influenza symptoms: Weakness, fever, runny nose for the last 7 days. There is no history of traumatic events. Laboratory tests showed coagulation indices within normal limits. Computed tomography scan (CT scan) of the head showed an acute subdural hematoma that extended from the left frontal lobe to the left temporal lobe [Figure 1].

A left pterional craniotomy was performed. A massive acute subdural hematoma was evacuated and an extra-axial lesion was identified on the left sphenoid wing with evidence of tumor bleeding. A Simpson grade I excision was performed. The histopathological diagnosis deposited for angiomatous and papillary meningioma with angio-invasiveness aspects of the dura [Figure 2].

Postoperative magnetic resonance (MR) showed no residual tumor [Figure 3]. Follow-up at 1 year showed no recurrence of the disease in the absence of neurologic deficits.

DISCUSSION

Non-traumatic acute subdural hematoma is an uncommon complication of meningiomas. Currently, only 18 cases have been described in literature.^[1,4-7,9,11-20,22]

The average age of patients (60 years) is slightly higher than the normal peak incidence of meningiomas, with a female prevalence (11:7), but the most frequent localization is the convexity.

There is insufficient evidence to show that hypertension and antiplatelet therapy are the factors responsible for bleeding, although hypertension and anticoagulation have been documented as precipitating factors of the hemorrhage in meningiomas [Table 1].^[8]

Bleeding in a malignant tumor generally results from weakness of neoplastic vessel, infiltration of tumor cells into the vessel, and tendency of the mural endothelium to proliferate, leading to vessel destruction and necrosis.

However, the mechanism leading to hemorrhage associated with meningioma is apparently not the same and not fully understood.^[9]

Some authors have emphasized a high risk of hemorrhage in angioblastic and malignant meningiomas, although transitional subtypes are the most common. In angioblastic meningiomas, it has been assumed that the thin-walled vessels are too fragile, causing easy bleeding. In malignant meningiomas, like other anaplastic tumors, direct invasion or endothelial proliferation by the tumor may obstruct the vascular channel, producing congestion and necrosis, resulting in hemorrhage, which can extend into subdural space.^[12]

In syncytial meningiomas, the bleeding is probably related to the presence of intratumoral vasoactive substances released, such as histamine, which could induce vasodilatation and tumoral hemorrhage.^[7]

The mechanical stretching and distortion of bridging veins by meningiomas may also be associated with hemorrhage.^[12]

Some authors do not believe there is a relationship between histological subtype and high risk of hemorrhage, but everyone seems to agree that age and sex of the patient do not show significant relationship with the hemorrhagic event.^[10]

The role of the location of the meningioma is controversial. According to Worm *et al.*, the localization of the tumor in the cerebral convexity increases the risk

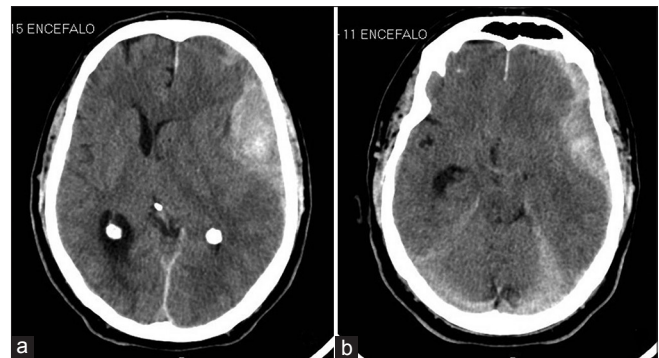


Figure 1: CT scan on admission showing an acute subdural hematoma extending from the left frontal lobe to the left temporal lobe (a, b)

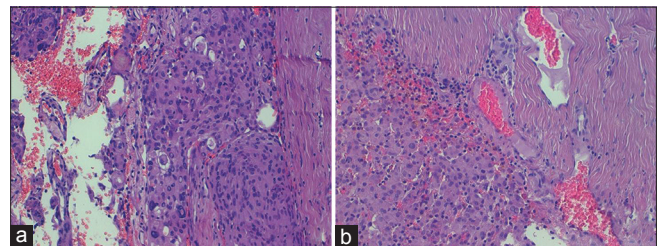


Figure 2: Photomicrographs of tumor specimens (Hematoxylin and Eosin); the histological diagnosis was angiomatous and papillary meningioma (a) with angio-invasiveness aspects of the dura (b)

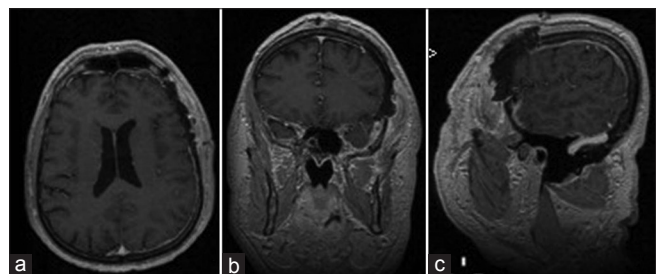


Figure 3: Postoperative MR (a-c) in axial, coronal, sagittal views

of hemorrhage.^[22] On the contrary, Chakis *et al.* believe that the site of the meningioma does not seem to influence the occurrence of hemorrhage,^[2] although most of the cases reported in the literature are located in the convexity.

CONCLUSION

In our case, the lesion invaded the dura and destroyed the bone. In our opinion, the bone changes are the origin of the hemorrhage in the case presented. Acute subdural hematomas caused by meningiomas have high mortality, and although meningiomas tend to evolve slowly, radical excision should be recommended.

Moreover, the presence of a meningioma should always be suspected in the presence of non-traumatic acute subdural hematoma.

Table 1: Review of the literature of meningioma associated with acute subdural hematoma

| Authors, year | Pt. age (years) and sex | Location | Hypertension | Antiplatelet therapy | Head trauma | Histology |
|-----------------|-------------------------|---------------------------------|--------------|----------------------|-------------|-------------------------------|
| Tokunaga, 1988 | 61, F | Left temporo-parietal convexity | Not reported | Not reported | No | Transitional |
| Sato, 1989 | 46, F | Middle temporal fossa | Not reported | Not reported | No | Not reported |
| Niikawa, 1990 | 49, F | Left parietal convexity | Not reported | Not reported | No | Meningothelomatous |
| Renowden, 1992 | 41, F | Parasagittal | Not reported | Not reported | No | Syncytial |
| Russel, 1993 | 55, F | Right frontal convexity | Not reported | Not reported | No | Transitional |
| Ueno, 1993 | 67, M | Left temporal convexity | No | Not reported | No | Vacuolated and meningothelial |
| Spektor, 1995 | 73, F | Left parietal convexity | Yes | Yes | No | Angioblastic |
| Shimizu, 1998 | 67, M | Left parietal convexity | Not reported | Not reported | No | Meningothelial |
| Sunada, 1998 | 48, F | Parasagittal | Not reported | Not reported | No | Fibrous |
| Okuno, 1999 | 78, F | Falx | Not reported | Not reported | No | Transitional |
| Lefranc, 2001 | 62, M | Frontal | Not reported | Not reported | No | Syncytial |
| (2 cases) | 68, F | Parietal | Not reported | Not reported | No | Transitional |
| Goyal, 2003 | 66, M | Falx | Not reported | Not reported | No | Transitional |
| Mitsuhara, 2006 | 60, F | Petrotentorial | Not reported | Not reported | No | Meningothelial |
| Kashimura, 2008 | 50, M | Convexity right temporal | Not reported | Not reported | No | Lipomatous |
| Worm, 2009 | 64, M | Falx | Not reported | Not reported | No | Not reported |
| Lakshmi, 2010 | 73, M | Right sphenoid wing | Not reported | Not reported | No | Not reported |
| Chonan, 2013 | 67, F | Fronto-temporal convexity | Not reported | Not reported | No | Meningothelial |

REFERENCES

- Chonan M, Niizuma K, Koyama S, Kon H, Sannohe S, Kurotaki H, et al. An operated case of a meningioma causing acute subdural hematoma. *No Shinkei Geka* 2013;41:235-9.
- Chaskis C, Raftopoulos C, Noterman J, Flament-Durand J, Brotchi J. Meningioma Associated with subdural haematoma: Report of 2 cases and review of the literature. *Clin Neurol Neurosurg* 1992;94:269-74.
- El-Banhawy A, Walter VV. Meningioma with acute onset. *Acta Neurochir (Wien)* 1962;10:194-206.
- Goyal A, Singh AK, Kumar S, Gupta V, Singh D. Subdural hemorrhage associated with falx meningioma. *Neurol India* 2003;51:419-21.
- Kashimura H, Arai H, Ogasawara K, Beppu T, Kurose A, Ogawa A. Lipomatous meningioma with concomitant acute subdural hematoma--case report. *Neurol Med Chir (Tokyo)* 2008;48:466-9.
- Lakshmi Prasad G, Ramdurg SR, Suri A, Mahapatra AK. A rare association of meningioma with intratumoral bleed and acute subdural hematoma. *Neurol India* 2010;58:977-8.
- Lefranc F, Nagy N, Dewitte O, Baleriaux D, Brotchi J. Intracranial meningiomas revealed by non-traumatic subdural haematomas. A series of four cases. *Acta Neurochir (Wien)* 2001;143:977-83.
- Martinez-Lage JF, Poza M, Martinez M, Esteban JA, Antunez MC, Sola J. Meningiomas with haemorrhagic onset. *Acta Neurochir (Wien)* 1991;110:129-32.
- Mitsuhara T, Ikawa F, Ohbayashi N, Imada Y, Abiko M, Inagawa T. A case of petrotentorial meningioma presented as an acute subdural hemorrhage. *No Shinkei Geka* 2006;34:827-32.
- Niuro M, Ishimaru K, Hirano H, Yunoue S, Kuratsu J. Clinico-pathological study of meningiomas with haemorrhagic onset. *Acta Neurochir (Wien)* 2003;145:767-72.
- Nikawa S, Kawaguchi M, Sugimoto S, Hattori T, Ohkuma A. Meningioma associated with subdural hematoma: Case report. *Neurol Med Chir (Tokyo)* 1990;30:169-72.
- Okuno S, Touho H, Ohnishi H, Karasawa J. Falx meningioma presenting as acute subdural hematoma: Case Report. *Surg Neurol* 1999;52:180-4.
- Renowden SA, Hourihan MD. Case report: Acute subdural haematoma an unusual presentation of a meningioma. *Clin Radiol* 1992;45:351-2.
- Russell NA, Al-Fayez N, Joaquin AJ. Acute subdural hematoma with intracranial meningioma. *Ann Saudi Med* 1993;13:369-71.
- Sato K, Sugawara T, Fujiwara S, Mizoi K, Yoshimoto T. A case of small meningioma with acute subdural hematoma. *No Shinkei Geka* 1989;17:687-90.
- Shimizu J, Tazawa T, Park-Matsumoto YC, Katano T, Akiba Y, Kuroiwa T. Meningioma associated with acute subdural hematoma: A case report. *No Shinkei Geka* 1998;26:743-7.
- Spektor S, Ashkenazi E, Israel Z. Intracranial haemorrhage from a meningioma in a patient receiving aspirin prophylaxis: A case report. *Acta Neurochir (Wien)* 1995;134:51-3.
- Sunada I, Nakabayashi H, Matsusaka Y, Yamamoto S. Meningioma associated with acute subdural hematoma--case report. *Radiat Med* 1998;16:483-6.
- Tokunaga T, Kuboyama M, Kojo N, Matsuo H, Shigemori M, Kuramoto S. A case of acute subdural hematoma associated with convexity meningioma. *No Shinkei Geka* 1988;16:1389-93.
- Ueno M, Nakai E, Naka Y, Kido T, Itakura T, Komai N. Acute subdural hematoma associated with vacuolated meningioma. Case Report. *Neurol Med Chir (Tokyo)* 1993;33:36-9.
- Wakai S, Yamakawa K, Manaka S, Takakura K. Spontaneous intracranial hemorrhage caused by brain tumor: Its incidence and clinical significance. *Neurosurgery* 1987;10:437-44.
- Worm PV, Ferreira MP, Ferreira NP, Cechetti F. Subdural haematoma in a patient with meningioma. *Arq Neuropsiquiatr* 2009;67:308-10.