

## Clinical Article

# Clinical Outcomes of Percutaneous Endoscopic Surgery for Lumbar Discal Cyst

Sang Woo Ha, M.D.,<sup>1</sup> Chang Il Ju, M.D.,<sup>1</sup> Seok Won Kim, M.D., Ph.D.,<sup>1</sup> SeungMyung Lee, M.D., Ph.D.,<sup>1</sup> Yong Hyun Kim, M.D., Ph.D.,<sup>2</sup> Hyeun Sung Kim, M.D., Ph.D.<sup>3</sup>

*Department of Neurosurgery,<sup>1</sup> College of Medicine, Chosun University, Gwangju, Korea*

*Department of Neurosurgery,<sup>2</sup> Cheomdan Medical Center, Gwangju, Korea*

*Department of Neurosurgery,<sup>3</sup> Hurisarang Hospital, Daejeon, Korea*

**Objective :** Discal cyst is rare and causes indistinguishable symptoms from lumbar disc herniation. The clinical manifestations and pathological features of discal cyst have not yet been completely known. Discal cyst has been treated with surgery or with direct intervention such as computed tomography (CT) guided aspiration and steroid injection. The purpose of this study is to evaluate the safety and efficacy of the percutaneous endoscopic surgery for lumbar discal cyst over at least 6 months follow-up.

**Methods :** All 8 cases of discal cyst with radiculopathy were treated by percutaneous endoscopic surgery by transforaminal approach. The involved levels include L5-S1 in 1 patient, L3-4 in 2, and L4-5 in 5. The preoperative magnetic resonance imaging and 3-dimensional CT with discogram images in all cases showed a connection between the cyst and the involved intervertebral disc. Over a 6-months period, self-reported measures were assessed using an outcome questionnaire that incorporated total back-related medical resource utilization and improvement of leg pain [visual analogue scale (VAS) and Macnab's criteria].

**Results :** All 8 patients underwent endoscopic excision of the cyst with additional partial discectomy. Seven patients obtained immediate relief of symptoms after removal of the cyst by endoscopic approach. There were no recurrent lesions during follow-up period. The mean preoperative VAS for leg pain was  $8.25 \pm 0.5$ . At the last examination followed longer than 6 month, the mean VAS for leg pain was  $2.25 \pm 2.21$ . According to MacNab's criteria, 4 patients (50%) had excellent results, 3 patients (37.5%) had good results; thus, satisfactory results were achieved in 7 patients (87.5%). However, one case had unsatisfactory result with persistent leg pain and another paresthesia.

**Conclusion :** The radicular symptoms were remarkably improved in most patients immediately after percutaneous endoscopic cystectomy by transforaminal approach.

**Key Words :** Lumbar discal cyst · Percutaneous endoscopic transforaminal cystectomy.

## INTRODUCTION

Discal cysts were referred as intraspinal extraepidural cysts with a distinct connection to the corresponding intervertebral discs<sup>8,21,38</sup>). Discal cyst is rare and it could be a main cause of indistinguishable radiculopathy from lumbar disc herniation. Reported symptomatic discal cysts have been treated by simple excision of the lesion or direct intervention<sup>5,8,16,19,20</sup>). Lumbar discal cysts were first described in 2001 by Chiba et al.<sup>8</sup>) and they reported 8 patients in Japan who underwent open surgical treatment. However, except for some case report, to our knowledge, the endoscopic surgical results for lumbar discal cysts

have not been reported. We applied a percutaneous endoscopic discal cystectomy by transforaminal approach to the symptomatic lumbar discal cyst with radiculopathy and the results are reported with a review of the literature.

## MATERIALS AND METHODS

### Patients and methods

Between January 2007 and September 2010, total 8 cases of lumbar discal cyst with symptomatic radiculopathy were selected for endoscopic surgery. All lumbar discal cyst were confirmed by radiological and operative findings. We have performed percuta-

• Received : December 21, 2011 • Revised : March 26, 2012 • Accepted : April 15, 2012

• Address for reprints : Chang Il Ju, M.D.

Department of Neurosurgery, College of Medicine, Chosun University, 365 Pilmun-daero, Dong-gu, Gwangju 501-717, Korea

Tel : +82-62-220-3126, Fax : +82-62-227-4575, E-mail : jchangil@chosun.ac.kr

• This is an Open Access article distributed under the terms of the Creative Commons Attribution Non-Commercial License (<http://creativecommons.org/licenses/by-nc/3.0>) which permits unrestricted non-commercial use, distribution, and reproduction in any medium, provided the original work is properly cited.

neous endoscopic transforaminal discal cystectomy and additional partial discectomy. All patients met the following criteria : 1) unilateral radicular leg pain, 2) lumbar discal cyst without disc herniation or spinal stenosis 3) no history of previous lumbar surgery, 4) failure of appropriate conservative treatment, and 5) neither instability nor spondylolisthesis.

First of all lumbar discal cysts were detected in the magnetic resonance images (MRI) and confirmed by 3-dimensional (3D) reconstruction computed tomography (CT) images with discogram (Fig. 1).

All patients who were selected for percutaneous endoscopic cystectomy were young male as 1 teenager, 6 cases of the 20s and one case of the 30s.

Postoperatively, all patients have been studied over at least 6 months and average follow-up period was 15 months.

**Anesthesia**

Epidural anesthesia was performed in all cases. Both 100 µg of fentanyl and 0.5% pucain was diluted by 1/2 and prepared as a 0.25% solution and approximately 15-20 cc injected into the epidural space or 15-20 cc of 0.5% Bupivacain stock solution was injected into the epidural space.

**Surgical technique**

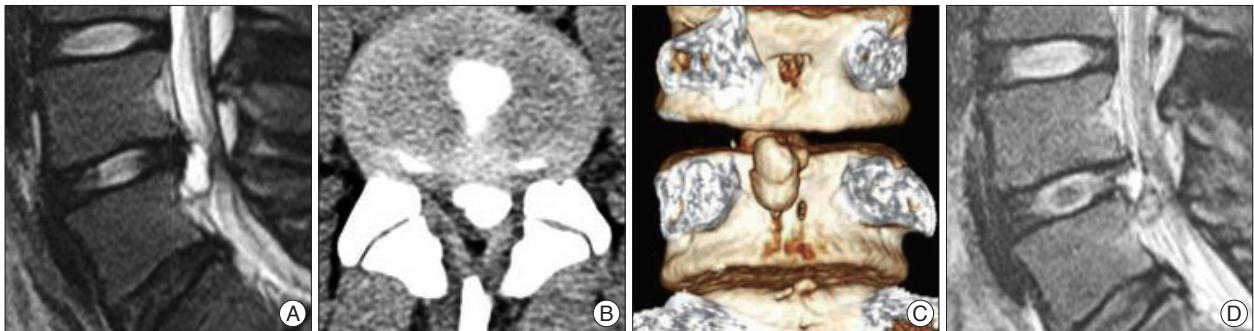The sequence of surgery was identical to the conventional percutaneous endoscopic transforaminal approach<sup>1,30,34</sup>. Prior

to the endoscopic procedure, using indigo-carmin dye, evocative chromodiskography was performed at the involved level<sup>24,31</sup>. A 1 cm-sized skin incision was placed 8-12 cm away from the midline according to the exact location of discal cyst. An operative sheath (YESS System; Wolf, Knittlingen, Germany) was installed in the disc space. In the endoscopic view, usually adhesion between discal cyst and disc material had been severe and vasculatures were well developed. For a successful surgery, it is very important procedure to remove the stalk of disc as well as the capsule of discal cyst. If the case required disc decompression, it was better to first perform decompression identical to the posterolateral procedure.

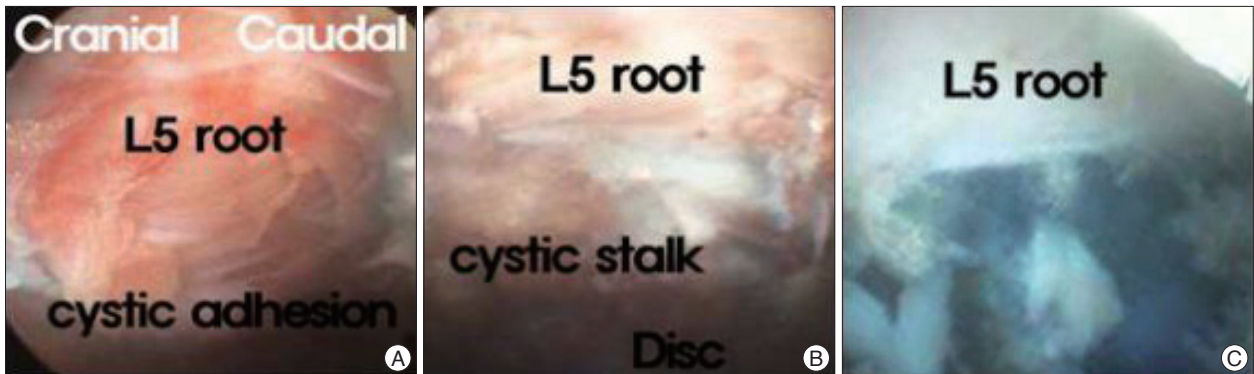In most our cases, we have performed decompressive discectomy at first and then followed cystectomy in order to reduce the risk of direct nerve root injury.

After completion of the decompression, discal stalk connected with cyst was removed. Finally, the nerve root went free and it was confirmed in endoscopic view.

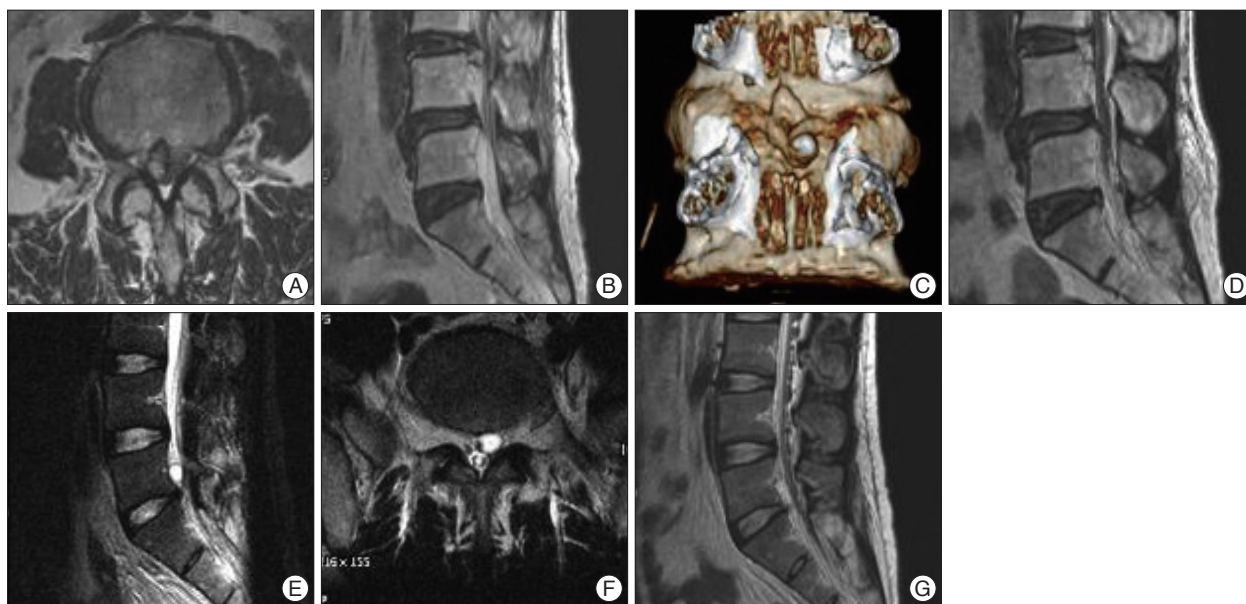
If cyst membrane could not be removed completely, a multiple fenestration of membrane was done by radiofrequency (RF) electrocautery. We made multiple fenestration of residual membrane in 2 cases. During removal of discal cyst and decompression of nerve root, we frequently had met bleeding due to adhesion of structures of peridiscal cyst. However, it could be controlled by bipolar coagulation and saline irrigation. Finally, we were able to expose the involved nerve root moving freely (Fig. 2).



**Fig. 1.** A : Preoperative magnetic resonance (MR) sagittal image showing discal cyst on L4-5. B and C : Preoperative discogram with 3D reconstruction computed tomography showing a connecting channel between the cyst and the corresponding disc. D : Postoperative MR image showing discal cyst which has been successfully removed. 3D : 3-dimensional.



**Fig. 2.** Endoscopic view of discal cyst by transforaminal approach. A : Right L5 nerve root is compressed by discal cyst with adhesion. B : Discal cystic stalk is connected to disc material beneath the L5 nerve root. C : L5 nerve root could be free after removal of discal cyst as well as cystic stalk.



**Fig. 3.** A and B : Preoperative magnetic resonance (MR) showing discal cyst on L3-4. C : Preoperative discogram with 3D reconstruction computed tomography showing a connecting channel between the cyst and the corresponding disc. D : Postoperative MR image showing discal cyst which has been successfully removed. E and F : Preoperative MR showing discal cyst on L5-S1. G : Postoperative MR image. 3D : 3-dimensional.

**Table 1.** Results of percutaneous endoscopic discectomy and additional discectomy by transforaminal approach

Case	Age/Sex	Level	PreOP symptoms	PreOP VAS	PostOP VAS	Macnab's criteria	Complication
1	19/M	L4-5 (Lt.)	LBP & leg pain later	8	1	Excellent	
2	22/M	L5-S1 (Lt.)	LBP & leg pain later	9	3	Good	Transient paresis
3	21/M	L4-5 (Rt.)	LBP & leg pain later	7	1	Excellent	
4	25/M	L4-5 (Rt.)	LBP & leg pain simulatneously	8	5	Fair	Hypesthesia Transient paresis
5	20/M	L3-4 (Lt.)	LBP & leg pain simulatneously	9	3	Good	Transient hypesthesia
6	22/M	L4-5 (Rt.)	LBP & leg pain later	8	3	Good	Transient hypesthesia
7	21/M	L3-4 (Rt.)	LBP & leg pain later	8	1	Excellent	
8	35/M	L4-5 (Lt.)	LBP & leg pain simulatneously	9	1	Excellent	
Average	23.1			8.25	2.25		

VAS : Visual Analogue Scale

**Evaluation**

All cysts connected to the corresponding intervertebral discs were confirmed by the MRI and 3D CT image with the discogram prior to surgery.

Approximately 1-4 hours after surgery, the remnant of discal cyst was assessed by the postoperative-MRI. Six month after surgery, symptomatic improvement was evaluated by the Visual Analogue Pain Score (VAS), including neurologic tests and MacNab's criteria.

**RESULTS**

Total 8 male patients were treated for discal cysts at between January 2007 and September 2010. Their mean age was 23.1 years (range 19-35 years). None had any history of trauma. The average follow-up was 18.3 months (range 6-64 months). All 8 patients have clinical symptoms, indistinguishable from those of

typical disc herniation, manifesting as a unilateral radiculopathy.

The mean operation time was 2 hours and the average length of stay in hospital was 3 days.

All MR images of patients have shown low signal intensity in T1-weighted image and high signal intensity in T2-weighted image, round to oval mass lesion on MRI, are compatible with a liquid-containing cyst.

The involved levels were L5-S1 in 1 patient, L3-L4 in 2, and L4-L5 in 5. Five patients experienced initial back pain later spreading to radiating leg pain and 3 patients noticed the both simultaneously (Table 1). All of the patients suffered from unilateral lower extremity pain and positive tension sign. Although the straight leg raising test was positive in all patients, their low-back pain was mild. The average interval between the initial clinical examination and surgery was 3 months (range 1-6 months).

The preoperative MRI and 3D CT with discogram images in all cases showed cyst connected to the intervertebral disc.

Postoperative MRI and follow-up MRI after 6 months showed no evidence of recurrence of cyst. Also, there was no progression of disc degeneration or herniation. Histological examination of the cyst wall revealed fibrous connective tissue without evidence of epithelial lining cell or disc materials in all patients.

The mean preoperative VAS for leg pain was  $8.25 \pm 0.5$ . At the last follow-up examination, after an average period of more than 6 months postoperatively, the mean VAS for leg pain was  $2.25 \pm 2.21$ .

According to MacNab's criteria, 4 patients (50%) had excellent results, 3 patients (37.5%) had good results; thus, satisfactory results were achieved in 7 patients (87.5%). One patient (12.5%) had fair result, and none (0%) had poor results (Table 1).

In 2 cases, transient paresis of leg developed, but resolved during follow-up over a week period. In 3 cases, transient hypoesthesia developed, and among them, the transient hypoesthesia resolved during follow-up in 2 weeks, but one patient had a persistent leg pain and newly developed paresthesia after 6 months. The reason of unsatisfactory result is not clear, but we consider there is high possibility of iatrogenic nerve root injury on right L5.

## DISCUSSION

The discal cyst is one of the intraspinal cyst<sup>(28,29,33)</sup> and intraspinal cyst can be differentiated into discal cyst as well as synovial cyst<sup>(4,5,35)</sup>, ganglion cyst<sup>(6,25,41)</sup>, Tarlov perineural cyst<sup>(36,42)</sup>, extradural arachnoid cyst<sup>(4)</sup>, dermoid cyst<sup>(7,13)</sup> and cystic schwannoma<sup>(2)</sup>.

Discal cysts were referred as intraspinal extraepidural cysts with a distinct connection to the corresponding intervertebral discs<sup>(8,12,21,38)</sup>. In general, most patients with discal cysts are in their third or fourth decade of life and are more likely to be male. In contrast, intraspinal cysts from the facet and the ligamentum flavum usually arise in elderly people with degenerative diseases and/or instability of the lumbar spine<sup>(3,8,15,28,29,33)</sup>.

The pathogenesis of discal cysts remains unknown. Chiba et al.<sup>(8)</sup> hypothesized that an epidural hematoma from an underlying intervertebral disc injuries initially formed from hemorrhage of the epidural venous plexus that occurs in the space between the peridural membrane and the vertebral body, and discal cysts form most likely as a consequence of impairment of hematoma resorption. Kono et al.<sup>(20)</sup> insisted that the pathogenesis of discal cysts is focal degeneration of the intervertebral disc with fluid production similar to that of meniscal cysts of the knee and synovial cysts of the facet joint. The extruded fluid from the herniated disc material provokes an inflammatory response leading to reactive pseudo-membrane formation and the development of a discal cyst.

Jeong and Bendo<sup>(17)</sup> have argued that the underlying pathological mechanism of discal cysts was not a vascular phenomenon but a subsequent change in a herniated disc.

In most our cases, in the endoscopic view, all the outer membrane of discal cyst were frequent hard and tight feature connected with annulus fibrosus and high vascularities. However,

in the inner part of discal cyst, there were soft nucleus pulposus and no vascularity. Also, there were enough space between outer tight cystic membrane and inner soft nucleus pulposus tissues. Histologically, hemosiderin laden macrophages meaning of evidence of hematoma were not detected. It means, at the first time, disc materials were herniated to epidural space and then slowly resolute with regress and shrinkage. At that time adhesive changes happened simultaneously between discal cyst and dura mater as well as nerve roots, also, fluid were collected in the space between the outer and inner membrane. Therefore, we support the theory of a subsequent change in a herniated disc as the pathological mechanism of discal cysts instead of vascular phenomenon.

During removal outer tight membrane, the outer membrane usually connected with discal stalk and it took longer time to remove them completely. Sometimes this procedure was difficult and more risky to injure traversing nerve root because of massive bleeding from plentiful vasculature around cyst. In such cases, multiple fenestration to cystic membrane could be another option. However, once inner disc material exposed after removal outer layer, the procedure to remove cystic materials and nucleus pulposus has been easier.

We have experienced 1 case of unsatisfactory result of percutaneous endoscopic cystectomy, right L5 traversing nerve root has been injured iatrogenically during removal of the tight outer membrane of cyst. During control of massive bleeding around cyst, without securing endoscopic view clearly, unconsciously the traversing nerve root could be injured by RF coagulation. Also, we consider an excessive access of rigid endoscope to the cystic lesion could cause compressing a traversing nerve root in the narrowed epidural space.

The clinical symptoms and signs of patients with discal cysts are similar to those of patients with a typical disc herniation manifesting as a unilateral radiculopathy.

The MRI is very effective method to identify discal cysts accurately. Usually, discal cysts shows a low signal intensity on T1-weighted images and a high signal intensity on T2-weighted images. However, this signal can vary depending on the contents of fluid. The surrounding peripheral rim and the contents of the cyst are enhanced by Gd-DTPA on the contrast enhanced MR images. A connecting channel between the cyst and the corresponding disc is the key to differentiate discal cysts from lumbar disc herniation. In spite of its invasive nature, it was reported that the discography is necessary to confirm communication between the cyst and the corresponding disc<sup>(8)</sup>.

We have studied 3D-reconstruction CT with discogram, and it helped us to differentiate discal cysts from lumbar disc herniation or other intraspinal cysts exactly. Also, from 3D-reconstruction CT images with discogram, we could obtain the information about discal cyst, such as location, shape, volume, anatomic relationship as well as to determine the direction of the working cannula accessing the discal cyst.

The natural history of discal cysts is still unknown. There is



only one case report on spontaneous regression of a discal cyst<sup>11</sup>. Therefore, still now, a therapeutic strategy for discal cysts remains to be established.

The symptomatic discal cysts have been treated surgically or direct intervention. Koga et al.<sup>20</sup> reported a good clinical results from percutaneous CT-guided puncture and steroid injection. In this minimally invasive procedure, it is essential that the accurate penetration on the cyst without nerve root injury<sup>10</sup>. The first surgical treatment of 8 cases of discal cyst by microscopic resection was reported by Chiba et al.<sup>8</sup> Recently, several authors reported experience of surgical excision of lumbar discal cysts<sup>16,22,23,26,27</sup>. Most surgical excision of the cysts for symptomatic discal cysts were reported as very effective for pain relief.

Recurrence rate of discal cyst after surgical excision is not exactly known. However, one case of recurrence after surgically removal of discal cyst was reported by Lee et al.<sup>22</sup>

Several authors reported the treatment of discal cyst without surgery. Demaerel et al.<sup>11</sup> reported a case of spontaneous imaging-documented cyst regression and symptomatic relief without surgery. Chou et al.<sup>9</sup> reported routine epidural injection and selective nerve root block could make discal cyst regress spontaneously in 2007.

Recently, various minimal invasive methods have been introduced to treat the intraspinal cystic lesion. Ishii et al.<sup>16</sup> reported 2 cases of endoscopic resection of intraspinal cyst.

In 2009, Kim et al.<sup>19</sup> reported a case of endoscopic transforaminal approach for the treatment of discal cyst and the traversing nerve root could be successfully decompressed and the unilateral radiculopathy subsided immediately after the procedure. Most previous studies were small series, whereas we have treated 8 cases of discal cyst by using endoscopic transforaminal approach.

In our cases, we have removed the discal cyst by percutaneous endoscopic transforaminal approach. Usually, adhesion between discal cyst and disc material has been severe and vasculatures were well developed in the endoscopic view.

When removal of discal cyst is performed by endoscopic surgery, the stalk between disc material and the capsule of disc should be confirmed and it is very important to remove the stalk of disc as well as the capsule of discal cyst.

During the endoscopic cystectomy, only removal of discal cystic membrane without injury of annulus could be enough to provide good surgical results. However, in our cases, we have performed additional partial discectomy to reduce recurrence of discal cyst or pseudocyst.

Theoretically, additional partial discectomy was performed to remove a degenerated nucleus pulposus and stabilize it not to be reherniated by RF electrocautery concealing. The inner layer of membrane of nucleus pulposus has been already exposed by discal cystectomy. The possibility of reherniation of nucleus pulposus has not reduced significantly after cystectomy. If the nucleus pulposus will reherniated, it will cause adhesive change in the epidural space around annulus fibrosus and nerve root. After

then, it will be resolved or regressed by itself, following same mechanism of discal cyst, it will cause new cyst. Our additional partial discectomy, though not perfect, could reduce the total volume of nucleus pulposus and RF coagulation make nucleus pulposus more stable. This procedure could help to prevent reherniation of nucleus pulposus.

Another reason of partial discectomy additionally is to prevent the postoperative discal pseudocyst occurrence. The theory of postoperative discal pseudocyst occurrence mechanism has been suggested in disc herniation and it is not clear applying to discal cyst.

Young et al.<sup>45</sup> reported when granulation tissue elicited by a herniated disc fragment surrounds a discrete fragment, it may form a pseudocapsule around the fragment, extending to the disc margin. If the disc fragment is removed but the pseudocapsule is not disrupted, fluid may accumulate through diffusion across the disrupted annulus, accentuated by increased disc pressure from repetitive loading.

Pathogenesis of postoperative pseudocapsule is likely associated with inflammation of the connective tissue at the procedure site, resulting in the pseudocyst. In particular, postoperative inflammatory reaction of posterior longitudinal ligament and annulus complex were supposed to be related with postoperative pseudocapsule formation<sup>18,32,45</sup>.

The postoperative condition of cystectomy comparing to discectomy could be different from each other. However, discal cyst also has the granulation tissue surrounds outer layer of cystic membrane like disc fragment and it may cause pseudocapsule. If the pseudocapsule remained, the fluid may accumulate through diffusion across the disrupt annulus, accentuated by increased disc pressure from repetitive loading. Also, during endoscopic surgery, heat from RF cautery or laser coagulation can cause inflammation.

Endoscopic lumbar cystectomy is less traumatizing and minimal invasive procedure without resection of bone and ligament. Comparing to open traditional cystectomy, this procedure has many advantages such as shorter operative time, less scarring with preserving epidural fat and yellow ligaments, less post-discectomy syndrome and easier revision surgery<sup>37,39,40</sup>.

Interlaminar approach is also another percutaneous endoscopic method to remove herniated disc materials as well as discal cyst. This approach is very useful in the cases with large interlaminar space like L5-S1 level. In our case of L5-S1 discal cyst, we could perform percutaneous transforaminal endoscopic cystectomy successfully, fortunately, because the iliac crest was not so high enough to access to L5-S1 disc level without blockage. However, as interlaminar approach is a better method in L5-S1 level, also interlaminar approach is useful for L5-S1 endoscopic discal cystectomy.

## CONCLUSION

A percutaneous endoscopic discal cystectomy is an effective

minimal invasive surgical treatment for symptomatic lumbar discal cyst. Our endoscopic operative findings showed that cystic membrane is originated from subsequent change in a herniated disc. MRI and CT with discogram is essential for the exact diagnosis and making the plan of the endoscopic approach.

#### • Acknowledgements

This paper was supported by research Chosun University in 2010.

#### References

- Abdullah AF, Wolber PG, Warfield JR, Gunadi IK : Surgical management of extreme lateral lumbar disc herniations : review of 138 cases. *Neurosurgery* 22 : 648-653, 1988
- Akhaddar A, Ajja A, Albouzidi A, Elmostarchid B, Boucetta M : Cystic schwannoma of the cauda equina mimicking hemangioblastoma. *Neurochirurgie* 54 : 101-103, 2008
- Baker JK, Hanson GW : Cyst of the ligamentum flavum. *Spine (Phila Pa 1976)* 19 : 1092-1094, 1994
- Baum JA, Hanley EN Jr : Intraspinial synovial cyst simulating spinal stenosis. A case report. *Spine (Phila Pa 1976)* 11 : 487-489, 1986
- Boviatsis EJ, Stavrinou LC, Kouyialis AT, Gavra MM, Stavrinou PC, Themistokleous M, et al. : Spinal synovial cysts: pathogenesis, diagnosis and surgical treatment in a series of seven cases and literature review. *Eur Spine J* 17 : 831-837, 2008
- Brish A, Payan HM : Lumbar intraspinal extradural ganglion cyst. *J Neurol Neurosurg Psychiatry* 35 : 771-775, 1972
- Buchwald C, Børgesen SE : Intraspinial thoracolumbar dermoid. Case report. *Acta Neurochir (Wien)* 101 : 163-164, 1989
- Chiba K, Toyama Y, Matsumoto M, Maruiwa H, Watanabe M, Nishizawa T : Intraspinial cyst communicating with the intervertebral disc in the lumbar spine : discal cyst. *Spine (Phila Pa 1976)* 26 : 2112-2118, 2001
- Chou D, Smith JS, Chin CT : Spontaneous regression of a discal cyst. Case report. *J Neurosurg Spine* 6 : 81-84, 2007
- Coscia MF, Broshears JR : Lumbar spine intracanalicular discal cysts : two case reports. *J Spinal Disord Tech* 15 : 431-435, 2002
- Demaerel P, Eerens I, Goffin J, Wilms G : Spontaneous regression of an intraspinal disc cyst. *Eur Radio* 111 : 2317-2318, 2001
- Fardon DE, Milette PC : Nomenclature and classification of lumbar disc pathology. Recommendations of the Combined task Forces of the North American Spine Society, American Society of Spine Radiology, and American Society of Neuroradiology. *Spine (Phila Pa 1976)* 26 : E93-E113, 2001
- Goyal A, Singh D, Singh AK, Gupta V, Sinha S : Spontaneous rupture of spinal dermoid cyst with disseminated lipid droplets in central canal and ventricles. *J Neurosurg Sci* 48 : 63-65, 2004
- Goyal RN, Russell NA, Benoit BG, Belanger JM : Intraspinial cysts : a classification and literature review. *Spine (Phila Pa 1976)* 12 : 209-213, 1987
- Hsu KY, Zucherman JF, Shea WJ, Jeffrey RA : Lumbar intraspinal synovial and ganglion cysts (facet cysts). Ten-year experience in evaluation and treatment. *Spine (Phila Pa 1976)* 20 : 80-89, 1995
- Ishii K, Matsumoto M, Watanabe K, Nakamura M, Chiba K, Toyama Y : Endoscopic resection of cystic lesions in the lumbar spinal canal : a report of two cases. *Minim Invasive Neurosurg* 48 : 240-243, 2005
- Jeong GK, Bendo JA : Lumbar intervertebral disc cyst as a cause of radiculopathy. *Spine J* 3 : 242-246, 2003
- Kambin P, Cohen LF, Brooks M, Schaffer JL : Development of degenerative spondylosis of the lumbar spine after partial discectomy. Comparison of laminotomy, discectomy, and posterolateral discectomy. *Spine (Phila Pa 1976)* 20 : 599-607, 1995
- Kim JS, Choi G, Lee CD, Lee SH : Removal of discal cyst using percutaneous working channel endoscope via transforaminal route. *Eur Spine J* 18 Suppl 2 : S201-S205, 2009
- Koga H, Yone K, Yamamoto T, Komiya S : Percutaneous CT-guided puncture and steroid injection for the treatment of lumbar discal cyst: a case report. *Spine (Phila Pa 1976)* 28 : E212-E216, 2003
- Kono K, Nakamura H, Inoue Y, Okamura T, Shakudo M, Yamada R : Intraspinial extradural cysts communicating with adjacent herniated disks: imaging characteristics and possible pathogenesis. *AJNR Am J Neuroradiol* 20 : 1373-1377, 1999
- Lee HK, Lee DH, Choi CG, Kim SJ, Suh DC, Kahng SK, et al. : Discal cyst of the lumbar spine: MR imaging features. *Clin Imaging* 30 : 326-330, 2006
- Lim G, Kim HS, Kim SW, Shin H : Discal cyst diagnosed by radiologic finding. *J Korean Neurosurg Soc* 41 : 418-420, 2007
- Mayer HM, Brock M : Percutaneous endoscopic discectomy : surgical technique and preliminary results compared to microsurgical discectomy. *J Neurosurg* 78 : 216-225, 1993
- Mizutamari M, Sei A, Fujimoto T, Taniwaki T, Mizuta H : L5 radiculopathy caused by a ganglion cyst of the posterior longitudinal ligament in a teenager. *Spine J* 9 : e11-e14, 2009
- Murata K, Ikenaga M, Tanaka C, Kanoe H, Okuaaira S : Discal cysts of the lumbar spine: a case report. *J Orthop Surg (Hong Kong)* 15 : 376-379, 2007
- Nabeta M, Yoshimoto H, Sato S, Hyakumachi T, Yanagibashi Y, Masuda T : Discal cysts of the lumbar spine. Report of five cases. *J Neurosurg Spine* 6 : 85-89, 2007
- Ogawa Y, Kumano K, Hirabayashi S, Aota Y : A ganglion cyst in the lumbar spinal canal. A case report. *Spine (Phila Pa 1976)* 17 : 1429-1431, 1992
- Onofrio BM, Mih AD : Synovial cysts of the spine. *Neurosurgery* 22 : 642-647, 1988
- Ozer AF, Oktenoglu T, Sasani M, Bozkus H, Canbulat N, Karaarslan E, et al. : Preserving the ligamentum flavum in lumbar discectomy: a new technique that prevents scar tissue formation in the first 6 months post-surgery. *Neurosurgery* 59 : ONS126-ONS133; discussion ONS126-ONS133, 2006
- Porchet F, Chollet-Bornand A, de Tribolet N : Long-term follow up of patients surgically treated by the far-lateral approach for foraminal and extraforaminal lumbar disc herniations. *J Neurosurg* 90 : 59-66, 1999
- Ross JS, Robertson JT, Frederickson RC, Petrie JL, Obuchowski N, Modic MT, et al. : Association between peridural scar and recurrent radicular pain after lumbar discectomy: magnetic resonance evaluation. ADCON-L European Study Group. *Neurosurgery* 38 : 855-861; discussion 861-863, 1996
- Sakas DE, Farrell MA, Young S, Toland J : Posterior thecal lumbar disc herniation mimicking synovial cyst. *Neuroradiology* 37 : 192-194, 1995
- Sasani M, Ozer AF, Oktenoglu T, Canbulat N, Sarioglu AC : Percutaneous endoscopic discectomy for far lateral lumbar disc herniations : prospective study and outcome of 66 patients. *Minim Invasive Neurosurg* 50 : 91-97, 2007
- Shah RV, Lutz GE : Lumbar intraspinal synovial cysts: conservative management and review of the world's literature. *Spine J* 3 : 479-488, 2003
- Tanaka M, Nakahara S, Ito Y, Nakanishi K, Sugimoto Y, Ikuma H, et al. : Surgical results of sacral perineural (Tarlov) cysts. *Acta Med Okayama* 60 : 65-70, 2006
- Tomecek FJ, Anthony CS, Boxell C, Warren J : Discography interpretation and techniques in the lumbar spine. *Neurosurg Focus* 13 : E13, 2002
- Toyama Y, Kamata N, Matsumoto M, Nishizawa T, Koyanagi T, Suzuki N, et al. : Pathogenesis and diagnostic title of intraspinal cyst communicating with intervertebral disk in the lumbar spine. *Rinsho Seikei Geka*

- 32 : 393-400, 1997
39. Tsou PM, Alan Yeung C, Yeung AT : Posterolateral transforaminal selective endoscopic discectomy and thermal annuloplasty for chronic lumbar discogenic pain : a minimal access visualized intradiscal surgical procedure. *Spine J* 4 : 564-573, 2004
40. Tsou PM, Yeung AT : Transforaminal endoscopic decompression for radiculopathy secondary to intracanal noncontained lumbar disc herniations: outcome and technique. *Spine J* 2 : 41-48, 2002
41. Vasani SS, Demetriades AK, Joshi SM, Yeh J, Ellamushi H : Traumatic intraspinal extradural ganglion cyst in a teenager : case report and review of the literature. *Clin Neurol Neurosurg* 109 : 88-91, 2007
42. Voyadzis JM, Bhargava P, Henderson FC : Tarlov cysts : a study of 10 cases with review of the literature. *J Neurosurg* 95 : 25-32, 2001
43. Watanabe N, Ogura T, Kimori K, Hase H, Hirasawa Y : Epidural hematoma of the lumbar spine, simulating extruded lumbar disk herniation : clinical, discographic, and enhanced magnetic resonance imaging features. A case report. *Spine (Phila Pa 1976)* 22 : 105-109, 1997
44. Wu X, Zhuang S, Mao Z, Chen H : Microendoscopic discectomy for lumbar disc herniation : surgical technique and outcome in 873 consecutive cases. *Spine (Phila Pa 1976)* 31 : 2689-2694, 2006
45. Young PM, Fenton DS, Czervionke LF : Postoperative annular pseudocyst : report of two cases with an unusual complication after microdiscectomy, and successful treatment by percutaneous aspiration and steroid injection. *Spine J* 9 : e9-e15, 2009