

Contents lists available at [ScienceDirect](#)

## International Journal of Surgery Case Reports

journal homepage: [www.casereports.com](http://www.casereports.com)

# A rare case of spontaneous rupture of an aneurysm of the right gastric artery



Yu-ki Takemoto<sup>a</sup>, Nobuaki Fujikuni<sup>a,\*</sup>, Kazuaki Tanabe<sup>b</sup>, Hironobu Amano<sup>a,b</sup>, Toshio Noriyuki<sup>a,b</sup>, Masahiro Nakahara<sup>a</sup>

<sup>a</sup> Department of Surgery, Onomichi General Hospital, 1-10-23 Hirahara, Onomichi, Hiroshima 722-0018, Japan

<sup>b</sup> Department of Gastroenterological and Transplant Surgery, Applied Life Sciences, Institute of Biomedical and Health Sciences, Hiroshima University, 1-2-3 Kasumi, Minami-ku, Hiroshima, 734-8551, Japan

## ARTICLE INFO

## Article history:

Received 11 July 2017

Received in revised form 28 August 2017

Accepted 28 August 2017

Available online 1 September 2017

## Keywords:

Aneurysm

Ruptured/Hemostasis

Surgical/Emergency Treatment

## ABSTRACT

**BACKGROUND:** Visceral artery aneurysms at the origin of the gastric and gastroepiploic artery are uncommon. Ruptured visceral aneurysms cause high mortality and require urgent and adequate intervention and treatment.

**PRESENTATION OF CASE:** A 65-year-old woman was transferred to the emergency department with sudden abdominal and back pain. Radiographically, we diagnosed intra-abdominal bleeding due to a ruptured aneurysm of the right gastric artery. Although her vital signs were relatively stable, transcatheter arterial embolization (TAE) could not be performed due to thrombotic occlusion of her abdominal aorta, and bilateral axillary arteries. She underwent an emergency laparotomy with ligation of the root of the right gastric artery and resection of the aneurysm, following which she showed good recovery. Histologically, the right gastric artery showed atherosclerosis with an organizing mural thrombus.

**DISCUSSION:** Ruptured visceral aneurysms cause high mortality; therefore, rapid and adequate treatment is necessary. Achieving adequate transcatheter access might be difficult in some cases. In our case, we performed an emergency laparotomy and had good recovery.

**CONCLUSION:** We report and discuss the literature review for a rare case of intra-abdominal bleeding from a ruptured aneurysm of the right gastric artery which was difficult to be approached by TAE. In patients with unstable vital signs or in whom it is not possible to obtain a good laparoscopic view and clear operative field, we should not hesitate to convert the procedure into an open one, and perform an emergency laparotomy.

© 2017 The Authors. Published by Elsevier Ltd on behalf of IJS Publishing Group Ltd. This is an open access article under the CC BY-NC-ND license (<http://creativecommons.org/licenses/by-nc-nd/4.0/>).

## 1. Background

This work has been reported in line with the SCARE criteria [18].

While visceral artery aneurysms are rare, and usually associated with the splenic and hepatic artery, gastric and gastroepiploic artery aneurysms are uncommon [1–4]. Feo et al visceral aneurysms are sometimes associated with congenital vascular anomalies [5]. Ruptured visceral artery aneurysms are associated with a high mortality rate [4,6,7]. Thus, urgent and adequate treatment is essential. Some recent reports have discussed the feasibility of transcatheter arterial embolization (TAE) for visceral artery aneurysms not only as prophylactic treatment but also in emergency situations [1,3,8,9]. However, it was difficult to approach the aneurysm using the TAE method in our patient. We report a case and discuss literature review in a patient with spontaneous bleed-

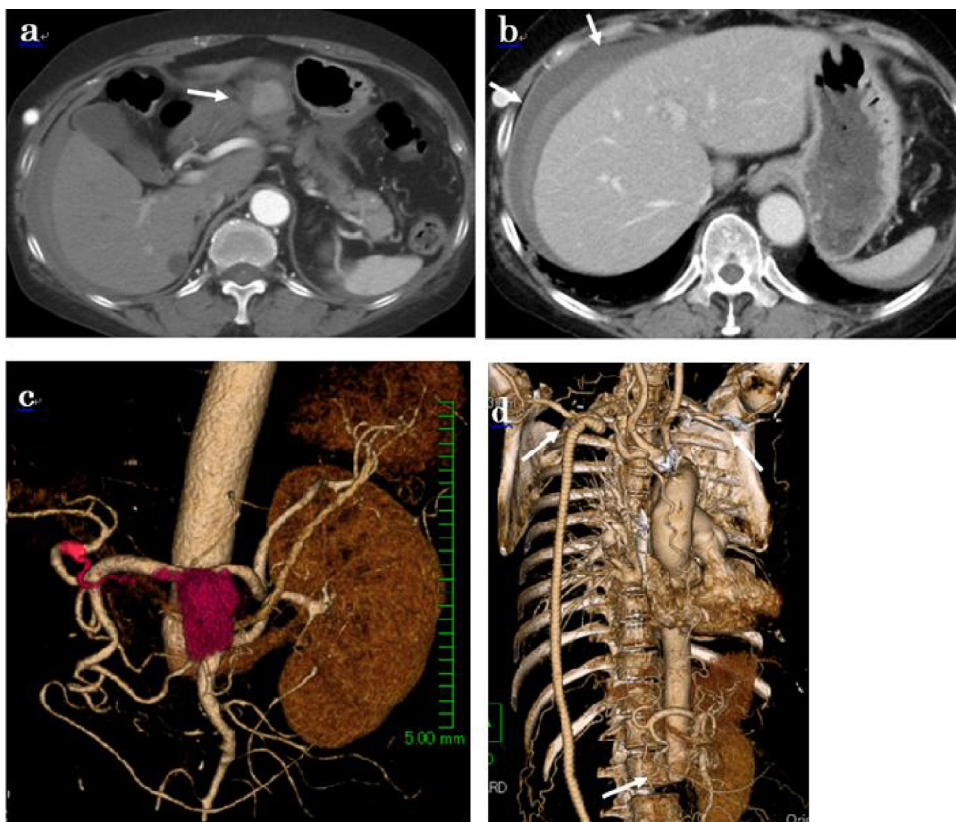
ing due to a ruptured aneurysm of the right gastric artery (RGA), which we treated by performing an urgent laparotomy.

## 2. Case presentation

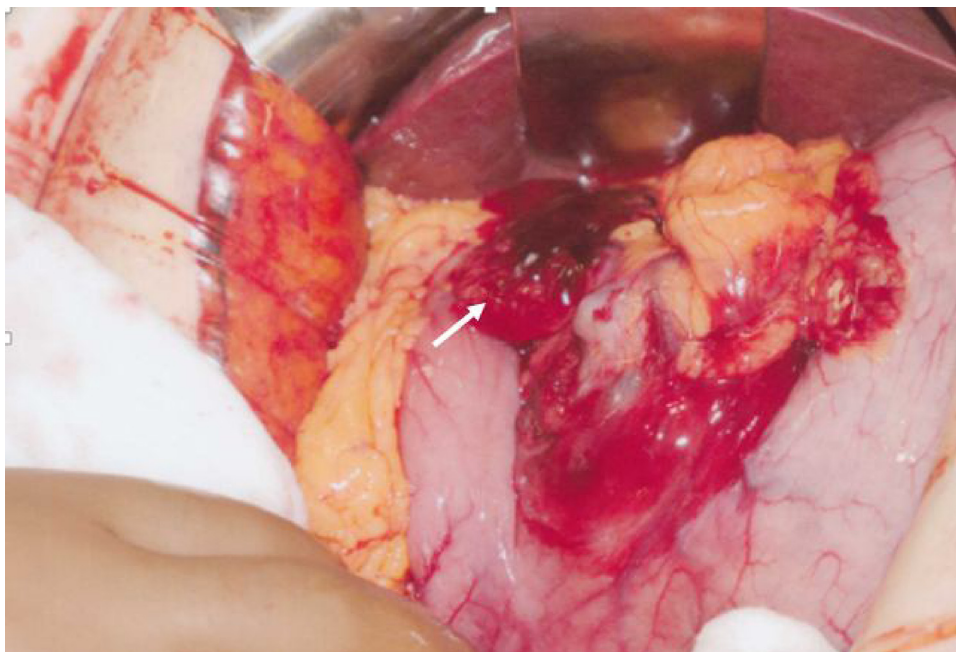
A 65-year-old woman was transferred to the emergency department with onset of sudden abdominal and back pain, and a short syncopal spell. When she presented to our hospital, about 30 minutes have passed from the onset of the symptoms, she did not have altered sensorium, vital signs showed a blood pressure of 175/102 mmHg, pulse rate of 106 beats/min, body temperature of 36.6 °C, and a respiratory rate of 22 breaths/min. She was known to have history of stenosis of the abdominal aorta at multiple locations and femoral artery aneurysm, for which she had undergone axillofemoral bypass (right axillary artery-left superficial femoral artery) and a femorofemoral bypass. These extra-anatomic bypasses were adopted in spite of their poor patency rate over time. It seems that an aorto-bifemoral bypass was an adequate option, however, the vascular surgeons concluded that a length of intact

\* Corresponding author.

E-mail address: [fujikuni2292@gmail.com](mailto:fujikuni2292@gmail.com) (N. Fujikuni).



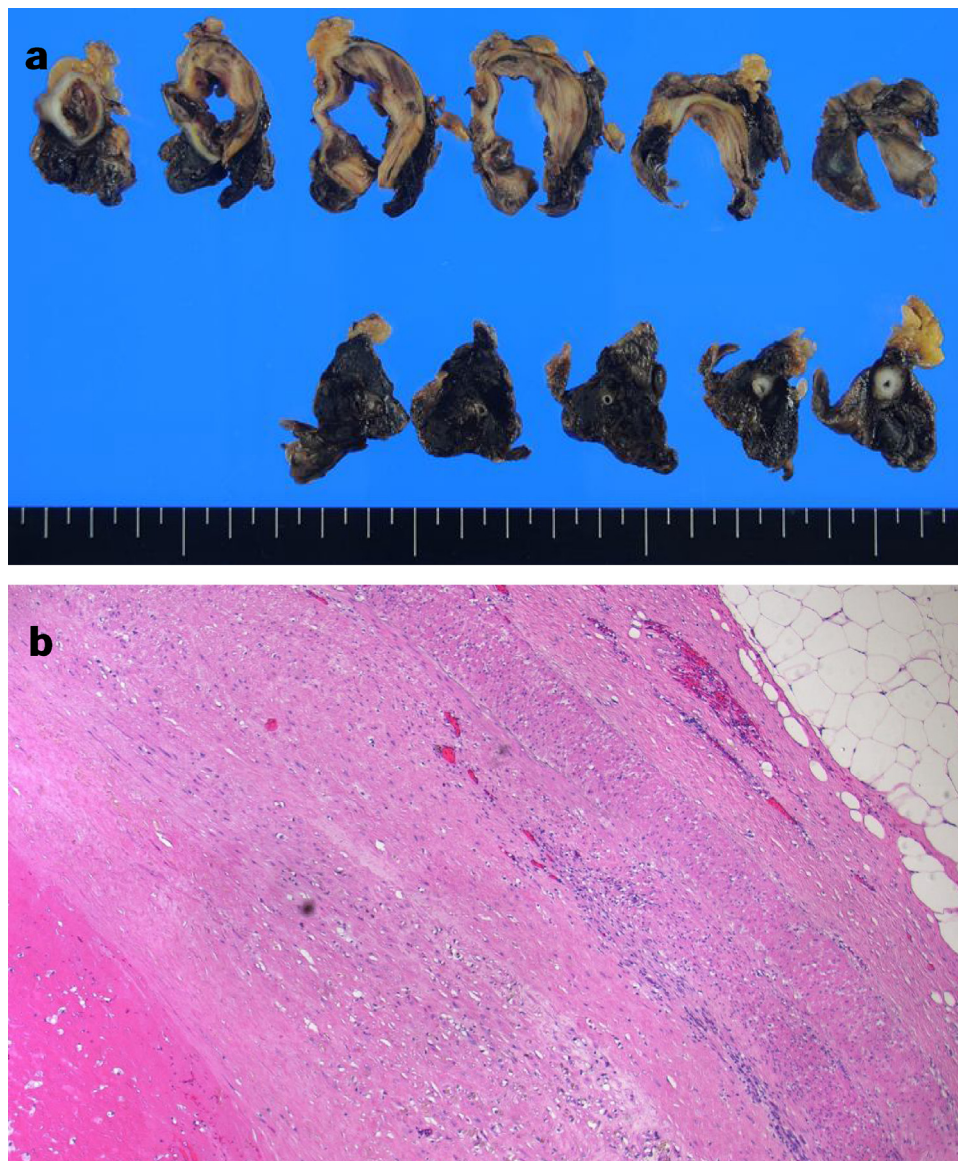
**Fig. 1.** An Abdominal computed tomography (CT) indicates the presence of a mass on the lesser curvature (white arrow). b: A liver surface surrounded by high-density ascites (white arrow). c: Angiography images reconstructed from CT showing a RGA aneurysm measuring 35 mm in diameter (white arrow). d: Thrombotic occlusion of the aorta at the level of the renal artery, and obstruction of both, right and left axillary arteries (white arrow). Right kidney was not described because of the chronically obstruction of the right renal artery.



**Fig. 2.** Seen in this image are hemorrhagic ascites and blood clot, as well as a 35 mm aneurysm on the peripheral side of the RGA along with a hematoma in the lesser omentum.

aortic wall beneath the renal arteries was too short to suture a vascular graft. She had been administered warfarin 2.25 mg, and cilostazol. Her blood tests revealed decreased hemoglobin levels (8.9 mg/dL), a prolonged prothrombin time (20%), and elevation of

white blood cells (19,840/ $\mu$ L). She was immediately given Vitamin K antagonists in order to reduce amount of bleeding. An abdominal contrast enhanced computed tomography (CT) scan indicated a nodule on the lesser curvature that showed enhancement in



**Fig. 3.** The vessel wall showing atherosclerosis with an organizing mural thrombus, but no findings of arteritis (a: macroscopic examination, b: H.E. staining, X100).

the early phase, as well as, a liver surface surrounded by high-density ascites (Fig. 1a,b). Angiography findings reconstructed from CT demonstrated a RGA aneurysm measuring 35 mm in diameter, which was diagnosed to be the cause of her intra-abdominal bleeding (Fig. 1c). Her vital signs were relatively stable, we consulted with the interventional radiologists about the indication of TAE, however, known thrombotic occlusion of her abdominal aorta at the level of the renal arteries, and bilateral axillary arterial obstruction and thrombosis ruled out the possibility of adopting an endovascular approach (Fig. 1d). We performed an emergency laparotomy that revealed hemorrhagic ascites and blood clot and a 35 mm aneurysm on the peripheral side of the right gastric artery, as well as a hematoma in the lesser omentum (Fig. 2). There was no active bleeding, or ischemic changes of the stomach wall. We ligated the root of the right gastric artery and resected the aneurysm. There were no postoperative complications, and she was discharged 12 days after surgery.

Histologically, the right gastric artery showed atherosclerosis with an organizing mural thrombus, but there were no findings of arteritis (Fig. 3).

### 3. Discussion

Visceral artery aneurysms are rare. Stanley et al., have reported that among 1118 cases, gastric and gastropiploic artery aneurysms constituted only 53 cases (4.7%) while other arteries were involved as follows: splenic artery-656 cases (58.7%), hepatic artery-227 cases (20.3%), and superior mesenteric artery-89 cases (8.0%) [2]. Some previous reports have shown similar results [1,3,4]. With regard to gastric and gastropiploic artery aneurysms, the left gastric artery (LGA) origin is the site of involvement in a majority of cases. Aneurysms occurring at the origin of the RGA have been reported in very few cases [4,10–15] (Table 1). In our patient, we detected an aneurysm at the origin of the RGA using angiography images reconstructed from a CT scan. Enhanced CT is useful to identify the location, to check if it is actively bleeding, and if so, to proceed with emergency intervention to control bleeding.

It is known that visceral artery aneurysms are associated with arteriosclerosis, aortic dissection, infection, inflammation (pancreatitis, cholecystitis, cholangitis, among others), trauma, iatrogenic causes, collagen vascular disease, and segmental arterial medioly-

**Table 1**  
Reported cases of ruptured RGA aneurysms.

Year	First author	Country	Age	Sex	Shock vitals	Treatment	Outcome
1956	Burkitt	UK	59	M	(+)	OS	alive
1978	Sawada	Japan	NA	NA	NA	NA	NA
1984	Adovasio	Italy	NA	NA	NA	NA	NA
1989	Hosaka	Japan	39	M	NA	TAE	alive
2001	Carr	USA	NA	NA	NA	OS	NA
2013	Choi	Korea	49	M	(+)	TAE → OS	died
2016	Toyoda	Japan	72	M	(+)	LS	alive
2017	Our case	Japan	65	F	(–)	OS	alive

Abbreviations: F: female; LS: laparoscopic surgery; M: male; NA: not available; OS: open surgery, TAE: transcatheter arterial embolization.

sis, among other etiologies [2]. Our patient showed atherosclerotic vessel walls with an organizing mural thrombus that was excised. She had many history of aortic stenosis and pseudoaneurysms, and had undergone aortic bypass surgery, which suggested an association with arteritis—a collagen vascular disease. However, there were no findings of arteritis noted histologically.

Recently, with advancements in radiographic techniques, for example CT, stable visceral artery aneurysms can be detected in asymptomatic patients. These aneurysms are prone to rupture; thus, immediate prophylactic resection is recommended owing to high mortality rates, if and when they rupture. Reportedly, mortality rates associated with ruptured aneurysms are 13–25% [4,6,7]. TAE and laparoscopic aneurysmal resection, by virtue of being less invasive are widely accepted treatment options for stable visceral aneurysms [1,3]. However, management of ruptured visceral aneurysms might be difficult using these techniques, although some studies have reported successful TAE for cases of ruptured visceral aneurysms [15–17]. TAE is becoming increasingly popular for management of emergency intra-abdominal bleeding, traumatic visceral organ injury, ruptured aneurysms, diverticular or ulcer bleeding among other such conditions. In a patient with stable vital signs, TAE is a safe and suitable option. If complete and adequate hemostasis cannot be achieved, embolization to control bleeding helps stabilize a patient hemodynamically, and acts as ‘bridging therapy’ to second radical treatments. TAE is suitable not only for stable aneurysms, but also in ruptured ones; however, the procedure in such cases needs to be cautiously adapted based on the condition in which it is used. Selectively approaching an aneurysm is difficult in some cases, and in cases of rupture, any delay in embolization increases the risk of fatal hemorrhagic shock. In our patient, because her vital signs were stable, we considered TAE as first-line therapy. We could not use an endovascular approach secondary to thrombotic occlusion of the abdominal aorta at the level of the renal artery, and bilateral axillary arteries. We therefore performed an emergency laparotomy with ligation of the RGA and resection of the aneurysm. Toyoda et al., have reported a case of ruptured visceral aneurysm successfully treated via a laparoscopic approach [15]. We recommend that in hemodynamically unstable patients with uncontrolled continuous bleeding, laparoscopic surgery must be avoided because if the surgical field during the laparoscopic procedure is not clear owing to profuse bleeding, an unacceptable delay in establishing hemostasis could be fatal. If active bleeding from the aneurysm is controlled, and a good laparoscopic view is possible, minimally invasive aneurysmal resection can be performed. In our case, patient’s vital signs were stable, we could have chosen the laparoscopic approach.

#### 4. Conclusions

We reported a case of ruptured aneurysm of the RGA, it was difficult to adopt an endovascular approach. In patients with unstable vital signs or in whom it is not possible to obtain a good laparo-

scopic view and clear operative field, we should not hesitate to convert the procedure into an open one, and perform an emergency laparotomy.

#### Conflicts of interest

None of the authors have any commercial or financial involvement in connection with this study that represents or appears to represent any conflicts of interest.

#### Funding

This research received no specific grant from any funding agency in the public, commercial, or not-for-profit sectors.

#### Ethical approval

Onomichi general hospital.

#### Consent

Written informed consent was obtained from the patient for publication of this case report and any accompanying images.

#### Author contribution

All authors mentioned in this manuscript have contributed to the interpretation of data, and drafting, and writing of this manuscript. Yu-ki Takemoto is the first author of this paper. Nobuaki Fujikuni is the corresponding author. Yu-ki Takemoto, and Nobuaki Fujikuni conceived and designed the study and drafted the manuscript. Nobuaki Fujikuni first diagnosed this condition in the patient. Yu-ki Takemoto, Nobuaki Fujikuni, Hironobu Amano, Masahiro Nakahara, and Toshio Noriyuki were engaged in the patient’s care in our hospital including surgery. Kazuaki Tanabe contributed to the concept of our study, review of the final manuscript, and submission of the paper. All coauthors read and approved the final manuscript.

#### Registration of research studies

The manuscript does not report the result of an experimental investigation or research on human subjects.

#### Guarantor

Nobuaki Fujikuni.  
E-mail: fujikuni2292@gmail.com.

#### References

- [1] E.M. Marone, et al., Is open repair still the gold standard in visceral artery aneurysm management? *Ann. Vasc. Surg.* 25 (7) (2011) 936–946.
- [2] J.C. Stanley, N.W. Thompson, W.J. Fry, Splanchnic artery aneurysms, *Arch. Surg.* 101 (6) (1970) 689–697.
- [3] N. Tulsyan, et al., The endovascular management of visceral artery aneurysms and pseudoaneurysms, *J. Vasc. Surg.* 45 (2) (2007) 276–283.
- [4] S.C. Carr, D.M. Mahvi, J.R. Hoch, C.W. Archer, W.D. Turnipseed, Visceral artery aneurysm rupture, *J. Vasc. Surg.* 33 (4) (2001) 806–811.
- [5] C.F. Feo, A.M. Fancellu, S. Constantino, Visceral aneurysm anomaly involving the splenic artery, *Dig Dis Sci* 49 (9) 1378–1380.
- [6] G.B. Zelenock, J.C. Stanley, Splanchnic artery aneurysms, in: *Vascular Surgery*, 5th ed., Rutherford RB, 2000, pp. 1369–1382.
- [7] A.J. Shukla, et al., Contemporary outcomes of intact and ruptured visceral artery aneurysms, *J. Vasc. Surg.* 61 (6) (2015) 1442–1447.
- [8] A.M. Belli, G. Markose, R. Morgan, The role of interventional radiology in the management of abdominal visceral artery aneurysms, *Cardiovasc. Intervent. Radiol.* 35 (2) (2012) 234–243.
- [9] A.C. Cordova, B.E. Sumpio, Visceral Artery Aneurysms - Should They All be Managed by Endovascular Techniques? *Ann. Vasc. Dis.* 6 (4) (2013) 687–693.

- [10] R. Adovasio, F. Gabrielli, F. Pancrazio, G. Siliotto, Double aneurysm of the common hepatic artery and of the right gastric artery, *Chir. Ital.* 36 (3) (1984) 412–421.
- [11] R. Burkitt, Abdominal apoplexy due to spontaneous rupture of right gastric artery, *Br. Med. J.* 1 (4960) (1956) 214.
- [12] S. Choi, et al., Acute abdominal pain due to spontaneous rupture of the right gastric artery, *Am. J. Emerg. Med.* 32 (5) (2014) 21.
- [13] J. Hosaka, et al., Rupture of right gastric artery aneurysm—a case report and the usefulness of TAE, *Rinsho Hoshasen* 34 (5) (1989) 621–624.
- [14] S. Sawada, M. Uchimura, Y. Muto, T. Murohisa, A. Kobayashi, Preoperative angiographic diagnosis of aneurysm of the right gastric artery (author's transl), *Rinsho Hoshasen* 23 (6) (1978) 673–677.
- [15] Y. Toyoda, et al., Laparoscopic surgery for the treatment of a ruptured aneurysm of the right gastric artery: a case report, *Asian J. Endosc. Surg.* (September (5)) (2016), <http://dx.doi.org/10.1111/ases.12323>.
- [16] R. Moll, S. Debus, S. Franke, G. Schindler, Pseudoaneurysm of the right gastric artery, *Vasa* 31 (3) (2002) 205–208.
- [17] Y. Nishikawa, et al., Acute remodeling of an adjoining aneurysm after endovascular treatment of a ruptured splanchnic arterial aneurysm: a case of clinically diagnosed segmental arterial mediolysis, *Ann. Vasc. Diseases* 5 (4) (2012) 449–453.
- [18] R.A. Agha, A.J. Fowler, A. Saeta, I. Barai, S. Rajmohan, D.P. Orgill, The SCARE Statement: consensus-based surgical case report guidelines, *Int. J. Surg.* (2016).

#### Open Access

This article is published Open Access at [sciedirect.com](http://sciedirect.com). It is distributed under the [IJSCR Supplemental terms and conditions](#), which permits unrestricted non commercial use, distribution, and reproduction in any medium, provided the original authors and source are credited.