



# Utility of positron emission tomography myocardial perfusion imaging for identifying ischemia and guiding treatment in patients with anomalous coronary arteries

Tom Kai Ming Wang, MBChB, MD,<sup>a</sup> Tiffany Dong, MD,<sup>a</sup> Paul C. Cremer, MD,<sup>a</sup> Hani Najm, MD,<sup>b</sup> Gosta Pettersson, MD, PhD,<sup>b</sup> and Wael A. Jaber, MD, FACC, FESC<sup>a,c</sup>

<sup>a</sup> Section of Cardiovascular Imaging, Heart, Vascular and Thoracic Institute, Cleveland Clinic, Cleveland, OH

<sup>b</sup> Department of Thoracic and Cardiovascular Surgery, Heart, Vascular and Thoracic Institute, Cleveland Clinic, Cleveland, OH

<sup>c</sup> Section of Cardiovascular Imaging, Robert and Suzanne Tomsich Department of Cardiovascular Medicine, Sydell and Arnold Miller Family Heart and Vascular Institute, Cleveland Clinic, Cleveland, OH

Received May 15, 2022; accepted Jul 6, 2022

doi:10.1007/s12350-022-03071-9

**Background.** The assessment of anomalous coronary arteries (AAOCA) remains controversial without an optimal stress modality for ischemia. We evaluated the value of PET-CT myocardial perfusion imaging in these patients and subsequent management.

**Methods and results.** AAOCA patients (n = 82) undergoing PET-CT from 2015 to 2021 were retrospectively chart reviewed. Multivariable analyses performed to assess relevant clinical and imaging factors associated with ischemia on PET and AAOCA surgery.

Key characteristics include mean age  $45 \pm 20$  years, 30 (37%) female, 45 (55%) with chest pain, 19 (23%) anomalous left main coronary artery, 58 (71%) anomalous right coronary artery, 26 (32%) with objective ischemia on PET-CT, and 37 (45%) who underwent AAOCA surgery. Adverse outcomes over mean follow-up of  $2.2 \pm 1.8$  years included one death and two myocardial infarctions. Anomalous left main was independently associated with ischemia on PET-CT, odds ratio (95% confidence intervals) 4.15 (1.31–13.1),  $P = .006$ . Chest pain and ischemia on PET-CT were independently associated with and provided incremental prognostic value for surgery, odds ratio 9.73 (2.78–34.0),  $P < .001$  and 6.79 (1.99–23.2),  $P = .002$ , respectively.

Tom Kai Ming Wang and Tiffany Dong are co-primary authors contributing equally to the manuscript.

**Supplementary Information** The online version contains supplementary material available at <https://doi.org/10.1007/s12350-022-03071-9>.

The authors of this article have provided a PowerPoint file, available for download at SpringerLink, which summarizes the contents of the paper and is free for re-use at meetings and presentations. Search for the article DOI on SpringerLink.com.

The authors have also provided an audio summary of the article, which is available to download as ESM, or to listen to via the JNC/ASNC Podcast.

Reprint requests: Wael A. Jaber, MD, FACC, FESC, Section of Cardiovascular Imaging, Robert and Suzanne Tomsich Department of Cardiovascular Medicine, Sydell and Arnold Miller Family Heart and Vascular Institute, Cleveland Clinic, Main Campus J1-5, 9500 Euclid Avenue, Cleveland, OH 44195; [jaberw@ccf.org](mailto:jaberw@ccf.org)

J Nucl Cardiol  
1071-3581/\$34.00

Copyright © 2022 The Author(s) under exclusive licence to American Society of Nuclear Cardiology

**Conclusion.** Ischemia on PET-CT occurred in a third of our cohort, identifying patients who may benefit from surgery. Larger studies are needed to evaluate the interplay between AAOCA, ischemia by PET and surgery. (J Nucl Cardiol 2022)

**Key Words:** Anomalous coronary arteries • positron emission tomography (PET) • nuclear imaging • stress test • ischemia • revascularization

#### Abbreviations

AAOCA	Anomalous coronary arteries
CCTA	Coronary computed tomography angiography
CMR	Cardiac magnetic resonance
FFR	Fractional flow reserve
PET-CT	Positron emission tomography with computed tomography
SPECT	Single photon emission computed tomography

## INTRODUCTION

Anomalous aortic origin of coronary arteries (AAOCA) is a congenital anomaly whereby a coronary artery originates aberrantly, such as from an opposite sinus, above the sinuses of Valsalva or from the pulmonary artery, with prevalence of 0.5% to 1%.<sup>1,2</sup> Although often incidentally found, AAOCA is one of the leading causes of sudden cardiac death in younger patients especially athletes.<sup>3,4</sup> Guidelines recommend anatomical and ischemia evaluation for AAOCA to decide on surgery management.<sup>5-7</sup> However, the optimal stress testing modality remains controversial with potential options including stress electrocardiogram, stress echocardiography, cardiac magnetic resonance (CMR) stress perfusion, nuclear stress testing (such as photon emission computed tomography (SPECT) and positron emission tomography with computed tomography (PET-CT)), and catheterization with fractional flow reserve (FFR).<sup>8</sup> The feasibility of exercise N13-ammonia PET-CT for ischemia evaluation with anomalous right coronary arteries was previously described.<sup>9</sup> This study aims to evaluate the interplay between clinical presentation, anatomy, presence of ischemia on PET-CT, management and outcomes in AAOCA.

## METHODS

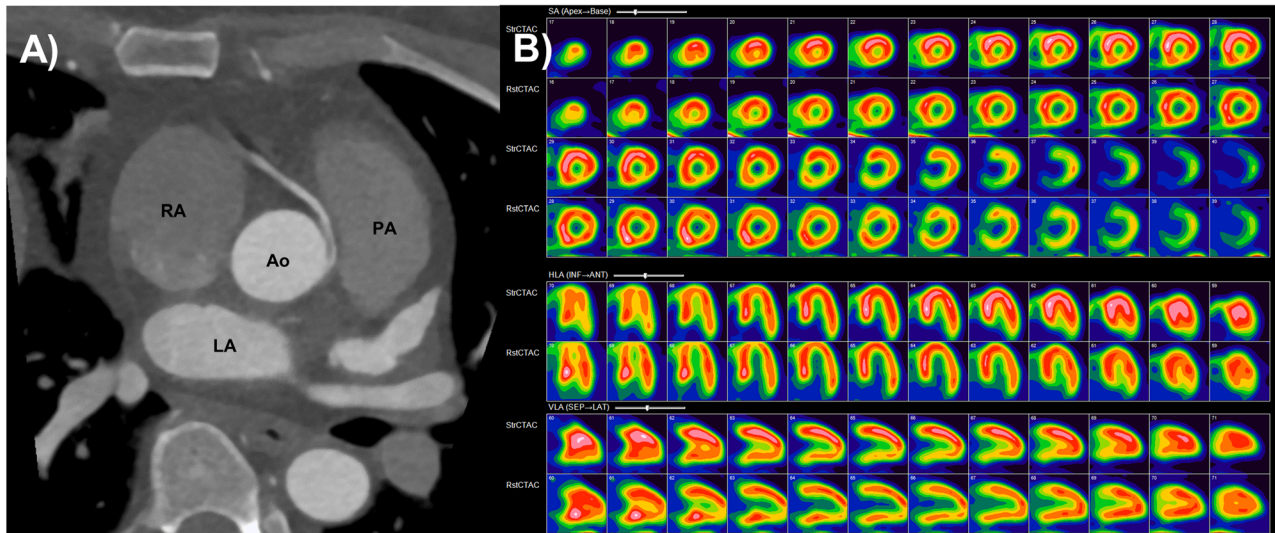
### Study population and clinical data

The retrospective cohort study was approved by our Institution's Review Board with informed consent waived. Consecutive AAOCA patients undergoing cardiac PET-CT stress (either rubidium-82 or nitrogen-13-ammonia as radio-isotope) at our institution during

January 2015 to June 2021 were studied. Referral for PET-CT was at the discretion of the managing cardiologist. Exclusion criteria included low-risk anatomy such as anomalous circumflex with retroaortic course (n = 2) or prior coronary surgery (n = 3). Clinical data obtained include demographics, symptoms on presentation and past medical history (including relevant co-morbidities), laboratory tests and medications.

### Cardiac stress test with PET

PET studies were acquired using a hybrid PET-CT scanner (Siemens Biograph 40, Munich, Germany) with lutetium oxyorthosilicate crystals in a three-dimensional (3D) mode without septa (Figure 1). The nominal transaxial/axial spatial resolutions were 4.4 mm/4.7 mm. The two radio-isotope tracers used were nitrogen-13-ammonia and rubidium-82, for the exercise and dobutamine stress modalities, respectively. Exercise stress testing involved reaching maximal exertion within 8 to 12 minute rather than using heart rate targets. After a low dose injection of N<sup>13</sup>-ammonia (6 to 8 mCi), images were acquired at rest. A minute after peak exercise the patient was injected with a high dose of N<sup>13</sup>-ammonia (12 to 18 mCi) and gated imaging was performed. Gated stress imaging was performed 30 to 40 minutes after the rest images. For dobutamine stress testing, rubidium-82 (25 to 30 mCi) was injected and rest images were obtained. Dobutamine was administered at increments of 10 mcg·kg<sup>-1</sup>·min<sup>-1</sup> every 3 minutes until a total of 40 mcg·kg<sup>-1</sup>·min<sup>-1</sup> regardless of if maximal heart rate was reached, and then another injection of rubidium-82 (25 to 30 mCi) was administered. Immediately after, images were obtained in list mode acquisition with static, dynamic, and gated data collected simultaneously. For attenuation correction, a low dose CT protocol (120 kVp, 12 mAs, 0.3 mSv dose per scan) was performed while patients were holding their breath at end expiration. Static and gated images were then reconstructed using 3D ordered subset expectation maximization algorithm (4 iterations, 8 subsets, 8 mm Gaussian filter for static and 2 iterations, 8 subsets, 12 mm Gaussian filter for gated). PET-CT were reoriented based on standard cardiac axes and displayed with INVIA Corridor 4DM software (Ann Arbor, Michigan, USA). Based off the respective images, summed rest, stress and difference scores were calculated on a 17 segment model of the left ventricle. The



**Figure 1.** Anomalous coronary artery case **A** CT coronary angiography showing anomalous right coronary artery (RCA) arising from the left sinus with slit-like origin and interarterial course (*Ao*, aorta; *PA*, pulmonary artery; *RA*, right atrium, *LA*, left atrium), and **B** exercise ammonia PET-CT showing normal rest perfusion and hypoperfusion of the inferior wall on stress, suggesting RCA territory ischemia.

percentage of ischemic myocardium was calculated by dividing SDS by 68 with low risk < 5% of myocardium, intermediate risk 5 to 10% of myocardium or high risk as > 10% of the myocardium.<sup>10</sup> Cases were divided between presence and absence of ischemia regardless of percentage. Myocardial blood flows were not analyzed, as this software was only available in the last 2 years, and is not feasible with exercise PET.

### Cardiac anatomy and function imaging

AAOCA anatomic evaluation was mostly reported from coronary computed tomography angiography (CCTA), catheterization, and less commonly from CMR angiography and TTE. CCTA was performed using the Siemens Somatom Force dual source ( $2 \times 192$  slice) scanner, at 70 to 120 kilovolts based on patient size, using either prospective (at mid-diastole) or retrospective ECG gating, thin 0.75 mm slice thickness for spatial resolution, and Omnipaque (iodinated-based) contrast administration with scan timed to optimize aortic and coronary artery enhancement (Figure 1). Patients were premedicated with sublingual nitroglycerin, and intravenous metoprolol for high heart rates. CMR was performed using the Philips Achieva (1.5 Tesla) or Ingenia (3.0 Tesla) scanners, either with Dotarem (gadolinium-based) contrast-enhanced magnetic resonance angiography, or non-contrast three-

dimensional whole- sequence. TTE was performed using the Philips EPIQ or GE Vivid7 or Vivid9 scanners.

### Management and outcomes

Cardiovascular medication use prior to and changes after PET-CT were extracted. Decision to undergo surgical AAOCA intervention and type of surgery were recorded. Follow-up was defined from the date of PET-CT until either death or date of last clinical contact. Outcomes collected include death, cardiovascular death, and all cardiovascular hospitalizations (including recurrent chest pain, myocardial infarction, stroke, heart failure, arrhythmia), and chest pain status.

### Statistical analysis

Univariable analyses were performed using student *T* test for continuous variables and Fisher's exact tests for categorical variables between those with and without PET-CT ischemia. Multivariable analyses were performed using logistic regression for ischemia on PET-CT using pre-specified covariates of age, anomalous left main and chest pain; and for AAOCA surgery using pre-specified covariates of age, chest pain, anomalous left main, and PET ischemia positive, and for this model stepwise incremental predictive value was tested with chi-squared and P values reported. All tests were two-

tailed with 5% significance level, and performed using SPSS (version 24, IBM, Chicago, Illinois) and Prism (version 8, GraphPad, San Diego, California) software.

## RESULTS

Table 1 displays the cohort characteristics of 82 AAOCA patients. Mean age was  $45 \pm 20$  years with 15 (18%) < 18 years old, 30 (37%) were female, 45 (55%) had chest pain and only 2 (2%) with prior cardiac arrest. CCTA and coronary catheterization were performed in 74 (90%) and 80 (98%), respectively. The anomalous vessel was the left main in 19 (29%), left anterior descending only in 3 (13%), and both the left anterior descending and the left circumflex in 2 (8%); and the right coronary artery in 58 (71%). PET-CT was performed using nitrogen 13-ammonia tracer in 54 (66%) and rubidium-82 tracer in 28 (34%). Ischemia was present on PET-CT in 26 patients (32%), including 36% of those with and 27% of those without chest pain ( $P = .479$ ).

Cohort management and outcomes are shown in Table 2. Surgery was performed in 37 (45%) patients, at median (interquartile range) of 1.3 (0.3 to 2.3) months after PET-CT. Surgical techniques were coronary unroofing in 29 (78%), coronary artery bypass grafting in 6 (17%) and coronary reimplantation in 2 (6%). Over mean follow-up of  $2.2 \pm 1.8$  years, there was 1 (1%) all-cause and cardiovascular death, with patient admitted with left ventricular apical aneurysm with thrombus, ventricular tachycardia and subsequently inferior ST elevation myocardial infarction and cardiac arrest. There were 2 (2%) with myocardial infarction including the death, and another patient with type 2 myocardial infarction in setting of COVID-19 infection. Chest pain was present in 21 (26%) patients at follow-up.

Results from multivariable analyses are summarized in Figure 2. Anomalous left main was the only factor independently associated with ischemia on PET-CT test with odds ratios (95% confidence intervals) of 4.15 (1.31 to 13.1),  $P = .016$ . Factors independently associated with undergoing AAOCA surgery include chest pain 9.73 (2.78–34.0),  $P < .001$ , and ischemia on PET-CT 6.79 (1.99 to 23.2),  $P = .002$ . Both factors had significant incremental value for predicting AAOCA surgery (both  $P < .001$ ) in stepwise multivariable model, while other factors did not (Figure 3). Patients with both chest pain and ischemia on PET-CT had the highest chance of having surgery, adjusted odds ratio 66.1 (8.46 to 517),  $P < .001$ .

## DISCUSSION

While guidelines recommend ischemic evaluation for AAOCA, this is based on expert opinion and the optimal ischemic assessment has yet to be established.

This cohort there are several important findings; 1. One third of AAOCA that are not low-risk anatomically have ischemia on PET-CT; 2. Ischemia on PET-CT is four times more likely in anomalous left main; 3 Chest pain or ischemia on PET-CT appear to drive referral to surgery, however, they were not significantly associated with each other. Patients with both chest pain and ischemia had the highest likelihood of undergoing surgery. 4. Contemporary short-term outcomes of AAOCA patients are excellent, including those undergoing surgery.

Anatomy assessment is the first step, and ECG-gated CCTA preferred due to superior spatial resolution and sensitivity over catheterization, CMR angiography and echocardiography.<sup>7,11</sup> Specific high risk anatomical features include anomalous left main or left anterior descending artery, interarterial course with intramural component, slit-like ostium or proximal narrowing and acute angle take off < 45° from the aorta.<sup>2</sup> The next step is ischemia evaluation, however, the optimal modality remains controversial with a paucity of comparative studies.<sup>5,6,8</sup> As ischemia in AAOCA is thought to be from dynamic compression or from enhanced systolic expansion leading to intermittent occlusion, we believe stress modalities that increase contractility such as exercise treadmill or bike, or dobutamine to work best, as opposed to vasodilators.<sup>5</sup> PET-CT has superior spatial resolution and less susceptibility artifact than SPECT, and has higher sensitivity and specificity for coronary heart disease and need for revascularization.<sup>12</sup> PET-CT allows for peak stress imaging especially when using dobutamine or supine bike and thus affords AAOCA patients an opportunity to allow perfusion and left ventricular function imaging at peak coronary compression. This study is one of very few and the largest using PET-CT evaluation of ischemia in AAOCA, demonstrating the utility of PET-CT by exercise and dobutamine stressors, ammonia and rubidium-82 radiotracers to influence decision-making for surgery. Notably, we found ischemia on PET-CT to be associated anomalous left main artery, suggesting that this may be an especially high risk group. Importantly, ischemia on PET-CT was not associated with chest pain, and therefore has additional value in asymptomatic patients for objective evaluation.

Other options for ischemia evaluation including stress electrocardiography, stress echocardiography, CMR, CT with fractional flow reserve (FFR), and catheterization. Stress echocardiography has relatively poor sensitivity possibly related to suboptimal windows and interobserver variability.<sup>13</sup> Stress-CMR studies for AAOCA in pediatric populations have promising results though further research is required.<sup>14</sup> Coronary catheterization can offer hemodynamic assessment using

**Table 1.** Cohort clinical and imaging characteristics of anomalous aortic origin of coronary artery (AAOCA)

	Total	PET/CT positive	PET/CT negative	P value
Number of patients	82	26	56	
Demographics				
Age (years)	45 ± 20	45 ± 20	45 ± 20	.967
Female	30 (37%)	10 (39%)	20 (36%)	.811
Body mass index (kg·m <sup>-2</sup> )	28 ± 6	28 ± 7	28 ± 6	.778
Body surface area (m <sup>2</sup> )	1.98 ± 0.28	1.90 ± 0.27	2.02 ± 0.27	.064
Symptoms				
Chest pain	45 (55%)	16 (62%)	29 (52%)	.479
New York Heart Association class				
1	56 (68%)	15 (58%)	41 (73%)	.375
2	15 (18%)	6 (23%)	9 (16%)	
3	10 (12%)	5 (19%)	5 (9%)	
4	1 (1%)	0 (0%)	1 (2%)	
Pre-syncope/syncope	15 (18%)	4 (15%)	11 (20%)	.765
Cardiac arrest	2 (2%)	0 (0%)	2 (4%)	1.000
Past history				
Cardiac surgery	1 (1%)	0 (0%)	1 (2%)	1.000
Cardiac implantable electronic device	1 (1%)	0 (0%)	1 (2%)	1.000
Myocardial infarction	3 (4%)	0 (0%)	3 (5%)	.548
Coronary artery disease	7 (9%)	4 (15%)	3 (5%)	.200
Hypertension	32 (39%)	8 (31%)	24 (43%)	.339
Hyperlipidemia	38 (46%)	12 (46%)	26 (46%)	1.000
Diabetes	7 (9%)	4 (15%)	3 (5%)	.200
Current smoker	7 (9%)	2 (8%)	5 (9%)	1.000
Stroke	2 (2%)	1 (4%)	1 (2%)	.536
Atrial fibrillation	5 (6%)	1 (4%)	4 (7%)	1.000
Estimated glomerular filtration rate (mL·m <sup>-2</sup> )	82 ± 17	80 ± 16	83 ± 17	.574
Hemoglobin (g·dL <sup>-1</sup> )	14.4 ± 3.4	14.0 ± 1.8	14.6 ± 4.0	.477
Medications				
Aspirin	27 (33%)	9 (35%)	18 (32%)	1.000
P2Y12 inhibitor	4 (5%)	1 (4%)	3 (5%)	1.000
Anticoagulant	3 (4%)	1 (4%)	2 (4%)	1.000
Statin	34 (42%)	11 (42%)	23 (41%)	1.000
Beta-blocker	31 (38%)	11 (42%)	20 (36%)	.632
Calcium channel blocker	14 (17%)	5 (19%)	9 (16%)	.758
Nitrates	11 (13%)	8 (31%)	3 (5%)	<b>.003</b>
Angiotensin converting enzyme inhibitor/ angiotensin receptor blocker	19 (23%)	9 (35%)	10 (18%)	.158
Diuretic	7 (9%)	3 (12%)	4 (7%)	.673
Anatomical diagnosis modality				
Computed tomography angiography	69 (84%)	24 (92%)	45 (80%)	.209
Left heart catheterization	80 (98%)	26 (100%)	54 (96%)	1.000
Magnetic resonance angiography	2 (2%)	1 (4%)	1 (2%)	.536
Transthoracic echocardiography total	77 (94%)	25 (96%)	52 (93%)	1.000
Anomalous vessel				
Left coronary artery/branches	24 (29%)	10 (39%)	14 (25%)	.297
Left main	19 (23%)	10 (39%)	9 (16%)	.046
Left anterior descending	5 (6%)	0 (0%)	5 (9%)	.173



**Table 1** continued

	<b>Total</b>	<b>PET/CT positive</b>	<b>PET/CT negative</b>	<b>P value</b>
Left circumflex	2 (2%)	0 (0%)	2 (4%)	1.000
Right coronary artery	58 (71%)	16 (62%)	42 (75%)	.297
Echocardiography				
Left ventricular end-diastolic volume indexed (mL·m <sup>-2</sup> )	51 ± 15	48 ± 13	52 ± 16	.295
Left ventricular end-systolic volume indexed (mL·m <sup>-2</sup> )	21 ± 9	20 ± 7	21 ± 10	.488
Left ventricular stroke volume indexed (mL·m <sup>-2</sup> )	30 ± 8	28 ± 8	31 ± 8	.237
Left ventricular ejection fraction (%)	60 ± 6%	60 ± 5	60 ± 6	.666
Left ventricular mass indexed (g·m <sup>-2</sup> )	85 ± 21	84 ± 19	85 ± 22	.879
Right ventricular systolic pressure (mmHg)	24 ± 7	23 ± 4	25 ± 8	.400
Dilated right ventricle	3 (4%)	2 (8%)	1 (2%)	.235
Right ventricular dysfunction	1 (1%)	0 (0%)	1 (2%)	1.000
Nuclear stress test				
Method				
Nitrogen 13-Ammonia	54 (66%)	21 (81%)	33 (59%)	.079
Rubidium-82	28 (34%)	5 (19%)	23 (41%)	
Stress method				
Exercise	54 (66%)	21 (81%)	33 (59%)	.079
Dobutamine	28 (34%)	5 (19%)	23 (41%)	
Heart rate rest (bpm)	67 ± 12	68 ± 10	66 ± 13	.582
Heart rate maximum (bpm)	151 ± 23	157 ± 24	149 ± 23	.134
Systolic blood pressure maximum (mmHg)	156 ± 25	159 ± 25	154 ± 25	.414
Heart rate x blood pressure product	23,613 ± 5740	25,004 ± 6021	22,967 ± 5542	.136
Estimated metabolic equivalents of task	9.8 ± 2.6	9.2 ± 2.4	10.2 ± 2.7	.181
Left ventricular ejection fraction rest (%)	60 ± 10%	61 ± 8	59 ± 10	.379
Left ventricular ejection fraction stress (%)	65 ± 8%	65 ± 8	65 ± 8	.820
Chest pain with exercise	6 (73%)	1 (4%)	5 (9%)	.659
ST depression with exercise	13 (16%)	6 (23%)	7 (13%)	.329
Summed rest score	0.5 ± 2.6	0.3 ± 0.9	0.5 ± 3.0	.681
Summed stress score	2.8 ± 5.3	7.8 ± 5.7	0.5 ± 3.0	< .001
Summed difference score	2.5 ± 5.0	8.2 ± 5.9	0.0 ± 0.0	< .001
Scan risk				< .001
Indeterminate	5 (6%)	3 (12%)	2 (4%)	
Low	57 (70%)	6 (23%)	51 (91%)	
Intermediate	13 (16%)	11 (42%)	2 (9%)	
High	7 (9%)	6 (23%)	1 (2%)	
Ischemia positive	26 (32%)	26 (100%)	N/A	N/A

Numbers are mean ± standard deviation or frequency (percentage)  
P < .05 in bold

instantaneous wave-free flow ratio (iFR), which may be preferred over FFR given less susceptibility to overshooting systolic pressure.<sup>15</sup> Finally, a recent study applied CT-FFR in 62 AAOCA patients, found lower FFR values to correlate with interarterial course and intramural path, with the optimal threshold ≤ 0.83 for this purpose (with sensitivity 96% and specificity

100%).<sup>16</sup> Further studies are required to compare stress testing modalities in AAOCA.

The most important treatment decision in AAOCA is whether it should be intervened or managed conservatively, and guidelines are shifting from anatomical to ischemia testing as the focus.<sup>5,6</sup> These empiric recommendation are reflected in our study where chest pain

**Table 2.** Management and outcomes of anomalous aortic origin of coronary artery (AAOCA)

	<b>Total</b>	<b>PET/CT positive</b>	<b>PET/CT negative</b>	<b>P value</b>
Number of patients	82	26	56	
Surgery	37 (45%)	19 (73%)	18 (32%)	<b>.001</b>
Unroofing	29 (78%)	12 (63%)	17 (94%)	<b>.042</b>
Coronary artery bypass grafting	6 (17%)	5 (28%)	1 (6%)	.177
Reimplantation	2 (6%)	2 (11%)	0 (0%)	.486
Medication changes (after nuclear stress test)				
Aspirin	22 (27%)	10 (39%)	12 (21%)	.117
P2Y12 inhibitor	3 (4%)	2 (8%)	1 (2%)	.235
Anticoagulant	3 (4%)	3 (12%)	0 (0%)	<b>.029</b>
Statin	3 (4%)	3 (12%)	0 (0%)	<b>.029</b>
Beta-blocker	16 (20%)	7 (27%)	9 (16%)	.369
Calcium channel blocker	5 (6%)	2 (8%)	3 (5%)	.650
Nitrates	1 (1%)	1 (4%)	0 (0%)	.317
ACE inhibitor/ARB	1 (1%)	1 (4%)	0 (0%)	.317
Diuretic	20 (24%)	10 (39%)	10 (18%)	.056
Outcomes				
Follow-up duration (years)	2.2 ± 1.8	2.2 ± 1.5	2.1 ± 1.9	.864
Death (all-cause)	1 (1%)	0 (0%)	1 (2%)	.000
Death (cardiovascular)	1 (1%)	0 (0%)	1 (2%)	.000
Myocardial infarction	2 (2%)	0 (0%)	2 (4%)	.000
Stroke/transient ischemic attack	1 (1%)	1 (4%)	0 (0%)	.317
Arrhythmia hospitalization	4 (5%)	2 (8%)	2 (4%)	.588
Heart failure hospitalization	0 (0%)	0 (0%)	0 (0%)	.000
Chest pain hospitalization	10 (12%)	3 (12%)	7 (13%)	.000
Chest pain at end of follow-up	21 (26%)	6 (29%)	15 (71%)	.792
Cardiovascular hospitalization	14 (17%)	7 (27%)	7 (13%)	.124

Numbers are mean ± standard deviation or frequency (percentage)  
*P* < .05 in bold

and ischemia on PET-CT are the main factors associated with surgery. Unroofing is the most widely used surgical technique (78%) in our cohort.<sup>2,5,6</sup> Conservative management is reasonable in the absence of symptoms, high risk anatomy and ischemia.<sup>5,6</sup> Our study reassuringly found good outcomes of AAOCA patients during the first few years after PET-CT assessment.

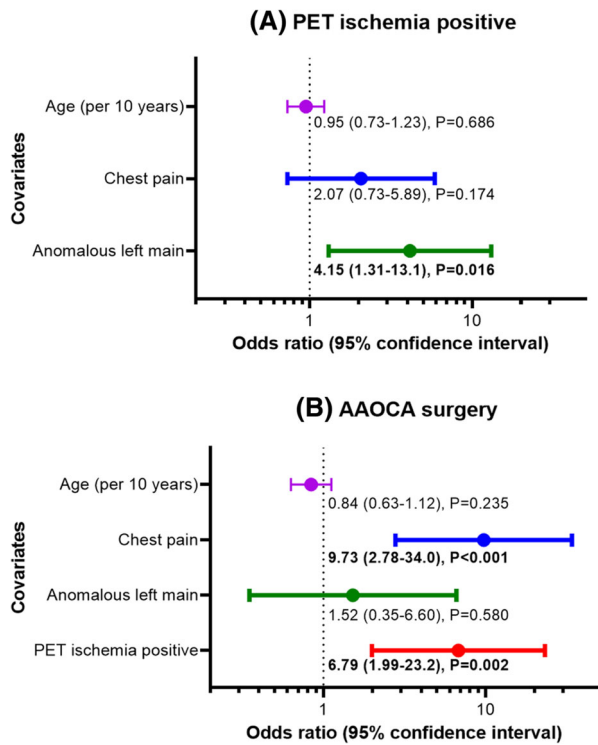
### LIMITATIONS

Limitations of this study include its single-center retrospective observational cohort design and relatively small cohort size and number of events, although it is the largest AAOCA study utilizing PET-CT. We included only AAOCA patients referred for PET-CT based on the decision of the managing cardiologist, possibly introducing selection bias and limiting generalizability. Non-PET imaging modalities such as TTE, CT, CMR, and catheterization were not performed in all patients, and other ischemia testing modalities were rarely performed

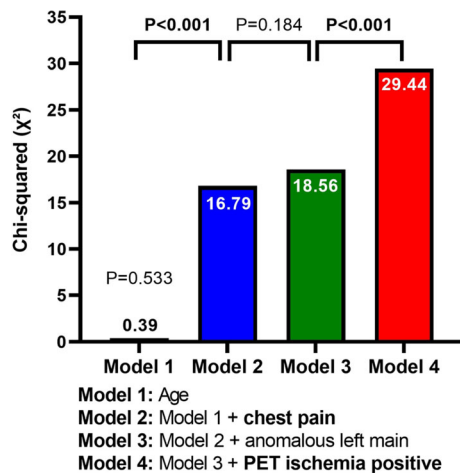
to enable comparison. Furthermore, adverse events were rare to allow for meaningful multivariable analyses of outcomes so we focused on what factors influenced proceeding to AAOCA surgery. Ischemia testing was rarely performed after AAOCA surgery, warranting further research. Follow-up was also restricted as this was tertiary referral center.

### CONCLUSION

In a consecutive cohort of 82 patients with AAOCA, ischemia is present in a third of patient on stress PET-CT, and adverse events were rare. Chest pain and the presence of ischemia on PET-CT were associated with referral to surgery. Anomalous left main artery was associated with ischemia on PET-CT; however, anatomical features alone were not drivers for surgery. Presence or absence of chest pain did not significantly correlate with ischemia on PET-CT, showing the importance of objectively assessing for ischemia



**Figure 2.** Forest plots of odds ratios (95% confidence intervals) of covariates from multivariable analyses for **A** PET ischemia and **B** anomalous coronary surgery.



**Figure 3.** Stepwise multivariable logistic regression for anomalous coronary artery surgery and incremental value of pre-specified covariates.

including in asymptomatic patients. Our findings encourage the greater use of PET-CT for ischemia evaluation in AAOCA patients to help with decision-making toward surgery. Larger multicenter studies are needed to evaluate the interplay between AAOCA anatomy, chest pain, ischemia by PET-CT, and surgical treatment.

## NEW KNOWLEDGE GAINED

PET-CT can evaluate ischemia in anomalous coronary artery and thus identify patients who would benefit from surgical intervention.

## Disclosures

*None to declare.*

## References

1. Yamanaka O, Hobbs RE. Coronary artery anomalies in 126,595 patients undergoing coronary arteriography. *Cathet Cardiovasc Diagn* 1990;21:28-40.
2. Cheezum MK, Liberthson RR, Shah NR, Villines TC, O'Gara PT, Landzberg MJ. Anomalous aortic origin of a coronary artery from the inappropriate sinus of valsalva. *J Am Coll Cardiol* 2017;69:1592-608.
3. Basso C, Maron BJ, Corrado D, Thiene G. Clinical profile of congenital coronary artery anomalies with origin from the wrong aortic sinus leading to sudden death in young competitive athletes. *J Am Coll Cardiol* 2000;35:1493-501.
4. Eckart RE, Scoville SL, Campbell CL, Shry EA, Stajduhar KC, Potter RN, et al. Sudden death in young adults: A 25-year review of autopsies in military recruits. *Ann Intern Med* 2004;141:829-34.
5. Baumgartner H, De Backer J, Babu-Narayan SV, Budts W, Chessa M, Diller G-P, et al. ESC Guidelines for the management of adult congenital heart disease: The Task Force for the management of adult congenital heart disease of the European Society of Cardiology (ESC). Endorsed by: Association for European Paediatric and Congenital Cardiology (AEPC), International Society for Adult Congenital Heart Disease (ISACHD). *Eur Heart J* 2020;42:563-645.
6. Stout KK, Daniels CJ, Aboulhosn JA, Bozkurt B, Broberg CS, Colman JM, et al. 2018 AHA/ACC guideline for the management of adults with congenital heart disease. *J Am Coll Cardiol* 2019;73:e81-192.
7. Frommelt P, Lopez L, Dimas VV, Eidem B, Han BK, Ko HH, et al. Recommendations for multimodality assessment of congenital coronary anomalies: A guide from the American Society of Echocardiography: Developed in Collaboration with the Society for Cardiovascular Angiography and Interventions, Japanese Society of Echocardiography, and Society for Cardiovascular Magnetic Resonance. *J Am Soc Echocardiogr* 2020;33:259-94.
8. Agrawal H, Mery CM, Day PE, Sexson Tejtel SK, McKenzie ED, Fraser CD Jr, et al. Current practices are variable in the evaluation and management of patients with anomalous aortic origin of a coronary artery: Results of a survey. *Congenit Heart Dis* 2017;12:610-4.
9. Cremer PC, Mentias A, Koneru S, Schoenhagen P, Majdalany D, Lorber R, et al. Risk stratification with exercise N(13)-ammonia PET in adults with anomalous right coronary arteries. *Open heart* 2016;3:e000490.
10. Dorbala S, Di Carli MF. Cardiac PET perfusion: Prognosis, risk stratification, and clinical management. *Semin Nucl Med* 2014;44:344-57.
11. Gentile F, Castiglione V, Caterina RD. Coronary artery anomalies. *Circulation* 2021;144:983-96.
12. Mc Ardle BA, Dowsley TF, deKemp RA, Wells GA, Beanlands RS. Does rubidium-82 PET have superior accuracy to SPECT



- perfusion imaging for the diagnosis of obstructive coronary disease? A systematic review and meta-analysis. *J Am Coll Cardiol* 2012;60:1828-37.
13. Molossi S, Agrawal H, Mery CM, Krishnamurthy R, Masand P, Sexson Tejtel SK, et al. Outcomes in anomalous aortic origin of a coronary artery following a prospective standardized approach. *Circulation* 2020;13:e008445.
  14. Scannell CM, Hasaneen H, Greil G, Hussain T, Razavi R, Lee J, et al. Automated quantitative stress perfusion cardiac magnetic resonance in pediatric patients. *Front Pediatr* 2021;9:699497.
  15. Driesen BW, Warmerdam EG, Sieswerda GT, Schoof PH, Meijboom FJ, Haas F, et al. Anomalous coronary artery originating from the opposite sinus of Valsalva (ACAOS), fractional flow reserve- and intravascular ultrasound-guided management in adult patients. *Catheter Cardiovasc Interventions* 2018;92:68-75.
  16. Ferrag W, Scalbert F, Adjedj J, Dupouy P, Ou P, Juliard JM, et al. Role of FFR-CT for the evaluation of patients with anomalous aortic origin of coronary artery. *JACC Cardiovasc Imaging* 2021;14:1074-6.

**Publisher's Note** Springer Nature remains neutral with regard to jurisdictional claims in published maps and institutional affiliations.

Springer Nature or its licensor holds exclusive rights to this article under a publishing agreement with the author(s) or other rightsholder(s); author self-archiving of the accepted manuscript version of this article is solely governed by the terms of such publishing agreement and applicable law.