



ORIGINAL ARTICLE

# Changes in mandibular border movements in adult patients after correction of functional anterior crossbite



Jian-Hong Yu <sup>a,b</sup>, Chih-Chieh Lin <sup>c\*</sup>, Yuan-Hou Chen <sup>b</sup>

<sup>a</sup> School of Dentistry, College of Medicine, China Medical University, Taichung, Taiwan

<sup>b</sup> Division of Orthodontics, Department of Dentistry, China Medical University Hospital, Taichung, Taiwan

<sup>c</sup> Division of General Practice, Department of Dentistry, China Medical University Hospital, Taichung, Taiwan

Received 1 October 2016

Available online 24 December 2016

## KEYWORDS

anterior crossbite;  
frontal plane;  
horizontal displacement;  
mandibular border movement;  
sagittal plane;  
vertical displacement

**Abstract** *Background/purpose:* An effective approach for assessing masticatory function is necessary. The goal of this study was to establish an efficient method for evaluating mandibular border movements in patients after functional anterior crossbite was corrected.

*Materials and methods:* Five patients with functional anterior crossbite were included in this study. They were treated with edgewise appliance and improved super-elastic nickel–titanium archwire. The digital images were collected before and after anterior crossbite was corrected. The trajectory paths of mandibular border movement were evaluated on both the frontal and sagittal planes.

*Results:* When the mandibular border movement paths were analyzed on the frontal plane for the vertical displacement, significant increases in the maximum left- and right-lateral movements were observed. For the horizontal displacement, although decreasing trends were observed in the maximum mouth opening and protrusive movements, no significant difference was detected. However, horizontal displacements were generally greater in men than in women. When the mandibular border movement paths were analyzed on the sagittal plane, significant increases in all the vertical and horizontal displacements were observed at all border movements, except the maximum mouth opening. However, if the data were compared between men and women, significant difference was shown only in the horizontal displacement of the maximum protrusion.

\* Corresponding author. School of Dentistry, China Medical University, 91, Xue-Shi Road, North District, Taichung City, 40402, Taiwan.  
E-mail address: [kenkoyu@mail.cmu.edu.tw](mailto:kenkoyu@mail.cmu.edu.tw) (C.-C. Lin).

**Conclusion:** On both the frontal and sagittal planes, after correction of the anterior crossbite there are increases in vertical and horizontal displacements at all kinds of mandibular border movements except for the horizontal displacements at the maximum mouth opening and the maximum protrusion.

© 2017 Association for Dental Sciences of the Republic of China. Publishing services by Elsevier B.V. This is an open access article under the CC BY-NC-ND license (<http://creativecommons.org/licenses/by-nc-nd/4.0/>).

## Introduction

The masticatory system is a functional system with a complex physiological structure composing of teeth, supporting structures around teeth, maxillary and mandibular bones, temporomandibular joint (TMJ), muscles and soft tissues attached to the mandible, as well as the vascular and nervous systems involved in mastication.<sup>1</sup> Disturbances in the structure, pattern, and function of the masticatory system are reflected by functional or structural disorders in its other components.<sup>2,3</sup>

The factors influencing masticatory functions can be divided into two groups according to physiological structures. The first group is the anatomic structures in the head and neck, including teeth, bones, muscles, TMJ, and ligaments. The second group is the ability of the nervous system that integrates the inputs from peripheral receptors and the rhythmical masticatory movements produced by a central pattern generator. Among the anatomic structures in the head and neck, dentition status appears to have a direct effect on masticatory function. Moreover, the most important factor influencing masticatory performance is the condition of teeth, including the number of teeth, occlusal patterns of teeth, structural intactness of teeth, and contact area between teeth.

Anterior crossbite is one kind of functional crossbite that can be defined as a situation in which the mandible is forced to an anterior position due to occlusal interference of the anterior teeth when the mandible is moving from mouth opening position to centric occlusion. The crowded maxillary and mandibular incisors are typically found in anterior crossbite patients who seek orthodontic treatment. In 1990, Eismann and Prusas<sup>4</sup> reported that anterior crossbite usually leads to excessive compression on the periodontal tissues during mastication. In case of anterior crossbite with concomitant teeth grinding, not only the produced large forces but also the direction of occlusal forces can result in changes of TMJ.<sup>4,5</sup> Thus, the stimulation of pressure receptors in the periodontal ligament and TMJ in anterior crossbite patients during mastication may change mandibular movements in order to relieve discomfort or to prevent structural damage.<sup>6</sup> For the anterior crossbite, patients who have no need for surgery, Proffit et al<sup>7</sup> described the principles for orthodontic treatment including labial tipping of the tooth axis of the maxillary anterior teeth or lingual tipping of the tooth axis of mandibular incisors. Furthermore, there are many optional devices for orthodontic treatment, which can be categorized into removable and fixed appliances.

This study aimed to establish an effective method for assessing masticatory efficiency, thereby to investigate the relationships between the mandibular border movements

and the patterns of permanent dentition before and after the orthodontic treatment of functional anterior crossbite, and to contribute to the improvements in assessing malocclusion, treatment outcome, and occlusal function.<sup>8–10</sup>

## Materials and methods

This study enrolled five patients (two men and three women, aged 16–28 years) from Division of Orthodontics, Department of Dentistry, China Medical University Hospital (CMUH). The inclusion criteria for the patients were as follows. First, the patients should have occlusal contacts in the center of the occlusion and should be diagnosed as having angle class III malocclusions of the first molars. Second, the relationships between maxillary and mandibular incisors should appear as an anterior crossbite in all four incisors during centric occlusion and the contact area should not be at the cutting edges of the maxillary and mandibular incisors during the closure to the centric relation position. Third, the permanent teeth should be intact and none of the teeth missing except the third molars. In addition, none of the teeth had unfilled cavity or obvious periodontitis. A single crown was acceptable, but there should be no dental bridge or fixed partial denture in the oral cavity. Fourth, no significant TMJ disorders were noted and there was no pain in masticatory muscles before entering the study. Fifth, the patients received no orthodontic treatments before entering the study.

All patients understood the procedures and related specific precautions. They signed the informed consent before entering the study. This study was reviewed and approved by the Institutional Review Board at the CMUH (Institutional Review Board number, CMUH-103-REC3-045).

All patients were treated with standard orthodontic brackets, adhesives, and improved super-elastic Nitinol nickel–titanium (Ti-Ni) alloy wire (ISW). The brackets were firstly bonded on the maxillary teeth, followed by using the ISW for leveling. Anterior crossbite arch was used for labial tipping of the maxillary incisors. The patients were asked to revisit the outpatient clinic every 2 weeks for evaluation to avoid the occurrence of excessive labial tipping of the incisors. Anterior crossbite arch was removed only after the cutting edges became the contact areas of the maxillary and mandibular incisors during the closure to the centric relation position (centric occlusion), and then replaced by a plain ISW for leveling. The mandibular incisors were also bonded with brackets for leveling. The patients were asked to revisit once per month at outpatient clinics for assessment. If necessary, the ISW multiloop edgewise archwire was placed in the mandibular arch for lingual tipping of the mandibular incisors, and appropriate intermaxillary elastics

were used for the adjustments of jaw position and teeth. The standards of removing brackets were the fulfillment of the "six keys" of Andrews.<sup>11</sup>

The three-dimensional movements of the mandibular incisors, including vertical, anterior–posterior, and left and right directions, were recorded using photography. Two video cameras were placed in the frontal and sagittal planes. The fixed angle was 90° between the two cameras. After recording, image analysis of mandibular movements was conducted using the software, DigiGnatho (Version 1.3), with a design dedicated to mandibular movement analysis. For tracking mandibular movements, two resin reference balls were used to label the cutting edges between the nose and the center point of mandibular incisors.

The mandibular movements were categorized into four types, including the maximum mouth opening, the maximum mouth opening and closing after protrusion, the maximum left-lateral mouth opening and closing, and the maximum right-lateral mouth opening and closing. All patients were asked to perform each mandibular movement seven times and were allowed to rest for intervals of 60 seconds between each type of movement to avoid deviations as a consequence of muscle exhaustion.

The recording was performed at the time points before orthodontic treatment, during the active orthodontic treatment at each outpatient revisit, and at the end of active treatment. During the active orthodontic treatment, the revisiting period was divided into two stages. The first stage was defined as the time period after orthodontic brackets were bonded and before the correction of anterior crossbite was achieved; the patients were seen once every 2 weeks at the first stage. The second stage was defined as the time period after the anterior crossbite correction was achieved and before the brackets was removed; the patients were seen once per month at the second stage.

The mandibular border movements were analyzed on both the frontal and sagittal planes. On the frontal plane, both vertical displacement (the maximum displacement between the upper and lower borders in a mandibular border movement cycle) and horizontal displacement (the maximum displacement between the left and right sides in a mandibular border movement cycle) were analyzed. On the sagittal plane, both vertical displacement (the maximum displacement between the upper and lower borders in a mandibular border movement cycle) and horizontal displacement (the maximum displacement between the left and right sides in a mandibular border movement cycle) were also analyzed.

This study was conducted to evaluate potential changes in the functional mandibular movements during the time period that the patients underwent orthodontic treatment. To present the time trend, the starting time point was defined as that before the anterior crossbite was corrected. Dependent variables were the measured parameters for analysis. The time points after the anterior crossbite was corrected were used as independent variables. Based on the data at different time points, the regression line of each patient was depicted to represent the trend of changes after the anterior crossbite was corrected. Furthermore, to describe the overall time-varying trend, we used generalized estimating equations, a method for analyzing longitudinal data by using generalized linear

models, to adjust the bias in the estimated relationships. After adjustment for sex, time-varying effects on the mandibular border movements and masticatory movements were evaluated after the anterior crossbite was corrected. In the analysis of generalized estimating equations, the autoregression with first order correlation structure was used to form estimates for structural parameters, in which the effects of time and sex were also considered. A two-tailed *P* value < 0.05 was considered statistically significant in each test. All statistical analyses were performed using the SAS 9.1 statistical software package.

## Results

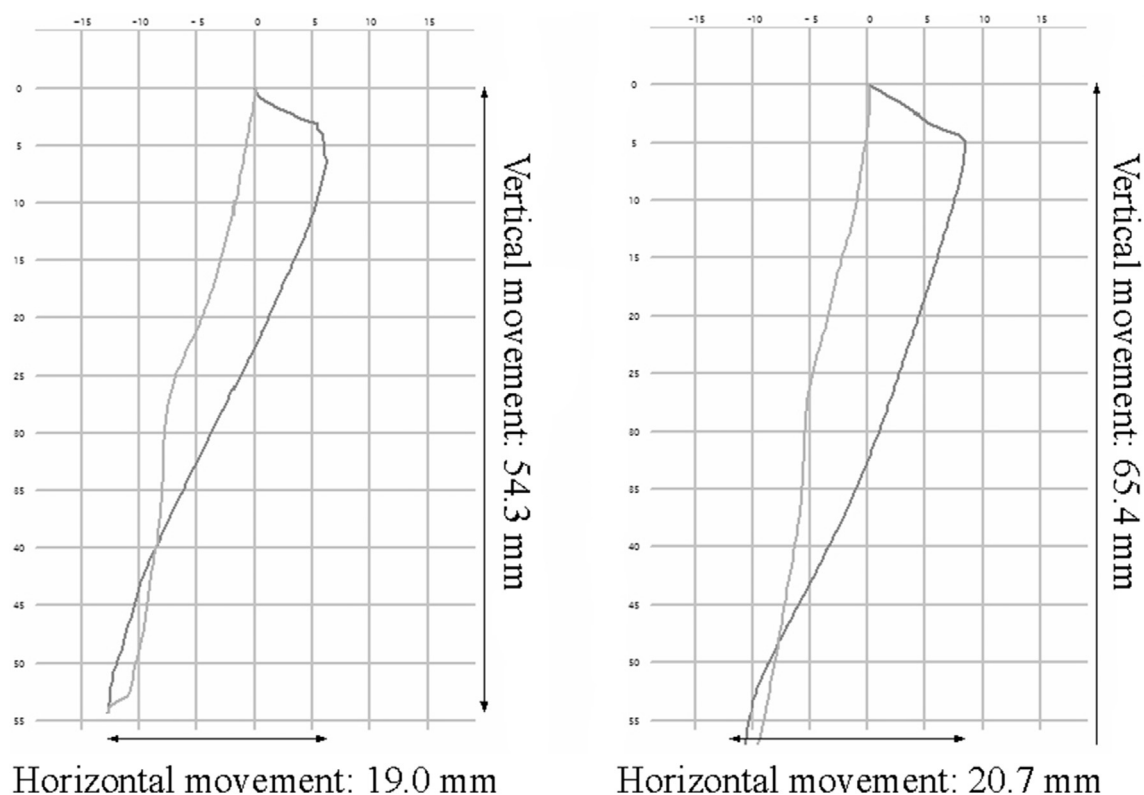
Figure 1 shows the change of mandibular border movement paths on the frontal plane before and after functional anterior crossbite was corrected. For the vertical displacements, significant increases in the maximum left- and right-lateral movements were observed (Table 1). For the horizontal displacement, although decreasing trends in the maximum mouth opening and protrusive movements were observed, no significant difference was detected. In addition, no significant differences in all vertical displacements were found between male and female patients. However, horizontal displacements were generally greater in men than in women.

Figure 2 shows the change of the mandibular border movement paths on the sagittal plane before and after functional anterior crossbite was corrected. Significant increases in all the vertical and horizontal displacements were observed at all border movements, except the maximum mouth opening (Table 2). However, if the data were compared between men and women, significant difference was shown only in the horizontal displacement of the maximum protrusion, in which men had a 5.604 mm greater horizontal displacements than women.

## Discussion

According to clinical experiences the average duration of orthodontic treatment with a common method is approximately 2 years. Compared with adults, the duration to complete a full course of orthodontic treatment is shorter in children. Therefore, the participants of the present study achieving a significantly faster correction (or shorter course) when compared with the patients undergoing treatment with general occlusal splints and functional appliances was cited. The success of active orthodontic treatment within 32 weeks was mainly attributed to the use of ISW in this study.<sup>12</sup> In recent years, the researchers in the National Tokyo Medical and Dental University in Japan have dedicated to investigate Ni-Ti orthodontic wires and the development of ISW. To solve the problems associated with changes in the specific properties of general super-elastic Ni-Ti alloy wires caused by intraoral temperature changes and the amount of deformation due to the wire material itself, ISW was invented to reduce the effects of stress hysteresis and to decrease the variations in intraoral temperature that increase the load of archwires.

Differences in treatment with ISW compared to general Ni-Ti wires and stainless steel wires can be summarized as follows. First, ISW is a more rigid rectangular wire, but has



**Figure 1** The change of left-side mandibular border movement paths on the front plane before and after anterior crossbite was corrected. (A) The path before anterior crossbite was corrected. (B) The path after anterior crossbite was corrected.

**Table 1** Analysis of the mandibular border movements on the frontal plane by a generalized linear model with generalized estimating equation under autoregression with first order correlation structures.

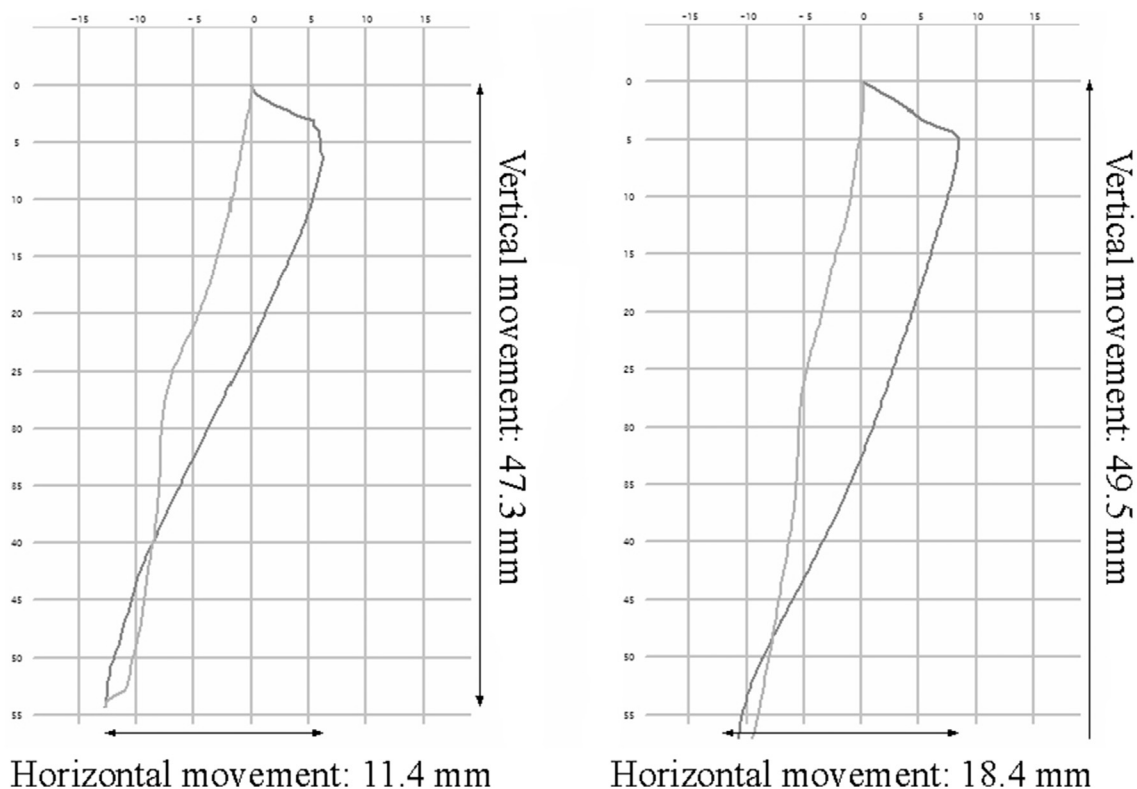
		Vertical displacement (mm)		Horizontal displacement (mm)	
		Mean (SE)	P	Mean (SE)	P
Displacement in the maximum mouth opening	When crossbite was corrected	0.552 (0.471)	0.241	-0.219 (0.153)	0.152
	Male versus female	3.052 (4.876)	0.531	4.030 (0.630)	<0.0001
Displacement in the maximum protrusion	When crossbite was corrected	0.601 (0.425)	0.158	-0.115 (0.112)	0.303
	Male versus female	1.980 (4.583)	0.666	5.013 (0.557)	<0.0001
Displacement in the maximum left-lateral movement	When crossbite was corrected	1.333 (0.441)	0.003	0.019 (0.095)	0.845
	Male versus female	2.598 (5.692)	0.648	9.337 (1.309)	<0.0001
Displacement in the maximum right-lateral movement	When crossbite was corrected	0.992 (0.376)	0.008	0.006 (0.156)	0.970
	Male versus female	0.404 (5.377)	0.940	2.167 (0.631)	0.001

SE = standard error.

about one-third the stiffness of a stainless-steel wire and an equivalent flexibility of 0.41-mm Sentalloy Ni-Ti alloy wire. Because of the super-elasticity and large working range, ISW can achieve direct bonding of teeth without the need of bending loops. After the orthodontic brackets were firstly bonded to teeth, ISW can be perfectly placed in the brackets, no matter how crowded the teeth are. Second, ISW has a low hysteresis characteristic that can generate consistent forces and is more resistant to deformation, thus it can provide constant and sustained forces and natural physiological movement of teeth in the mouth. Third, ISW possesses higher and specific damping capacities. This property ensures that shock and vibration are minimized to

prevent excessive forces and root resorption and can result in the formation of more healthy alveolar bone in the surrounding tissues. Fourth, ISW does not have a fixed arch form type, which can be adapted to different dental arches of different individuals to achieve a normal occlusion.

Mandibular border movements are the nonfunctional movements of the mandible. These movements are the maximum amount of movement in any direction and plane, reproducible, can be affected by the TMJ, muscles, ligaments and other tissues, and are also closely associated with occlusal patterns. In other words, mandibular border movements are highly restricted by anatomical structures. Any defect of these structures will result in dysfunction in



**Figure 2** The change of horizontal mandibular border movement paths on the sagittal plane before and after anterior crossbite was corrected. (A) The path before anterior crossbite was corrected. (B) The path after anterior crossbite was corrected.

**Table 2** Analysis of the mandibular border movements on the sagittal plane by a generalized linear model with generalized estimating equation under autoregression with first order correlation structures.

		Vertical displacement (mm)		Horizontal displacement (mm)	
		Mean (SE)	P	Mean (SE)	P
Displacement in the maximum mouth opening	When crossbite was corrected	0.570 (0.355)	0.108	0.543 (0.376)	0.149
	Male versus female	4.130 (5.362)	0.441	2.784 (1.585)	0.079
Displacement in the maximum protrusion	When crossbite was corrected	0.821 (0.391)	0.036	1.057 (0.447)	0.018
	Male versus female	3.193 (5.301)	0.547	5.604 (2.164)	0.010
Displacement in the maximum left-lateral movement	When crossbite was corrected	1.300 (0.431)	0.003	1.237 (0.417)	0.003
	Male versus female	3.215 (5.431)	0.554	1.222 (2.253)	0.588
Displacement in the maximum right-lateral movement	When crossbite was corrected	1.033 (0.409)	0.012	1.217 (0.444)	0.006
	Male versus female	1.767 (6.084)	0.772	0.950 (2.351)	0.686

SE = standard error.

mandibular movement. Therefore, the TMJ is commonly used in clinical practice to measure the range of movements or treatment outcomes.

The results of the present study revealed no significant difference in the vertical movement during maximum mouth opening before and after treatment. We also found at the time that the anterior crossbite was just corrected, a minimum duration is required to achieve the maximum mouth opening. Afterwards, the length of duration was observed in a trend of gradually increasing over time, with an average of  $0.552 \pm 0.471$  mm/mo. The results might be caused by the pre-existing anatomical structures (such as

the ligaments or muscles associated with the TMJ) that could limit the range of maximum mouth opening. At that time when anterior crossbite was corrected, the maxillary and mandibular incisors contacted with each other at the cutting edges, and thus resulted in increased occlusal contact as well as reduced movement during the maximum mouth opening. However, the dental coverage was gradually decreased with time to a normal range of coverage (or same as that prior to treatment) during orthodontic therapy, so that no significant difference was detected before and after the treatment for the vertical displacement at maximum mouth opening.

Our findings showed significant differences in the lateral–vertical displacements of the mandibular movements; however, it is a natural consequence following the correction of the anterior crossbite, because the range of movement would be increased as a result of interference removal.

Previous studies indicated that there is almost no evidence of canine guidance in functional anterior crossbite. During lateral movement, occlusal interference could lead to downward movements of the mandible for dodging the interference in order to further move towards the lateral side. However, the lateral movements are still often interrupted due to the interference. Therefore, in line with the results of previous studies,<sup>13</sup> our findings reflect natural consequences following the correction of crossbite, in which the range of movement was increased as a result of removal of interference.

In terms of the sex differences, we found that men had greater mandibular movements in both the vertical and horizontal directions. A previous study suggested that a larger border movement in men than women is the result of different anatomical structures. Mandible size is greater in men than in women and, therefore, when rotation in the TMJ occurs at the same angle during mandibular opening, a larger radius in men may result in a greater movement.<sup>14,15</sup>

In the patients with functional anterior crossbite before treatment, the jaw position is forced forward due to the interference from maxillary incisors, and thus leading to an anterior crossbite. After the anterior crossbite was corrected, rubber bands were used for three-dimensional jaw positioning to move the mandible backwards. Therefore, we observed a greater horizontal displacement of mandibular movement in the later stage of orthodontic treatment.

No anterior guidance was observed before crossbite treatment, but anterior guidance appeared after the occlusion was stabilized following the treatment. Indeed, anterior guidance actually can provide stable occlusions for the mandible to have a proper occlusal stop and to prevent the TMJ from a position with long term and excessive forces.

## Conflicts of interest

The authors have no conflicts of interest relevant to this article.

## Acknowledgments

This study was supported by grants from China Medical University in Taichung, Taiwan (CMU-105-S-30).

## References

1. Ash MM, Ramfjord PC. Neurophysiology and clinical correlation. In: Rice D, editor. *Occlusion*. Philadelphia: Saunders, 1995:1–41.
2. Neto GP, Puppim RM, Garcia R. Changes in the masticatory cycle after treatment of posterior crossbite in children aged 4 to 5 years. *Am J Orthodont Dentofac Orthoped* 2007;131:464–72.
3. Nanda R. The differential diagnosis and treatment of excessive overbite. *Dent Clin North Am* 1981;25:69–84.
4. Eismann D, Prusas R. Periodontal findings before and after orthodontic therapy in cases of incisor crossbite. *Eur J Orthodont* 1990;12:281–3.
5. Thompson JR. Abnormal function of the temporomandibular joints and related musculature. *Orthodont Implic Angle Orthod* 1986;56:181–92.
6. Faulkner MG, Hatcher DC, Hay A. A three-dimensional investigation of temporomandibular joint loading. *J Biomech* 1987;20:997–1002.
7. Proffit W, Fields Jr W, Sarver DM. *Contemporary Orthodontics*, 5th ed. Amsterdam: Elsevier, 2006:643.
8. Zafar H, Nordh E, Eriksson PO. Temporal coordination between mandibular and head–neck movements during jaw opening–closing tasks in man. *Arch Oral Biol* 2000;45:675–82.
9. Matsubara N, Hisano M, Minakuchi S, et al. Head movements in the occlusal phase of mastication. *J Med Dent Sci* 2002;49:37–42.
10. Gerstner GE, Fehrman J. Comparison of chin and jaw movements during gum chewing. *J Prosthet Dent* 1999;81:179–85.
11. Andrews LF. The six keys to normal occlusion. *Am J Orthodont* 1972;62:296–309.
12. Otsubo K. Development of the super-elastic Ti-Ni alloy wire appropriate to the oral environment. *J Jpn Orthod Soc* 1994;53:41–50.
13. Kiliaridis S, Karlsson S, Kjellberg H. Characteristics of masticatory mandibular movements and velocity in growing individuals and young adults. *J Dent Res* 1991;70:1367–70.
14. Sheppard IM. The effect of extreme vertical overlap on masticatory strokes. *J Prostho* 1965;15:1035–42.
15. Ogawa T, Ogawa M, Koyano K. Different responses of masticatory movements after alteration of occlusal guidance related to individual movement pattern. *J Oral Rehabil* 2001;28:830–41.