



Case Report

Dissociation of Bipolar Hemiarthroplasty of the Hip and Review of Literature

Athanasίου Vasileios, MD, PhD, Papagiannis Spyridon, MD *

Department of Orthopaedics, Patras University Hospital, Patras, Greece

ARTICLE INFO

Article history:

Received 21 March 2022
 Received in revised form
 3 May 2022
 Accepted 4 May 2022
 Available online xxx

Keywords:

Bipolar hemiarthroplasty
 Dissociation
 Disassembly
 Inner head displacement

ABSTRACT

Component dissociation after a bipolar hemiarthroplasty is an uncommon complication that usually necessitates reoperation due to difficulties in closed reduction. To our knowledge, only a few cases have been published in the recent literature. We present a case of disassembly location of in a 68-year-old woman who underwent bipolar hemiarthroplasty 10 years ago due to a left hip femoral neck fracture. She began complaining about pain and difficulty to bear weight after an unintentional internal rotation movement of her left hip. The initial radiographs showed the disassembly of the bipolar hip prosthesis, and the patient underwent conversion to total hip arthroplasty. We conducted a literature review to explain the potential causes and mechanisms.

© 2022 The Authors. Published by Elsevier Inc. on behalf of The American Association of Hip and Knee Surgeons. This is an open access article under the CC BY-NC-ND license (<http://creativecommons.org/licenses/by-nc-nd/4.0/>).

Introduction

Femoral neck fractures have a high prevalence around the world. They are associated with high mortality and disability rate, deteriorating patients' independence and quality of life. When it comes to treatment, the aims are to alleviate pain, allow early mobilization, and restore patient's preinjury level of function. Hip hemiarthroplasty, using either monopolar or bipolar implants to restore joint biomechanics, is still regarded among the most effective treatment options for displaced femoral neck fractures. In monopolar components, which were the first to be introduced, the femoral head is fastened to the stem whereas bipolar implants feature a polyethylene bearing between the stem and the head of the endoprosthesis that allows component rotation. Since they were first introduced in the 1970s, bipolar components have been widely used to treat displaced femoral neck fractures in elderly patients [1,2]. There are conflicting results and no consensus on which component is preferable for hip hemiarthroplasty. Randomized controlled trials comparing clinical outcomes between patients treated with bipolar or unipolar components have shown no obvious clinical advantage for one over the other [3–5]. Bipolar hemiarthroplasty resulted in a statistically significant reduction in

acetabular erosion when compared to unipolar implants, according to the primary findings of a newly published meta-analysis [6]. There were no significant variations in dislocation rate, revisions, or Harris Hip Score. A hip prosthesis dislocation is a common problem that has been thoroughly explored. On the contrary, there have been few reports of bipolar prosthesis dissociation. Through a literature analysis, we provide a rare incidence of a bipolar hemiarthroplasty disassembly and examine the potential mechanisms of failure.

Case history

A 68-year-old woman came to the accident and emergency department of our hospital complaining about left hip pain and inability to bear weight after a spontaneous internal rotation movement of her left hip during mobilization out of bed, with no history of falling. She was a nonsmoker, with a history of hypertension, who underwent a bipolar hip hemiarthroplasty for a left hip femoral neck fracture in another hospital 10 years ago. A bipolar self-centering head (Zimed Gaziantep, Turkey) was combined with a cementless stem (Bicontact, Aesculap Center Valley, PA, USA) (Fig. 1). The patient was entirely self-sufficient in daily activities and could walk without assistance. The left lower limb was shortened and externally rotated with a restricted range of motion on clinical examination, raising concerns for dislocation. The neurovascular system was intact. On the initial x-rays dissociation between the polyethylene ring and the inner femoral head was observed, while

* Corresponding author. Department of Orthopaedics, Patras University Hospital, Vlachogianni 9, Patras, Greece PC:26443. Tel.: +30 697 923 9434.
 E-mail address: papajohn_1217@hotmail.com

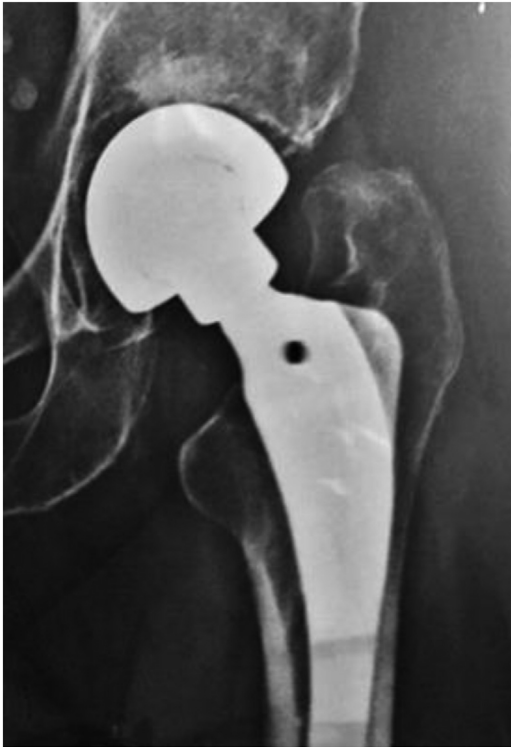

Figure 1. Patient's initial postoperative anteroposterior radiograph of a left hip bipolar hemiarthroplasty.

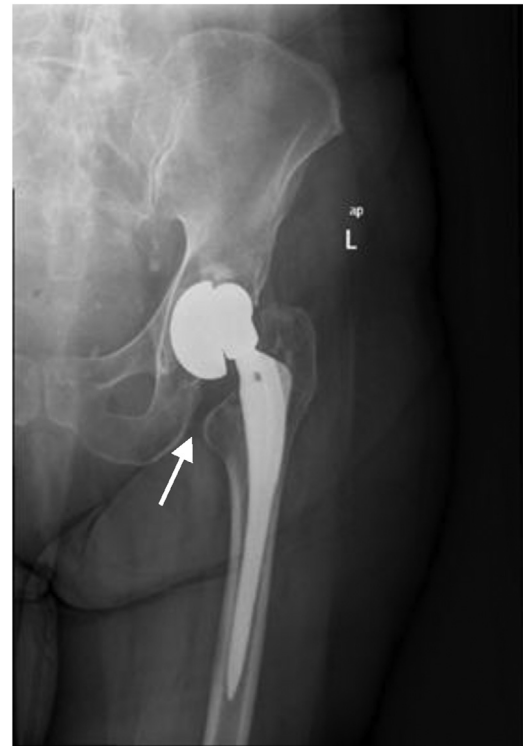


Figure 2. Anteroposterior radiograph demonstrating a dissociation of a left hip bipolar hemiarthroplasty. The outer head is in extreme varus position (arrow)—osteoarthritic changes of the acetabulum.

the outer head was still in the acetabulum. Varus position of the outer head and osteoarthritic changes of the acetabulum were identified (Fig. 2). No closed reduction maneuver was attempted and the patient was admitted to the orthopaedic ward. The erythrocyte sedimentation rate and C-reactive protein levels were normal. Four days later, the patient underwent a conversion of the bipolar hemiarthroplasty to total hip arthroplasty under spinal anesthesia. The patient was placed in the lateral decubitus position, the skin was incised over the previous scar, and a posterior approach to the left hip was used. Dislocation between the inner head and the polyethylene was observed, while the locking ring was dislodged but still attached to the inner head, with an excessive amount of wear (Fig. 3a-c). The prosthetic acetabular component was found to be intact, with no signs of wear, and still located inside the native acetabulum. We did not observe any findings of trunnionosis at the time of revision. The stem was well fixed and left in place, while the inner head, the polyethylene ring, and the outer head were removed. An uncemented, hemispherical, multiple-hole, acetabular component with 52 mm diameter was placed (Zimmer Biomet, Warsaw, Indiana) along with a polyethylene-bearing surface and a skirted metallic femoral head (12/14, 32 mm, XXL) (Fig. 4). Intraoperative cultures were negative. Although we had a medial acetabular wall breach complication due to over-reaming, the cup was well fixed and no additional screws were used. However, we decided to limit weight-bearing for 6 weeks until cup ingrowth could be achieved. There were no postoperative complications, and the patient was discharged 4 days after the operation. At 1-month follow-up, no complications were observed, partial weight-bearing was obtained using crutches, and the radiograph showed ongoing integration of the acetabular component (Fig. 5). The patient was encouraged to gradually return to full weight-bearing after 6 weeks. She was able to walk without any restrictions after 3 months. Finally, at 12-month follow-up, the

patient was able to return to her everyday activities, with a Harris Hip Score of 87.2 at that time.

Discussion

For treatment of femoral neck fractures, bipolar hemiarthroplasty of the hip has been a well-established procedure, with complication rates between unipolar and bipolar implants being nearly identical. Hemiarthroplasty dislocation is unusual, with a reported total rate of around 3.4% [7]. The detachment of the outer and inner heads of a bipolar prosthesis, which is referred as component disassembly or dissociation, was originally documented in 1985 after a polyethylene breakage during a Bateman bipolar hemiarthroplasty [8,9]. However, there have been only a few published case reports in recent literature concerning component dissociation following bipolar hemiarthroplasty (Table 1). Guo et al identified three different types of component disassembly to demonstrate plausible mechanisms [10]. Iatrogenic dissociation, commonly known as the “bottle opener” effect, is the first type. It occurs during reduction maneuvers of the bipolar prosthesis's locked outer head behind the acetabulum. The capturing ring of the polyethylene cup appears to absorb the twisting force during reduction, according to the findings [11]. This is thought to be the most common cause of dissociation following bipolar hemiarthroplasty [12]. To avoid the risk of component disassembly, Bian et al used a unique closed reduction technique, described as the “Push-turnover-pull” maneuver, that involved pressing the lower limb in an axial direction proximally, internal rotation, and finally the standard traction maneuver [13].

The presence of a single internal polyethylene ring rather than a double-locking mechanism was the only factor associated with an increased risk of dissociation during attempts for closed reduction, according to Lee et al, who reported a dissociation rate of 13% (7 out




Figure 3. Retrieved bipolar component and femoral head (a). No macroscopic wear was found at the articulating surface of the polyethylene insert (b). Excessive wear was found at the slots and groove of the polyethylene that contributed to the locking mechanism (c).

of 55) during manual reduction of a dislocated bipolar hemiarthroplasty [14]. Using a single-locking mechanism, the femoral head is fitted into the polyethylene liner within a metal shell, with a slotted polyethylene ring positioned and expanding to fit into a groove on the polyethylene liner's peripheral lip. On the contrary, in a double-locking mechanism, the femoral head is assembled within the polyethylene liner with a slotted polyethylene ring. The inner metal ring expands to lock the polyethylene liner within the metal shell, while the outer metal ring secures the polyethylene liner within the metal shell.

The second type of dissociation arises when the polyethylene liner of the prosthesis wears out. Fixed varus position of the outer head of the prosthesis can cause damage to the locking mechanism, resulting in component separation between the polyethylene and the inner head. Osteophyte growth and granular proliferation around the osteoarthritic acetabulum, as well as acetabular cartilage loss, are related with varus position of the outer head. By causing impingement on the femoral stem neck and inducing dislodgment of the inner locking ring, these variables may exacerbate wear on the beveled rim of the bearing insert [15]. The use of a skirted femoral head component with a decreased head-to-neck diameter ratio may compromise the prosthetic range of motion,

thus contributing to polyethylene wear [16]. Ito et al reported a case of bilateral bipolar heads disassembly caused by a combination of impingement and smaller oscillation angle using skirted femoral heads [17].

Hasegawa et al. described three types of dissociation based on the location of the locking ring in a series of seven cases of bipolar prosthesis dissociation due to marked polyethylene wear: type I, where the locking ring is loosened but the femoral ball is not

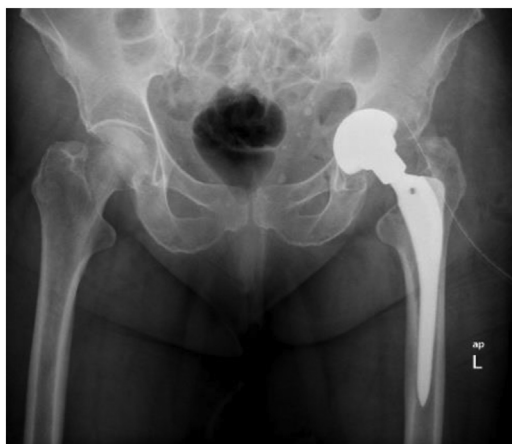

Figure 4. Postoperative anteroposterior radiograph after conversion of the bipolar hemiarthroplasty to total hip arthroplasty.

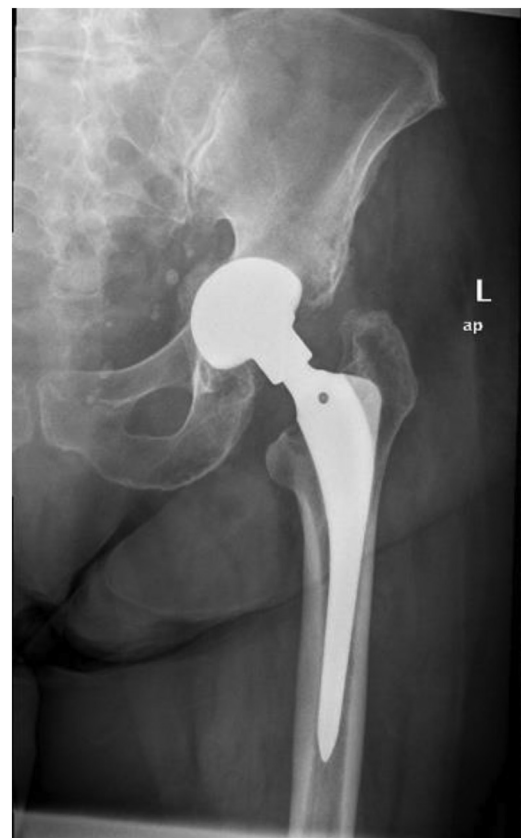

Figure 5. Anteroposterior radiograph of the left hip at 1-month follow-up after conversion to a total hip arthroplasty.

Table 1
Recently published cases of dissociation of bipolar hip hemiarthroplasty.

Article	Patients no.	Mechanism of injury	Time from surgery	Type of injury
Georgiou et al.	5 patients (1 male, 4 females)	Mobilization out of bed Fall from standing height Sitting up from chair Kneeling Chronic onset of pain	7 wk 10 y 1 mo 3 y 2 mo	One patient with posterior dislocation and simultaneous dissociation Two patients with posterior dislocation and component dissociation during reduction maneuver Two patients with spontaneous dissociation
Sevinç HF.	2 patients (1 male, 1 female)	Fall from standing height	10 mo Undefined	One patient with component dissociation One patient with posterior dislocation and component dissociation during reduction maneuver
Moriarity et al.	1 female	Fall from standing height	4 wk	Posterior dislocation and simultaneous dissociation
Chau et al.	1 female	Spontaneous hip pain with no history of falling	5 y	Spontaneous dissociation
H.H. Lee et al.	1 female	Fall from a chair	10 years	Component dissociation
Hasegawa et al.	6 patients (5 females, 1 male—7 hips)	Mild hip pain with no history of falling	7.5 y (range between 4.8 and 9.2 y)	Spontaneous dissociation failure of a self-centering locking system due to polyethylene wear
Saini MK et al.	1 male	Mobilization out of bed	3 wk	Posterior dislocation and component dissociation during reduction maneuver
Bian et al.	4 patients (3 females, 1 male)	Mobilization on the bed Falling off the bed Sitting up from chair Fall from standing height	2 d 9 d 6 wk 4 wk	Three patients with posterior dislocation and component dissociation during reduction maneuver One successful reduction with the “push-turnover-pull” maneuver
Lee et al.	7 patients (2 males, 5 females)	Undefined	4.4 mo (range between 2 wk and 33 mo)	Disassembly of the components during reduction maneuver in patients with posterior dislocation
Uruc et al.	5 patients (2 males, 3 females)	Climbing stairs Wearing shoes Mobilization out of bed Walking	3 mo 3 mo 6 wk 2 mo	Two patients with spontaneous dissociation Three patients with posterior dislocation and component dissociation during reduction maneuver

dislocated; type II, where the locking ring is loosened and the inner femoral head is dislocated; and type III, where the inner femoral head is dislocated but locking ring remains attached to the outer cup [18]. The third type of disassembly, also known as spontaneous type, is extremely unusual and is caused by inter-acetabular dislocation due to a breakdown of the locking mechanism. The inner head dislocates posteriorly, while the outer head remains in place.

Our case is a type II dissociation of a bipolar hemiarthroplasty due to polyethylene wear and locking ring failure that occurred 10 years after initial intervention. Osteoarthritic changes of the acetabulum lead to a varus position of the outer head, causing impingement on the femoral stem neck and wear on the polyethylene ring. Intraoperatively, the polyethylene locking ring was found detached from the insert and with significant wear, causing the bipolar shell to separate from the polyethylene insert. This was a category II locking mechanism failure, according to Hasegawa et al. No attempt for closed reduction was performed, and the patient underwent conversion to total hip arthroplasty.

There is no statistically significant difference in conversion rates between unipolar and bipolar hemiarthroplasty [19]. Meanwhile, conversion to total hip arthroplasty after a failed bipolar hemiarthroplasty can provide pain relief and improved function, with perioperative complications similar to those observed following revision total hip arthroplasty [20].

We do not use bipolar hemiarthroplasties in our everyday practice. However, due to the risk of acetabular erosion after bipolar hemiarthroplasties, we would recommend a follow-up period according to the protocols applied for patients undergoing total hip arthroplasty.

Summary

Component dissociation is a rare occurrence after a bipolar hemiarthroplasty. Even though there is a strong connection between disassembly and reduction maneuvers of a dislodged prosthesis, the underlying mechanisms remain elusive. Strict adherence to surgical technique during the initial operation as well as

particular caution after closed reduction maneuvers of a displaced bipolar hemiarthroplasty may improve component security.

Conflicts of interest

The authors declare there are no conflicts of interest.

For full disclosure statements refer to <https://doi.org/10.1016/j.artd.2022.05.003>.

Informed patient consent

The author(s) confirm that informed consent has been obtained from the involved patient(s) or if appropriate from the parent, guardian, power of attorney of the involved patient(s); and, they have given approval for this information to be published in this article.

References

- [1] Lestrangle NR. Bipolar arthroplasty for 496 hip fractures. *Clin Orthop Relat Res* 1990;251:7–19.
- [2] LaBelle LW, Colwill JC, Swanson AB. Bateman bipolar hip arthroplasty for femoral neck fractures. A five- to ten-year follow-up study. *Clin Orthop Relat Res* 1990;251:20–5.
- [3] Calder SJ, Anderson GH, Jagger C, Harper WM, Gregg PJ. Unipolar or bipolar prosthesis for displaced intracapsular hip fracture in octogenarians: a randomised prospective study. *J Bone Joint Surg Br* 1996;78:391–4.
- [4] Ng DZ, Lee KB. Unipolar versus bipolar hemiarthroplasty for displaced femoral neck fractures in the elderly: is there a difference? *Ann Acad Med Singap* 2015;44:197–201.
- [5] Yang B, Lin X, Yin XM, Wen XZ. Bipolar versus unipolar hemiarthroplasty for displaced femoral neck fractures in the elder patient: a systematic review and meta-analysis of randomized trials. *Eur J Orthop Surg Traumatol* 2015;25:425–33.
- [6] Filippo M, Driessen A, Colarossi G, Quack V, Tingart M, Eschweiler J. Bipolar versus monopolar hemiarthroplasty for displaced femur neck fractures: a meta-analysis study. *Eur J Orthop Surg Traumatol* 2020;30:401–10.
- [7] Varley J, Parker MJ. Stability of hip hemiarthroplasties. *Int Orthop* 2004;28:274–7.
- [8] Barmada R, Mess D. Bateman hemiarthroplasty component disassembly. A report of three cases of high-density polyethylene failure. *Clin Orthop Relat Res* 1987;224:147–9.

- [9] Herzenberg JE, Harrelson JM, Campbell 2nd DC, Lachiewicz PF. Fractures of the polyethylene bearing insert in Bateman bipolar hip prostheses. *Clin Orthop Relat Res* 1988;228:88–93.
- [10] Guo JJ, Yang H, Yang T, Tang T. Disassembly of cemented bipolar prosthesis of the hip. *Orthopedics* 2008;31:813.
- [11] Saini MK, Reddy NR, Reddy PJ. Disassembly of components of a monoblock bipolar hip prosthesis following dislocation: a case report and review on "bottle opener effect". *J Orthop Case Rep* 2020;10:90–3.
- [12] Georgiou G, Siapkara A, Dimitrakopoulou A, Provelengios S, Dounis E. Dissociation of bipolar hemiarthroplasty of the hip after dislocation. A report of five different cases and review of literature. *Injury* 2006;37:162–8.
- [13] Bian YY, Wang LC, Xiao K, Jin J, Zhang BZ, Weng XS. Hip dislocation and femoral component disassembly after bipolar hemiarthroplasty: a report of four cases and introduction of new reduction maneuvers. *Chin Med J (Engl)* 2019;132:370–2.
- [14] Lee YK, Park CH, Ha YC, Koo KH. What is the frequency of early dissociation of bipolar cups and what factors are associated with dissociation? *Clin Orthop Relat Res* 2018;476:1585–90.
- [15] Lee HH, Lo YC, Lin LC, Wu SS. Disassembly and dislocation of a bipolar hip prosthesis. *J Formos Med Assoc* 2008;107:84–8.
- [16] Chen PY, Wu CT, Hou CH, Hou SM. Loosening of total hip arthroplasty with a prosthesis employing a skirted femoral head. *J Formos Med Assoc* 2005;104:370–3.
- [17] Ito J, Takakubo Y, Momma R, Oki H, Sasaki K, Takagi M. Disassembly of bilateral bipolar heads within 10 years after hip hemiarthroplasties for avascular necrosis of femoral heads: a case report. *Mod Rheumatol Case Rep* 2020;4:147–51.
- [18] Hasegawa M, Sudo A, Uchida A. Disassembly of bipolar cup with self-centering system: a report of seven cases. *Clin Orthop Relat Res* 2004;425:163–7.
- [19] Alazzawi S, Sprenger De Rover WB, Brown J, Davis B. The conversion rate of bipolar hemiarthroplasty after a hip fracture to a total hip arthroplasty. *Clin Orthop Surg* 2012;4:117–20.
- [20] Diwanji SR, Kim SK, Seon JK, Park SJ, Yoon TR. Clinical results of conversion total hip arthroplasty after failed bipolar hemiarthroplasty. *J Arthroplasty* 2008;23:1009–15.