

Unilateral Cleft Lip Repair: Technical Maneuvers to Achieve Vermilion and Mucosal Height

Sarah N. Chiang, BS
Ema Zubovic, MD
Gary B. Skolnick, MBA
Kamlesh B. Patel, MD, MSc

Background: Patients with unilateral cleft lip often require secondary procedures due to asymmetric fullness or deficiencies along the mucosal free margin of the upper lip. Here, we describe our technique for mucosal advancement and repair to attain symmetry.

Methods: Maneuvers to obtain vermilion and mucosal height include (1) use of a tailored vermilion flap; (2) supraperiosteal release of the lesser segment; (3) back-cut “poker incision” to mobilize the mucosal flap on the lesser segment; (4) transverse release of mucosa across the greater segment; (5) accurate reduction along vermilion-mucosal junction; and (6) bilateral medial mucosal advancement. To examine postoperative outcomes, photographic data were available for 14 patients with unilateral complete cleft lip. The Cleft Lip Component Symmetry Index was then calculated as a ratio of upper lip height on cleft to noncleft sides, where an index of 1 indicates symmetry.

Results: Sixteen consecutive patients underwent unilateral cleft lip repair with this technique over a 3-year period, none of whom have required secondary operations. The symmetry index for 14 of 16 patients was 1.02 ± 0.11 (95% confidence interval [0.96, 1.08], $P = 0.56$), demonstrating satisfactory upper lip symmetry.

Conclusions: Postoperative asymmetry after unilateral cleft lip repair, particularly along the free margin, continues to be a common problem, necessitating secondary procedures. The technique of mucosal repair merits more careful attention than it has previously received, and here we describe in detail a method that has allowed for improved symmetry. (*Plast Reconstr Surg Glob Open* 2022;10:e4125; doi: 10.1097/GOX.0000000000004125; Published online 17 February 2022.)

INTRODUCTION

Since Millard's first description of rotation-advancement repair,¹ the focus of cleft lip repair has overwhelmingly been on achieving sufficient and symmetric cutaneous lip height. Millard noted, however, that the vermilion was often asymmetric as well, requiring a secondary operation to add fullness to the cleft side.¹ It was not until years later that vermilion height was taken into consideration as an important component of primary lip repair in an effort to reduce reoperations. Despite evolution in techniques for both cutaneous lip and vermilion repair, many repairs continue to result in asymmetry and

secondary procedures, particularly along the mucosal free margin of the upper lip (Fig. 1).²

The mucosal component of cleft lip repair plays an important role in achieving symmetry and fullness, but it has yet to be illustrated and adequately described in a reproducible manner. A recent literature review revealed that just 33% of articles detailing techniques of cleft lip repair directly address mucosal reapproximation.³ In his initial articles, Millard merely mentions the use of posterior vertical mucosal flaps, specifying only that mucosal closure was adjusted on a case-by-case basis and could vary widely.^{1,4,5} Noordhoff noted that the mucosal closure is crucial to giving the lip its pout, and the majority of subsequent techniques take similar approaches to the mucosa, only dedicating a few sentences to its importance.⁶⁻⁸

In this work, we aimed to describe and illustrate a technique for mucosal repair to obtain mucosal and vermilion height. This technique allows for overall improved symmetry of the lip, particularly in addressing inconsistent fullness or deficiencies along the free margin of the upper lip.

From the Division of Plastic and Reconstructive Surgery, Department of Surgery, Washington University School of Medicine, St Louis, Mo.

Received for publication December 3, 2021; accepted December 10, 2021.

Copyright © 2022 The Authors. Published by Wolters Kluwer Health, Inc. on behalf of The American Society of Plastic Surgeons. This is an open-access article distributed under the terms of the Creative Commons Attribution-Non Commercial-No Derivatives License 4.0 (CCBY-NC-ND), where it is permissible to download and share the work provided it is properly cited. The work cannot be changed in any way or used commercially without permission from the journal.

DOI: 10.1097/GOX.0000000000004125

Disclosure: KBP is a consultant for Stryker CMF. The authors have no financial interest to declare in relation to the content of this article. No funding was received for this article.

PATIENTS AND METHODS

Consecutive patients with unilateral complete cleft lip underwent cleft lip repair by the senior author at a single tertiary care academic center from 2018 to 2021. Surgery was typically performed at 5 months of age using a rotation-advancement technique, with modifications as described by Mulliken, in combination with a tailored vermilion flap to address medial vermilion height deficiency.^{2,9,10} Primary nasal repair was done at the time of lip repair using a semi-open approach, with placement of domal and intercartilaginous sutures under direct vision as previously described.¹¹ Centralization of the anterior caudal margin of the septum and release of the tail of the cleft side lateral crus in a V-Y fashion was performed before approximation of the domes.¹²⁻¹⁴

Surgical Technique: Tailored Vermilion Flap

The red line is marked on the greater and lesser lip segments, at the junction of keratinized mucosa (vermilion) and nonkeratinized mucosa.¹⁵ Point A is marked at the peak of Cupid's bow on the greater segment, closest to the cleft (Fig. 2). To ensure appropriate cutaneous height, point a is defined as the point on the lesser segment lip border, whose distance to the cleft side subalare (sbal') is equal to the distance from the noncleft side subalare (sbal) to crista philtri inferioris (cphi).¹⁶ Lip length and vermilion height are also taken into account when positioning point a.

Points B and C are marked on the red line of the greater segment. Point B is marked below Cupid's peak (point A). Point C is marked where the vermilion begins to taper.¹⁷ Point b is identified on the lesser segment where vermilion height on the greater (A-B) and lesser (a-b) lip segments are equal. Point c is chosen to ensure recruitment of vermilion length (b-c) to fill the deficiency in the greater segment (B-C). On the lesser lip segment, the incision is carried from point b on the red line directly into the vestibule through point c (Fig. 2). In contrast to the Noordhoff vermilion flap, which utilizes a pennant triangle, this incision extends directly down into the vestibule in a straight line without a pennant triangle.¹⁰ This creates a robust segment of vermilion from the cleft side to fill in the medial deficiency, rather than a narrow triangle. This design forces the vermilion and mucosal fullness to be midline rather than paramedian,

Takeaways

Question: Does the technique of mucosal release and closure affect symmetry after unilateral cleft lip repair?

Findings: We describe our technique for mucosal closure during cleft lip repair that has been used in 16 patients to date, none of whom have required revision surgeries. Upper lip measurements showed a cleft-to-noncleft vermilion lip height ratio of 1.02 (95% CI 0.96–1.08), indicating satisfactory symmetry.

Meaning: The technique of mucosal repair merits more careful attention than it has previously received, and here we describe in detail a method that has allowed for good symmetry.

which is the primary benefit of the tailored vermilion flap. Furthermore, maintaining the vermilion flap as a single unit without a pennant triangle results in better blood supply and more facile closure, especially if a longer flap is needed to fill a medial vermilion deficiency extending past midline.

Surgical Technique: Mucosal Advancement

Recruitment of mucosa along the cleft margin is facilitated by supraperiosteal release on the cleft side and transverse release of the mucosa across the frenulum on the greater segment.⁸ This bilateral release and advancement markedly increases the mucosal height (Fig. 3). On the lesser segment, a backcut "poker incision" is made to mobilize the mucosal flap (Figs. 4, 5).¹ Care is taken to avoid the parotid duct. Tissue is recruited from the greater and lesser segments, and closure is performed with interrupted 4-0 chromic suture (Ethicon, Inc., Somerville, N.J.) (Fig. 6A). A reduction maneuver is performed to approximate the red line, and points C and c are brought together with 5-0 chromic (Ethicon, Inc., Somerville, N.J.). This dictates how the mucosal flaps are approximated and the amount of medial advancement required from each side. No specific points are marked on the mucosa for approximation of the greater and lesser segments, and any excess mucosa is trimmed as needed. The inset of the vermilion is performed with 7-0 chromic (Ethicon, Inc., Somerville, N.J.) (Fig. 6B).

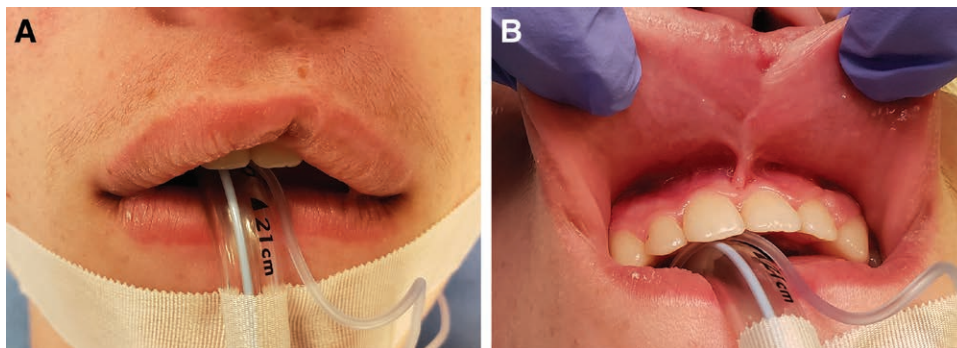


Fig. 1. Appropriate cutaneous lip height, but deficiency in vermilion height. A, external view. B, intraoral view demonstrating mucosal scar band with deficiency in mucosal height.

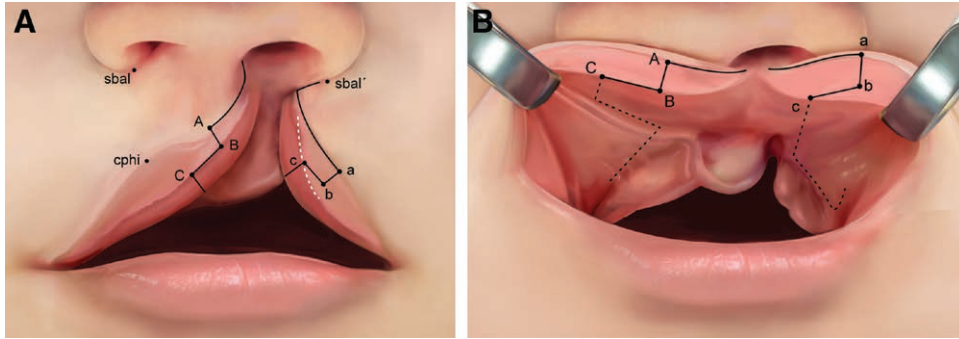


Fig. 2. Vermilion markings. Point A is the peak of the cleft side Cupid's bow. Points B and C are marked on the red line of the lip, below the Cupid's bow peak (point B) and when the vermilion starts to taper (point C). Point b is placed such that segments A-B and a-b are equidistant to ensure symmetric vermilion height. Point c is placed on the lesser segment red line, where B-C equals b-c. A, External view of preoperative markings. B, Intraoral view of markings and planned incisions.

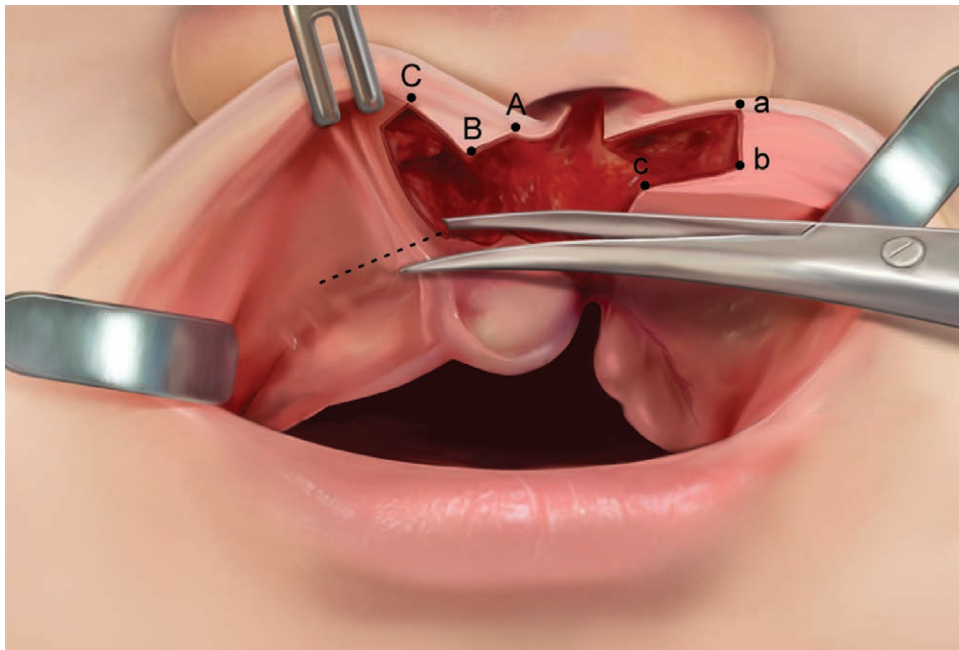


Fig. 3. Transverse mucosal release across frenulum.

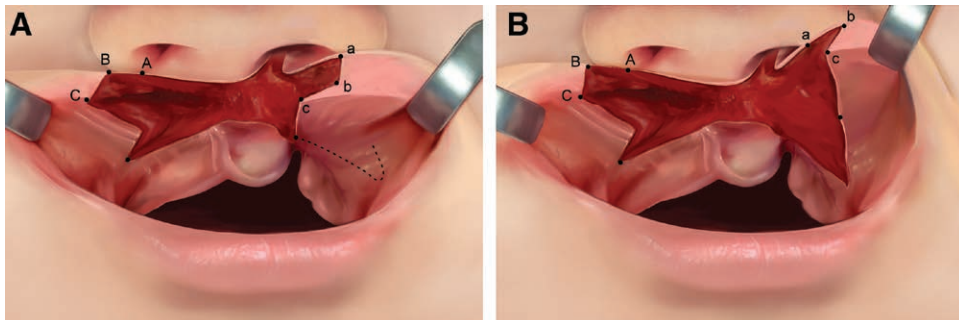


Fig. 4. Lesser segment mucosal incisions with backcut "poker incision," allowing for mucosal advancement from the lesser segment. A, Planned incision, dashed line. B, Appearance after mucosal incisions are complete.

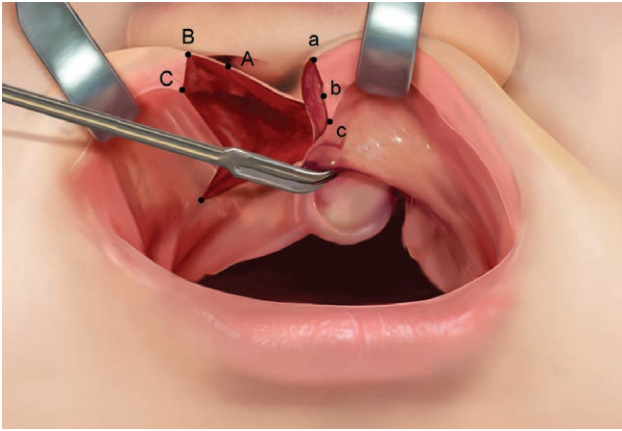


Fig. 5. Mobilization of the mucosal flap.

Postoperative Outcomes

Symmetry was compared using the Cleft Lip Component Symmetry Index (CLCSI), a ratio of measurements on the cleft side to the noncleft side; here we focus on the vermilion and mucosal height.¹⁸ The CLCSI was calculated using measurements from three-dimensional or two-dimensional photographs taken at a mean of 314 days postoperatively (range 52–1121 days). Three-dimensional photographs were taken at routine follow-up visits for seven patients. Vultus software (version 2.7.2; 3dMD, Atlanta, Ga.) was utilized to orient the images to the Frankfort horizontal, defined as the plane created by the left inferior orbital rim and the superior margin of the external auditory meatus bilaterally. Vermilion lip height was then defined as vertical distance from cphi to the free margin of the lip (fm), measured on cleft and noncleft sides (Fig. 7). The ratio of cleft to noncleft vermilion lip height was then calculated. In two-dimensional images obtained from caregivers from the remaining patients, the image was aligned horizontally utilizing the inferior orbital rim bilaterally. Vermilion lip height CLCSI was calculated as above, utilizing ImageJ software (version 1.53j; National Institutes of Health, Bethesda, Md.).

Numerical data are reported as means \pm SDs. Measurements were repeated by the same observer, and the mean of these two observations was used in subsequent analyses. To confirm reliability of measurements, an average measures intra-class correlation coefficient was

calculated based on the two-way mixed effects model.¹⁹ A one-sample *t*-test was conducted to determine if the CLCSI was significantly different from 1 (perfect symmetry), with a significance level of $\alpha = 0.05$. Measurements are considered asymmetric if they are greater than 1.05 (excessive) or less than 0.95 (deficient).¹⁸ All statistical analyses were performed utilizing SAS Studio software (version 3.8; SAS Institute Inc., Cary, N.C.).

RESULTS

Our technique of mucosal closure has been utilized for 16 patients with unilateral complete cleft lip, with or without cleft palate, with mean follow-up of 360 days (range 107–1040; one participant moved away after repair and did not follow up at our institution). On average, patients were 5.6 ± 0.96 months of age at operation. No secondary procedures have been required during the study period. One patient was found at 18 months postoperatively to have some excess fullness along the free margin, with a CLCSI of 1.24; however, the family was not concerned, and no revision has been scheduled at this time.

Photographs were available for 14 of 16 patients (88%); the remaining patients could not be contacted. The mean CLCSI was 1.02 ± 0.11 (95% confidence interval [0.96, 1.08]), with no statistically significant difference from the ideal value of 1 ($P = 0.56$). The mean absolute difference in height between cleft and noncleft sides was 0.30 ± 0.35 mm, calculated from 3D photographs only ($n = 7$). The intra-class correlation coefficient was 0.53, indicating good intra-rater reliability when measuring lip height.

DISCUSSION

Despite the myriad described techniques for repair of unilateral cleft lip, postoperative asymmetry—particularly along the free margin—continues to be a common problem necessitating correction with secondary procedures.²⁰ The technique of mucosal repair merits more careful attention than it has previously received, as an uneven mucosal and/or vermilion height can lead to both deficiency and excess in the lip, resulting in dryness and aesthetically displeasing asymmetry (Fig. 1).²¹ Here we describe in detail a mucosal repair technique that has allowed for improved symmetry, decreasing the need for secondary procedures.

Overall lip revision rates have been reported between 12% and 57% of patients with unilateral cleft lip.^{2,20,22} In

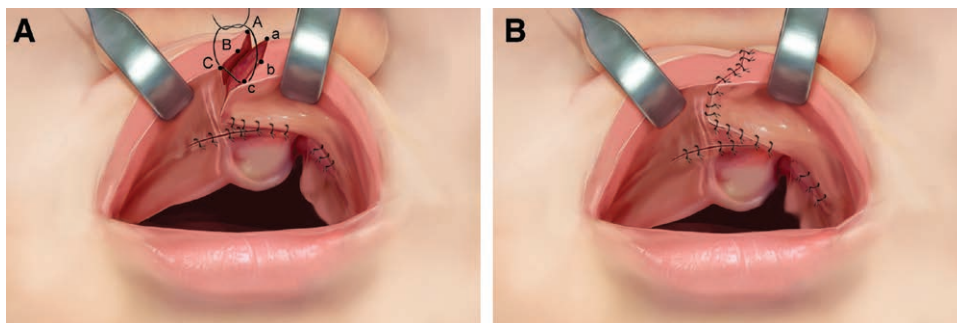


Fig. 6. Closure of incisions after mobilization of the mucosal flap. Mucosal height is increased, as shown by the increased distance from point c to the vestibule. A, Mucosal backcut closure. B, Vermilion closure.

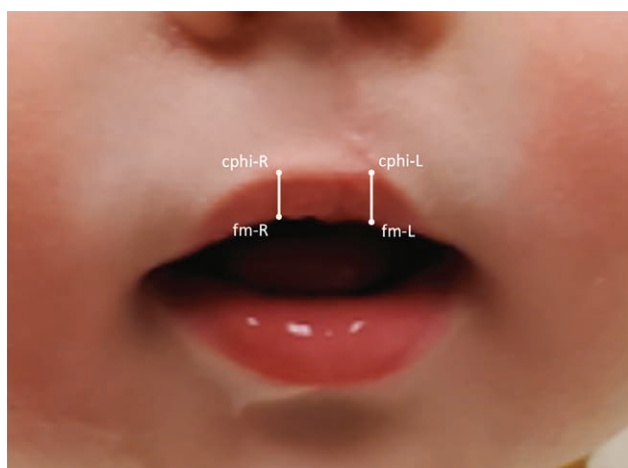


Fig. 7. Measurements for the calculation of the CLCSI of lip height postoperatively. cphi, crista philtri inferioris; fm, free margin of lip.

many cases requiring secondary procedures, the problems are not only asymmetry in cutaneous or mucosal lip height, but also exposure of nonkeratinized mucosa. For example, vermilion discontinuity has been cited as a common deformity for which a Z-plasty can be performed at the vermilion-mucosal junction to return nonkeratinized mucosa to the interior of the oral cavity.²¹ Importantly, exposed mucosa poses not only an aesthetic problem, but it can also lead to discomfort, dryness, crusting, and bleeding.^{23,24} Noordhoff therefore describes a technique of primary repair that takes vermilion height into account to achieve better symmetry, which involves the addition of a vermilion triangular flap to augment the medial vermilion.¹⁰ Mulliken also incorporated a lateral triangular flap of vermilion into his repair, while Zuker described a similar diamond-shaped flap for the same purpose.^{2,25} Powar et al precisely measured the vermilion deficiency to design a tailored vermilion flap, with the goal of avoiding the asymmetric bulge created by a triangular vermilion flap.⁹

Mulliken reported that 27% of his patients underwent secondary procedures to correct asymmetry along the mucosal free margin, specifically excess fullness at the lateral mucosal border and corresponding deficiency of the median tubercle.² There is a general consensus that mucosa from the lesser segment must be advanced to the cleft to provide fullness. Tse and colleagues identified that the noncleft alar base is displaced laterally, while the cleft alar base is normal in position from midline.²⁶ In their foundation-based approach, they noted the impact of muscle sill, floor, sidewall, and septum repair on nasal correction.¹³ In our observation, noncleft alar base correction also involves medialization of mucosa from the greater segment. To attain mucosal height, mucosa must be recruited from both lesser and greater segments, with the aim of inseting the flaps in the midline to avoid asymmetric fullness along the free margin.

Challenges in mucosal repair are frequently absent from published techniques of primary cleft lip repair, and just one-third of recent publications specifically address mucosal reapproximation, of which very few dedicate more than a few sentences.^{3,21} Here, we illustrate our

technique for mucosal repair in patients with unilateral cleft lip. No revisions were required with the implementation of this technique. In the 5 years before transitioning to the described method, two of 24 patients required revisions due to increased fullness at the free margin of the lip. One patient for whom this technique was used was found to have increased fullness along the free margin at 18 months postoperatively. We believe this likely resulted from inadequate removal of mucosa along the greater segment, as the initial mucosal incision from point C should be perpendicular to the vermilion to allow for appropriate inset of the tailored vermilion flap from the lesser segment.

In conclusion, precision in mucosal and vermilion repair during primary cleft lip repair merits more careful attention than it has previously received. The advantages of this technique include its simplicity and reproducibility in obtaining symmetry in vermilion and mucosal height, reducing the need for secondary procedures after unilateral cleft lip repair.

Kamlesh B. Patel, MD, MSc

Division of Plastic and Reconstructive Surgery

Department of Surgery

Washington University School of Medicine

660 South Euclid Avenue, Northwest Tower

Suite 1150, Campus Box 8238

St. Louis, MO 63110

E-mail: kamlesh.patel@wustl.edu

ACKNOWLEDGMENT

The authors thank Ms. Cora Brown of Core BioVisuals for her work on the illustrations presented here.

REFERENCES

1. Millard DR. *Cleft Craft: The Evolution of its Surgery*. Vol 1. Boston, MA: Little, Brown; 1976.
2. Mulliken JB, Martínez-Pérez D. The principle of rotation advancement for repair of unilateral complete cleft lip and nasal deformity: technical variations and analysis of results. *Plast Reconstr Surg*. 1999;104:1247–1260.
3. Taub PJ, Piccolo P. Cleft lip repair: through the looking glass. *J Craniofac Surg*. 2016;27:2031–2035.
4. MILLARD DR Jr. Refinements in rotation-advancement cleft LIP technique. *Plast Reconstr Surg*. 1964;33:26–38.
5. Stal S, Brown RH, Higuera S, et al. Fifty years of the Millard rotation-advancement: looking back and moving forward. *Plast Reconstr Surg*. 2009;123:1364–1377.
6. Noordhoff MS, Chen Y-R, Chen K-T, et al. The surgical technique for the complete unilateral cleft lip-nasal deformity. *Operative Techniques in Plastic and Reconstructive Surgery*. 1995;2:167–174.
7. Chait L, Kadwa A, Potgieter A, et al. The ultimate straight line repair for unilateral cleft lips. *J Plast Reconstr Aesthet Surg*. 2009;62:50–55.
8. Chong DK, Swanson JW. The essential anatomical subunit approximation unilateral cleft lip repair. *Plast Reconstr Surg*. 2016;138:91e–94e.
9. Powar RS, Kumar NV, Das R. A new tailored technique of vermilion repair in unilateral cleft lip. *J Plast Reconstr Aesthet Surg*. 2013;66:896–899.
10. Noordhoff MS. Reconstruction of vermilion in unilateral and bilateral cleft lips. *Plast Reconstr Surg*. 1984;73:52–61.
11. Patel KB, Mulliken JB. Correction of the vestibular web during primary repair of unilateral cleft lip. *Plast Reconstr Surg*. 2014;134:600e–607e.

12. Stenström SJ. The alar cartilage and the nasal deformity in unilateral cleft lip. *Plast Reconstr Surg.* 1966;38:223-231.
13. Tse RW, Mercan E, Fisher DM, et al. Unilateral cleft lip nasal deformity: foundation-based approach to primary rhinoplasty. *Plast Reconstr Surg.* 2019;144:1138-1149.
14. Ridgway EB, Andrews BT, Labrie RA, et al. Positioning the caudal septum during primary repair of unilateral cleft lip. *J Craniofac Surg.* 2011;22:1219-1224.
15. Mommaerts MY. Cleft lip vermilion: below the red line. *Br J Oral Maxillofac Surg.* 2018;56:561-562.
16. Tse R. Reply: unilateral cleft lip repair using the anatomical subunit approximation: modifications and analysis of early results in 100 consecutive cases. *Plast Reconstr Surg.* 2015;136:855e-857e.
17. Fisher DM. Unilateral cleft lip repair: an anatomical subunit approximation technique. *Plast Reconstr Surg.* 2005;116:61-71.
18. Tangco I, Bhandari K, Yao CF, et al. Unilateral cleft lip repair using the Chang Gung technique: an outcome analysis. *Ann Plast Surg.* 2021;86(2S Suppl 1):S41-S45.
19. Koo TK, Li MY. A guideline of selecting and reporting intraclass correlation coefficients for reliability research. *J Chiropr Med.* 2016;15:155-163.
20. Tan SPK, Ganske IM, Mulliken JB. Nasolabial revisions in unilateral incomplete cleft lip: one surgeon's 28-year experience. *Plast Reconstr Surg.* 2020;145:1477-1485.
21. Monson LA, Khechoyan DY, Buchanan EP, et al. Secondary lip and palate surgery. *Clin Plast Surg.* 2014;41:301-309.
22. Fisher DM. Discussion: the Skoog lip repair for unilateral cleft lip deformity: the Uppsala experience. *Plast Reconstr Surg.* 2018;141:1234-1236.
23. Powar RS, M Patil S, Kleinman ME. A geometrically sound technique of vermilion repair in unilateral cleft lip. *J Plast Reconstr Aesthet Surg.* 2007;60:422-425.
24. Yotsuyanagi T, Yamashita K, Yamauchi M, et al. New technical method to correct secondary vermilion deformities with cleft lip. *J Plast Reconstr Aesthet Surg.* 2018;71:1810-1815.
25. Gur E, Zuker RM. The diamond vermilion flap—a new technique for vermilion augmentation in cleft lip repair. *Cleft Palate Craniofac J.* 2000;37:123-124.
26. Tse RW, Knight R, Oestreich M, et al. Unilateral cleft lip nasal deformity: three-dimensional analysis of the primary deformity and longitudinal changes following primary correction of the nasal foundation. *Plast Reconstr Surg.* 2020;145:185-199.