



Case Study

Non-surgical relief of cervical radiculopathy through reduction of forward head posture and restoration of cervical lordosis: a case report

BRET M. WICKSTROM, DC¹⁾, PAUL A. OAKLEY, MSc, DC^{2)*}, DEED E. HARRISON, DC³⁾

¹⁾ Private Practice, USA

²⁾ Private Practice: 11A-1100 Gorham Street, Newmarket, ON, L3Y 8Y8, Canada

³⁾ CBP NonProfit, Inc., USA

Abstract. [Purpose] To present a case demonstrating the relief of cervical radiculopathy following the dramatic reduction of forward head posture and restoration of the cervical lordosis by use of a multi-modal rehabilitation program incorporating cervical extension traction. [Subject and Methods] A 31-year-old male patient presented with severe cervical radiculopathy and muscle weakness as well as neck pain. The patient had limited neck range of motion, and multiple positive orthopedic tests. Radiography revealed excessive forward head posture with a cervical kyphosis. [Results] The patient received a multi-modal rehabilitation protocol including mirror image extension exercises, cervical extension traction, and spinal manipulative therapy. After forty treatments over 17 weeks, the patient reported a complete resolution of radiculopathy and significant improvement in neck pain level. Post radiography demonstrated correction of the spine and posture alignment. The patient remained well and maintained corrected posture with limited treatment one year later. [Conclusion] Our case demonstrates the relief of cervical radiculopathy resulting from the non-surgical correction of forward head posture and cervical kyphosis.

Key words: Rehabilitation, Cervical kyphosis, Radiculopathy

(This article was submitted Feb. 22, 2017, and was accepted May 9, 2017)

INTRODUCTION

The cervical lordosis has been demonstrated to occur as early as 7.5–9 weeks in utero¹⁾ and should be considered more a primary, rather than a secondary curve of the spine. A reversal of the cervical lordosis—a kyphosis, is abnormal and associated with a barrage of symptoms, including neck pain, headache, and radiculopathy^{2, 3)}.

The correction of cervical lordosis by surgical means has been the procedure of choice for cervical radiculopathy for many years^{4, 5)}. Traditional physiotherapy approaches in the treatment of patients with cervical radiculopathy have not proven to be more effective than surgical approaches⁶⁾, and as a stand-alone treatment has been shown to be no better than wearing a neck brace⁷⁾. Physiotherapy approaches in treating this disorder must improve; one means is for the non-surgical restoration of cervical lordosis.

The restoration of cervical lordosis by non-surgical means has been established in the manual therapy literature^{8–11)}, and recently it has been shown to be effective in treating patients suffering from cervical radiculopathy¹¹⁾. This new approach in the non-surgical treatment of cervical radiculopathy mirrors the achievement of surgical fusion for successful treatment of patients suffering with radiculopathy; that is, by re-establishing the cervical lordosis—only not surgically, but by extension traction¹¹⁾. This case presents the successful reduction in right arm radicular symptoms in a 31-year-old male by improving posture through use of a multi-modal rehabilitation program incorporating cervical extension traction. This case is novel as it demonstrates a dramatic correction in head and neck alignment in a short period of time, and was maintained at a years' follow up.

*Corresponding author. Paul A. Oakley (E-mail: docoakley.icc@gmail.com)



©2017 The Society of Physical Therapy Science. Published by IPEC Inc.

This is an open-access article distributed under the terms of the Creative Commons Attribution Non-Commercial No Derivatives (by-nc-nd) License. (CC-BY-NC-ND 4.0: <http://creativecommons.org/licenses/by-nc-nd/4.0/>)

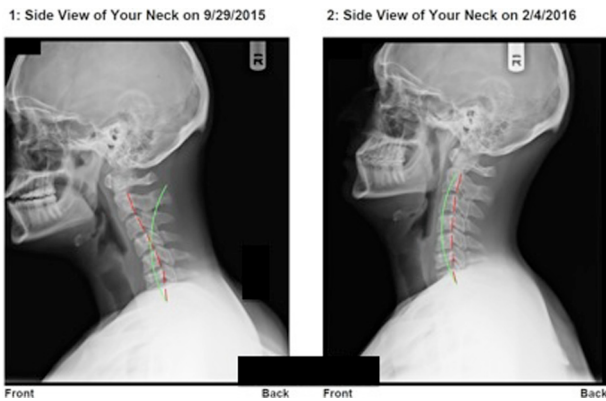


Fig. 1. Lateral cervical radiographs
Left: Initial taken on 9/29/15. Right: Follow-up taken on 2/4/16.
Green line indicates normal alignment; Red line indicates patient

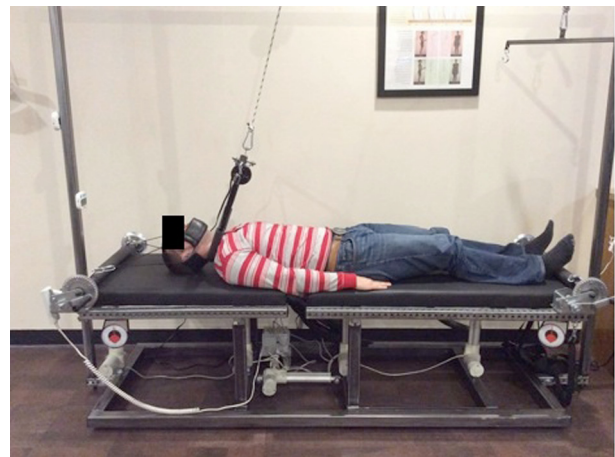


Fig. 2. Cervical extension traction set-up

SUBJECT AND METHODS

On September 28, 2015, a 31-year-old male presented with a chief complaint of right upper arm weakness and neck pain, both a 6/10 (0=no pain; 10=worst pain ever). The patient scored a 46% on the neck Bournemouth questionnaire (NBQ)¹²⁾ and had reduced mobility in the neck and multiple positive cervical orthopedic tests.

Cervical spine antero-posterior and lateral radiographic images were taken, then digitized and analyzed using the PostureRay system (New Port Richey, FL, USA). This system uses the Harrison posterior tangent method for lateral spine images^{13, 14)}, and the modified Riser-Ferguson method for AP spine images¹⁴⁾. These measurement methods are repeatable and reliable¹³⁻¹⁵⁾. The patient had excessive forward head posture (FHP), measured to be 49 mm, and a cervical kyphosis of +16° (normal lordosis is -31°- -42°^{16, 17)}) (Fig. 1). Patient was diagnosed with right cervical radiculopathy.

The patient was treated with a structural spine rehabilitation protocol¹⁸⁻²⁰⁾ at a frequency of 2-3 times a week, totaling 40 treatments over 17-weeks. Treatment consisted of cervical extension exercises, cervical extension traction and spinal manipulative therapy.

Ten to fifteen repetitions of neck extension exercises were done against resistance bands (Pro-lordotic™: Circular Traction, Huntington Beach, CA, USA). The traction was done in an extension set-up designed to restore the cervical lordosis⁸⁾ (Fig. 2) and performed for 15-20 minutes each session. Home cervical extension 'Denneroll' traction was also prescribed¹¹⁾ starting at 5 minutes, progressing up to 20 minutes maximum daily. The patient was also given full-spine spinal manipulative therapy, as well as paraspinal stimulation with a hand-held instrument (Arthrostim®: Impac Inc., Salem, OR, USA). The patient gave verbal and written consent for the presentation of this case.

RESULTS

On February 4, 2016, the patient was re-examined after 40 treatment sessions (17 weeks later) and reported complete alleviation of upper arm weakness and neck pain. The patient scored a 0% on the NBQ, and had a cervical lordosis of -30.6° and a reduced forward head posture to -5.6 mm (Fig. 1). A one-year follow-up exam with minimal treatment (i.e. up to 2x/month) showed the maintenance of cervical lordosis (lordosis: -19.5°; FHP: 0.5mm), no radiculopathy and a NBQ score of 10%.

DISCUSSION

This report documents the successful outcome in a 31-year-old patient suffering from cervical radiculopathy by reducing extreme forward head posture and re-establishing the cervical lordosis.

The structural correction of cervical lordosis is an emerging evidence-based practice. Contemporary cervical spine surgical approaches attempt to preserve and/or re-establish the cervical lordosis to avoid neurologic symptoms as well as adjacent segmental disc disease. The same goals should hold true for the non-surgical re-modeling of the cervical lordosis.

Advances in non-surgical, manual techniques involving cervical extension traction have demonstrated consistency in the structural re-modeling of the cervical lordosis in symptomatic patients⁸⁻¹¹⁾. Specifically, in cervical radiculopathy patients, Moustafa et al.¹¹⁾ were able to demonstrate that patients under a multimodal physiotherapy program were only able to have lasting (1 year) symptomatic improvements if the cervical lordosis was corrected.

Re-establishing the cervical lordosis and reducing forward head posture is presumed to relieve cervical radiculopathy by decreasing the spinal canal length and thereby reducing the tension in the pons-cord neurological tissue tract²¹). Relaxation of the neural elements with a simultaneous improvement in neurological function was long ago demonstrated by the ‘cervicordodosis’ surgical procedure invented by Alf Breig in the 1970s, for many neurological illnesses²²).

Since contemporary, non-surgical methods have evolved to show consistent improvement in cervical lordosis in patients with cervical symptoms including radiculopathy, these should be practiced before resorting to surgical approaches which have potential risks including reoperation²³). Limitations to this study is that it is just a single case; we believe the results from this case warrant further study to the non-surgical approach to cervical radiculopathy.

REFERENCES

- 1) Bagnall KM, Harris PF, Jones PR: A radiographic study of the human fetal spine. 1. The development of the secondary cervical curvature. *J Anat*, 1977, 123: 777–782. [[Medline](#)]
- 2) Scheer JK, Tang JA, Smith JS, et al. International Spine Study Group: Cervical spine alignment, sagittal deformity, and clinical implications: a review. *J Neurosurg Spine*, 2013, 19: 141–159. [[Medline](#)] [[CrossRef](#)]
- 3) Bess S, Protosaltis TS, Lafage V, et al. International Spine Study Group: Clinical and radiographic evaluation of adult spinal deformity. *Clin Spine Surg*, 2016, 29: 6–16. [[Medline](#)]
- 4) Grosso MJ, Hwang R, Mroz T, et al.: Relationship between degree of focal kyphosis correction and neurological outcomes for patients undergoing cervical deformity correction surgery. *J Neurosurg Spine*, 2013, 18: 537–544. [[Medline](#)] [[CrossRef](#)]
- 5) Kawakami M, Tamaki T, Yoshida M, et al.: Axial symptoms and cervical alignments after cervical anterior spinal fusion for patients with cervical myelopathy. *J Spinal Disord*, 1999, 12: 50–56. [[Medline](#)] [[CrossRef](#)]
- 6) Engquist M, Löfgren H, Öberg B, et al.: A 5- to 8-year randomized study on the treatment of cervical radiculopathy: anterior cervical decompression and fusion plus physiotherapy versus physiotherapy alone. *J Neurosurg Spine*, 2017, 26: 19–27. [[Medline](#)] [[CrossRef](#)]
- 7) Kuijper B, Tans JT, Beelen A, et al.: Cervical collar or physiotherapy versus wait and see policy for recent onset cervical radiculopathy: randomised trial. *BMJ*, 2009, 339: b3883. [[Medline](#)] [[CrossRef](#)]
- 8) Harrison DE, Harrison DD, Betz JJ, et al.: Increasing the cervical lordosis with chiropractic biophysics seated combined extension-compression and transverse load cervical traction with cervical manipulation: nonrandomized clinical control trial. *J Manipulative Physiol Ther*, 2003, 26: 139–151. [[Medline](#)] [[CrossRef](#)]
- 9) Moustafa IM, Diab AA, Harrison DE: The effect of normalizing the sagittal cervical configuration on dizziness, neck pain, and cervicocephalic kinesthetic sensibility: a 1-year randomized controlled study. *Eur J Phys Rehabil Med*, 2017, 53: 57–71. [[Medline](#)]
- 10) Harrison DE, Cailliet R, Harrison DD, et al.: A new 3-point bending traction method for restoring cervical lordosis and cervical manipulation: a nonrandomized clinical controlled trial. *Arch Phys Med Rehabil*, 2002, 83: 447–453. [[Medline](#)] [[CrossRef](#)]
- 11) Moustafa IM, Diab AA, Taha S, et al.: Addition of a sagittal cervical posture corrective orthotic device to a multimodal rehabilitation program improves short- and long-term outcomes in patients with discogenic cervical radiculopathy. *Arch Phys Med Rehabil*, 2016, 97: 2034–2044. [[Medline](#)] [[CrossRef](#)]
- 12) Bolton JE, Humphreys BK: The Bournemouth Questionnaire: a short-form comprehensive outcome measure. II. Psychometric properties in neck pain patients. *J Manipulative Physiol Ther*, 2002, 25: 141–148. [[Medline](#)] [[CrossRef](#)]
- 13) Harrison DE, Harrison DD, Cailliet R, et al.: Cobb method or Harrison posterior tangent method: which to choose for lateral cervical radiographic analysis. *Spine*, 2000, 25: 2072–2078. [[Medline](#)] [[CrossRef](#)]
- 14) Harrison DE, Holland B, Harrison DD, et al.: Further reliability analysis of the Harrison radiographic line-drawing methods: crossed ICCs for lateral posterior tangents and modified Risser-Ferguson method on AP views. *J Manipulative Physiol Ther*, 2002, 25: 93–98. [[Medline](#)] [[CrossRef](#)]
- 15) Harrison DE, Harrison DD, Colloca CJ, et al.: Repeatability over time of posture, radiograph positioning, and radiograph line drawing: an analysis of six control groups. *J Manipulative Physiol Ther*, 2003, 26: 87–98. [[Medline](#)] [[CrossRef](#)]
- 16) Harrison DD, Harrison DE, Janik TJ, et al.: Modeling of the sagittal cervical spine as a method to discriminate hypolordosis: results of elliptical and circular modeling in 72 asymptomatic subjects, 52 acute neck pain subjects, and 70 chronic neck pain subjects. *Spine*, 2004, 29: 2485–2492. [[Medline](#)] [[CrossRef](#)]
- 17) McAviney J, Schulz D, Bock R, et al.: Determining the relationship between cervical lordosis and neck complaints. *J Manipulative Physiol Ther*, 2005, 28: 187–193. [[Medline](#)] [[CrossRef](#)]
- 18) Oakley PA, Harrison DD, Harrison DE, et al.: Evidence-based protocol for structural rehabilitation of the spine and posture: review of clinical biomechanics of posture (CBP) publications. *J Can Chiropr Assoc*, 2005, 49: 270–296. [[Medline](#)]
- 19) Harrison DE, Harrison DD, Hass JW: Structural rehabilitation of the cervical spine. Evanston, WY: Harrison CBP® Seminars, Inc., 2002.
- 20) Harrison DD, Janik TJ, Harrison GR, et al.: Chiropractic biophysics technique: a linear algebra approach to posture in chiropractic. *J Manipulative Physiol Ther*, 1996, 19: 525–535. [[Medline](#)]
- 21) Breig A: Biomechanics of the central nervous system. Almqvist & Wiksell International, 1960.
- 22) Breig A: Adverse mechanical tension in the central nervous system. Relief by functional neurosurgery. Almqvist & Wiksell International, 1978.
- 23) Zhong ZM, Zhu SY, Zhuang JS, et al.: Reoperation after cervical disc arthroplasty versus anterior cervical discectomy and fusion: a meta-analysis. *Clin Orthop Relat Res*, 2016, 474: 1307–1316. [[Medline](#)] [[CrossRef](#)]