

OPEN

First Robotic-Assisted Dual Kidney Transplant: Surgical Technique and Report of a Case With 24-month Follow-up

Mauro Frongia, MD,¹ Rossano Cadoni, MD,¹ and Andrea Solinas, MD¹

Background. Open surgery is the gold standard procedure for kidney transplantation. There is a strong rationale for using minimally invasive surgery in patients with end-stage renal disease. A robotic-assisted dual kidney transplant was performed for the first time at our institution. **Methods.** In August 2013, a 63-year-old man with end-stage renal disease and diabetes mellitus under pharmacological control received both kidneys from a 70-year-old marginal donor. Pretransplant donor biopsy demonstrated a bilateral Karpinski score greater than 5. The organs did not exhibit malformations and each had an artery and a vein. The procedure was carried out by a 7-port intraperitoneal approach using the da Vinci surgical system. The procedure was identical for the 2 kidneys except that mobilization of the sigmoid colon was required to introduce the left graft. The renal vessels were anastomosed to the left external iliac vessels. The novel aspect of the technique was the introduction of both grafts through a single, 7-cm upper midline incision. **Results.** Total operative time was 400 minutes and blood loss was 120 mL. Both grafts immediately began functioning. There were no intraoperative or postoperative complications. The patient was discharged on the seventh postoperative day with normal renal function. At 24 months, he is well and does not require hemodialysis. **Conclusions.** Minimally invasive robotic-assisted technology is a promising technique that provides exceptional patient outcomes by reducing operative morbidity, immobilization, and time to recovery, while affording better esthetic results. Selected patients with multiple comorbidities benefit most. Grafts from marginal donors are an extremely valuable resource.

(*Transplantation Direct* 2015;1: e34; doi: 10.1097/TXD.0000000000000547. Published online 13 October 2015.)

Open surgery is the gold standard procedure for kidney transplantation (KT).¹ However, minimally invasive laparoscopic and robot-assisted surgical approaches are increasingly applied and have become safe and effective alternatives to traditional techniques. An all-laparoscopic approach was first described by Rosales and colleagues² and Modi and colleagues³⁻⁵; more recently, laparoscopic robotic-assisted KT has been described by Giulianotti and colleagues,^{6,7} Boggi and coworkers,⁸ Abaza and coworkers,⁹ Menon and

coworkers,¹⁰ and Tsai and coworkers.¹¹ The main advantages of robot-assisted techniques are smaller incisions, a lower risk of wound infection, limited blood loss, reduced postoperative pain, a shorter hospital stay, faster recovery, and better aesthetic results. There is a strong rationale for using minimally invasive surgery in patients with end-stage renal disease.

In December 2010, our institution acquired a da Vinci surgical system (Intuitive Surgical, Sunnyvale, CA) to carry out bladder, ureter, prostate, and kidney procedures. After an initial, successful experience with robotic-assisted KT, performed in nonobese patients according to the techniques described by Giulianotti and colleagues^{6,7} and Tzvetanov and colleagues¹²; in August 2013, the approach was applied to dual KT to achieve similar outcomes and obtain the same advantages. Twenty-four months after the procedure, we report on the first robotic-assisted dual kidney transplant and discuss its safety and feasibility.

MATERIALS AND METHODS

Case Report

A 63-year-old man with end-stage renal disease managed by hemodialysis for 4 years and arterial hypertension and diabetes mellitus under pharmacological control underwent robotic-assisted dual KT. He provided his written informed consent to the procedure. The patient had not undergone prior surgical treatment. The kidneys came from a marginal donor, a 70-year-old man who had died of cerebral

Received 19 July 2015. Revision submitted 25 August 2015.

Accepted 9 September 2015.

¹ Department of Renal Pathology, Urology, Kidney Transplantation and Robotic Surgery Unit, Azienda Ospedaliera "G. Brotzu", Cagliari, Italy.

The authors declare no funding or conflicts of interest.

M.F. was the senior surgeon, he participated in planning the procedure, operated the robot, and participated in writing the article. R.C. was the assistant surgeon and participated in planning the procedure and in writing the paper. A.S. was the assistant surgeon, he participated in planning the procedure in writing the article.

Correspondence: Mauro Frongia, MD, S.C. di Urologia, Trapianto di Rene e Chirurgia Robotica, Azienda Ospedaliera "G. Brotzu", Piazzale A. Ricchi 1, 09134, Cagliari, Italy. (maurofrongia@aob.it).

Copyright © 2015 The Authors. *Transplantation Direct*. Published by Wolters Kluwer Health, Inc. This is an open-access article distributed under the terms of the Creative Commons Attribution-Non Commercial-No Derivatives License 4.0 (CCBY-NC-ND), where it is permissible to download and share the work provided it is properly cited. The work cannot be changed in any way or used commercially.

ISSN: 2373-8731

DOI: 10.1097/TXD.0000000000000547

hemorrhage. Pretransplant donor biopsy demonstrated a bilateral Karpinski¹³ score greater than 5. The organs did not exhibit malformations and had an artery and a vein each. Once removed, they were perfused with Viaspan (University of Wisconsin Solution; Bristol-Myers Squibb, Chester, UK) and stored in ice.

Surgical Technique

After induction of general anesthesia, an 18 F Foley catheter was applied. The right-side procedure was performed first. The surgeon sat at the console, and the assistant surgeon stood beside the table. The patient lay supine in approximately 20° Trendelenburg position and slight left rotation, with the legs flexed and spread. Pneumoperitoneum was created by inserting a Veress needle at the midline, just above the umbilicus. The needle was then replaced with a 12-mm trocar for the 30° robotic scope. Two 8-mm robotic ports for the robotic arms—one under the right costal arch and the other close to the right anterosuperior iliac spine—were inserted along an oblique line passing through the umbilicus (Figure 1). Two additional trocars, respectively, 5 mm and 12 mm in diameter, were inserted through the right flank, to avoid interference with the robotic tools. The assistant surgeon, standing to the left of the patient, made a 7-cm upper midline incision for a hand-access device, through which both grafts would be introduced. The da Vinci robot was docked on the right side of the patient and integrated into the ports. The operation began with mobilization of the right colon and preparation of the external iliac vessels. After accurate hemostasis and lymphostasis using, respectively, a bipolar cautery forceps and a monopolar cautery hook, the right external iliac vein was clamped using robotic bulldog clamps, and venotomy was performed with Potts scissors. During backbench surgery, small vessels and perihilar lymphatics were carefully ligated to avoid bleeding after declamping. The kidney was placed on ice slush (Figure 2) to prolong hypothermia during vessel anastomosis, and introduced into the abdominal cavity wrapped in gauze through the hand-access device (GelPoint; Johnson & Johnson, Cincinnati, OH). The renal vein was anastomosed end-to-side to the external iliac vein with a 5-0 Gore-Tex suture (Figure 3). The external iliac artery was then clamped with a robotic bulldog clamp, resected, and anastomosed end-to-side to the renal

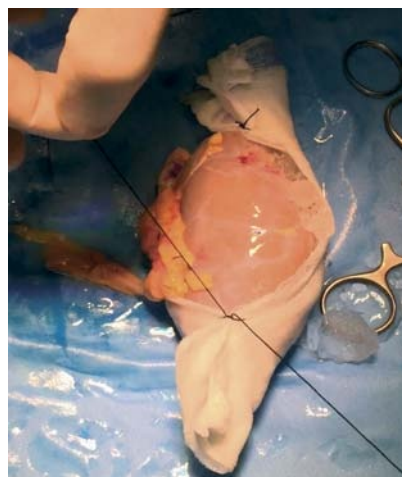


FIGURE 2. The graft was wrapped in gauze containing ice slush to prolong hypothermia.

artery using a 5-0 Gore-Tex suture (Figure 4). After anastomotic leak testing, the gauze and ice were removed and the graft was revascularized, achieving complete reperfusion. Then the bladder was distended with saline. An incision was performed through the muscle layer as far as the mucosa; the ureter was anastomosed to the bladder by the extravesical Lich-Gregoir technique using two 4-0 polydioxanone semi-continuous sutures, and a double J ureteral stent was inserted. After completing and testing the anastomosis, the serous-muscular layer was closed with a single 4-0 polydioxanone suture above the ureterocystostomy, to avoid reflux. A drain was applied through the 5-mm trocar.

The procedure for the left kidney was identical, except that it required mobilization of the sigmoid colon to introduce the graft. The robot was moved to the left side, leaving the optics trocar in place. Two ports for the robotic arms were opened in mirror fashion on the upper and lower left quadrants. The presence of the right kidney slightly hampered robot operation but enabled safe execution of the anastomosis, with the technique adopted for the right side (Figure 5).

RESULTS

Patient information and operative data are summarized in Table 1. Operative time was 400 minutes, and blood loss was

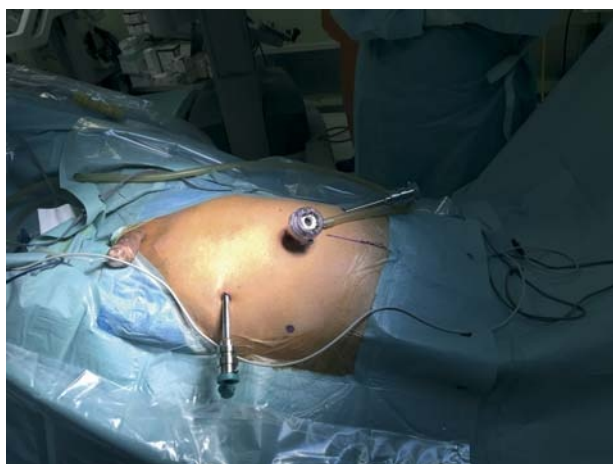


FIGURE 1. Position of the trocars for right graft implantation.

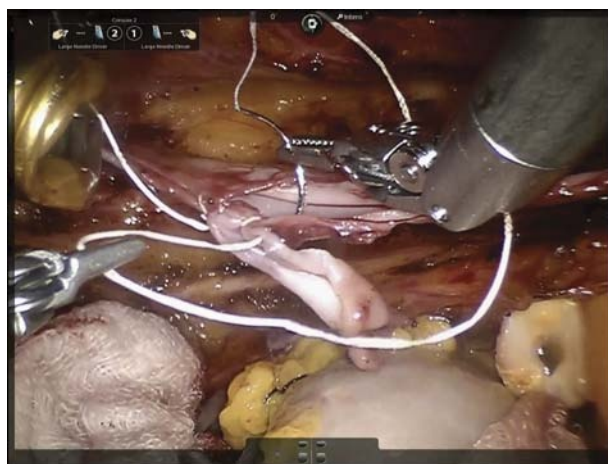

FIGURE 3. Renal vein to external iliac vein anastomosis.

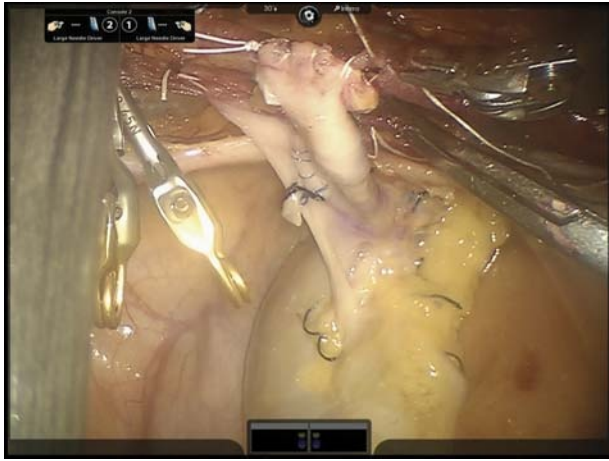


FIGURE 4. Anastomosis of the renal vessels to the external iliac vessels.

about 120 mL. The 2 organs began to function immediately. Warm ischemia time was 45 minutes and 49 minutes for the right and left kidney, respectively, but the organs were consistently in contact with ice during anastomosis execution up until declamping. Cold ischemia time was 13 hours and 16 hours for the right and the left kidney, respectively. There were no intraoperative or postoperative complications, and the patient was discharged on the seventh day with 1.1 mg/dL creatinine. The novel aspect of the technique was the single, 7-cm upper midline incision through which both grafts were introduced. Now, 24 months from the operation, the patient is well with normal kidney function and a creatinine level of 1.3 mg/100 mL.

DISCUSSION

In 2009, our institution adhered to the expanded criteria donor program for KT¹⁴ and began performing dual KT with the open surgical technique. Marginal donors were subjects older than 75 years or subjects aged 60 to 74 years with glomerulosclerosis greater than 15%. The organs of marginal donors aged 60 to 74 years with glomerulosclerosis less than 15% were used for single KT. Dual KT using grafts from marginal donors is a valuable option to meet the ever growing demand and diminishing supply of organs for

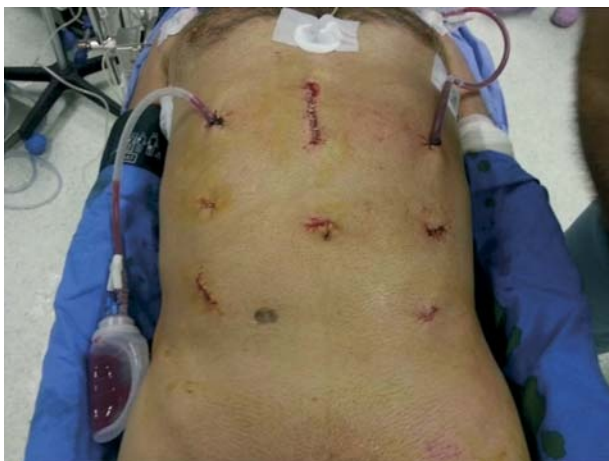

FIGURE 5. View of the patient at the end of the procedure.

TABLE 1.

Patient information and operative data

Sex	M
Ethnicity	White
Body mass index, kg/m ²	23.81
ASA score	2
Actual surgical time, min	360
Cold ischemia time, h	13 right/16 left
Hypertension	Yes
Diabetes	Yes
Intraoperative blood requirements, mL	120
Postoperative blood requirements	No
Postoperative dialysis	No
Manchester scar scale (5-18)	10
Surgical site infection	No
Donor characteristics	Deceased donor
Creatininemia	1.4 mg/100 mL

M indicates male.

transplantation. From 1997 to the present, 40 patients received open dual KT at our institution. Initially, the approach was through a wide Pfannenstiel incision extending nearly as far as the anterosuperior iliac spine, but in 2006, a technique involving 2 pararectal Gibson incisions was adopted to reduce invasiveness and ensure faster patient mobilization, thus also reducing the risks associated with prolonged bed rest.

Kidney transplantation is the most effective treatment for patients with end-stage renal disease, and the open technique is still the gold standard for its execution.¹ The advent of laparoscopic kidney removal from live donors in 1995 and the introduction of robotic-assisted surgery in 1999 opened the way for an increasingly frequent use of minimally invasive techniques also for KT.¹ Minimally invasive techniques, that is open surgery using very small skin incisions, laparoscopic surgery, and robotic-assisted surgery, have now become well-established approaches. Traditional open surgery involves skin incisions of variable length, depending on patient characteristics and surgeon preference; this approach, however, is associated with significant complications due to the frequent presence of comorbidities such as diabetes and obesity and of risk factors such as tobacco smoking. The immunosuppressive treatment is an additional risk factor. Moreover, wound size determines the intensity and duration of postoperative pain (hence the use of pain medications), the length of hospital stay and recovery, and esthetic outcomes. Minimally invasive techniques—including robotic-assisted surgery—involve a number of important benefits that include smaller surgical wounds, a reduced risk of wound infection, minimum blood loss, a shorter hospital stay, and a faster return to normal life. These goals are desirable in all surgical patients, but especially in those with end-stage renal disease, who often suffer from considerable comorbidities.¹⁴ The da Vinci robot affords 3-dimensional vision, optics management by the operator, and total tremor filtering, which is fundamental for accurate vessel anastomosis.

A total of 952 open transplant procedures have been performed at our center over the past 25 years; of these, 75 were from living donors, and 60 were dual KT. According to the protocol applied at our center, patients older than 60 years are placed on a separate list to receive organs from donors

who are older than 60 years; therefore, a 63-year-old patient requiring a renal transplant receives the organ from a marginal donor. Patients aged 65 years or older are excluded from living donor transplantation. Donated kidneys are biopsied and subjected to morphological examination, count of functioning nephrons, and calculation of the Karpinski score (percent glomerulosclerosis). If the score is between 5 and 7, both kidneys are implanted in a single recipient, as in the patient described herein.

Since we began to use the da Vinci system in 2011, 800 patients have received a range of robotic-assisted procedures for a variety of diseases. A robotic-assisted KT program was started in February 2013, after our team trained at the International School of Robotic Surgery (University of Illinois at Chicago, directed by Prof. E. Benedetti). The learning curve for the utilization of the da Vinci system involved 2 years of intense work with more than 600 procedures on kidney, bladder, ureter, and prostate. The critical step of the procedure is the arteriovenous anastomosis, whose mastery requires intense training.

A total of 15 single kidney transplants were carried out since early 2013, with outcomes that are in line with the literature (article submitted). We soon realized that the advantages of robotic surgery could be harnessed to perform dual transplants, with even greater benefit due to the significant impact of open dual KT. The outcome of the case described herein is encouraging and supports the feasibility of robotic-assisted dual KT and the value of inserting both grafts through a single incision. Clearly, the approach is restricted to selected patients. Its main disadvantage, that is, the extended duration of the procedure, which is generally longer than open dual KT owing especially to the execution of the vessel anastomoses, is limited in the hands of surgeons with strong experience in robotic surgery. Grafts from marginal donors are an extremely valuable resource.

We feel that robotic-assisted surgery applied to renal transplantation is a promising technique, whose diffusion is currently limited by steep purchase and operating costs. Larger patient samples and longer follow-ups are required to assess its actual effectiveness.¹⁵ The evolution and spread of robotic-

assisted dual KT after the unique experience reported herein are even more difficult to forecast.

ACKNOWLEDGMENT

The authors acknowledge Dr. Luigina Micolucci (Università Politecnica delle Marche, Ancona, Italy) for editorial assistance and Word Designs for the language revision (www.silviamodena.com).

REFERENCES

1. Modi P, Pal B, Modi J, et al. Robotic assisted kidney transplantation. *Indian J Urol.* 2014;30:287–292.
2. Rosales A, Salvador JT, Urdaneta G, et al. Laparoscopic kidney transplantation. *Eur Urol.* 2010;57:164–167.
3. Modi P, Rizvi J, Pal B, et al. Laparoscopic kidney transplantation: an initial experience. *Am J Transplant.* 2011;11:1320–1324.
4. Modi P, Thyagaraj K, Rizvi SJ, et al. Laparoscopic en bloc kidney transplantation. *Indian J Urol.* 2012;28:230–231.
5. Modi P, Pal B, Modi J, et al. Retroperitoneoscopic living-donor nephrectomy and laparoscopic kidney transplantation: experience of initial 72 cases. *Transplantation.* 2013;95:100–105.
6. Giulianotti P, Gorodner V, Sbrana F, et al. Robotic transabdominal kidney transplantation in a morbidly obese patient. *Am J Transplant.* 2010;10:1478–1482.
7. Oberholzer J, Giulianotti P, Danielson KK, et al. Minimally invasive robotic kidney transplantation for obese patients previously denied access to transplantation. *Am J Transplant.* 2013;13:721–728.
8. Boggi U, Vistoli F, Signori S, et al. Robotic renal transplantation: first European case. *Transpl Int.* 2011;24:213–218.
9. Abaza R, Ghani KR, Sood A, et al. Robotic kidney transplantation with intraoperative regional hypothermia. *BJU Int.* 2014;113:679–681.
10. Menon M, Sood A, Bhandari M, et al. Robotic kidney transplantation with regional hypothermia: a step-by-step description of the Vattikuti Urology Institute-Medanta technique (IDEAL phase 2a). *Eur Urol.* 2014;65:991–1000.
11. Tsai MK, Lee CY, Yang CY, et al. Robot-assisted renal transplantation in the retroperitoneum. *Transpl Int.* 2014;27:452–457.
12. Tzvetanov I, D'Amico G, Benedetti E. Robotic-assisted kidney transplantation: our experience and literature review. *Curr Transplant Rep.* 2015;2:122–126.
13. Remuzzi G, Cravedi P, Perna A, et al. Long-term outcome of renal transplantation from older donors. *N Engl J Med.* 2006;354:343–352.
14. Port FK, Bragg-Gresham JL, Metzger RA, et al. Donor characteristics associated with reduced graft survival: an approach to expanding the pool of kidney donors. *Transplantation.* 2002;74:1281–1286.
15. Sood A, Ghosh P, Menon M, et al. Robotic renal transplantation: current status. *J Minim Access Surg.* 2015;11:35–39.