

^{18}F -FLT-PET for Response Evaluation of MEK Inhibitor Selumetinib (AZD6244, ARRY-142886) in Patients with Solid Tumors

Ingrid M. E. Desar, Rozemarie Gilles¹, Carla M. L. van Herpen, Anja (J.) N. H. Timmer-Bonte, Mireille V. Cantarini², Winette T. A. van der Graaf, Wim J. G. Oyen¹

Departments of Medical Oncology, ¹Nuclear Medicine, Radboud University Nijmegen Medical Centre, Nijmegen, The Netherlands, ²Astra Zeneca, Alderley Park, Macclesfield, UK

Abstract

Selumetinib (AZD6244, ARRY-142886) is a potent, selective, uncompetitive inhibitor of MEK 1 / 2, part of the RAF/MEK/ERK protein kinase signal cascade, which is responsible for tumor. This pilot study was used to explore if ^{18}F -fluoro-l-thymidine (FLT), a thymidine analogue positron emission tomography (PET) tracer and a surrogate marker for proliferation, can be used as an early predictor of response for patients with solid cancers treated with Selumetinib. FLT-PET scans were performed in four patients at baseline and after 2 weeks of treatment with Selumetinib. FLT uptake in tumors was analyzed qualitatively and quantitatively by measuring standard uptake value (SUV) max in regions of interest (ROI). Results were compared to computed tomography (CT) scans (baseline and after 8 weeks), which were evaluated using the response evaluation criteria in solid tumors (RECIST) 1.0 criteria. One patient with melanoma showed both a qualitative and quantitative decrease in FLT uptake associated with a decrease in sum of longest diameter of 12% RECIST on CT evaluation. Another patient who had colorectal carcinoma (CRC) showed a significant increase in FLT uptake with initially stable, but eventually progressive disease on CT. The other two patients (one with melanoma and one with CRC) showed no significant changes in FLT uptake, whereas CT evaluation showed progressive disease. This is the first report describing changes in FLT-PET in patients receiving Selumetinib. In two patients, changes in FLT uptake as early as after 2 weeks of treatment were consistent with CT results after 8 weeks. Biomarkers to predict and evaluate treatment the outcome of targeted therapies are highly warranted. These initial results need further investigation.

Key words: F-18 FLT, PET-CT, Selumetinib, treatment response

Introduction

The intracellular Ras-regulated Raf/MEK/ERK protein kinase signal cascade is a key pathway involved in cellular proliferation and survival. A strong correlation between deregulation of this pathway and uncontrolled cell proliferation has been demonstrated.^[1] Selumetinib (AZD6244, ARRY-142886) is a potent, selective, uncompetitive inhibitor of MEK $\frac{1}{2}$, developed as

targeted therapy to treat solid cancers. A favorable toxicity, pharmacokinetic, and pharmacodynamic profile has been observed in phase I studies and phase II studies focusing on melanoma and colorectal cancer (CRC).^[2-4] The development of targeted agents requires identification and better understanding of positive predictive biomarkers of clinical response to these agents. Currently, the CT Response Evaluation Criteria in Solid Tumors (RECIST) are mostly used to evaluate response.^[5] These RECIST guidelines are based on the sum of one-dimensional measurements of the greatest diameter of the tumor and/or metastases.^[5,6] However, treatment with targeted therapies is cytostatic rather than cytotoxic, and can result in necrosis and cavitation without a change in lesion (or tumor) size, leading to an underestimation of therapeutic efficacy. Imaging techniques able to predict treatment outcome in an early

Access this article online

Quick Response Code:



Website:

www.wjnm.org

DOI:

10.4103/1450-1147.103413

Address for correspondence:

Dr. I. M. E. Desar, Department of Medical Oncology, Radboud University Nijmegen Medical Centre, PO Box 9101, 6500HB Nijmegen, The Netherlands. E-mail: i.desar@aig.umcn.nl

phase of treatment are warranted. Molecular imaging may enable alternative evaluation procedures for these new drugs and enable the early change to an alternative therapy if no functional response is indicated. Recently the functional imaging technique of positron emission tomography (PET) using the radiopharmaceutical tracer ^{18}F -fluorodeoxyglucose (FDG) has been found to be a useful method for response monitoring in various malignancies.^[7-11] However, FDG is a tracer for glucose metabolism, which does not always reflect proliferation activity. The PET agent ^{18}F -fluoro-l-thymidine (FLT) has been introduced for imaging of cell proliferation. FLT is a thymidine analogue, which is retained in proliferating cells through the activity of the enzyme thymidine kinase-1, which is expressed during the DNA synthesis phase of the cell cycle.^[12] FLT-PET has been applied for the assessment of proliferation rate in different tumors.^[13-18] In this pilot study, we assessed the effect of Selumetinib on tumor cell proliferation in patients with a variety of solid tumors by FLT-PET-CT and determined whether changes in FLT uptake can potentially be used as an early predictive biomarker for treatment response.

Materials and Methods

Patients

This single-institution study was conducted in conjunction with Phase I clinical trial of the capsule formulation of Selumetinib (NCT00463814) in patients with solid tumors.^[2] In this study, patients with advanced solid cancer refractory to standard therapies or for whom no conventional therapies exists were treated with oral Selumetinib twice daily in a dose escalation schedule. As part of this study protocol, an evaluation CT scan was performed after every two cycles (i.e. at 8 weekly intervals of treatment with Selumetinib).

Patients participating in the FLT-PET side study had to have at least one tumor deposit of at least 2 cm outside the liver and axial skeleton. All patients gave written informed consent and both studies were approved by the local ethical committee.

FLT-PET

FLT-PET scans were performed at baseline and after 2 weeks of treatment. The scans were performed on an integrated PET-CT scanner (Siemens/Biograph) using a static whole body protocol (hips to base of skull) 1 h after administration of 250 MBq FLT.

The FLT-PET images were analyzed both visually for any tumor targeting and quantitatively for changes in FLT uptake. Quantitative assessment was realized by drawing CT-derived 3D regions of interest (ROI) over the tumors, with both a threshold of 50% and 70% of

the maximum FLT-activity via an automatic algorithm. Standardized uptake values (SUVs) were calculated using the concentration of FLT in the volume of interest (VOI) as measured by PET, divided by the injected dose per kg body weight as a normalization factor.

Evaluation

FLT-PET scans were analyzed by two nuclear medicine physicians. Only lesions outside of the liver and axial skeleton, with a diameter of 2 cm or more, which were also measured on CT, were evaluated. Based on two recent studies by de Langen *et al.* and Wahl *et al.*, any changes in SUVmax greater than 30% were considered as significant and medically relevant, independent of day-to-day variability.^[19,20] CT scans were analyzed using the RECIST 1.0 guidelines.^[6] Quantitative (mean SUVmax of measured lesions) FLT-PET results were compared with the results of the radiological evaluation with CT-scan based on RECIST 1.0 criteria.

Results

In four patients, both baseline and follow-up FLT-PET-CTs were performed. Two patients had metastasized melanoma and two patients had advanced/metastatic CRC. One patient with melanoma showed both a qualitative and quantitative decrease in FLT uptake, correlating with a decrease in sum of diameters of 12% applying RECIST to CT evaluation [Figures 1 and 2]. Another patient who had CRC showed a significant increase in FLT uptake with initially (at 8 weeks) stable disease, but eventually progressive disease on CT. The other two patients (one with melanoma and one with CRC) showed no significant changes in FLT uptake, whereas CT evaluation showed progressive disease [Table 1].

Discussion

In the new era of targeted therapies, there is a need for early identification of therapy responding and non-responding patients, in order to be able to change therapy, thereby working toward personalized medicine. Response monitoring for targeted therapies demands more specific diagnostic modalities than conventional imaging alone. Differentiation between vital tumor and fibrosis or necrosis is not possible by using morphological features as in RECIST. Furthermore, with functional and molecular imaging techniques, one could prevent a patient from unnecessarily suffering from drug side effects by differentiating responders from non-responders in an early stage of treatment.

As mentioned before, PET with FDG already has an established role in monitoring various anti-cancer therapies such as targeted therapies in malignant

gastrointestinal stromal tumors.^[10] This has led to the creation of the recently developed PET Response Criteria in Solid Tumors (PERCIST).^[20]

Beyond FDG, more specific imaging biomarkers for PET have been developed of which a reasonable amount is already in clinical stage like ^{18}F -16 α -17-fluoroestradiol

(^{18}F -FES), ^{18}F -galacto-RGD, and ^{18}F -FLT, which was used in this study.^[21]

However, PET is not the only imaging modality with potential in early response monitoring in clinical oncology. Different magnetic resonance imaging (MRI) and magnetic resonance spectroscopy (MRS)

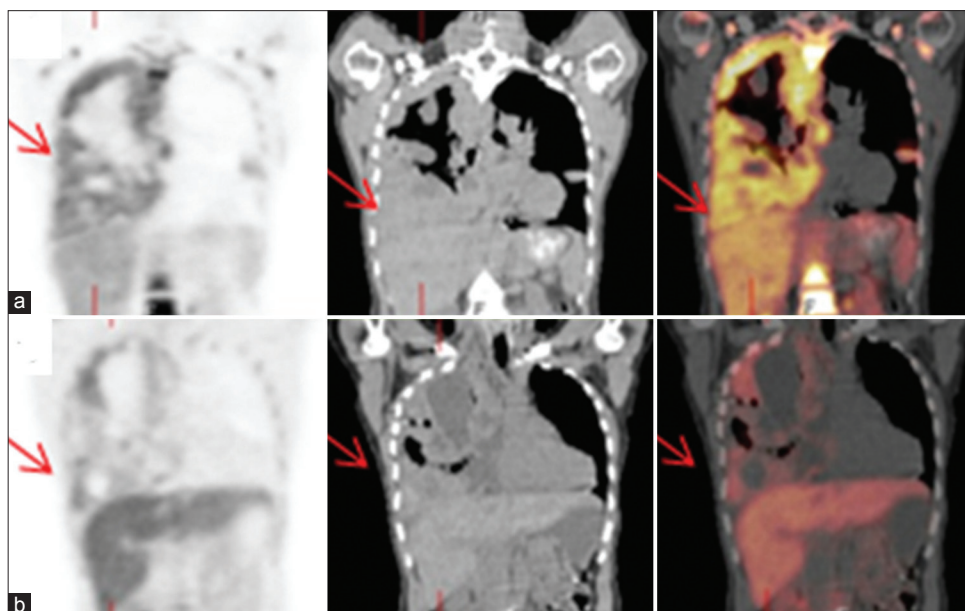


Figure 1: F-18 FLT PET/CT scan. Coronal images: (a) Before treatment and (b) after treatment. A female patient with pleural metastases of a melanoma, showing decreased FLT uptake in the pleural metastases after treatment with Selumetinib for 2 weeks (Patient No. 1) [Table 1]

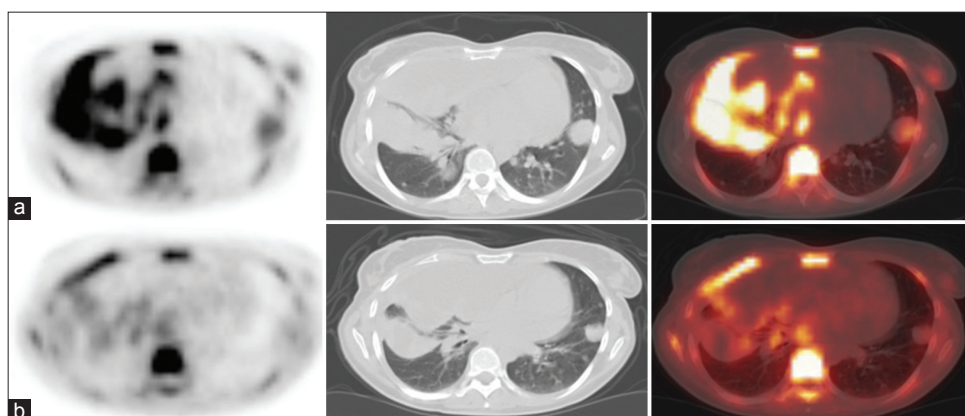


Figure 2: F-18 FLT PET/CT scan. Transaxial images: (a) Before treatment and (b) after treatment. A female patient with pleural metastases of a melanoma, showing decreased FLT uptake in the pleural metastases after treatment with Selumetinib for 2 weeks (Patient No. 1) [Table 1]

Table 1: Changes in mean SUVmax compared to CT changes according to RECIST after Selumetinib therapy in four patients with metastatic melanoma or metastatic colorectal carcinoma

Patient	Tumor type	No. of lesions	SUVmax baseline	SUVmax post therapy	% Change in SUVmax	RECIST (mm) baseline	RECIST (mm) post therapy	% Change in RECIST
1	Melanoma	3	4.59	1.43	-69	156	138	-12
2	CRC	1	1.81	4.19	+130	77	81	+5
3	Melanoma	5	6.47	5.32	-18	212	257	+21
4	CRC	2	2.39	1.72	-28	215	223	+4*

*Although no significant change was observed in the sum of diameters, a new lesion was found and thus progressive disease according to RECIST 1

techniques for functional and molecular imaging have been developed.

One of them is dynamic contrast-enhanced MRI (DCE-MRI) in which the kinetics of contrast agent inflow into the tumor after intravenous injection of the agent is followed.^[22] Since tumor angiogenesis is associated with an increase in vessel permeability, this can be measured using DCE-MRI techniques.^[23] Morgan *et al.* found that in patients treated with an anti-angiogenic vascular endothelial growth factor receptor tyrosine kinase inhibitor, there were significantly greater reductions in a pharmacokinetic parameter that was related to vessel permeability in patients who showed a positive response to treatment than in those who had progressive disease.^[24]

Furthermore, multimodality imaging has potential role in clinical response monitoring, whereas PET/CT and single-photon emission computed tomography (SPECT) CT are already widely used for the evaluation of cancer.^[25] However, the major drawback of these techniques is that they are combined by software and not acquired simultaneously. Recently, Judenhover *et al.* have performed simultaneously FLT-PET and MRI in a mouse model for colon carcinoma. This system was able to image three functional imaging techniques, PET, functional MRI, and MRS with morphological MRI.^[26]

No fully statistically powered human studies on FLT-PET for cancer therapy response monitoring have been performed. Nevertheless, a possible beneficial role in therapeutic response of various solid tumors with different types of therapy have been shown,^[27-29] as well as the potential of using quantitative parameters for FLT uptake such as SUV.^[19]

This is the first report of ¹⁸F-FLT-PET to assess the effect of the MEK inhibitor Selumetinib. In this limited study, FLT-PET-CT as an early predictor of response on Selumetinib is interesting. Further investigation of FLT-PET as a biomarker of early treatment response is needed.

References

- Kolch W. Meaningful relationships: The regulation of the Ras/Raf/MEK/ERK pathway by protein interactions. *Biochem J* 2000; 351 Pt 2:289-305.
- Banerji U, Camidge DR, Verheul HM, Agarwal R, Sarker D, Kaye SB, *et al.* The first-in-human study of the hydrogen sulfate (Hyd-sulfate) capsule of the MEK1 / 2 inhibitor AZD6244 (ARRY-142886): A phase I open-label multicenter trial in patients with advanced cancer. *Clin Cancer Res* 2010;16:1613-23.
- Bennouna J, Lang I, Valladares-Ayerbes M, Boer K, Adenis A, Escudero P, *et al.* A Phase II, open-label, randomised study to assess the efficacy and safety of the MEK1 / 2 inhibitor AZD6244 (ARRY-142886) versus capecitabine monotherapy in patients with colorectal cancer who have failed one or two prior chemotherapeutic regimens. *Invest New Drugs* 2011;29:1021-8.
- Kirkwood JM, Bastholt L, Robert C, Sosman J, Larkin J, Hersey P, *et al.* Phase II, open-label, randomized trial of the MEK1 / 2 inhibitor selumetinib as monotherapy versus temozolomide in patients with advanced melanoma. *Clin Cancer Res* 2012;18:555-67.
- Therasse P, Arbuck SG, Eisenhauer EA, Wanders J, Kaplan RS, Rubinstein L, *et al.* New guidelines to evaluate the response to treatment in solid tumors. European Organization for Research and Treatment of Cancer, National Cancer Institute of the United States, National Cancer Institute of Canada. *J Natl Cancer Inst* 2000;92:205-16.
- Eisenhauer EA, Therasse P, Bogaerts J, Schwartz LH, Sargent D, Ford R, *et al.* New response evaluation criteria in solid tumours: Revised RECIST guideline (version 1.1). *Eur J Cancer* 2009;45:228-47.
- Capirci C, Rampin L, Erba PA, Galeotti F, Crepaldi G, Banti E, *et al.* Sequential FDG-PET/CT reliably predicts response of locally advanced rectal cancer to neo-adjuvant chemo-radiation therapy. *Eur J Nucl Med Mol Imaging* 2007;34:1583-93.
- De Geus-Oei LF, van der Heijden HF, Visser EP, Hermesen R, van Hoorn BA, Timmer-Bonte JN, *et al.* Chemotherapy response evaluation with ¹⁸F-FDG PET in patients with non-small cell lung cancer. *J Nucl Med* 2007;48:1592-8.
- De Geus-Oei LF, van Laarhoven HW, Visser EP, Hermesen R, van Hoorn BA, Kamm YJ, *et al.* Chemotherapy response evaluation with FDG-PET in patients with colorectal cancer. *Ann Oncol* 2008;19:348-52.
- Gayed I, Vu T, Iyer R, Johnson M, Macapinlac H, Swanson N, *et al.* The role of ¹⁸F-FDG PET in staging and early prediction of response to therapy of recurrent gastrointestinal stromal tumors. *J Nucl Med* 2004;45:17-21.
- Schwarz JK, Siegel BA, Dehdashti F, Grigsby PW. Association of posttherapy positron emission tomography with tumor response and survival in cervical carcinoma. *JAMA* 2007;298:2289-95.
- Shields AF, Grierson JR, Dohmen BM, Machulla HJ, Stayanoff JC, Lawhorn-Crews JM, *et al.* Imaging proliferation *in vivo* with [¹⁸F]-FLT and positron emission tomography. *Nat Med* 1998;4:1334-6.
- Apisarnthanarax S, Alauddin MM, Mourtada F, Ariga H, Raju U, Mawlawi O, *et al.* Early detection of chemoradioresponse in esophageal carcinoma by 3'-deoxy-3'-H-fluorothymidine using preclinical tumor models. *Clin Cancer Res* 2006;12:4590-7.
- Buck AK, Bommer M, Stilgenbauer S, Juweid M, Glatting G, Schirmermeister H, *et al.* Molecular imaging of proliferation in malignant lymphoma. *Cancer Res* 2006;66:11055-61.
- Francis DL, Visvikis D, Costa DC, Arulampalam TH, Ownsend C, Luthra SK, *et al.* Potential impact of [¹⁸F]3'-deoxy-3'-fluorothymidine versus [¹⁸F]fluoro-2-deoxy-D-glucose in positron emission tomography for colorectal cancer. *Eur J Nucl Med Mol Imaging* 2003;30:988-94.
- Seitz U, Wagner M, Neumaier B, Wawra E, Glatting G, Leder G, *et al.* Evaluation of pyrimidine metabolising enzymes and *in vitro* uptake of 3'-[¹⁸F]fluoro-3'-deoxythymidine ([¹⁸F]FLT) in pancreatic cancer cell lines. *Eur J Nucl Med Mol Imaging* 2002;29:1174-81.
- Van Westreenen HL, Cobben DC, Jager PL, van Dulleman HM, Wesseling J, Elsinga PH, *et al.* Comparison of ¹⁸F-FLT PET and ¹⁸F-FDG PET in esophageal cancer. *J Nucl Med* 2005;46:400-4.
- Vesselle H, Grierson J, Muzi M, Pugsley JM, Schmidt RA, Rabinowitz P, *et al.* *In vivo* validation of 3'-deoxy-3'-[¹⁸F]fluorothymidine ([¹⁸F]FLT) as a proliferation imaging tracer in humans: Correlation of [¹⁸F]FLT uptake by positron

- emission tomography with Ki-67 immunohistochemistry and flow cytometry in human lung tumors. *Clin Cancer Res* 2002;8:3315-23.
19. De Langen AJ, Klabbers B, Lubberink M, Boellaard R, Spreeuwenberg MD, Slotman BJ, *et al.* Reproducibility of quantitative ¹⁸F-3'-deoxy-3'-fluorothymidine measurements using positron emission tomography. *Eur J Nucl Med Mol Imaging* 2009;36:389-95.
 20. Wahl RL, Jacene H, Kasamon Y, Lodge MA. From RECIST to PERCIST: Evolving Considerations for PET response criteria in solid tumors. *J Nucl Med* 2009;50:122S-50S.
 21. Seaman ME, Contino G, Bardeesy N, Kelly KA. Molecular imaging agents: Impact on diagnosis and therapeutics in oncology. *Expert Rev Mol Med* 2010;12:e20.
 22. Leach MO, Brindle KM, Evelhoch JL, Griffiths JR, Horsman MR, Jackson A, *et al.* The assessment of antiangiogenic and antivascular therapies in early-stage clinical trials using magnetic resonance imaging: Issues and recommendations. *Br J Cancer* 2005;92:1599-610.
 23. McDonald DM, Choyke PL. Imaging of angiogenesis: From microscope to clinic. *Nat Med* 2003;9:713-25.
 24. Morgan B, Thomas AL, Dreves J, Hennig J, Buchert M, Jivan A, *et al.* Dynamic contrast-enhanced magnetic resonance imaging as a biomarker for the pharmacological response of PTK787/ZK 222584, an inhibitor of the vascular endothelial growth factor receptor tyrosine kinases, in patients with advanced colorectal cancer and liver metastases: Results from two phase I studies. *J Clin Oncol* 2003;21:3955-64.
 25. Bockisch A, Freudenberger LS, Schmidt D, Kuwert T. Hybrid imaging by SPECT/CT and PET/CT: Proven outcomes in cancer imaging. *Semin Nucl Med* 2009;39:276-89.
 26. Judenhofer MS, Wehrli HF, Newport DF, Catana C, Siegel SB, Becker M, *et al.* Simultaneous PET-MRI: A new approach for functional and morphological imaging. *Nat Med* 2008;14:459-65.
 27. Chen W, Delaloye S, Silverman DH, Geist C, Czernin J, Sayre J, *et al.* Predicting treatment response of malignant gliomas to bevacizumab and irinotecan by imaging proliferation with [¹⁸F] fluorothymidine positron emission tomography: A pilot study. *J Clin Oncol* 2007;25:4714-21.
 28. Herrmann K, Wieder HA, Buck AK, Schöffel M, Krause BJ, Fend F, *et al.* Early response assessment using 3'-deoxy-3'-[¹⁸F] fluorothymidine-positron emission tomography in high-grade non-Hodgkin's lymphoma. *Clin Cancer Res* 2007;13:3552-8.
 29. Sohn HJ, Yang YJ, Ryu JS, Oh SJ, Im KC, Moon DH, *et al.* [¹⁸F] Fluorothymidine positron emission tomography before and 7 days after gefitinib treatment predicts response in patients with advanced adenocarcinoma of the lung. *Clin Cancer Res* 2008;14:7423-9.

How to cite this article: Desar IM, Gilles R, Van Herpen CM, Timmer-Bonte AN, Cantarini MV, Van der Graaf WT, *et al.* ¹⁸F-FLT-PET for response evaluation of mek inhibitor selumetinib (AZD6244, ARRY-142886) in patients with solid tumors. *World J Nucl Med* 2012;11:65-7.

Source of Support: Nil. **Conflict of Interest:** None declared.

Announcement

"QUICK RESPONSE CODE" LINK FOR FULL TEXT ARTICLES

The journal issue has a unique new feature for reaching to the journal's website without typing a single letter. Each article on its first page has a "Quick Response Code". Using any mobile or other hand-held device with camera and GPRS/other internet source, one can reach to the full text of that particular article on the journal's website. Start a QR-code reading software (see list of free applications from <http://tinyurl.com/yzlh2tc>) and point the camera to the QR-code printed in the journal. It will automatically take you to the HTML full text of that article. One can also use a desktop or laptop with web camera for similar functionality. See <http://tinyurl.com/2bw7fn3> or <http://tinyurl.com/3ysr3me> for the free applications.