

# Clinical utility of voriconazole eye drops in ophthalmic fungal keratitis

Daoud Al-Badriyeh  
Chin Fen Neoh  
Kay Stewart  
David CM Kong

Centre for Medicine Use and Safety, Faculty of Pharmacy and Pharmaceutical Sciences, Monash University, Victoria, Australia

**Abstract:** Fungal keratitis is one of the major causes of ophthalmic mycosis and is difficult to treat. The range of common antifungal agents available for fungal keratitis remains inadequate and is generally associated with poor clinical outcomes. Voriconazole is a new generation triazole antifungal agent. Only marketed in systemic formulation and, with broad-spectrum activity and high intraocular penetration, voriconazole has demonstrated effectiveness against fungal keratitis. Systemic voriconazole, however, is not without side effects and is costly. Voriconazole eye drops have been prepared extemporaneously and used for the treatment of ophthalmic fungal keratitis. The current article sought to review the literature for evidence related to the effectiveness and safety of topical voriconazole and its corneal penetration into the aqueous humor of the eye. The voriconazole eye drops used are typically of 1% concentration, well tolerated by the eye, and are stable. Despite existing evidence to suggest that the eye drops are effective in the treatment of fungal keratitis, more studies are needed, especially in relation to using the eye drops as first-line and stand-alone treatment, preparation of higher concentrations, and optimal dosing frequency.

**Keywords:** voriconazole, fungal keratitis, eye drops, corneal penetration

## Introduction

Corneal disease is second only to cataracts as the most common cause of blindness worldwide, resulting in more than 1.5 million new cases of vision loss annually.<sup>1</sup> As a consequence of attention being directed towards the management of cataracts, especially in developing countries, strategies for the management of traditional infections that cause blindness have been neglected.<sup>2</sup>

Ophthalmic mycosis is emerging as a major cause of vision loss and morbidity, and can be life-threatening.<sup>3,4</sup> Fungal keratitis is one of the major causes of ophthalmic mycosis,<sup>5</sup> accounting for more than 50% of proven ophthalmic mycoses in some countries.<sup>6</sup> Fungal keratitis is usually characterized by a corneal epithelial defect and inflammation of the corneal stroma. If untreated, fungal keratitis can lead to corneal scarring and vision loss.<sup>1</sup>

## Fungal keratitis

The first description of fungal keratitis was in the late 1870s.<sup>7</sup> Fungal keratitis is most common in tropical regions and developing countries, where it constitutes over 50% of keratitis.<sup>8</sup> In South India, about 44% of corneal ulcers are caused by fungi. Although lower, the prevalence of fungal keratitis is still relatively high in other countries, being 17% in Nepal, 36% in Bangladesh, 38% in Ghana, and 35% in south Florida in the US.

Correspondence: David CM Kong  
Centre for Medicine Use and Safety,  
Department of Pharmacy Practice,  
Faculty of Pharmacy and Pharmaceutical  
Sciences, Monash University, 381 Royal  
Parade, Parkville, Victoria 3052,  
Australia  
Tel +61 39903 9035  
Fax +61 39903 9629  
Email david.kong@pharm.monash.edu.au

In China, the incidence has been increasing in the past decade.<sup>9</sup> By contrast, fungal keratitis generally accounts for only 1%–5% of the keratitis treated in developed countries and temperate regions, such as Britain and the northern US.<sup>9,10</sup> This also applies to Australia, where the incidence of fungal keratitis at the Royal Victorian Eye and Ear Hospital (RVEEH) in Melbourne was reported at 5%. The RVEEH is a tertiary referral eye hospital responsible for the care of most serious corneal infections in a population of about five million across Victoria, southern New South Wales, and Tasmania.<sup>10</sup>

## Etiology

Filamentous fungi were long considered as a major cause of fungal keratitis.<sup>11,12</sup> Ophthalmic infections from these fungi are most commonly associated with agricultural and outdoor activities.<sup>13,14</sup> Of the filamentous fungi, infections from *Fusarium* and *Aspergillus* species are the most common. While *Fusarium* species are particularly prevalent in crop plants,<sup>15</sup> *Aspergillus* species are found in decaying vegetation and soil. *Aspergillus* is a contaminant in hospital air and has been involved in recent outbreaks of ocular infections in several hospitals.<sup>16,17</sup> Keratitis caused by these filamentous fungi may involve any part of the cornea.<sup>18,19</sup> Other less common keratitis-causative filamentous fungi include *Paecilomyces* and *Acremonium* species.<sup>20</sup> *Paecilomyces* species have been shown to be resistant to most common sterilising techniques, including those applied during surgical procedures.<sup>21,22</sup> *Acremonium* species can be isolated from a variety of common sources, and can be associated with severe eye infections.<sup>23,24</sup>

Dematiaceous fungi such as *Curvularia*, *Bipolaris*, and *Exserohilum* species have also been reported to cause fungal keratitis. After *Aspergillus* and *Fusarium* species, *Curvularia* and *Bipolaris* species are the third most common keratitis-causative fungi worldwide.<sup>20</sup> *Curvularia*, *Bipolaris*, and *Exserohilum* species usually cause persistent, but low-grade ulcerations near the epithelial part of the cornea. These ulcerations, if not appropriately treated or if associated with topical steroid use, can develop into resilient infections involving the deeper layers of cornea.<sup>25–27</sup> *Scedosporium* and *Lecytophora* species are also dematiaceous fungi that are known to result in very severe keratitis infections that often do not respond to medical therapies.<sup>25,28</sup>

Whilst filamentous and dematiaceous fungi are the common causes of fungal keratitis at a global level, yeasts are the major cause of fungal keratitis in developed countries.<sup>8</sup> Yeasts are infrequent in tropical countries, characterized by major agricultural presence, which is associated with higher

prevalence of other types of fungal keratitis, such as the filamentous fungi.<sup>20</sup> Yeast infections have no geographical dominance and are most commonly caused by *Candida* species, especially *Candida albicans*.<sup>8,10,20</sup> *Candida* keratitis predominantly occurs in the stromal layer of the cornea. It is associated with epithelial defect and distinct infiltration, and is slow in development.<sup>18</sup> *Cryptococcus* species are another type of yeast that causes fungal keratitis, but less commonly than *Candida* species.<sup>20</sup>

Fungal keratitis can also be caused by zygomycetes fungi such as *Rhizopus* and *Mucorales* species,<sup>4,29,30</sup> and other fungi such as *Cladosporium*, *Cylindrocarpon*, *Penicillium*, and *Chrysonilia* species.<sup>6,14,31–33</sup> Keratitis due to these fungi, however, is very low in occurrence.

The incidence of different types of fungal keratitis in various areas and countries is shown in Table 1.

## Risk factors

The general predisposing factors for fungal keratitis include ocular trauma, prolonged use of topical or systemic immunosuppressants, pre-existing corneal surface disease, underlying systemic disease (eg, diabetes mellitus), and contact lens wear.<sup>10,20,35</sup>

The significance of these factors, however, varies according to geographical area. For instance, in Melbourne, ocular trauma, chronic steroid use, and ocular surface disease were the most common risk factors,<sup>10</sup> whilst the common risk factors in Philadelphia were ocular surface disease, contact lens wear, and topical steroids.<sup>33</sup> In the southern US, however, trauma was generally identified as the major risk factor for fungal keratitis. A similar trend was also observed in Singapore and Bangladesh.<sup>36,37</sup> In contrast, in the northern US, ocular trauma was reported as only a secondary risk factor for fungal keratitis.<sup>9</sup>

The type of predisposing risk factors relates to the type of causative fungi. For example, keratitis associated with ocular trauma is commonly caused by *Aspergillus*, *Fusarium*, and *Curvularia* species.<sup>14</sup> The use of lawn trimmers was found to be associated with *Fusarium* and *Curvularia* keratitis,<sup>14,38</sup> while the use of topical steroids was linked to *Candida*, *Aspergillus*, *Acremonium*, and *Curvularia* keratitis. Underlying chronic diseases were frequently related to keratitis caused by *Fusarium* and *Candida* species.<sup>14</sup> *Candida* keratitis is common where traumatic keratitis is infrequent.<sup>20</sup> Previous corneal ulceration resulting, for example, from previous keratitis or contact lens-related trauma, is a particular risk factor for *Candida* keratitis.<sup>18</sup> Trauma by plant material, contaminated water, or immune suppression is a risk

**Table I** Studies of the incidence of types of fungal keratitis<sup>8,10,13,20,34</sup>

Place	Number of patients	Study duration	Principal pathogen (%)
Melbourne, Australia	56	18 months	<i>Candida albicans</i> (37), <i>Aspergillus fumigatus</i> (17), <i>Fusarium</i> spp. (14)
Madurai, India	434	3 months	<i>Fusarium</i> spp. (47), <i>Aspergillus</i> spp. (16)
London, UK	65	13 years	<i>Candida albicans</i> (35), <i>Candida parapsilosis</i> (15), <i>Fusarium solani</i> (11), <i>Aspergillus fumigatus</i> (9)
Hyderabad, India	1352	10 years	<i>Fusarium</i> spp. (37), <i>Aspergillus</i> spp. (31)
Paraguay	45	1 year	<i>Fusarium</i> spp. (42), <i>Aspergillus</i> spp. (21)
Sri Lanka	66	2 years	<i>Aspergillus</i> spp. (25)
Florida, US	125	10 years	<i>Fusarium</i> spp. (68), <i>Candida</i> spp. (14), <i>Curvularia</i> spp. (9)
Bangladesh	142	11 months	<i>Aspergillus</i> spp. (37), <i>Fusarium</i> spp. (20), <i>Curvularia</i> spp. (18)
Ghana	199	N/A	<i>Fusarium</i> spp. (52), <i>Aspergillus</i> spp. (15), <i>Lecytophora theobromae</i> (9)
New Delhi, India	211	5 years	<i>Aspergillus</i> spp. (40), <i>Fusarium</i> spp. (14), <i>Alternaria</i> spp. (10)
Singapore	29	5 years	<i>Fusarium</i> spp. (52), <i>Aspergillus flavus</i> (17)
Philadelphia, US	24	9 years	<i>Candida albicans</i> (46), <i>Fusarium</i> spp. (25)
Houston, US	32	30 years	<i>Curvularia senegalensis</i> (30), <i>Curvularia lunata</i> (25)
Qingdao, China	108	4 years	<i>Fusarium</i> spp. (65), <i>Aspergillus</i> spp. (14), <i>Candida</i> spp. (9)
Nepal	405	2 years	<i>Aspergillus</i> spp. (47), <i>Candida</i> spp. (13), <i>Fusarium</i> spp. (12)

**Abbreviations:** spp., species; N/A, not available.

factor for keratitis caused by *Scedosporium apiospermum*.<sup>20</sup> Keratitis caused by *Paecilomyces* species has been reported following surgical procedures.<sup>21,39</sup>

## Treatment

The ultimate goal in the treatment of fungal keratitis is to conserve vision. This requires timely diagnosis of the infection and administration of the appropriate antifungal therapy.<sup>40</sup> Patient with fungal keratitis can be treated with either medical or surgical therapy. Whilst surgical procedures are more effective in patients with acute corneal perforation, antifungal agents are still the major therapeutic option in fungal keratitis,<sup>41</sup> whereby success depends on the agent's ability to penetrate into the aqueous humor and achieve therapeutic levels. Currently, the range of antifungal therapies available for fungal keratitis remains inadequate.<sup>9,42</sup> The antifungal agents that can be used in fungal keratitis are broadly divided into three main groups: polyenes (amphotericin B, natamycin, and nystatin), azoles (ketoconazole, miconazole, econazole, fluconazole, itraconazole, voriconazole, and posaconazole), allylamine (terbinafine) and echinocandins (caspofungin).

Amphotericin B has poor ocular penetration after intravenous (IV) administration and, hence, the administration of higher doses may be required to ensure adequate concentration of amphotericin B in the eye;<sup>20,43</sup> however, IV administration of high-dose amphotericin B is known to cause severe renal toxicity, which can occur in up to 80% of patients.<sup>20,43</sup> To minimize renal toxicity, low-dose amphotericin B is often used, which in many cases, results in suboptimal doses,<sup>44</sup> especially when taking its poor ocular penetration into consideration. Amphotericin B eye drops are manufactured extemporaneously by hospital pharmacy departments. The most commonly prescribed concentration of the eye drops for fungal keratitis is 0.15%.<sup>10,20</sup> Topical amphotericin B penetrates well into the stroma and can achieve sufficient concentrations against susceptible fungi;<sup>20</sup> however, its penetration through the cornea with intact epithelium is poor. Whilst amphotericin B is active against *Aspergillus* and *Candida* keratitis, it has no activity against keratitis caused by *Fusarium* species.<sup>9,45</sup>

Natamycin is the only commercially available topical antifungal preparation approved by the Food and Drug Administration for ophthalmic use.<sup>28,46</sup> It is insoluble in water

and is stable in 5% suspension.<sup>20</sup> Natamycin is the standard of care in many countries, especially developed countries,<sup>9,10,20</sup> and is initially administered as one drop every one or two hours.<sup>47</sup> It adheres well to the cornea surface, is well tolerated, has good activity against *Candida*, *Aspergillus*, and *Fusarium*, and is routinely used for keratitis caused by filamentous fungi.<sup>9,20</sup> This antifungal, however, has poor penetration into deeper structures of the eye and, hence, is generally effective against superficial infections that are not severe.<sup>9,48</sup> In addition, only about 2% of the drug is bioavailable after topical application.<sup>49</sup> The usefulness of topical natamycin is further complicated by the fact that it settles out on the cornea upon instillation and degrades easily.<sup>28</sup>

Nystatin is another polyene that can be used topically as a suspension in fungal keratitis. However, nystatin is rarely used clinically due to the availability of more potent polyene agents.<sup>50</sup>

Ketoconazole has a broad spectrum of activity, including against *Aspergillus*, *Candida*, and *Fusarium* species.<sup>28</sup> It is available orally and, although it has demonstrated good tissue distribution after administration,<sup>46</sup> it has not been used for fungal keratitis. Long-term administration of high-dose ketoconazole may result in impotence, gynecomastia, or alopecia, which is problematic considering the long-term nature of keratitis therapy.<sup>51</sup> Topical 1% eye drops and suspension formulations of ketoconazole have been extemporaneously prepared and used for fungal keratitis. These have been reported to inhibit the progression of corneal fungal infections and were not associated with significant corneal toxicity.<sup>52,53</sup>

Miconazole has been used in patients with *S. apiospermum* orbital infections.<sup>20</sup> It has a broad spectrum of activity, including against *Aspergillus*, *Candida*, and *Scedosporium* species.<sup>20</sup> Systemic miconazole, however, is associated with significant toxicity and has resulted in undetectable concentrations in the cornea.<sup>20,54</sup> Topical application of extemporaneously prepared 1% miconazole eye drops achieved high concentrations in the ocular tissues.<sup>54</sup> The eye drops are generally well tolerated and are used as second-line therapy in fungal keratitis that is unresponsive to natamycin.<sup>54</sup>

Econazole has a broad spectrum of activity against filamentous fungi, and is effective against *Fusarium* keratitis.<sup>55</sup> Topical application of 2% econazole appears to be as effective as 5% natamycin in fungal keratitis,<sup>56</sup> but has been associated with ocular irritation.<sup>55</sup>

Oral and IV fluconazole are very safe, and penetrate very well into the corneal tissue.<sup>20,57,58</sup> Whilst oral fluconazole

is a commonly used agent for the treatment of fungal keratitis,<sup>10</sup> topical application of 0.2% fluconazole solution is as effective as systemic fluconazole. Fluconazole, when applied topically, penetrates well into the cornea, is safe, and has been used successfully against fungal keratitis.<sup>59-61</sup> A major limitation associated with fluconazole, however, is its narrow spectrum of antifungal activity. Fluconazole is inactive against *Aspergillus* and *Fusarium* species;<sup>62</sup> although active against *Candida* species, it is less active against *Candida glabrata* and *Candida krusei* than against *C. albicans*.<sup>46</sup>

Although itraconazole is commonly associated with gastrointestinal side effects, it is considered relatively safe.<sup>63</sup> It has activity against *Candida* and *Aspergillus* species; however, is rarely used for the treatment of fungal keratitis.<sup>28</sup> Itraconazole is inactive against *Fusarium* species<sup>10,28</sup> but, more importantly, it has poor penetration into the cornea after systemic administration.<sup>64</sup> Experimental use of topical itraconazole (1% solution) has been reported, but appears to demonstrate insufficient corneal penetration.<sup>65</sup>

Voriconazole, a more recent azole antifungal, is available commercially for systemic administration in the form of oral and IV formulations. It has an excellent broad spectrum of antifungal activity and is active against species that are known to be resistant to the other antifungal agents commonly used in fungal keratitis.<sup>28</sup> Voriconazole is increasingly being used, orally in particular, against fungal keratitis. Oral voriconazole is highly bioavailable (96%) and has demonstrated good penetration into the different parts of the eye,<sup>66,67</sup> with sufficient concentrations achieved to cover a wide range of keratitis-causative fungi.<sup>28</sup> However, oral voriconazole can be associated with side effects as well as significant drug interactions.<sup>68</sup> Topical voriconazole eye drops, manufactured extemporaneously and used in an off-label manner, have also been prescribed for the treatment of keratitis, with promising results.<sup>69</sup> With topical administration, voriconazole demonstrated good penetration through the cornea into the aqueous humour,<sup>69</sup> without compromising intraocular safety.<sup>70</sup>

Posaconazole has an excellent broad spectrum of activity and is as active as voriconazole, with added activity against zygomycetes.<sup>71</sup> It is safe, with mild gastrointestinal side effects being the most common adverse events.<sup>72</sup> Posaconazole was only recently introduced worldwide and, as such, studies on its ocular penetration are lacking. In a number of recent case reports involving the use of oral posaconazole alone as salvage therapy, or in combination with topical posaconazole, this antifungal agent demonstrated

success against fungal keratitis.<sup>73,74</sup> The formulation used for the topical posaconazole was the same formulation used for the oral suspension (10 mg/0.1 mL).<sup>28</sup>

Terbinafine is fungicidal against many molds, but only a few types of yeast.<sup>75</sup> Despite its activity, its clinical efficacy and use are limited by its pharmacokinetic characteristics after the systemic administration.<sup>76,77</sup> When used as 0.25% eye drops, however, it is as effective against filamentous mycotic keratitis as 5% natamycin, especially in cases with smaller and shallower ulcers.<sup>78</sup> The eye drops are safe, but required longer durations of treatment when compared with other common topical therapies.<sup>78</sup>

Caspofungin has significantly less systemic toxicity than azoles. Intravenously administered caspofungin does not penetrate well into the eye and, hence, it is not used for fungal keratitis.<sup>79</sup> Nonetheless, in one recent case report, when administered topically (0.5%) as adjunctive therapy, caspofungin demonstrated clinical success against fungal keratitis.<sup>60</sup> Caspofungin is safe,<sup>79</sup> but lacks activity against *Fusarium* species.<sup>9,80</sup>

Of the aforementioned antifungal agents, amphotericin B, natamycin, fluconazole, and miconazole have been used routinely to treat fungal keratitis for quite some time; however, poor corneal penetration after topical administration, poor ocular penetration after systemic administration, limited spectra of antifungal activity, and/or limited clinical success associated with these agents are major limitations and have rendered these therapies challenging and inadequate for fungal keratitis. The limited clinical success is particularly true with the topical use of these agents, as they often require co-administration of an additional systemic antifungal agent,<sup>20</sup> which increases the risk of toxicity and is costly. This has led to consideration of using newer antifungal agents, such as voriconazole, posaconazole, and caspofungin, and/or in-house preparations of these agents as a means to overcome the shortcomings of the current therapies.

This review will focus on the use of voriconazole eye drops as a treatment for fungal keratitis.

## Topical voriconazole for fungal keratitis

Voriconazole acts by inhibiting the synthesis of ergosterol in the fungal membranes and, ultimately, the growth of the microorganism (Figure 1). Voriconazole binds to the active site of the P450-dependent enzyme lanosterol 14-demethylase (CYP51 or Erg11p) and ligates the iron heme cofactor via a nitrogen atom. This results in depletion of ergosterol and the accumulation of 14-methyl sterols such as lanosterol,

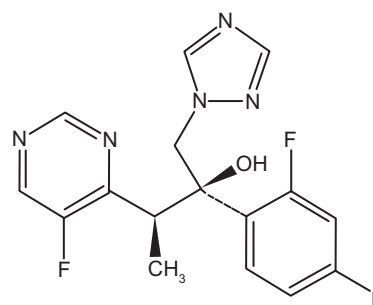


Figure 1 Chemical structure of voriconazole.<sup>83</sup>

affecting the integrity and function of the fungal membrane. Voriconazole is a derivative of fluconazole with the addition of a methyl group to the propyl backbone and the replacement of a triazole moiety with a fluoropyrimidine group, which significantly increased the affinity of the compound for 14-demethylase and its potency to inhibit CYP51. Voriconazole concentrations needed for a 50% decrease in ergosterol synthesis (IC<sub>50</sub>) in fungi extracts of *C. albicans* and *C. krusei* are 2 and 20 µg/L, respectively, compared with 10 and 230 µg/L, respectively, with fluconazole. With these two fungi, voriconazole is considered to be a more potent inhibitor of CYP51 than fluconazole. Similarly, the IC<sub>50</sub> for *Aspergillus fumigatus* is 0.48 with voriconazole against 4.8 for fluconazole.<sup>81,82</sup>

Voriconazole is ideal for use in the treatment of fungal keratitis, as it has a broad spectrum of activity with low minimum inhibitory concentrations (MIC), as well as a high systemic intraocular penetration profile.<sup>28,81</sup>

Voriconazole is potent against a wide spectrum of keratitis-causative fungi, namely, the most common pathogens *C. albicans*, *C. parapsilosis*, *C. tropicalis*, *A. fumigatus*, *Aspergillus flavus*, and *Fusarium solani*,<sup>81,84,85</sup> and other less common pathogens from the *Paecilomyces*, *Histoplasma*, *Scedosporium*, *Curvularia*, and *Acremonium* species.<sup>81,84</sup> The *in vitro* MICs of voriconazole against typical keratitis-causative fungi are shown in Table 2.

Although the MIC of voriconazole against *Fusarium* species is higher than that for other fungi, compared with other antifungal agents, voriconazole has the best activity against *Fusarium* species.<sup>86</sup> In a study by Marangon et al,<sup>86</sup> in which the *in vitro* susceptibility of common pathogens to voriconazole was compared with that for amphotericin B, fluconazole, itraconazole, and ketoconazole, voriconazole demonstrated the lowest MIC<sub>90</sub>, as shown in Table 3. In addition, voriconazole was the only antifungal agent that demonstrated 100% antifungal activity against 541 different



**Table 2** *In vitro* minimum inhibitory concentrations (MIC<sub>90</sub>) with voriconazole<sup>69,81,96</sup>

Organism	MIC <sub>90</sub> (µg/mL)
<i>Candida albicans</i>	0.06
<i>Candida parapsilosis</i>	0.12–0.25
<i>Candida tropicalis</i>	0.25–>16.0
<i>Cryptococcus neoformans</i>	0.06–0.25
<i>Aspergillus fumigatus</i>	0.50
<i>Aspergillus flavus</i>	0.50
<i>Fusarium</i> spp.	0.25–8
<i>Fusarium solani</i>	2
<i>Paecilomyces lilacinus</i>	0.50
<i>Acremonium alabamensis</i>	0.25
<i>Blastomyces dermatitidis</i>	0.25
<i>Coccidioides immitis</i>	0.25
<i>Histoplasma capsulatum</i>	0.25
<i>Penicillium marneffei</i>	0.03
<i>Cucularia</i> spp.	0.06–0.25
<i>Scedosporium</i> spp.	0.5
<i>Scedosporium apiospermum</i>	0.5

**Abbreviation:** spp, species.

fungal isolates comprising *Candida*, *Aspergillus*, and *Fusarium* species (Figure 2).

## Intraocular penetration of systemic voriconazole

In a prospective clinical study by Hariprasad et al,<sup>67</sup> systemically administered voriconazole was demonstrated to achieve good penetration into the aqueous and vitreous humors of the human eye. Two 12-hourly 400 mg doses of voriconazole were administered to 14 patients with noninflamed eyes and attending elective surgery. The aqueous and vitreous humor samples were collected within three hours after drug administration. The mean measured plasma, aqueous, and vitreous voriconazole concentrations were 2.13, 1.13, and 0.81 µg/mL, respectively. The voriconazole concentration in the aqueous humor was 53% of the concentration obtained in the plasma, and was sufficiently high to be effective against most common fungi associated with fungal keratitis. A similar outcome was reported by Nulens et al,<sup>87</sup> where a case of *S. apiospermum* keratitis was successfully treated with oral voriconazole. The voriconazole concentration in the aqueous humor (1.8 µg/mL) was measured after 12 days of drug administration and was also 53% of the voriconazole concentration observed in the patient's plasma (3.4 µg/mL). Surprisingly, however, and despite good intraocular penetration of oral voriconazole, the reported

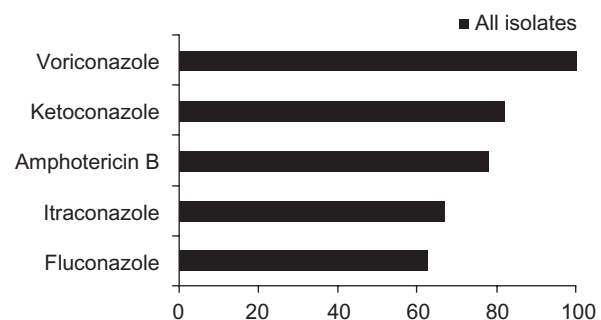
**Table 3** *In vitro* minimum inhibitory concentrations (MIC<sub>90</sub>) of common antifungals<sup>86</sup>

Antifungal agent	<i>Aspergillus</i> spp. (µg/mL)	<i>Candida</i> spp. (µg/mL)	<i>Fusarium</i> spp. (µg/mL)
Voriconazole	0.5	0.016	2
Amphotericin B	2	0.5	2
Itraconazole	1	0.256	>16
Fluconazole	>256	0.5	>256
Ketoconazole	4	0.032	>16

**Abbreviation:** spp., species.

success of oral voriconazole against fungal keratitis may not necessarily translate into success against fungal infections occurring in the posterior part of the eye (eg, endophthalmitis). Indeed, while in the case reported by Nulens et al,<sup>87</sup> oral voriconazole resulted in a voriconazole concentration in the aqueous humor that is sufficient to treat *S. apiospermum* keratitis, in a case report by Nochez et al,<sup>88</sup> the voriconazole concentration in the vitreous humor, resulting from oral voriconazole, was not sufficiently high to manage successfully an endophthalmitis infection that is also caused by *S. apiospermum*. Concomitant administration of intravitreal voriconazole was required to achieve a successful outcome.<sup>88</sup>

Although it has good intraocular penetration, systemic voriconazole may result in side effects (including ocular events), complications, and interactions with concomitant medications.<sup>68</sup> Whilst mostly reversible, these side effects may lead to the discontinuation of therapy.<sup>81</sup> In addition, systemic voriconazole is very costly. The cheapest of its formulations (ie, oral voriconazole tablets) costs about AU\$3,000 (US\$2,600) per month of therapy for fungal keratitis.<sup>61</sup> When administered intravenously, it can cost up to AU\$11,400 (US\$9,600) per month.<sup>89</sup> Therefore, an efficient and economical strategy of using voriconazole for the treatment of fungal keratitis is highly desirable and would be invaluable in clinical practice.

**Figure 2** *In vitro* susceptibility of 541 fungal isolates to common antifungals.<sup>86</sup>

## Eye drops and ophthalmic drug delivery

The topical administration of medications to the eye is a typical strategy for treating disorders of anterior eye structures, such as the cornea.<sup>90,91</sup> Eye drops are the most common dosage form used,<sup>91</sup> because they are an economical and efficient method of delivering drugs into the eye, and have four main advantages.<sup>90</sup> Firstly, the drug effect is localized where it is needed and a minimal amount of the drug reaches the systemic circulation. Secondly, drug concentrations that are hard to achieve at the site via systemic administration, can be achieved via topical administration. Thirdly, topically administered drugs avoid hepatic metabolism. Lastly, topical administration is convenient, simple, and painless.

The corneal tissues comprise three major layers of cells, ie, a lipophilic outermost layer called the epithelium, a hydrophilic middle layer called the stroma, and an innermost layer of single cells called the endothelium.<sup>92,93</sup>

Given that the cornea comprises both lipophilic and hydrophilic substances, it represents an effective barrier against delivering both lipophilic and hydrophilic drugs into the eye.<sup>90</sup> A lipophilic compound encounters minimal resistance in penetrating the outer epithelium of the cornea, but more resistance in infiltrating the stroma. The converse applies to hydrophilic compounds, which encounter more resistance to absorption from the epithelium and less by the stroma. As the corneal epithelium is the main and first barrier to drug absorption into the eye,<sup>94</sup> it is not surprising that lipophilic compounds are more favorable for corneal absorption.<sup>90</sup>

## Formulation of voriconazole eye drops

Whilst lipophilic compounds (or drugs) have higher corneal permeability, they usually have limited aqueous solubility. As such, formulating eye drops for drugs with low aqueous solubility can be challenging.<sup>90</sup> Voriconazole is a lipophilic compound with low solubility (0.061% at pH 7), and is unstable in aqueous environments.<sup>90,95</sup> For the IV formulation of voriconazole to be feasible, the manufacturer encapsulated voriconazole with a  $\beta$ -cyclodextrin derivative in the form of lyophilized powder of cyclodextrin-voriconazole complex.<sup>68</sup> This increases the solubility and stability of voriconazole in aqueous solutions, while maintaining its lipophilicity and high corneal permeability.<sup>90,94</sup> Cyclodextrins are a group of homologous cyclic oligosaccharides that, in complex formation with a drug, increase dissolution rate (solubility), aqueous stability, and/or bioavailability of the drug.<sup>94</sup>

Currently, voriconazole eye drops are not commercially available, and are aseptically manufactured<sup>61,96</sup> by diluting the IV formulation of voriconazole. IV voriconazole (Vfend®, Pfizer) is available as a glass vial that contains a white lyophilized powder containing 200 mg voriconazole and 3,200 mg sulfobutyl ether  $\beta$ -cyclodextrin sodium. As per the voriconazole package insert, the powder is reconstituted with 19 mL of water for injection to produce a 20 mL aqueous voriconazole solution with a concentration of 10 mg/mL (1%).<sup>68</sup> This voriconazole solution is what is typically being used as eye drops.<sup>96,97</sup>

Pharmacokinetic data on the corneal penetration of topically administered voriconazole are lacking; however, a number of studies have suggested good penetration of voriconazole through the cornea into the aqueous humor.

## Animal studies

Several studies have been performed to assess the penetration and tolerability of voriconazole eye drops in animals. In a study by Sponsel et al,<sup>98</sup> topical voriconazole (5 or 10  $\mu$ g/mL) was evaluated for efficacy against *Paecilomyces lilacinus* keratitis in 10 rabbits (10 infected eyes). Voriconazole demonstrated good and deep penetration into the rabbits' eyes. The measured tissue concentrations in the cornea were sufficiently high (24.3 and 51 ng/mL with 5 and 10  $\mu$ g/mL voriconazole, respectively), and the experimental keratitis was treated successfully.

Topical application of voriconazole eye drops was also investigated in a horse model by Clode et al,<sup>99</sup> where voriconazole eye drops (0.5%, 1.0%, and 3% solutions) were administered to seven healthy horses (four eyes for each concentration). With the measured aqueous humor concentrations being 1.43, 2.35, and 2.4  $\mu$ g/mL, respectively, topical voriconazole was shown to penetrate effectively through the cornea and achieve detectable levels.

It is important to recognize, however, that extrapolating penetration data from animal models to humans may not be reliable. Rabbits, for instance, have a very low blink rate and a large epithelial eye surface, which enhances the penetration of lipophilic and nonirritating drugs, such as voriconazole, into the cornea.<sup>100</sup> In addition, while the drainage rate of eye drops from the ocular surface in rabbits is about 4  $\mu$ L per minute, it is over twice as much in humans.<sup>94</sup>

## Studies in nonkeratitis patients

Three studies have investigated voriconazole penetration through the human cornea into the aqueous humor. Two of the studies investigated 1% voriconazole eye drops,<sup>61,96</sup> and one study investigated 2% voriconazole eye drops.<sup>101</sup>

In a prospective study by Vemulakonda et al,<sup>96</sup> 13 patients scheduled for vitrectomy surgery were recruited to receive a two-hourly 1% voriconazole eye drop for 24 hours. Samples were taken  $24 \pm 14$  minutes after the last dose. Topical voriconazole was well tolerated by the eye, and the mean measured voriconazole concentration in the aqueous humor was  $6.49 \pm 3.04$   $\mu\text{g/mL}$ , which is sufficiently high to be effective against common pathogens. The concentration, however, was a peak level concentration, because it was taken 24 minutes after a two-hourly dosing regimen (peak concentration is reached 20 to 30 minutes after eye drop administration).<sup>91</sup> While this study did not demonstrate that the two-hourly dosing regimen results in sustained and adequate therapeutic trough voriconazole concentrations in the eye, the ability of topically administered voriconazole eye drops to achieve high aqueous humor concentrations was demonstrated.

In another prospective study by Lau et al,<sup>61</sup> 10 patients scheduled for anterior segment surgery were recruited to receive either a 1% voriconazole eye drop every six hours for three days, or every hour for four doses. The eye drops were well tolerated, but the aqueous humor concentrations achieved were not sufficiently high to be effective against all common pathogenic fungi. After the six-hourly and hourly dosing, the voriconazole concentrations in the aqueous humor were  $0.94 \pm 1.21$  and  $1.9 \pm 1.12$   $\mu\text{g/mL}$ , with average sampling times of  $2.1 \pm 0.6$  and  $1.1 \pm 0.5$  hours after the last dose, respectively. If samples from the six-hourly regimen were to be taken six hours after the last dose (ie, at trough level), the concentrations measured would be even less than  $0.94$   $\mu\text{g/mL}$ , suggesting that six-hourly dosing of 1% voriconazole eye drops may be ineffective. Samples taken after hourly dosing were collected approximately one hour after the last dose, representing trough level concentrations. Although the measured  $1.9$   $\mu\text{g/mL}$  concentration is effective against *Aspergillus* and *Candida* keratitis, it is ineffective against other common types, such as *Fusarium* keratitis.

Al-Badriyeh et al investigated the penetration of 2% voriconazole eye drops,<sup>101</sup> with the hypothesis that increasing the concentration of voriconazole in the eye drops will increase the amount of voriconazole penetrating into the eye. Hourly 2% voriconazole eye drops were given to 13 human subjects four hours prior to elective anterior segment eye surgery. The mean voriconazole concentration in the aqueous humor was  $1.67 \pm 0.97$   $\mu\text{g/mL}$ , while the mean sampling time after the last eye drop administration was at  $1.3 \pm 0.3$  hours. No side effects or toxicities were reported. The design of this study was similar to that of Lau et al,<sup>61</sup> in that both studies had identical numbers and fre-

quencies of doses administered; trough voriconazole levels were measured; the same volumes ( $\sim 0.05$  mL) of eye drops were administered at each dose,<sup>102</sup> and 0.01% benzalkonium chloride solution (a preservative) was used as a diluent for the preparation of the eye drops. It should be noted that the clinical studies by Lau et al,<sup>61</sup> and Al-Badriyeh et al,<sup>101</sup> are the only studies in the literature that involved the use of benzalkonium chloride solution. Benzalkonium chloride is a quaternary ammonium compound with a broad range of antimicrobial activity.<sup>103</sup> It is the most frequently used preservative in ophthalmic solutions, and its concentration ranges from 0.004 to 0.02%.<sup>103</sup> In addition to preventing microbial contamination, benzalkonium chloride is known to act as a corneal penetrating enhancer, promoting drug penetration through the strong corneal barrier.<sup>104</sup> The study by Al-Badriyeh et al found that the concentration of voriconazole in the aqueous humor resulting from the 2% voriconazole eye drops was not significantly different from that reported for the 1% solution,<sup>61,101</sup> suggesting that the penetration of voriconazole through an intact infection-free cornea is not concentration-dependent, at least for the concentration range studied. This appears to be counterintuitive to the hypothesis of the study but is consistent with data from the horse model by Clode et al,<sup>99</sup> in which the voriconazole level in the corneas of horses with fungal keratitis did not change when the concentration of the administered voriconazole eye drops was changed from 1% to 3%.

The studies by Vemulakonda et al, Lau et al, and Al-Badriyeh et al explored the penetration of voriconazole eye drops into the human aqueous humor using different dosage regimens and concentrations.<sup>61,96,101</sup> However, it is important to recognize the major limitation of these studies, ie, that the eye drops were applied to noninfected eyes. It has been widely observed that corneal drug penetration will generally be enhanced with the destruction of the corneal epithelium.<sup>105</sup> For instance, the removal of the surface of the corneal epithelium is recommended to improve the penetration of topical amphotericin B.<sup>100</sup> On the other hand, in the rabbit model by Sponsel et al,<sup>98</sup> when the penetration of topical voriconazole into the infected eyes was compared with penetration into the noninfected eyes of the rabbits, it was found that the corneal concentration of voriconazole in the noninfected eyes (after topical administration) was higher than that in the infected corneas. However, in a recent case series by Thiel et al (where voriconazole concentrations in the aqueous humor, following the administration of voriconazole eye drops, were compared among patients with different degrees of corneal injuries) voriconazole concentrations in the infected eyes depended



neither on the size of the epithelial defect nor on epithelial removal.<sup>100</sup> These, however, are preliminary findings, and the effect of corneal damage on the penetration of voriconazole into the human eye remains to be fully elucidated.

## Studies in keratitis patients

To date, the penetration of topical voriconazole eye drops through the infected cornea in humans has only been reported twice, and in the form of case reports. In the case reported by Klont et al,<sup>69</sup> the aqueous humor voriconazole concentration was measured after 13 days of topical 1% voriconazole, co-administered with oral voriconazole, for the treatment of a patient with *Fusarium* keratitis. The advantage of topical voriconazole was demonstrated by an aqueous humor concentration of 3.2 µg/mL, which was 160% of the voriconazole concentration in plasma (2 µg/mL). In the previously mentioned case series by Thiel et al,<sup>100</sup> six patients, including five patients with fungal keratitis, received IV and topical voriconazole for the treatment of *Aspergillus* and *Candida* infections. The aqueous humor samples were collected at stages of therapy where voriconazole eye drops were used alone, yielding voriconazole concentrations ranging from 0.61 to 3.3 µg/mL. The results were highly variable, but provided support for the benefit of using voriconazole eye drops.

## Efficacy

Although voriconazole concentrations were detected in the aqueous humor after topical administration of voriconazole eye drops, this may not necessarily correlate with efficacy in the clinical setting of fungal keratitis.<sup>20</sup> Well-designed clinical studies of voriconazole eye drops in patients with active fungal keratitis are difficult to perform and, therefore, lacking. The difficulties in conducting such studies relate to the low incidence of fungal keratitis as well as the need for long treatment duration. In addition, in clinical settings, patients will mostly be receiving other antifungal therapies that will interfere with the outcomes measured.

Currently, evidence of the clinical efficacy of voriconazole eye drops in fungal keratitis is based solely on case reports. A review of the published literature identified nine reports on the use of voriconazole eye drops for the treatment of fungal keratitis.<sup>69,74,106–111</sup> The case reports are summarized in Table 4.

In most of the reported cases, voriconazole eye drops were used in combination with systemic voriconazole, except for the case reports by Al-Badriyeh et al,<sup>110,111</sup> where voriconazole eye drops were used as monotherapy. Voriconazole 1% eye

drops were used in all cases, except in the case reported by Polizzi et al,<sup>106</sup> where 2% voriconazole was used. Brief summaries of these cases are given below.

The first of these cases, reported by Reis et al,<sup>108</sup> involved a 16-year-old girl diagnosed with keratitis caused by *F. solani* after swimming in a lake. After months of antifungal therapy, the fungal keratitis failed to respond. The patient was initially prescribed topical amphotericin B and fluconazole, followed by itraconazole at a later stage. These, however, had no effect on the infection and, hence, IV voriconazole followed by oral voriconazole was administered. A significant improvement was noticed, followed by resolution upon the addition of topical voriconazole to therapy, which was discontinued after eight weeks.

The case report by Klont et al also reported the use of 1% voriconazole eye drops in the treatment of *Fusarium* keratitis.<sup>69</sup> A 23-year-old man with *F. solani* keratitis failed to respond to treatment despite initial topical amphotericin B and itraconazole. The patient was then prescribed, as salvage therapy, concomitant IV and topical voriconazole followed by oral and topical voriconazole. The treatment was ceased at week 6, with a successful outcome.

In the case report by Prats et al,<sup>107</sup> a 19-year-old man was admitted with an incisive eye wound, with the cornea totally sectioned upon trauma. *S. apiospermum* keratitis was diagnosed. Upon failure of initial empirical antifungal therapy, systemic (IV and oral) and topical voriconazole were commenced. The infection resolved, and the eye did not have to be enucleated. This was the first case report where voriconazole was used for the treatment of *S. apiospermum* keratitis. Five months after the incident, a penetrating keratoplasty and chamber intraocular lens implantation was performed with a favorable visual outcome.

Jones et al demonstrated that voriconazole was effective in a 52-year-old woman diagnosed with *Aspergillus niger* keratitis.<sup>109</sup> The patient was initially treated with topical amphotericin B, which was not effective. When the patient was switched to a combination of oral and topical voriconazole, the infection improved rapidly and resolved after five weeks.

In the first of the two cases reported by Tu et al,<sup>74</sup> a 29-year-old man received oral and topical voriconazole for the treatment of trauma-induced *Fusarium* keratitis. In the second case, a 43-year-old woman received a combination of IV, topical, and intravitreal voriconazole for keratitis caused by *F. solani* that was associated with contact lens wear. In both of these cases, voriconazole was initially effective until it had to be discontinued because of severe

**Table 4** Case reports of the use of topical voriconazole in fungal keratitis<sup>69,74,106–111</sup>

Author	Patient (age, sex)	Pathogen	Voriconazole concentration	Treatment	Outcome	Systemic voriconazole
Reis et al	16, female	<i>Fusarium solani</i>	1%	Salvage	Success	Intravenous voriconazole 6 mg/kg twice daily on day 1, followed by intravenous voriconazole 4 mg/kg twice daily until day 11. Oral voriconazole 6 mg/kg twice daily was then given for eight weeks
Klont et al	23, male	<i>Fusarium solani</i>	1%	Salvage	Success	Intravenous voriconazole 6 mg/kg twice daily on day 1, followed by intravenous voriconazole 4 mg/kg twice daily for two weeks. Oral voriconazole 200 mg twice daily was then given for two weeks
Prats et al	19, male	<i>Scedosporium apiospermum</i>	1%	Salvage	Success	Oral voriconazole 200 mg twice daily for six weeks
Jones et al	52, female	<i>Aspergillus niger</i>	1%	Salvage	Success	Oral voriconazole 200 mg twice daily for five weeks
Tu et al	29, male	<i>Fusarium species</i>	1%	Primary	Failure	Oral voriconazole 200 mg twice daily for five weeks
Tu et al	43, female	<i>Fusarium solani</i>	1%	Primary	Failure	Intravenous voriconazole 200 mg twice daily on day 1, followed by oral voriconazole 200 mg twice daily for six weeks
Al-Badriyeh et al	54, female	<i>Scedosporium apiospermum</i>	1%	Salvage	Success	None
Al-Badriyeh et al	48, male	<i>Candida albicans</i>	1%	Primary	Success	None
Polizzi et al	56, male	<i>Fusarium solani</i>	2%	Salvage	Success	Intravenous voriconazole 400 mg twice daily on day 1, followed by intravenous voriconazole 300 mg twice daily until day 15. Oral voriconazole 200 mg twice daily was then given for four weeks

hepatotoxicity. Patients were then switched to posaconazole as salvage therapy.

In the two case reports by Al-Badriyeh et al,<sup>110,111</sup> 1% voriconazole was used as a stand-alone therapy. In one case report,<sup>110</sup> a 54-year-old woman presented with a painful injected eye. Despite empirical therapy, symptoms persisted. Keratitis was later diagnosed and identified as a rare *S. apiospermum* keratitis. Primary antifungal therapy with natamycin 5% was not successful and was switched to 1% voriconazole eye drops. Vision improved in five days, and the corneal defect completely re-epithelialized in a week. In the other report by Al-Badriyeh et al,<sup>111</sup> a 48-year-old presented with keratitis following exposure to dust, the cause of which was later identified as *C. albicans*. Despite empirical antibacterial therapy, the epithelial defect persisted. Primary antifungal therapy with 1% voriconazole eye drops was initiated. The corneal infiltrate resolved in two days,

the epithelial defect was completely healed, and visual acuity was restored in seven days.

Polizzi et al reported the only case where 2% voriconazole eye drops were used.<sup>106</sup> A 56-year-old man developed corneal ulceration caused by *F. solani* upon accidental contact with vegetation. Corneal ulceration developed and a perforating keratoplasty was performed. Systemic and topical amphotericin B and fluconazole were administered initially, but the patient did not improve. A new abscess formed on the transplanted graft and a wound leak developed. Therapy was then switched to IV and oral voriconazole in combination with topical 2% voriconazole eye drops. The patient completely recovered after 20 days of treatment with voriconazole.

A number of important considerations are associated with the above cases. One is that the use of voriconazole eye drops was associated with successful outcomes in most cases of fungal keratitis. Whilst the voriconazole therapy appeared to

fail in the cases reported by Tu et al,<sup>74</sup> the failure was not due to lack of efficacy, but to severe side effects from systemically administered voriconazole, which required discontinuation of treatment. A second issue is that voriconazole eye drops were used as an adjunct to systemic voriconazole in most reported cases. Only Al-Badriyeh et al have demonstrated the clinical benefit of topical voriconazole when used alone as primary and salvage therapies.<sup>110,111</sup> Thirdly, whilst the 2% voriconazole eye drops were effective,<sup>106</sup> the advantage of using 2% compared with 1% voriconazole eye drops remains unknown. A fourth issue is that, in the reports by Al-Badriyeh et al,<sup>110,111</sup> the voriconazole eye drops were prepared as a solution containing 0.01% benzalkonium chloride as preservative, whereas, in all other case reports, the eye drops were prepared in sterile water for injection. In these case reports, voriconazole eye drops were typically administered with a dosing frequency of one drop every 0.5, 1.0, or 2.0 hours,<sup>69,74,106–111</sup> and the average duration of administration of the voriconazole eye drops as adjunct therapy (ie, one to two months) was similar to the average duration of administration of the voriconazole eye drops given as monotherapy (ie, one month). However, it is common for the administration of the eye drops to extend beyond the resolution of fungal keratitis, with a duration that is more related to local clinical practices rather than time to resolution.

## Safety

The safety of voriconazole in the eye was first evaluated in a rat model by Gao et al,<sup>85</sup> who demonstrated that intravitreal voriconazole concentration as high as 25 mg/mL did not result in any electroretinographic or histologic abnormalities in the rat retina. This, however, cannot be extrapolated as an evidence of the safety of voriconazole when topically applied to the human cornea.

In a stability study by Al-Badriyeh et al,<sup>112</sup> changes in the pH of 1% and 2% voriconazole eye drops were followed for over three months, and were found to range between 6.02 and 6.27. This was consistent with the findings of the only other stability study of voriconazole eye drops, performed by Dupuis et al,<sup>97</sup> where a pH of 7 was maintained for 1% voriconazole eye drops with a storage duration of 30 days. These pH values are usually well tolerated by the eye.<sup>112</sup> It is unlikely, therefore, that any eye irritation resulting from the use of the voriconazole eye drops would be a consequence of low pH.

Indeed, in the above studies that evaluated the application of voriconazole eye drops to the eye of animals and humans, the drops were well tolerated, and associated with mild or no side effects. In the animal model by Sponset et al,<sup>98</sup> all rabbits

responded well to the voriconazole eye drops with no apparent side effects. In the horse model by Clode et al,<sup>99</sup> 0.5% and 1% voriconazole eye drops resulted in no side effects, and only the higher 3% concentration was associated with ocular toxicity. In the clinical study by Vemulakonda et al,<sup>96</sup> only two patients reported a mild transient stinging sensation on instillation of the 1% voriconazole eye drops. Visualization was excellent in all 13 patients. Of the 10 patients in the study by Lau et al,<sup>61</sup> four patients reported one or two instances of mild stinging, and one patient reported sneezing after the initial dose. None of the patients in the clinical study by Al-Badriyeh et al reported any side effects with the 2% voriconazole eye drops.<sup>101</sup> These outcomes were consistent with the outcome in another study by Lau et al that evaluated voriconazole penetration into the vitreous humor of the eye after topical application of the eye drops.<sup>113</sup> Here also, no side effects were reported. Similarly, in all of the case reports of using topical voriconazole in fungal keratitis, the eye drops were well tolerated with no side effects reported.<sup>69,74,106–111</sup>

Systemic side effects resulting from the topical administration of the voriconazole solution should be negligible. In the case of the 2% eye drops (the highest concentration that has been reported in humans), each drop contains only 0.001 mg of voriconazole which, when compared with the standard systemic dose of 200 mg oral or IV voriconazole twice daily,<sup>68</sup> is unlikely to result in systemic concentration that is high enough to induce side effects.

## Stability of voriconazole eye drops

According to the stability study by Al-Badriyeh et al,<sup>112</sup> 1% voriconazole eye drops, prepared in sterile benzalkonium chloride 0.01% solution, were stable for at least 14 weeks when stored at 2–8°C, while 2% voriconazole eye drops, also prepared in sterile benzalkonium chloride solution, were stable for 16 weeks at 2–8, 25, and 40°C. This was consistent with the stability study by Dupuis et al,<sup>97</sup> where 1% voriconazole eye drops, prepared in sterile water for injection, were stable for at least four weeks when stored at 4°C. Such long-term stability data will help minimize wastage and is pivotal to facilitate the use of the eye drops in the outpatient setting.

## Patient adherence and satisfaction

Given the observed efficacy, safety, and stability, voriconazole eye drops appear to be a good option in the treatment of fungal keratitis. However, non-adherence to the prescribed dosing regimen may pose a challenge to achieving the desired treatment outcome and, consequently, lead to progression of

the infection. The benefits of using voriconazole eye drops, especially in the outpatient setting, could be diminished due to poor patient adherence if the dosing regimen is intense (eg, hourly to two-hourly drops) and is for an extended duration. The outpatient setting is different from the situation in clinical studies, in which maximal compliance can be achieved because the eye drops are often administered by nursing staff in hospitals.<sup>100</sup> To date, there are no published data available about patient adherence to voriconazole eye drops.

The appropriate dosing frequency of voriconazole eye drops is not clear. The voriconazole aqueous humor concentration measured by Vemulakonda et al ( $6.49 \pm 3.04$  mg/L),<sup>96</sup> where 1% eye drops were administered every two hours for 24 hours, is more than three times the concentration reported by Lau et al ( $1.90 \pm 1.12$  mg/L),<sup>61</sup> where one drop was administered every hour for four hours. Based on these data, it is tempting to assume that the higher concentration measured by Vemulakonda et al was a result of drug accumulation in the eye; however, the significant difference in the post-dose sampling time (0.4 hours versus 1.1 hours in the Vemulakonda et al and Lau et al studies, respectively) could have been the key factor behind the differences in the measured voriconazole level in the aqueous humor.

## Conclusion

Voriconazole eye drops appear to be effective when used for the treatment of fungal keratitis caused by a variety of fungi, including *F. solani*, *C. albicans*, *S. apiospermum*, and *A. niger*. The eye drops are well tolerated in the reported clinical trials and case studies. In addition, stability data for the extemporaneously prepared eye drops are available, minimizing the manufacturing cost and wastage associated with the eye drops.

Case reports have shown that voriconazole eye drops are effective when used as adjunctive therapy or monotherapy, and as primary or salvage therapy for the management of ophthalmic fungal keratitis. However, the number of these case reports and, hence, their significance remains limited. Whilst large-scale, randomized, controlled studies are needed, such studies are difficult to conduct and, consequently, audits or large case series on the use of voriconazole eye drops as monotherapy are necessary to confirm current findings and help establish the extent of their effectiveness.

Increasing the concentration of voriconazole eye drops may lead to increased efficacy and/or reduced dosing

frequency; however, the benefit of using concentrations greater than 1% has not been evaluated in patients with fungal keratitis beyond a single case report. Studies using intact corneas have suggested concentration-independent penetration of voriconazole through the cornea and, consequently, it appears that administering 2% over 1% voriconazole eye drops in fungal keratitis is unlikely to give any additional benefit. Although some studies have suggested that epithelial damage is not necessary for voriconazole penetration, future studies that evaluate the penetration of 2% versus 1% voriconazole eye drops in patients with fungal keratitis, despite being difficult to perform, will be important. Given that the optimal dosing of the voriconazole eye drops remains unknown, studies to investigate the extent of voriconazole clearance from the human eye after topical administration should be conducted to guide the dosing frequency.

Current literature has provided some evidence on the effectiveness of voriconazole eye drops for the treatment of fungal keratitis; however, more data are required before a definite conclusion regarding their utility is drawn.

## Disclosures

The authors report no financial or other conflicts of interest in this work.

## References

- Whitcher J, Srinivasan M, Upadhyay M. Corneal blindness: A global perspective. *Bull World Health Organ*. 2001;79(3):214–221.
- Dandona L, Dandona R, Naduvilath T, et al. Is current eye-care-policy focus almost exclusively on cataract adequate to deal with blindness in India? *Lancet*. 1998;351(9112):1312–1316.
- Levin L, Avery R, Shore J, Woog J, Baker A. The spectrum of orbital aspergillosis: A clinicopathological review. *Surv Ophthalmol*. 1996;41(2):142–154.
- Yohai R, Bullock J, Aziz A, Markert R. Survival factors in rhino-orbital-cerebral mucormycosis. *Surv Ophthalmol*. 1994;39(1):3–22.
- See J, Wong T, Yeo K. Trends in the pattern of blindness and major ocular diseases in Singapore and Asia. *Ann Acad Med Singapore*. 1998;27(4):540–546.
- Hagan M, Wright E, Newman M, Dolin P, Johnson G. Causes of suppurative keratitis in Ghana. *Br J Ophthalmol*. 1995;79(11):1024–1028.
- Puttanna S. Primary keratomycosis. *J All India Ophthalmol Soc*. 1969;17(5):171–200.
- Galarreta D, Tuft S, Ramsay A, Dart J. Fungal keratitis in London: Microbiological and clinical evaluation. *Cornea*. 2007;26(9):1082–1086.
- Srinivasan M. Fungal keratitis. *Curr Opin Ophthalmol*. 2004;15(4):321–327.
- Bhartiya P, Daniell M, Constantinou M, Islam F, Taylor H. Fungal keratitis in Melbourne. *Clin Experiment Ophthalmol*. 2007;35(2):124–130.
- Nelson PE, Dignani MC, Anaissie EJ. Taxonomy, biology, and clinical aspects of *Fusarium* species. *Clin Microbiol Rev*. 1994;7(4):479–504.
- Thomas P. Mycotic keratitis – an underestimated mycosis. *J Med Vet Mycol*. 1994;32(4):235–256.



13. Gopinathan U, Garg P, Fernandes M, Sharma S, Athmanathan S, Rao G. The epidemiological features and laboratory results of fungal keratitis: A 10-year review at a referral eye care center in South India. *Cornea*. 2002;21(6):555–559.
14. Rosa R, Miller D, Alfonso E. The changing spectrum of fungal keratitis in south Florida. *Ophthalmology*. 1994;101(6):1005–1013.
15. Cuero RG. Ecological distribution of *Fusarium solani* and its opportunistic action related to mycotic keratitis in Cali, Colombia. *J Clin Microbiol*. 1980;12(3):455–461.
16. Stevens D, Kan V, Judson M, et al. Practice guidelines for diseases caused by aspergillus. Infectious Diseases Society of America. *Clin Infect Dis*. 2000;30(4):696–709.
17. Tabbara K, al Jabarti A. Hospital construction-associated outbreak of ocular aspergillosis after cataract surgery. *Ophthalmology*. 1998;105(3):522–526.
18. Smolin G, Foster CS, Azar DT, Dohlman CH. *The Cornea: Scientific Foundations and Clinical Practice*. 4th ed. Philadelphia, PA: Lippincott Williams & Wilkins Inc.; 2005.
19. Klintworth G. The cornea – structure and macromolecules in health and disease. A review. *Am J Pathol*. 1977;89(3):718–808.
20. Thomas PA. Current perspectives on ophthalmic mycoses. *Clin Microbiol Rev*. 2003;16(4):730–797.
21. Gordon M, Norton S. Corneal transplant infection by *Paecilomyces lilacinus*. *Sabouraudia*. 1985;23(4):295–301.
22. Kozarsky A, Stulting R, Waring G, Cornell F, Wilson L, Cavanagh H. Penetrating keratoplasty for exogenous *Paecilomyces* keratitis followed by postoperative endophthalmitis. *Am J Ophthalmol*. 1984;98(5):552–557.
23. Fincher R, Fisher J, Lovell R, Newman C, Espinel-Ingroff A, Shadomy H. Infection due to the fungus *Acremonium* (cephalosporium). *Medicine (Baltimore)*. 1991;70(6):398–409.
24. Guarro J, Gams W, Pujol I, Gene J. *Acremonium* species: New emerging fungal opportunists – in vitro antifungal susceptibilities and review. *Clin Infect Dis*. 1997;25(5):1222–1229.
25. Garg P, Gopinathan U, Choudhary K, Rao G. Keratomycosis: Clinical and microbiologic experience with dematiaceous fungi. *Ophthalmology*. 2000;107(3):574–580.
26. Jones B. Principles in the management of oculomycosis. XXXI Edward Jackson memorial lecture. *Am J Ophthalmol*. 1975;79(5):719–751.
27. Stern G, Buttross M. Use of corticosteroids in combination with antimicrobial drugs in the treatment of infectious corneal disease. *Ophthalmology*. 1991;98(6):847–853.
28. Hariprasad SM, Mieler WF, Lin TK, Sponkel WE, Graybill JR. Voriconazole in the treatment of fungal eye infections: A review of current literature. *Br J Ophthalmol*. 2008;92(7):871–878.
29. Fairley C, Sullivan T, Bartley P, Allworth T, Lewandowski R. Survival after rhino-orbital-cerebral mucormycosis in an immunocompetent patient. *Ophthalmology*. 2000;107(3):555–558.
30. Marshall D, Brownstein S, Jackson W, Mintsoulis G, Gilberg S, al-Zeerah B. Post-traumatic corneal mucormycosis caused by *Absidia corymbifera*. *Ophthalmology*. 1997;104(7):1107–1011.
31. Mino de Kaspar H, Zoulek G, Paredes M, et al. Mycotic keratitis in Paraguay. *Mycoses*. 1991;34(5–6):251–254.
32. Panda A, Sharma N, Das G, Kumar N, Satpathy G. Mycotic keratitis in children: Epidemiologic and microbiologic evaluation. *Cornea*. 1997;16(3):295–299.
33. Tanure M, Cohen E, Sudesh S, Rapuano C, Laibson P. Spectrum of fungal keratitis at Wills Eye Hospital, Philadelphia, Pennsylvania. *Cornea*. 2000;19(3):307–312.
34. Srinivasan M, Gonzales CA, George C, et al. Epidemiology and aetiological diagnosis of corneal ulceration in Madurai, south India. *Br J Ophthalmol*. 1997;81(11):965–971.
35. Sony P, Sharma N, Vajpayee R, Ray M. Therapeutic keratoplasty for infectious keratitis: A review of the literature. *CLAO J*. 2002;28(3):111–118.
36. Dunlop A, Wright E, Howlader S, et al. Suppurative corneal ulceration in Bangladesh. A study of 142 cases examining the microbiological diagnosis, clinical and epidemiological features of bacterial and fungal keratitis. *Aust N Z J Ophthalmol*. 1994;22(2):105–110.
37. Wong T, Ng T, Fong K, Tan D. Risk factors and clinical outcomes between fungal and bacterial keratitis: A comparative study. *CLAO J*. 1997;23(4):275–281.
38. Clinch T, Robinson M, Barron B, Insler M, Liang K, Kaufman H. Fungal keratitis from nylon line lawn trimmers. *Am J Ophthalmol*. 1992;114(4):437–440.
39. Okhravi N, Dart JK, Towler HM, Lightman S. *Paecilomyces lilacinus* endophthalmitis with secondary keratitis: A case report and literature review. *Arch Ophthalmol*. 1997;115(10):1320–1324.
40. Manzouri B, Vafidis G, Wyse R. Pharmacotherapy of fungal eye infections. *Expert Opin Pharmacother*. 2001;2(11):1849–1857.
41. FlorCruz NV, Peczon Jr I. Medical interventions for fungal keratitis. *Cochrane Database Syst Rev*. 2008;CD004241.
42. O'Day D. Selection of appropriate antifungal therapy. *Cornea*. 1987;6(4):238–245.
43. Khoo SH, Bond J, Denning DW. Administering amphotericin B – a practical approach. *J Antimicrob Chemother*. 1994;33(2):203–213.
44. Bates D, Su L, Yu D, et al. Mortality and costs of acute renal failure associated with amphotericin B therapy. *Clin Infect Dis*. 2001;32(5):686–693.
45. O'Day D, Head W, Robinson R, Clanton J. Corneal penetration of topical amphotericin B and natamycin. *Curr Eye Res*. 1986;5(11):877–882.
46. O'Brien TP. Therapy of ocular fungal infections. *Ophthalmol Clin North Am*. 1999;12:33–50.
47. Natamycin [Package insert]. Alcon Laboratories Inc., Texas, May 2008.
48. Panda A, Sharma N, Angra S. Topical fluconazole therapy of *Candida* keratitis. *Cornea*. 1996;15(4):373–375.
49. Seal D, Pleyer U. *Ocular Infection and Immunity*. 2nd ed. New York, NY: Informa Healthcare Inc.; 2007.
50. Ganegoda N, Rao SK. Antifungal therapy for keratomycoses. *Expert Opin Pharmacother*. 2004;5(4):865–874.
51. O'Day D, Head W, Robinson R, Williams T, Gedde S. Anomalous effect of subconjunctival miconazole on *Candida albicans* keratitis in rabbits. *Am J Ophthalmol*. 1991;112(5):562–566.
52. Torres MA, Mohamed J, Cavazos-Adame H, Martinez LA. Topical ketoconazole for fungal keratitis. *Am J Ophthalmol*. 1985;100(2):293–298.
53. Foster CS, Lass JH, Moran-Wallace K, Giovanoni R. Ocular toxicity of topical antifungal agents. *Arch Ophthalmol*. 1981;99(6):1081–1084.
54. Foster CS, Stefanyshyn M. Intraocular penetration of miconazole in rabbits. *Arch Ophthalmol*. 1979;97(9):1703–1706.
55. Thomas PA. Fungal infections of the cornea. *Eye (Lond)*. 2003;17(8):852–862.
56. Prajna NV, John RK, Nirmalan PK, Lalitha P, Srinivasan M. A randomised clinical trial comparing 2% econazole and 5% natamycin for the treatment of fungal keratitis. *Br J Ophthalmol*. 2003;87(10):1235–1237.
57. Avunduk A, Beuerman R, Warnel E, Kaufman H, Greer D. Comparison of efficacy of topical and oral fluconazole treatment in experimental *Aspergillus* keratitis. *Curr Eye Res*. 2003;26(2):113–117.
58. Nunery W, Welsh M, Saylor R. *Pseudallescheria boydii* (Petriellidium boydii) infection of the orbit. *Ophthalmic Surg*. 1985;16(5):296–300.
59. Sonogo-Krone S, Sanchez-Di Martin D, Ayala-Lugo R, et al. Clinical results of topical fluconazole for the treatment of filamentous fungal keratitis. *Graefes Arch Clin Exp Ophthalmol*. 2006;244(7):782–787.
60. Tu E. *Alternaria* keratitis: Clinical presentation and resolution with topical fluconazole or intrastromal voriconazole and topical caspofungin. *Cornea*. 2009;28(1):116–119.
61. Lau D, Fedinands M, Leung L, et al. Penetration of voriconazole, 1%, eyedrops into human aqueous humor: A prospective open-label study. *Arch Ophthalmol*. 2008;126(3):343–346.
62. Rao S, Madhavan H, Rao G, Padmanabhan P. Fluconazole in filamentous fungal keratitis. *Cornea*. 1997;16(6):700.
63. Rajasekaran J, Thomas P, Kalavathy C, Joseph P, Abraham D. Itraconazole therapy for fungal keratitis. *Indian J Ophthalmol*. 1987;35(5–6):157–160.



64. Savani DV, Perfect JR, Cobo LM, Durack DT. Penetration of new azole compounds into the eye and efficacy in experimental *Candida* endophthalmitis. *Antimicrob Agents Chemother.* 1987;31(1):6–10.
65. Vanden Bossche H, Mackenzie D, Cauwenbergh G. *Aspergillus and Aspergillosis*. New York, NY: Plenum Press Inc.; 1988.
66. Johnson L, Kauffman C. Voriconazole: A new triazole antifungal agent. *Clin Infect Dis.* 2003;36(5):630–637.
67. Hariprasad SM, Mieler WF, Holz ER, et al. Determination of vitreous, aqueous, and plasma concentration of orally administered voriconazole in humans. *Arch Ophthalmol.* 2004;122(1):42–47.
68. Vfend [Package insert]. New York, NY: Pfizer Inc.; March 2008.
69. Klont R, Eggink C, Rijs A, Wesseling P, Verweij P. Successful treatment of *Fusarium* keratitis with cornea transplantation and topical and systemic voriconazole. *Clin Infect Dis.* 2005;40(12):e110–e112.
70. Gao H, Pennesi ME, Shah K, et al. Intravitreal voriconazole: An electroretinographic and histopathologic study. *Arch Ophthalmol.* 2004;122(11):1687–1692.
71. Torres H, Hachem R, Chemaly R, Kontoyiannis D, Raad I. Posaconazole: A broad-spectrum triazole antifungal. *Lancet Infect Dis.* 2005;5(12):775–785.
72. Ullmann AJ, Cornely OA, Burchardt A, et al. Pharmacokinetics, safety, and efficacy of posaconazole in patients with persistent febrile neutropenia or refractory invasive fungal infection. *Antimicrob Agents Chemother.* 2006;50(2):658–666.
73. Sponcel WE, Graybill JR, Nevarez HL, Dang D. Ocular and systemic posaconazole (SCH-56592) treatment of invasive *Fusarium solani* keratitis and endophthalmitis. *Br J Ophthalmol.* 2002;86(7):829–830.
74. Tu E, McCartney D, Beatty R, Springer K, Levy J, Edward D. Successful treatment of resistant ocular fusariosis with posaconazole (SCH-56592). *Am J Ophthalmol.* 2007;143(2):222–227.
75. Abdel-Rahman S, Nahata M. Oral terbinafine: A new antifungal agent. *Ann Pharmacother.* 1997;31(4):445–456.
76. Jensen J. Clinical pharmacokinetics of terbinafine (Lamisil). *Clin Exp Dermatol.* 1989;14(2):110–113.
77. Nedelman JR, Gibiansky E, Robbins B, et al. Pharmacokinetics and pharmacodynamics of multiple-dose terbinafine. *J Clin Pharmacol.* 1996;36(5):452–461.
78. Liang QF, Jin XY, Wang XL, Sun XG. Effect of topical application of terbinafine on fungal keratitis. *Chin Med J (Engl).* 2009;122(16):1884–1888.
79. Goldblum D, Frueh BE, Sarra GM, Katsoulis K, Zimmerli S. Topical caspofungin for treatment of keratitis caused by *Candida albicans* in a rabbit model. *Antimicrob Agents Chemother.* 2005;49(4):1359–1363.
80. Lalitha P, Shapiro BL, Srinivasan M, et al. Antimicrobial susceptibility of *Fusarium*, *Aspergillus*, and other filamentous fungi isolated from keratitis. *Arch Ophthalmol.* 2007;125(6):789–793.
81. Jurkunas U, Langston D, Colby K. Use of voriconazole in the treatment of fungal keratitis. *Int Ophthalmol Clin.* 2007;47(2):47–59.
82. Leveque D, Nivoix Y, Jehl F, Herbrecht R. Clinical pharmacokinetics of voriconazole. *Int J Antimicrob Agents.* 2006;27(4):274–284.
83. Carrillo-Munoz A, Quindos G, JL LR. Current development in antifungal agents. *Curr Med Chem.* 2004;3(4):297–323.
84. Breit S, Hariprasad S, Mieler W, Shah G, Mills M, Grand M. Management of endogenous fungal endophthalmitis with voriconazole and caspofungin. *Am J Ophthalmol.* 2005;139(1):135–140.
85. Gao H, Pennesi M, Shah K, et al. Safety of intravitreal voriconazole: Electroretinographic and histopathologic studies. *Trans Am Ophthalmol Soc.* 2003;101:183–189.
86. Marangon F, Miller D, Giaconi J, Alfonso E. In vitro investigation of voriconazole susceptibility for keratitis and endophthalmitis fungal pathogens. *Am J Ophthalmol.* 2004;137(5):820–825.
87. Nulens E, Eggink C, Rijs AJMM, Wesseling P, Verweij PE. Keratitis caused by *Scedosporium apiospermum* successfully treated with a cornea transplant and voriconazole. *J Clin Microbiol.* 2003;41(5):2261–2264.
88. Nochez Y, Arsene S, Le Guellec C, et al. Unusual pharmacokinetics of intravitreal and systemic voriconazole in a patient with *Scedosporium apiospermum* endophthalmitis. *J Ocul Pharmacol Ther.* 2008;24(1):87–90.
89. Stewart A, Powles R, Hewetson M, Antrum J, Richardson C, Mehta J. Costs of antifungal prophylaxis after bone marrow transplantation. A model comparing oral fluconazole, liposomal amphotericin and oral polyenes as prophylaxis against oropharyngeal infections. *Pharmacoeconomics.* 1995;8(4):350–361.
90. Davies N. Biopharmaceutical considerations in topical ocular drug delivery. *Clin Exp Pharmacol Physiol.* 2000;27(7):558–562.
91. Urtti A. Challenges and obstacles of ocular pharmacokinetics and drug delivery. *Adv Drug Deliv Rev.* 2006;58(11):1131–1135.
92. Forrester JV, Dick AD, Roberts F. *The Eye: Basic Sciences in Practice: Basic Science in Practice*. 2nd ed. London, UK: Saunders Ltd; 2002.
93. Klotz S, Penn C, Negvesky G, Butrus S. Fungal and parasitic infections of the eye. *Clin Microbiol Rev.* 2000;13(4):662–685.
94. Jtirvinen K, Urtti A. Ocular absorption following topical delivery. *Adv Drug Deliv Rev.* 1995;16(1):3–19.
95. Silveira FP, Husain S. Fungal infections in solid organ transplantation. *Med Mycol.* 2007;45(4):305–320.
96. Vemulakonda GA, Hariprasad SM, Mieler WF, Prince RA, Shah GK, Van Gelder RN. Aqueous and vitreous concentrations following topical administration of 1% voriconazole in humans. *Arch Ophthalmol.* 2008;126(1):18–22.
97. Dupuis A, Tournier N, Le Moal G, Venisse N. Preparation and stability of voriconazole eye drop solution. *Antimicrob Agents Chemother.* 2009;53(2):798–799.
98. Sponcel W, Chen N, Dang D, et al. Topical voriconazole as a novel treatment for fungal keratitis. *Antimicrob Agents Chemother.* 2006;50(1):262–268.
99. Clode A, Davis J, Salmon J, Michau T, Gilger B. Evaluation of concentration of voriconazole in aqueous humor after topical and oral administration in horses. *Am J Vet Res.* 2006;67(2):296–301.
100. Thiel MA, Zinkernagel AS, Burhenne J, Kaufmann C, Haefeli WE. Voriconazole concentration in human aqueous humor and plasma during topical or combined topical and systemic administration for fungal keratitis. *Antimicrob Agents Chemother.* 2007;51(1):239–244.
101. Al-Badriyeh D, Leung L, Roydhouse T, et al. Prospective open-label study of the administration of two-percent voriconazole eye drops. *Antimicrob Agents Chemother.* 2009;53(7):3153–3155.
102. Lau D. Penetration of 1% voriconazole eye drops into human aqueous and vitreous humor – a prospective, open-label study (MClinPharm thesis). Melbourne, Australia: Monash University; 2006.
103. Freeman PD, Kahook MY. Preservatives in topical ophthalmic medications: Historical and practical review of benzalkonium chloride. *Expert Rev Ophthalmol.* 2009;4(1):59–64.
104. van der Bijl P, van Eyk A, Meyer D. Effects of three penetration enhancers on transcorneal permeation of cyclosporine. *Cornea.* 2001;20(5):505–558.
105. Sengupta KK, Mikherji R. *Essentials Ocular Pharmacology and Therapeutics*. 1st ed. Kent, UK: Anshan Pub.; 2007.
106. Polizzi A, Siniscalchi C, Mastromarino A, Sacca S. Effect of voriconazole on a corneal abscess caused by *Fusarium*. *Acta Ophthalmol Scand.* 2004;82(6):762–764.
107. Prats CH, Tello FL, Jose ABS, Otaolauruchi JS, Baines JPO. Voriconazole in fungal keratitis caused by *Scedosporium apiospermum*. *Ann Pharmacother.* 2004;38(3):414–417.
108. Reis A, Sundmacher R, Tintelnot K, Agostini H, Jensen HE, Althaus C. Successful treatment of ocular invasive mould infection (*Fusariosis*) with the new antifungal agent voriconazole. *Br J Ophthalmol.* 2000;84(8):932–933.
109. Jones A, Muhtaseb M. Use of voriconazole in fungal keratitis. *J Cataract Refract Surg.* 2008;34(2):183–184.

110. Al-Badriyeh D, Leung L, Davies GE, Stewart K, Kong D. Successful salvage treatment of *Scedosporium apiospermum* keratitis with topical voriconazole after failure of vatamycin. *Ann Pharmacother.* 2009;43(6):1139–1142.
111. Al-Badriyeh D, Leung L, Davies GE, Stewart K, Kong D. Successful use of topical voriconazole 1% alone as first-line antifungal therapy against *Candida albicans* keratitis. *Ann Pharmacother.* 2009;43(12):2103–2107.
112. Al-Badriyeh D, Li J, Stewart K, et al. Stability of extemporaneously prepared voriconazole ophthalmic solution. *Am J Health Syst Pharm.* 2009;66(16):1478–1483.
113. Lau D, Leung L, Fedinands M, et al. Penetration of 1% voriconazole eye drops into human vitreous humour – a prospective, open-label study. *Clin Experiment Ophthalmol.* 2009;37(2):197–200.

### Clinical Ophthalmology

#### Publish your work in this journal

Clinical Ophthalmology is an international, peer-reviewed journal covering all subspecialties within ophthalmology. Key topics include: Optometry; Visual science; Pharmacology and drug therapy in eye diseases; Basic Sciences; Primary and Secondary eye care; Patient Safety and Quality of Care Improvements. This journal is indexed on

Submit your manuscript here: <http://www.dovepress.com/clinical-ophthalmology-journal>

Dovepress

PubMed Central and CAS, and is the official journal of The Society of Clinical Ophthalmology (SCO). The manuscript management system is completely online and includes a very quick and fair peer-review system, which is all easy to use. Visit <http://www.dovepress.com/testimonials.php> to read real quotes from published authors.