



Case Report

Reinforcement Ring–Augmented Hip Arthroplasty: A 35-Year Follow-up

Reinhold Ganz, MD ^a, Gary Ulrich, MD ^b, Srinath Kamineni, MD, FRCS-Orth ^{b,*}^a Department of Orthopedic Surgery, University of Bern, Bern, Switzerland^b Department of Orthopedic Surgery, Elbow Shoulder Research Center, University of Kentucky College of Medicine, Lexington, KY, USA

ARTICLE INFO

Article history:

Received 8 May 2023

Received in revised form

9 September 2023

Accepted 13 September 2023

Available online xxx

Keywords:

Reinforcement ring

Hip arthroplasty

Case report

ABSTRACT

During the late 1980s, techniques were evolving to prevent acetabular component loosening. Inadequate acetabular bone stock further complicated this concern, which was traditionally addressed with cementation and bone grafting during this time period. However, one evolving tactic to address acetabular component loosening in the setting of inadequate acetabular bone stock was to augment bone graft with an acetabular reinforcement ring. In 1963, a 26-year-old, active male sustained a right-sided femoral neck fracture following a skiing accident. He ultimately developed a collapsed femoral head and varus deformity of the femoral neck requiring a total hip arthroplasty with a cemented monoblock femoral component and a polyethylene acetabular component cemented into a reinforcement ring. The initial procedure was performed in 1988, and this prosthesis is still functioning 35 years later and represents one of the longest follow-ups of a patient with a primary total hip arthroplasty with a reinforcement ring.

© 2023 Published by Elsevier Inc. on behalf of The American Association of Hip and Knee Surgeons. This is an open access article under the CC BY-NC-ND license (<http://creativecommons.org/licenses/by-nc-nd/4.0/>).

Introduction

First described in 1958 by Wiles, total hip arthroplasty (THA) is currently considered to be one of the most successful orthopedic procedures to date. The modern procedure affords pain relief while also restoring hip mobility for prolonged periods of time in patients with painful hip dysfunction [1,2]. However, as is the case with most prosthetic arthroplasty procedures, these joint implants have a finite lifespan. The current literature suggests that only 58% of modern THAs last 25 years, and there are seldom reports of cases lasting beyond this timeframe [3].

Since the 1950s, numerous advances have been made regarding THAs, all with the common goal of prolonging the longevity of the prostheses while also minimizing complications such as osteolysis [4–8]. Patients with inadequate acetabular bone stock, such as elderly patients with fractures or with a history of avascular necrosis (AVN), are particularly prone to early hardware failure [9–13]. There were several early developments to counter the challenges presented by

insufficient acetabular bone stock, many of which focused on acetabulum reinforcement [14]. Four such acetabular support systems were the Kerboul plate, Burch-Schneider anti-protrusio cage, Müller acetabular cage, and the reinforcement ring (Fig. 1) [15].

The Kerboul plate was introduced in 1974 by Dr. Marcel Kerboul and was made of stainless steel [16]. Its hemispheric cross-design incorporated a distal hook that inserted onto the teardrop and superior border of the obturator foramen and had a proximal plate fixed to the iliac bone with up to 4 cortical screws. The Burch-Schneider anti-protrusio cage consists of a cup with a proximal and distal flange for stabilization to the ileum and ischium, respectively. This cage is designed to widely distribute the forces during loading over the pelvis, allowing for bridging of areas of insufficient bone stalk in the acetabulum. Although these cages have been shown to have favorable medium-term results, most of these studies have been predominantly focused on elderly patients with acetabular fractures [17–21]. The Müller ring runs superiorly from the ilium to the inferomedial acetabulum [22]. Such a design affords protection of the acetabular dome, and several studies have shown this to be an effective option for both revision and primary THAs [23–28]. However, most of the studies that report outcomes of the Müller ring are performed on patients with an underlying diagnosis of

* Corresponding author. Department of Orthopedic Surgery, 740 South Limestone Street, K-401 Kentucky Clinic, Lexington, KY 40536-0284, USA. Tel.: +1 859 806 7703.

E-mail address: srinathkamineni@gmail.com

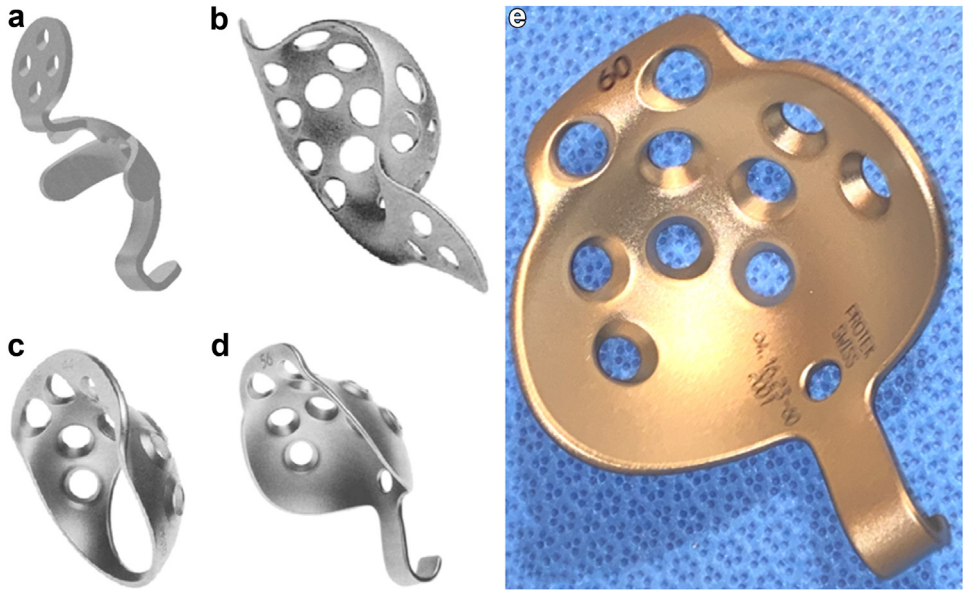


Figure 1. Kerboul device (a), Burch-Schneider cage (b), Mueller ring (c), Reinforcement Ring (d and e). Pictures (a-d) are credited to source with permission - Kawanabe, K., Akiyama, H., Goto, K., Maeno, S., & Nakamura, T. (2011).[15] Picture e is used with permission from The Orthopedic Museum.

osteoporosis, and the follow-up in these studies is relatively limited.

Inspired by the Kerboul plate's hook design, which allowed for precise placement of the device, the "Reinforcement Ring" was

subsequently designed. This Reinforcement Ring design allowed for reinforcement of the anterior and posterior walls, the acetabular dome, and the acetabular fossa. The inferior hook facilitated the accurate location of the anatomic center of rotation [29]. This ring is

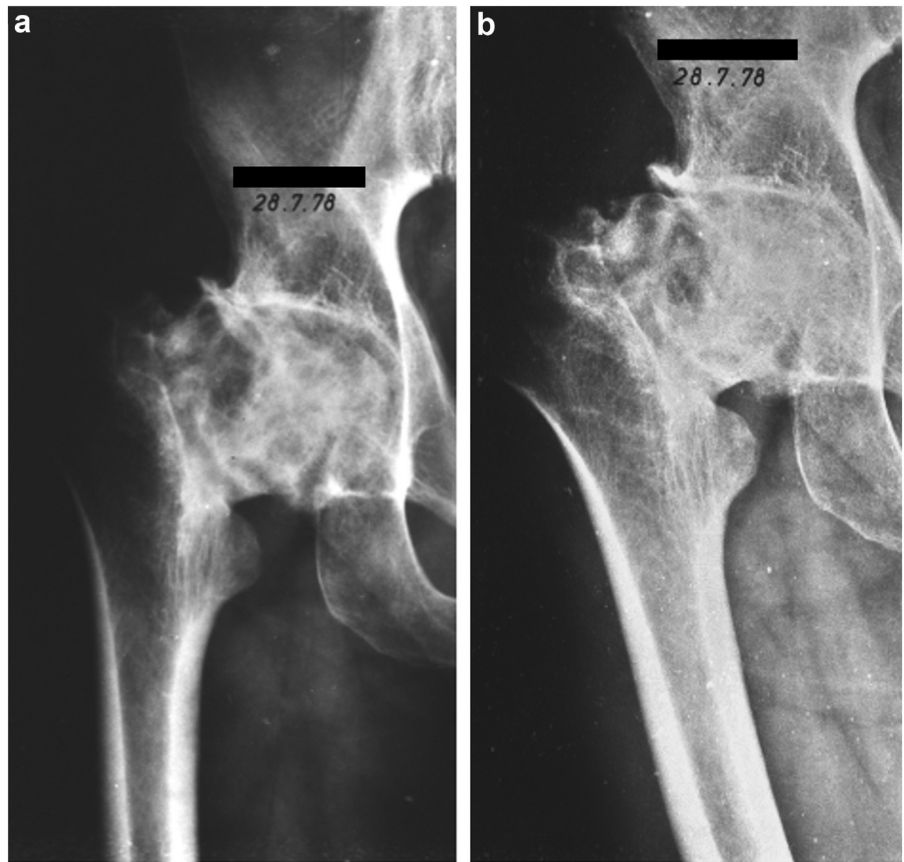


Figure 2. Anteroposterior (a) and lateral (b) radiographs demonstrating a collapsed femoral head with an altered contour and varus deformity.

smaller in size than the Burch-Schneider cage and Müller rings, a feature that allows for smaller incisions but requires intact inferior and posterior acetabular rims. While initially designed for use in revision cases, the reinforcement ring has been shown to lead to successful outcomes in primary THAs in patients with inadequate acetabular bone stock [30-32].

In this case report, we present the “time-capsule” case of a primary THA with a reinforcement ring performed in 1988 that is still functioning, without symptoms or further surgical intervention, 35 years later.

Case history

In 1963, a 26-year-old, active male sustained an injury to the right hip following a ski jumping accident. He was a butcher in his family-owned meat market, a relatively manual profession, as well as being a regional competition skier. Unable to bear weight after the accident, he was carried home and was visited at home by a local trauma doctor, who performed an x-ray on his portable x-ray machine. A slightly displaced femoral neck fracture was diagnosed. The initial conservative treatment with 6 weeks of soft-tissue traction was complicated by the development of skin blisters, prompting a conversion to calcaneal transfixation pin traction. As was routine during this time period, all treatment took place in the patient's own home without physical therapy during the healing and remobilization period.

Several months later, the patient noticed increasing right hip pain with weightbearing combined with a significant reduction in hip range of motion (ROM). Radiographs revealed femoral head collapse which was nonoperatively managed. He was instructed to live a more sedentary lifestyle and retrained as a driving instructor. Over the next several years, he gradually returned to his active lifestyle, including skiing. In 1978, the patient again noted increasing pain that was significantly restricting his physical activity. At this time, his physical examination revealed atrophy of the proximal thigh muscles, decreased hip ROM, and an antalgic gait. Plain radiographs demonstrated an irregularly shaped contour of a collapsed femoral head and a varus femoral neck deformity (Fig. 2).

A 30-degree valgus femoral osteotomy was performed to widen the lateral joint space without worsening the subluxation (Fig. 3). This procedure provided significant pain relief and allowed the patient to again return to his active lifestyle for the next 10 years.

In 1988, with worsening hip pain and dysfunction, a conversion surgery was performed to a Mueller THA (Sulzer Medica, Winterthur, Switzerland). A cemented monoblock Mueller femoral component with a 22-mm head and a polyethylene acetabular component was cemented into a Reinforcement Ring (Sulzer Medica/Protek AG, Switzerland). Based on the preoperative plain films, the original operative plan did not involve a Reinforcement Ring. However, following curettage and preparation of the acetabular cavity, several intraosseous and confluent ganglion cysts were present, leaving only a few bony trabeculae to support the planned acetabular component. With these intraoperative findings of inadequate acetabular bone stock and the subsequent concern for acetabular component loosening, the decision was made to utilize bone graft and the Reinforcement Ring. Autologous cancellous bone graft from the resected femoral head was impacted into the acetabular cavities, and the Reinforcement Ring was then fixed to the bone with 4 screws into the surrounding cortical bone and provided optimal and rigid support for the cemented acetabular component. This procedure provided immediate improvement in hip ROM and postural control, allowing the patient to resume the more physically demanding activities that he enjoyed for the next several decades (Figs. 4-6).

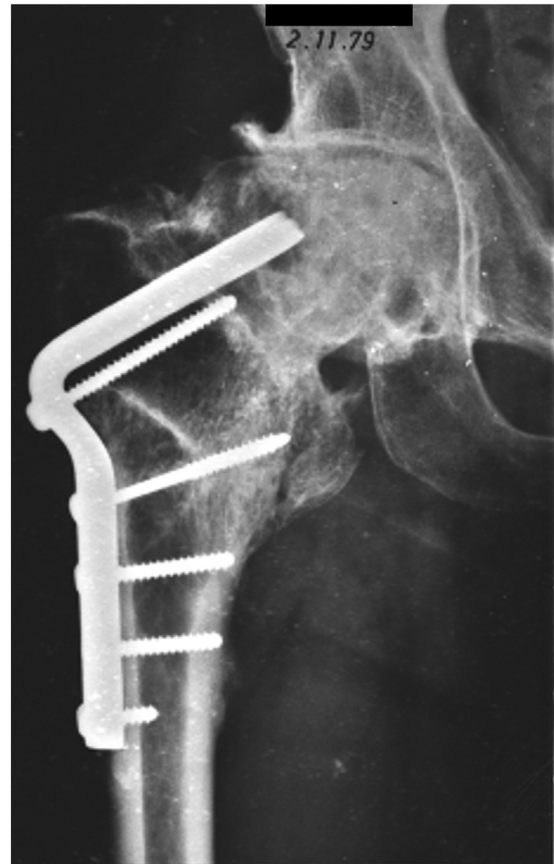

Figure 3. Valgus femoral osteotomy with a fixed angle blade plate. One-year after operation with the persistence of a lateral joint space.

His latest radiographic follow-up (Fig. 7) in 2019 revealed a stable total hip replacement with no visible loosening of either the femoral or the acetabular component. The Reinforcement Ring remained well-fixed and in its original position. Furthermore, there was remarkably minimal polyethylene wear despite this patient's active lifestyle. As of his 35-year clinical follow-up, the patient reported sustained symptom-free hip function as evidenced by his ability to continue such activities as hiking and skiing at the age of 86 years. Moreover, the patient provided written informed consent for the publication of data concerning his case.

Discussion

During the late 1980s time period of our patient case, one of the major concerns of THA was aseptic loosening, particularly of the cemented polymethylmethacrylate acetabular cup [33]. Sir John Charnley, among others, had found that the rate of acetabular cup loosening was infrequent during the first 8 years postoperatively but then exponentially increased after 10 years postoperatively, presenting a concern for the longevity of THA implants [34-36]. Charnley found rates of aseptic loosening to be 11% at 12-15 years postoperatively, and Gudmundsson et al. further reported a 10% rate at 10-14 years postoperatively [34,37]. Moreover, Mulroy and Harris found a 20-fold increase in the rate of acetabular component loosening between 5 years and 11 years postoperatively [38].

To combat aseptic loosening, different THA strategies were evolving and being experimented during this time period to achieve the best patient outcome and implant longevity. Some of these strategies included metal-backed cemented polyethylene

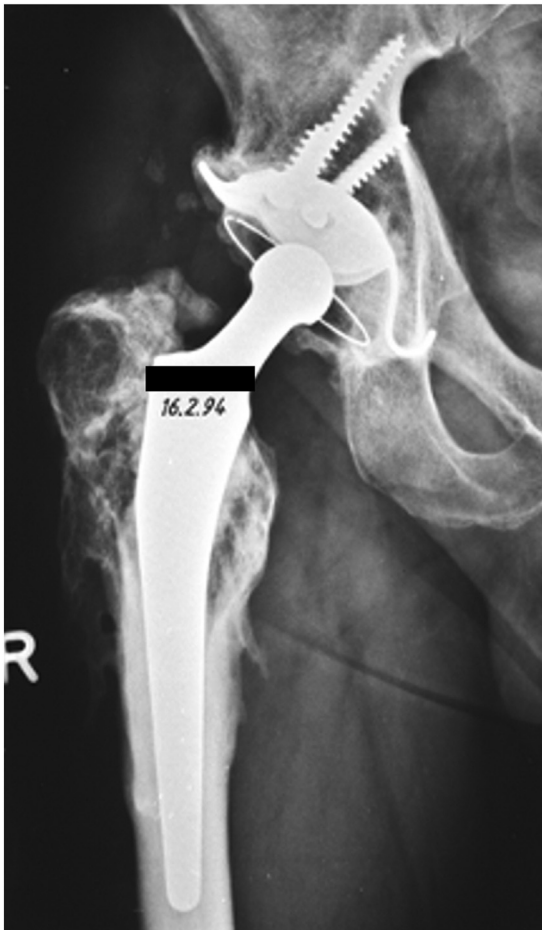

Figure 4. Five-year postoperative anteroposterior radiograph, demonstrating a solidly fixed total hip arthroplasty with no loosening.

acetabular cups, screw fixation with polyethylene acetabular cups, press-fit fixation, surface coating of acetabular cups, cup placement, and preservation of the acetabular subchondral bone [33]. Ritter et al. demonstrated that metal-backed cemented polyethylene acetabular cups lead to significantly increased loosening and failure rates compared with all-polyethylene cups [39]. The use of

acetabular screws in polyethylene cups led to higher rates of loosening with screws (9.5%) than with no screws (5%), and further studies highlighted the neurovascular and impingement risks of acetabular screws [40–42]. On the other hand, the development of the press-fit cup and its fixation by the “snap fastener mechanism” demonstrated success. Early studies found that porous-coated cups greatly outperformed threaded cups with respect to component loosening, migration, and revision rates, which led to the abandonment of the threaded cup design [43–45]. The use of hydroxyapatite as a surface coating material also emerged and demonstrated enhanced ingrowth and ongrowth results, but there was still skepticism during this time [33,46]. Finally, Yoder et al. reported that recreating the anatomical center of hip rotation with the THA implant led to decreased loosening rates as opposed to hips with a center of rotation that was superolateral [47]. There was also a notion to use a low-profile hemispherical acetabular component and preserve as much supportive subchondral bone of the acetabulum as possible to mitigate component migration [33].

While acetabular cup fixation with minimal risk of loosening was a challenge in sufficient acetabular bone, it was even more of a challenge in patients with inadequate acetabular bone. The Reinforcement Ring, along with other forms of acetabular reinforcement, represented a strategy during this time period to specifically address acetabular deficiency. Although initially designed to be used for revision cases, the reinforcement ring was highly effective for primary THA with acetabular deficiencies. Sadri et al. reported the results of 185 primary THAs using the Reinforcement Ring with a median follow-up of 122 months and found that there were only 8 (4.3%) revisions required (6 for aseptic loosening and 2 for sepsis) [30]. In a more recent study by Attinger et al. with a mean follow-up of 23.1 years, only 17.2% of hips that underwent a primary THA with the Reinforcement Ring between 1987 and 1991 ultimately required a revision [31]. These favorable outcomes can be extended to patients who are considered particularly challenging candidates for THAs, such as those with underlying AVN of the femoral head, with acetabular deficiency, as was the case with the patient in the present study. Indeed, Koch et al. demonstrated this fact in their study of 23 patients with an underlying diagnosis of AVN of the femoral head who underwent a THA with the Reinforcement Ring [32]. In this study, the authors found the cumulative 12-years survivorship to be 95.2% [32].

In the case of our patient, who had a history of femoral head AVN and was found to have inadequate acetabular bone stock intraoperatively, a decision was made to utilize the Reinforcement

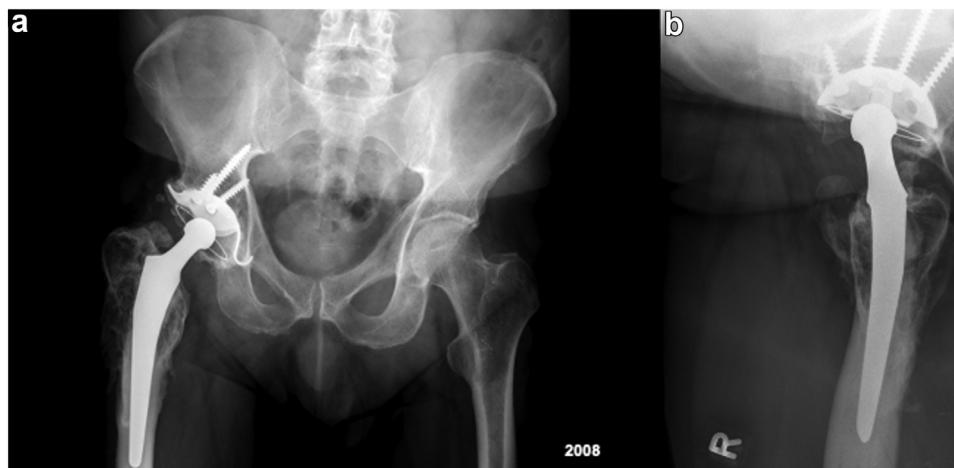


Figure 5. Anteroposterior (a) and lateral (b) radiographs demonstrating well-fixed components. Some heterotopic bone evident on both the anteroposterior and lateral views.

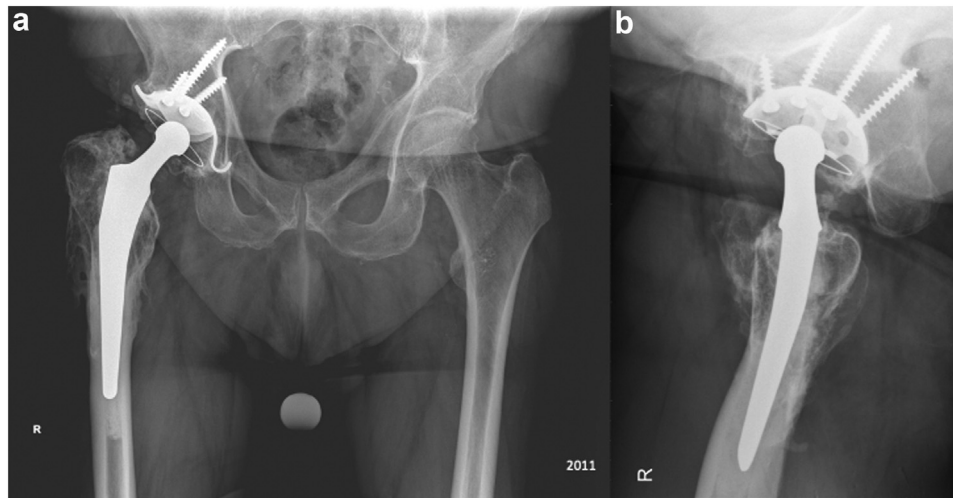


Figure 6. Anteroposterior (a) and lateral (b) radiographs demonstrating well-fixed components. A mature heterotopic bone evident on the AP and lateral view. No loosening visible of either component.

Ring given the advantages mentioned earlier. In this particular case, the use of Reinforcement Ring was successful and enabled our patient to return to high-level physical activities, including skiing and hiking for 35 years. Despite several decades of physically demanding activities, no further surgical intervention has been required for his hip since the initial THA in 1988, and there has been remarkably minimal wear. Our case represents one of the longest follow-ups of a patient with a primary THA that included a Reinforcement Ring. Moreover, the survival of this THA is all the more remarkable when considering the activity level of our patient, the time period of this implantation, and the absence of such modern-day instrumentation including modern uncemented femoral and acetabular components, advanced imaging, fourth-generation cementing techniques, cross-linked polyethylene, and porous metals.

Summary

Implant longevity remains a concern in THA despite continued advancements in the field. We present a case of a THA with a cemented monoblock femoral component and a polyethylene

acetabular component cemented into a reinforcement ring with a 35-years follow-up. Our case represents one of the longest follow-ups of a patient with a primary THA with a reinforcement ring.

Conflicts of interest

The authors declare there are no conflicts of interest.

For full disclosure statements refer to <https://doi.org/10.1016/j.artd.2023.101248>.

Informed patient consent

The author(s) confirm that written informed consent has been obtained from the involved patient(s) or if appropriate from the parent, guardian, power of attorney of the involved patient(s); and, they have given approval for this information to be published in this case report (series).

References

- [1] Wiles P. The surgery of the osteoarthritic hip. *Br J Surg* 1958;45:488–97. <https://doi.org/10.1002/bjs.18004519315>.
- [2] Learmonth ID, Young C, Rorabeck C. The operation of the century: total hip replacement. *Lancet* 2007;370:1508–19. [https://doi.org/10.1016/S0140-6736\(07\)60457-7](https://doi.org/10.1016/S0140-6736(07)60457-7).
- [3] Evans JT, Evans JP, Walker RW, Blom AW, Whitehouse MR, Sayers A. How long does a hip replacement last? A systematic review and meta-analysis of case series and national registry reports with more than 15 years of follow-up. *Lancet* 2019;393:647–54. [https://doi.org/10.1016/S0140-6736\(18\)31665-9](https://doi.org/10.1016/S0140-6736(18)31665-9).
- [4] Harris WH, Schiller AL, Scholler JM, Freiberg RA, Scott R. Extensive localized bone resorption in the femur following total hip replacement. *J Bone Joint Surg Am* 1976;58:612–8.
- [5] Maloney WJ, Jasty M, Rosenberg A, Harris WH. Bone lysis in well-fixed cemented femoral components. *J Bone Joint Surg Br* 1990;72:966–70. <https://doi.org/10.1302/0301-620X.72B6.2246299>.
- [6] Schmalzried TP, Guttman D, Grecula M, Amstutz HC. The relationship between the design, position, and articular wear of acetabular components inserted without cement and the development of pelvic osteolysis. *J Bone Joint Surg Am* 1994;76:677–88. <https://doi.org/10.2106/00004623-199405000-00008>.
- [7] Yoon TR, Rowe SM, Jung ST, Seon KJ, Maloney WJ. Osteolysis in association with a total hip arthroplasty with ceramic bearing surfaces. *J Bone Joint Surg Am* 1998;80:1459–68. <https://doi.org/10.2106/00004623-199810000-00007>.
- [8] Kurcz B, Lyons J, Sayeed Z, Anoushiravani AA, Iorio R. Osteolysis as it Pertains to total hip arthroplasty. *Orthop Clin North Am* 2018;49:419–35. <https://doi.org/10.1016/j.joc.2018.06.001>.
- [9] Ritter MA, Meding JB. A comparison of osteonecrosis and osteoarthritis patients following total hip arthroplasty. A long-term follow-up study. *Clin Orthop Relat Res* 1986;139–46.

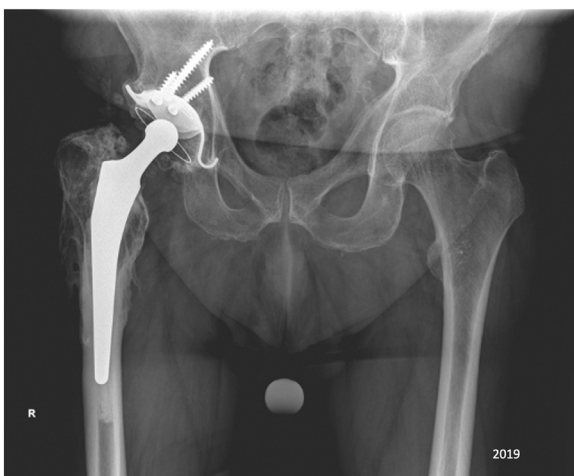

Figure 7. Anteroposterior radiograph in 2019 (latest radiographic follow-up) demonstrating well-fixed components. No loosening visible of either component.

- [10] Saito S, Saito M, Nishina T, Ohzono K, Ono K. Long-term results of total hip arthroplasty for osteonecrosis of the femoral head. A comparison with osteoarthritis. *Clin Orthop Relat Res* 1989;198–207.
- [11] Mnamneh WA. Bone stock deficiency in total hip replacement. *Classification and Management. J Bone Joint Surg* 1990;72:317.
- [12] D'Antonio JA, Capello WN, Manley MT, Feinberg J. Hydroxyapatite coated implants. Total hip arthroplasty in the young patient and patients with avascular necrosis. *Clin Orthop Relat Res* 1997;124–38.
- [13] Fyda TM, Callaghan JJ, Olejniczak J, Johnston RC. Minimum ten-year follow-up of cemented total hip replacement in patients with osteonecrosis of the femoral head. *Iowa Orthop J* 2002;22:8–19.
- [14] Gibon E, Kerboull L, Coupied JP, Hamadouche M. Acetabular reinforcement rings associated with allograft for severe acetabular defects. *Int Orthop* 2019;43:561–71. <https://doi.org/10.1007/s00264-018-4142-1>.
- [15] Kawanabe K, Akiyama H, Goto K, Maeno S, Nakamura T. Load dispersion effects of acetabular reinforcement devices used in revision total hip arthroplasty: a simulation study using finite element analysis. *J Arthroplasty* 2011;26:1061–6. <https://doi.org/10.1016/j.arth.2011.04.019>.
- [16] Kerboull M, Hamadouche M, Kerboull L. The Kerboull acetabular reinforcement device in major acetabular reconstructions. *Clin Orthop Relat Res* 2000;155–68. <https://doi.org/10.1097/00003086-200009000-00025>.
- [17] Gill TJ, Sledge JB, Müller ME. The Burch-Schneider anti-protrusion cage in revision total hip arthroplasty: indications, principles and long-term results. *J Bone Joint Surg Br* 1998;80:946–53. <https://doi.org/10.1302/0301-620x.80b6.8658>.
- [18] Tidermark J, Blomfeldt R, Ponzer S, Söderqvist A, Törnkvist H. Primary total hip arthroplasty with a Burch-Schneider antiprotrusion cage and autologous bone grafting for acetabular fractures in elderly patients. *J Orthop Trauma* 2003;17:193–7. <https://doi.org/10.1097/00005131-200303000-00007>.
- [19] Pieringer H, Auersperg V, Böhrer N. Reconstruction of severe acetabular bone-deficiency: the Burch-Schneider antiprotrusion cage in primary and revision total hip arthroplasty. *J Arthroplasty* 2006;21:489–96. <https://doi.org/10.1016/j.arth.2005.02.016>.
- [20] Enocson A, Blomfeldt R. Acetabular fractures in the elderly treated with a primary Burch-Schneider reinforcement ring, autologous bone graft, and a total hip arthroplasty: a prospective study with a 4-year follow-up. *J Orthop Trauma* 2014;28:330–7. <https://doi.org/10.1097/BOT.0000000000000016>.
- [21] Liaw F, Govilkar S, Banks D, Kankanalu P, Youssef B, Lim J. Primary total hip replacement using Burch-Schneider cages for acetabular fractures. *Hip Int* 2022;32:401–6. <https://doi.org/10.1177/1120700020957642>.
- [22] Rajkumar N, Soundararajan D, Kumar PC, Dhanasekararaja P, Rajasekaran S. Clinical and radiological outcome of acetabular reconstruction rings in complex primary and revision total hip arthroplasty. *Indian J Orthop* 2021;55:1267–76.
- [23] Haentjens P, Handelberg F, Casteleyn PP, Opdecam P. The müller acetabular support ring. A preliminary review of indications and clinical results. *Int Orthop* 1986;10:223–30. <https://doi.org/10.1007/BF00454401>.
- [24] Stöckl B, Beerkotte J, Krismser M, Fischer M, Bauer R. Results of the Müller acetabular reinforcement ring in revision arthroplasty. *Arch Orthop Trauma Surg* 1997;116:55–9.
- [25] Stöckl B, Beerkotte J, Krismser M, Fischer M, Bauer R. Results of the Müller acetabular reinforcement ring in revision arthroplasty. *Arch Orthop Trauma Surg* 1997;116:55–9. <https://doi.org/10.1007/BF00434102>.
- [26] Panski A, Tauber C. Acetabular supporting ring in total hip replacement. *Arch Orthop Trauma Surg* 1997;116:233–5. <https://doi.org/10.1007/BF00393718>.
- [27] Schlegel UJ, Bitsch RG, Pritsch M, Clauss M, Mau H, Breusch SJ. Mueller reinforcement rings in acetabular revision: outcome in 164 hips followed for 2–17 years. *Acta Orthop* 2006;77:234–41. <https://doi.org/10.1080/17453670610045966>.
- [28] Sirka A, Clauss M, Tarasevicius S, Wingstrand H, Stucinskas J, Robertsson O, et al. Excellent long-term results of the Müller acetabular reinforcement ring in primary total hip arthroplasty: a prospective study on radiology and survival of 321 hips with a mean follow-up of 11 years. *Acta Orthop* 2016;87:100–5. <https://doi.org/10.3109/17453674.2015.1103607>.
- [29] Beckmann NA, Hasler JF, Moradi B, Schlegel UJ, Gotterbarm T, Streit MR. Long-term results of acetabular reconstruction using Ganz acetabular rings. *J Arthroplasty* 2018;33:3524–30. <https://doi.org/10.1016/j.arth.2018.06.036>.
- [30] Sadri H, Pfander G, Siebenrock KA, Tannast M, Koch P, Fujita H, et al. Acetabular reinforcement ring in primary total hip arthroplasty: a minimum 10-year follow-up. *Arch Orthop Trauma Surg* 2008;128:869–77. <https://doi.org/10.1007/s00402-008-0612-z>.
- [31] Attinger MC, Haefeli PC, Bäcker HC, Flueckiger R, Ballmer PM, Siebenrock KA, et al. The Ganz acetabular reinforcement ring shows excellent long-term results when used as a primary implant: a retrospective analysis of two hundred and forty primary total hip arthroplasties with a minimum follow-up of twenty years. *Int Orthop* 2019;43:2697–705. <https://doi.org/10.1007/s00264-018-04284-9>.
- [32] Koch PP, Tannast M, Fujita H, Siebenrock K, Ganz R. Minimum ten year results of total hip arthroplasty with the acetabular reinforcement ring in avascular osteonecrosis. *Int Orthop* 2008;32:173–9. <https://doi.org/10.1007/s00264-006-0303-8>.
- [33] Morscher EW. Current status of acetabular fixation in primary total hip arthroplasty. *Clin Orthop Relat Res* 1992;274:172–93. <https://doi.org/10.1097/00003086-199201000-00018>.
- [34] Charnley J. *Low friction arthroplasty of the hip. Theory and Practice*. Berlin, Germany: Springer; 1979. <https://doi.org/10.1007/978-3-642-67013-8>.
- [35] Morscher E, Schmassmann A. Failures of total hip arthroplasty and probable incidence of revision surgery in the future: calculations according to a mathematical model based on a ten years' experience in total hip arthroplasty. *Arch Orthop Trauma Surg* 1983;101:137–43. <https://doi.org/10.1007/bf00433274>.
- [36] Sutherland CJ, Wilde AH, Borden LS, Marks KE. A ten-year follow-up of one hundred consecutive Müller curved-stem total hip-replacement arthroplasties. *J Bone Joint Surg Am* 1982;64:970–82. <https://doi.org/10.2106/00004623-198264070-00002>.
- [37] Gudmundsson GH, Hedeboe JE, Kjaer JA. Mechanical loosening after hip replacement. Incidence after 10 years in 125 patients. *Acta Orthop Scand* 1985;56:314–7. <https://doi.org/10.3109/17453678508993023>.
- [38] Mulroy RD, Harris WH. The effect of improved cementing techniques on component loosening in total hip replacement. An 11-year radiographic review. *J Bone Joint Surg Br* 1990;72:757–60. <https://doi.org/10.1302/0301-620x.72b5.2211749>.
- [39] Ritter MA, Keating EM, Faris PM, Brugo G. Metal-backed acetabular cups in total hip arthroplasty. *J Bone Joint Surg Am* 1990;72:672–7. <https://doi.org/10.2106/00004623-199072050-00005>.
- [40] Severt R, Wood R, Cracchiolo III AN. Long-term follow-up of cemented total hip arthroplasty in rheumatoid arthritis. *Clin Orthop Relat Res* 1991;265:137–45. <https://doi.org/10.1097/00003086-199104000-00016>.
- [41] Wasielewski RC, Cooperstein LA, Kruger MP, Rubash HE. Acetabular anatomy and the transacetabular fixation of screws in total hip arthroplasty. *J Bone Joint Surg Am* 1990;72:501–8. <https://doi.org/10.2106/00004623-199072040-00005>.
- [42] Keating EM, Ritter MA, Faris PM, Czarkowski RA, Brugo G. Early clinical results of the TTAP acetabular cup. *Orthopedics* 1989;12:1213–6. <https://doi.org/10.3928/0147-7447-19890901-10>.
- [43] Blum HJ, Noble PC, Tullos HS. Migration and rotation of cementless acetabular cups: incidence, etiology and clinical significance. *Orthop Trans* 1990;14:580.
- [44] Engh CA, Griffin WL, Marx CL. Cementless acetabular components. *J Bone Joint Surg Br* 1990;72:53–9. <https://doi.org/10.1302/0301-620x.72b1.2298795>.
- [45] Tooke SM, Nugent PJ, Chotivichit A, Goodman W, Kabo JM. Comparison of in vivo cementless acetabular fixation. *Clin Orthop Relat Res* 1988;235:253–60. <https://doi.org/10.1097/00003086-198810000-00024>.
- [46] Morscher EW, Dick W, Kernen V. Cementless fixation of polyethylene acetabular component in total hip arthroplasty. *Arch Orthop Trauma Surg* 1982;99:223–30. <https://doi.org/10.1007/bf00381397>.
- [47] Yoder SA, Brand RA, Pedersen DR, O'Gorman TW. Total hip acetabular component position affects component loosening rates. *Clin Orthop Relat Res* 1988;79–87.