



Special Topic

Injection Guidelines for Treating Midface Volume Deficiency With Hyaluronic Acid Fillers: The ATP Approach (Anatomy, Techniques, Products)

Patrick Trévidic, MD; Joely Kaufman-Janette, MD; Susan Weinkle, MD; Raymond Wu, MD; Benji Dhillon, MD; Stéphanie Antunes, PhD; Emilie Macé, PharmD; and Pauline Maffert, MSc

Aesthetic Surgery Journal
2022, Vol 42(8) 920–934

© 2022 The Aesthetic Society.

This is an Open Access article distributed under the terms of the Creative Commons Attribution-NonCommercial-NoDerivs licence

(<https://creativecommons.org/licenses/by-nc-nd/4.0/>), which

permits non-commercial reproduction and distribution of the work, in any medium, provided the original work is not altered or transformed in any way, and that the work is properly cited.

For commercial re-use, please contact

journals.permissions@oup.com

<https://doi.org/10.1093/asj/sjac007>

www.aestheticsurgeryjournal.com

OXFORD
UNIVERSITY PRESS

Abstract

Midface rejuvenation is among the most valuable indications of hyaluronic acid dermal fillers, because malar projection and full upper cheeks significantly contribute to a youthful appearance. Hyaluronic acid fillers have evolved over the past 2 decades to meet specific clinical needs such as strong projection capacity and adaptability to facial dynamism. As a result, they now represent the treatment of choice for midface rejuvenation throughout age ranges by offering the potential for noninvasive treatment, immediate results, and minimal downtime. Because the 5-layered structure of the midface plays a central role in the human face, injecting the midface area may also indirectly improve other aesthetic concerns such as infraorbital hollowing and nasolabial folds. Nonetheless, midface rejuvenation requires a tailored treatment approach and a thorough knowledge of anatomy to minimize procedural risks and achieve natural-looking results. This article provides an extensive anatomical description of the midface and of the usual course and depth of vascular structures circulating nearby to delineate a treatment area and minimize procedural risks. Furthermore, considering the differential mobility and mechanical constraints of each layer of the midface, a multilayer treatment algorithm is proposed for adapting the treatment strategy to patient specificities (including age, gender, skin type, and morphology). Emphasis is also placed on desirable filler properties to create deep structural support on the one hand and accompany facial movement on the other hand.

Editorial Decision date: January 11, 2022; online publish-ahead-of-print January 17, 2022.

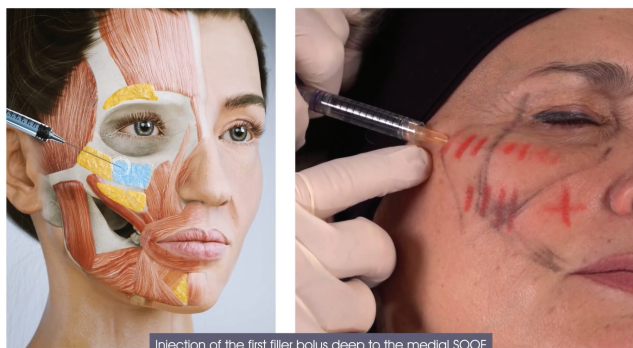Desirable aesthetic features in the midface usually involve malar projection and full cheeks as well as a smooth convexity from the lower eyelid down to the nasolabial fold, forming an ogee curve.¹ Because aging results in volume changes throughout all tissues layers, this youthful midface shape tends to fade over time.¹ A concavity may develop at the junction between the thin lower eyelid and the thicker cheek skin below. The upper cheek also flattens, and a prominent nasojugal groove may appear. Orbital and maxillary bone resorption and atrophy or selective hypertrophy of the deep and superficial fat pads, potentially combined

Dr Trévidic is a plastic surgeon in private practice in Paris, France. Dr Kaufman-Janette is a dermatologist in private practice in Miami, FL, USA. Dr Weinkle is a dermatologist, Bay Area Medical Complex, Bradenton, FL, USA. Dr Wu is a cosmetic surgeon in private practice in Hong Kong. Dr Dhillon is a cosmetic surgeon in private practice in Beaconsfield, UK. Dr Antunes is a clinical research specialist, Dr Macé is a medical information specialist, and Ms Maffert is a medical writer, Clinical and Medical Affairs Department, Teoxane SA, Geneva, Switzerland.

Corresponding Author:

Dr Patrick Trévidic, 7 rue de Sontay, 75116 Paris, France.

E-mail: patrick.trevindic@orange.fr



Injection of the first filler bolus deep to the medial SOOF

Video. Watch now at <http://academic.oup.com/asj/article-lookup/doi/10.1093/asj/sjac007>

with changes in muscular or ligamentous structures, can result in a sunken face with prominent folds.²

Dermal filler injections in the midface are now routinely performed in aesthetic clinics worldwide, representing an effective and minimally invasive alternative to surgery for malar augmentation or midface contouring.³⁻⁵ Specifically, hyaluronic acid (HA) gels have gained popularity over the past 20 years because they provide durable aesthetic improvement while staying biocompatible and reversible.^{6,7}

Although manufactured from the same starting material, there is an ever-increasing number of HA filler formulations available on the market, each exhibiting very specific physicochemical properties and mechanical behaviors.^{8,9} To categorize these gels, numerous rheological concepts have been employed, the most well-known being the elastic or storage modulus (G') representing a gel's hardness or ability to resist deformation.¹⁰ The G' , its counterpart the viscous modulus (G''), and other characteristics such as gels' cohesivity, swelling propensity, etc, directly result from manufacturing parameters, including HA molecular weight, crosslinking process, degree of chemical modification, and final HA concentration.^{8,10} Furthermore, some manufacturers have categorized their fillers as either "monophasic" or "biphasic" depending on the homogeneity of the final mixture and the presence of particles in the gel. These 2 categories have been purported to result in differences in tissue integration or longevity, although evidence remains limited.¹¹⁻¹⁴ More recently, Faivre et al. introduced new rheological concepts deemed more adapted to describe a gel's behavior in vivo, namely the "strength" and "stretch" scores.¹⁵ The former represents an integration of the G' curve over the range of stresses or deformations under which a gel retains its structural integrity, probing the gel's resilience, and the latter defines its ability to deform and adapt under mechanical constraints. These 2 parameters may deepen the understanding of a gel's behavior and evaluate its suitability to various clinical applications, particularly depending on the degree of mobility and need for structural support in the treatment area.

Thus, HA fillers now encompass a broad variety of facial treatments, going further than their original "dermal wrinkle filling" role to being employed in sculpting and volumizing indications. This paradigm shift has been accompanied by the development of new formulations combining strong projection capacity and adaptability to facial dynamism.^{3,16}

To guide aesthetic treatments in the midface and pursue natural-looking results, several clinicians proposed to rely on well-known anatomical landmarks of the face such as the Hinderer's lines to divide the area into treatment subunits or the Frankfort's horizontal plane to locate the malar eminence.^{4,17-19} While building on these global concepts derived from surgery, dermal filler injections are now transitioning to individualized treatment approaches adapted to specific patient needs.²⁰

In this publication, we propose a multilayer treatment algorithm aiming to adapt to individual patient needs and optimize outcomes, considering the 5-layered arrangement of the midface and age-related changes affecting all hard and soft tissues. Our algorithm takes advantage of specific filler properties designed for injecting deep static or superficial mobile fat compartments. Furthermore, based on an extensive review of the main anatomical characteristics and dangers of the midface, we delineate a treatment area aiming to minimize procedural risks, including vascular complications. We then provide technical guidelines for applying our algorithm in clinical practice with either a needle or a cannula, injecting deep fat compartments with a bolus or a fanning technique, and filling the subcutaneous fat employing a fan-like approach.

Anatomical descriptions and treatment guidance provided in this review combine evidence gathered from an exhaustive analysis of the medical literature, and expert opinions based on the authors' own anatomical observations and clinical experience with the multilayering technique.

ANATOMY

To optimize procedural safety and achieve natural-looking results, injectors attempting to correct midface volume deficiency should master the 3-dimensional anatomy of this area. A key anatomical concept is the 5-layered arrangement of this region, spanning from bone to skin and featuring deep static fat compartments separated from superficial mobile fat pads by a thin muscular layer (Figure 1A).^{21,22} Understanding how aging affects each of these layers is also essential to restore a youthful appearance without resulting in an exaggeratedly full face.¹ Finally, awareness of anatomical dangers represented by neighboring vascular structures must guide the physician's choices regarding injection technique, depth, as well as pre- and posttreatment precautions.

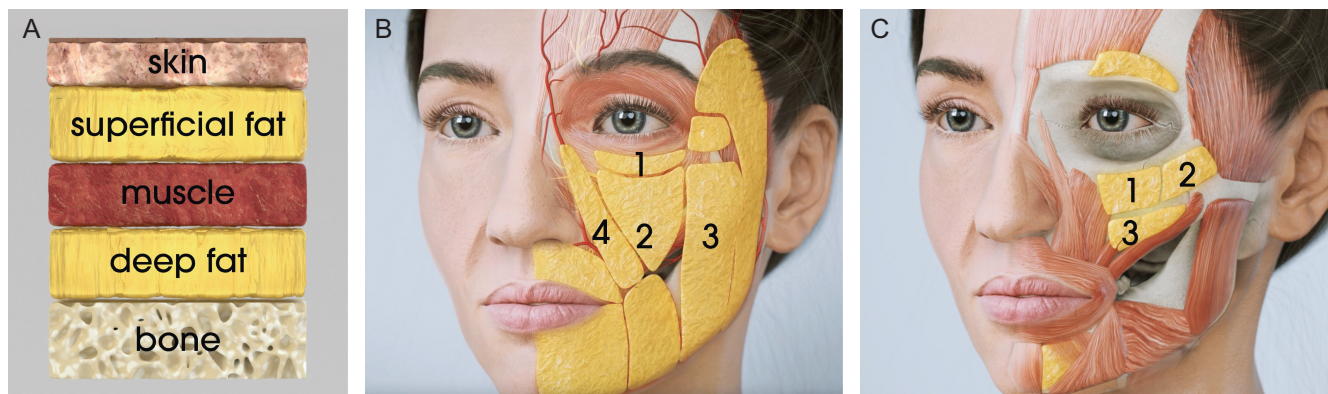


Figure 1. (A) The multilayer anatomy of the cheek spanning from bone to skin. (B) The mobile superficial fat compartments: 1, infraorbital fat compartment; 2, medial cheek fat compartment; 3, middle cheek fat compartment; 4, nasolabial fat compartment. (C) The static deep fat compartments: 1, medial sub-orbicularis oculi fat; 2, lateral sub-orbicularis oculi fat; 3, deep medial cheek fat (medial and lateral deep medial cheek fat).

This section aims to provide an overall picture of the midface anatomy, focusing on structural and functional aspects deemed relevant for augmentation with fillers. Of note, extensive anatomical studies published in the literature have uncovered complex and variable arrangements and may have utilized different nomenclatures to describe these structures. Our simplified view may thus differ from other midface representations due to the variability of other denominations and anatomical descriptions, exacerbated by inter-individual variability.

Multilayer Anatomy of the Midface and Changes Due to Aging

Superficial Fat Compartments

Immediately deep to the dermis, superficial fat compartments of the midface constitute a dynamic soft tissue layer moving along with the underlying muscles (Figure 1B). Through connective tissue fibers rising upwards to the dermis, superficial fat pads provide a strong attachment of the skin to the muscles.²³⁻²⁶ There are essentially 4 superficial fat pads that contribute to midface aging through changes in volume distribution: the infraorbital fat compartment (IOF), the medial cheek fat compartment (MCF), the middle cheek fat compartment (MiCF), and the nasolabial fat compartment (NLF).

The IOF is bound superiorly by the superficial extension of the orbicularis retaining ligament (ORL) and the inferior eyelid and connects with the MCF inferiorly. Atrophy of the IOF during aging causes the bony appearance of the lateral side of the orbital rim and may worsen tear trough deformity.^{27,28}

The MCF occupies the middle portion of the cheek where it overlies the lateral part of the deep medial cheek fat (DMCF). Over time, MCF atrophy may accentuate the depth of the mid-cheek concavity and the appearance of

the mid-cheek groove, contrasting with the increased fullness of the nasolabial fat.²⁹

The MiCF bounds medially with the MCF, laterally with the temporal cheek fat, and superiorly with the superficial extension of the zygomatic cutaneous ligament (ZCL). Aging of the MiCF primarily results in volume loss, which accentuates the depression of the MCF.

Finally, the NLF is the most medial superficial fat compartment of the midface. This rectangular fat pad bounds medially with the nasal sidewall, the levator labii superioris alaeque nasi muscle, and the nasolabial septum, and laterally with the medial cheek septum, the IOF, and the MCF. Compared with its neighboring fat compartments, the NLF increases in width and collapses inferiorly over time, resulting in pronounced nasolabial folds and nasojugal grooves in older patients.^{28,30}

Facial Muscles and Superficial Musculoaponeurotic System

The superficial musculoaponeurotic system (SMAS) is essential in creating facial expression through transmission of the muscles' contraction to the skin. Because superficial fat pads are intricately connected to the underlying muscle layer, the dynamism of this area should be well-understood when filling the superficial fat to avoid any unwanted lumpy appearance on muscle activation, for example, when smiling.

Located just beneath the superficial fat compartments, this soft tissue layer includes both facial muscles and ligament-like tissue. Three laminae form the aponeurosis: (1) the thin fascia on the outer surface of muscles, (2) the mimetic muscles, and (3) the thicker fascia on the underside of muscles. Fasciae 1 and 3 fuse in the absence of muscles.^{29,31}

In the midface region, the orbicularis oculi muscle (OOM), the levator labii superioris, the levator labii

superior alaeque nasi, the zygomaticus minor and major, the depressor anguli oris, the platysma, and the risorius constitute the superficial layer of facial muscles. The levator anguli oris muscle and the buccinator constitute the deeper layer.³²

Deep Fat Compartments

In the midface, 3 deep fat compartments adhere to the bone and provide structural support to the overlying soft tissue layers (SMAS and superficial fat). Atrophy of these compartments thus leads to deflation of the upper cheeks during aging (Figure 1C).³³

Recent anatomical studies found the deep sub-orbicularis oculi fat to be systematically divided into 2 separate compartments: medial and lateral.^{29,34} The medial sub-orbicularis oculi fat (mSOOF) is a triangular fat compartment extending from the lateral canthal line onto the maxillary bone. It is separated from the lateral SOOF by a vertical septum, and from the inferior eyelid's pre-septal space by the ORL. Inferiorly, the mSOOF also connects with the medial ZCL. Finally, the deep fascia of the OOM cover the mSOOF and create a "hermetic" cover fusing with surrounding ligaments.²⁹ The lateral sub-orbicularis oculi fat (ISOOF) lies laterally to the vertical septum and covers the prominence of the zygomatic bone, meeting with the temporal fat laterally. The lateral ZCL and the buccal fat pad constitute its inferior border.²⁹ Although some interpretations of the periorbital anatomy differentiate the SOOF from a deeper pre-periosteal fat, published anatomical evidence, as well as the authors' own observations, mostly support the idea of the SOOF directly adhering to the bone.^{29,34-36}

Finally, underneath the superficial MCF and the SMAS, the triangular-shaped DMCF directly overlies the maxillary bone. The DMCF is occasionally represented as 2 compartments (medial and lateral DMCF) partitioned by the levator anguli oris.³⁷

The nomenclature and location of the deep fat pads may vary throughout the literature, occasionally leading to discrepancies in recommended target injection areas. Our recommendation is to specifically target the deep fat compartments, that is, the mSOOF, ISOOF and/or DMCF (as appropriate depending on patient needs), which are directly affected by the aging process. In the following sections, the proposed treatment approach does not aim to fill spaces but rather to compensate fat atrophy and volume loss directly in the impacted areas.

Furthermore, because deep fat compartments have been shown to be relatively stable during aging (they are not displaced inferiorly onto the bone), deep filler implantation in these compartments and in contact with the bone will provide support for the overlying structures and increase anterior projection.³⁴

Ligaments and Septa

In the midface, the ORL and tear trough ligament, the ZCL, the buccal-maxillary ligaments, and the mandibular ligaments originate from the facial skeleton and pierce the SMAS to finally insert and spread into the dermis, thus qualifying as "true" retaining ligaments.³⁸⁻⁴¹ With age, loosening of this ligamentous system may contribute to the gravitational descent of superficial tissues.³⁸ Though the role of ligaments in facial aging has not been fully elucidated, weakening of the ORL may play a specific part in the formation of the tear trough deformity and palpebromalar groove.²⁷

Importantly, several pre-septal spaces permit the mobility of superficial tissue layers over deep ones and independent movements of the orbital and perioral portions of the superficial fascia: the pre-septal space of the lower lid is separated from the prezygomatic space by the ORL, in turn separated from the masticator space by the ZCL.⁴² These pre-septal spaces are generally exempt from blood vessels and nerves that pass through their boundaries, so the area is relatively safe for dermal filler injection.

Bone

With age, bone remodeling (resorption or augmentation) affects the facial skeleton at specific sites, thereby altering the location of all structures overlying the bone, that is, fat pads, ligaments, and muscles.^{43,44} Resorption of the superomedial and inferolateral aspects of the orbit contributes to the stigmata of periorbital aging, such as increased prominence of the medial fat pad, elevation of the medial brow, and lengthening of the lid-cheek junction (tear-trough deformity). In parallel, retrusion of the maxilla affects maxillary and pyriform angles, resulting in less support to the alar base and upper lip part of the nasolabial groove.⁴³

Anatomical Dangers

Extensive knowledge of the depth and course of blood vessels circulating in or nearby the midface area, along with their anatomical variations, is paramount to minimize the risk of complications associated with vascular injuries. Based on the usual course of essential neurovascular structures, we propose to rely on 2 anatomical lines, respectively running from the medial canthus to the mandibular angle (the mid-cheek safety line) and descending vertically from the middle of the zygomatic arch (the lateral safety line) (Figure 2).

In this section, the common pathway of the main arteries and veins running in the middle third of the face is hence reminded and placed in perspective with the proposed treatment area, as delineated by the 2 aforementioned "safety lines."

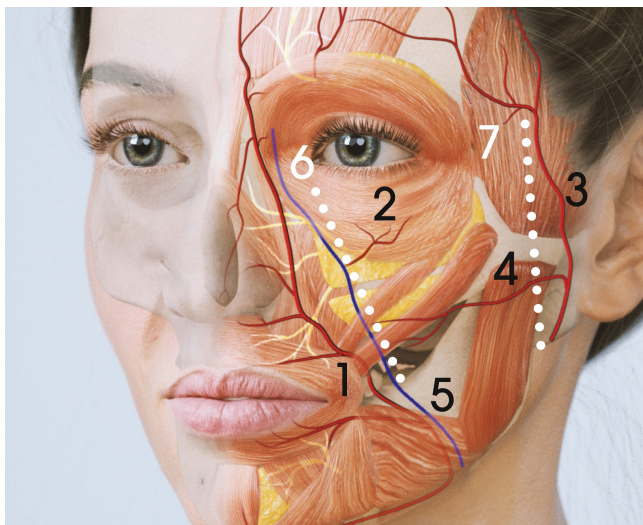


Figure 2. Vascular dangers of the midface and proposed safety lines delineating a relatively avascular area. 1, facial artery; 2, infra orbital foramen; 3, superficial temporal artery; 4, transverse facial artery; 5 facial vein 6, mid cheek safety line; 7, lateral safety line.

Facial Artery

The facial artery (FA), the main blood supply to the face, arises from the external carotid artery and enters the face from the submaxillary region. When running up sinuously in the face, its course is highly variable among individuals.⁴⁵⁻⁴⁸

According to recent anatomical studies, the FA runs along the nasolabial fold in most individuals, finishing up to the angular artery (36.6%), lateral nasal artery (48.6%), or superior labial artery (8.5%). However, a few individuals present a hypoplastic FA stopping at the inferior labial artery (6.8%). Furthermore, in approximately 30% of individuals, the FA divides into a nasolabial trunk and an infraorbital trunk, with the latter going up vertically and running toward the nasojugal groove.^{46,47}

In a cadaver study on 44 adult faces, Lee et al⁴⁹ found several paths of the FA that were categorized as Type I (51.8%), Type II (29.6%), and Type III (18.6%). Type II arteries feature an infraorbital trunk running either superficial to the zygomaticus major and deep to the zygomaticus minor (Type IIa), or above the muscles (Type IIb), but in any case, going up vertically toward the nasojugal groove, close to the facial vein (FV), and never above the mid-cheek groove.⁴⁹

None of the other studies published in the scientific literature suggested that the FA could run laterally to the mid-cheek groove (including the Hong et al study on 284 patients), and neither did any of the authors' own cadaver dissections.⁴⁵

Although this should not prevent the injector from applying other precautionary principles and monitoring signs and symptoms emerging during and after treatment,

staying above the mid-cheek groove should thus minimize risks of vascular injury implicating the FA or FV.

Infraorbital Artery

The infraorbital artery emerges through the infraorbital foramen and divides into 2 to 3 main branches: the palpebral branch, the nasal branch, and the labial branch). The 2 latter branches are located within the DMCF and supply the lateral nasal and superior labial regions, respectively, but mainly circulate under the mid-cheek safety line.⁵⁰

Importantly, the infraorbital foramen opening forms a downward angle with the maxilla; therefore, this area should never be approached from below with a tilt angle to minimize risks of slashing the artery.⁵¹

Superficial Temporal Artery

Originating in the parotid gland, the superficial temporal artery supplies the temporal and parietal areas. It runs superficially upward along the matching vein and the auriculotemporal nerve, between the ear tragus and the posterior root of the zygomatic arch, then divides into 2 main branches: the frontal branch and the parietal branch.⁴⁹ These vessels and nerves are theoretically not at risk if the injector refrains from injecting past the lateral safety line.

Transverse Facial Artery

Along with the FA, the transverse FA (TFA) constitutes one of the main blood supplies to the cheeks.⁵² Anatomical studies have shown that most individuals present a single TFA emerging from the superficial temporal artery and giving 2 branches: a superior emerging branch, and a deep emerging branch, which supplies the parotid gland, the parotid duct, and the masseter.⁵³ Because the superior emerging branch lies in the subcutaneous tissue, caution should be exerted when filling the superficial fat of the lateral cheek.⁵⁴

Zygomaticofacial Artery

Finally, the zygomaticofacial artery (ZFA) originates in the SOOF from the lacrimal artery, emerging from the zygomaticofacial foramen. Although this foramen has been relatively rarely described, studies have located it approximately 12 to 15 mm inferiorly and 5 to 9 mm laterally to the lateral canthus. Some authors also noted the absence of ZFA and foramen in a few patients.^{35,55-57}

The ZFA gives rise to many small branches either at the foramen level or soon after, which can anastomose with the TFA. Together with the zygomaticotemporal arteries, they form a vascular network below the OOM. However, the size of these capillaries is theoretically too small to constitute a potential HA embolus' entry door.

Facial Vein

The FV is the main venous drainage pathway of the face. At the lower border of the mandible, it courses near the FA, then follows a direct path up to the medial canthus, always passing under the zygomaticus major and minor muscles. Because the FV lies underneath the mid-cheek groove, it is located below the mid-cheek safety line.⁵²

TECHNIQUES

The Multilayering Approach

Changes in midface volume and shape may be efficiently and effectively compensated for with HA filler injections. Depending on each specific patient's anatomy, degree of bone resorption, midface volume loss, and ptosis of fat compartments, both subcutaneous and supraperiosteal injections may be performed and combined to reshape and replenish the upper cheek. Of note, though the actual "lifting effect" of midface augmentation remains controversial, some clinicians reported indirect benefits to the nasolabial fold.^{33,58}

Although young patients with limited volume deficit can generally be improved with injections limited to the deep fat compartments, older patients with significant volume loss and midface hollowing require double plane treatment to optimize outcomes. This "multilayering" approach starts with supraperiosteal injections targeting the deep fat pads (mainly the medial SOOF, lateral SOOF, and DMCF to create deep support for the cheek) and finishes with superficial injections into the mobile subcutaneous fat pads.

Anatomical differences between genders and ethnicities should also guide the treatment strategy. For instance, high injection volumes in the ISOOF could feminize the face of a male patient. The treatment should respect the specific anatomy of the man's cheek, which is generally flatter but more angulated than the female midface.⁵⁹ Briefly, midface injections tend to be more inferomedial in men compared with superolateral in women.⁶⁰ On the other hand, patient ethnicity may also impact bony structure, fat distribution, or skin thickness, thereby requiring an adapted treatment strategy. For instance, in Asian patients, the anteromedial cheek should generally be injected before the zygomatic arch to avoid an exaggerated lateral projection.^{61,62}

In this section, we describe deep and superficial techniques consistent with previously described anatomical landmarks and "safety lines," which may be combined to perform a multilayering midface treatment. The step-by-step video of a midface augmentation procedure involving deep and superficial fat injection with a cannula is available online at www.aestheticsurgeryjournal.com.

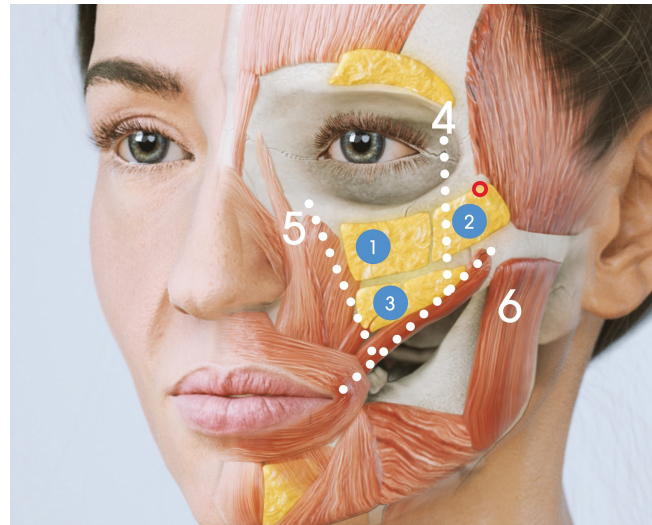


Figure 3. Deep fat injection technique: bolus. The medial sub-orbicularis oculi fat (1), lateral sub-orbicularis oculi fat (2), and deep medial cheek fat (3) can be located employing the following anatomical landmarks: (4) vertical facial line, (5) mid-cheek line, (6) zygomatic line. Blue dots can be employed as needle entrance points. The red circle shows the lateral entry point that may be utilized to perform the bolus technique with a cannula.

Deep Fat Injection Techniques

The first step of a midface rejuvenation treatment is to provide structural support through injection into the deep fat layer, targeting the mSOOF, the ISOOF, and the DMCF, which can be mapped by tracing 3 lines on the patient's face: the vertical facial line descending vertically from the lateral canthus, the mid-cheek line coinciding with aforementioned safety line, and the zygomatic line (following the path of the zygomatic major muscle) spanning from the oral commissure to the lowest peak of the cheekbone (Figure 3).

Multiple Bolus Technique With a Needle

The original Tri-Site Bolus technique patented by Dr Wayne Carey⁶³ was subsequently adapted by several authors aiming to achieve a similar effect, that is, create deep pillars supporting the superficial mid-cheek structures.^{18,36}

This technique involves the injection of 3 boluses respectively targeting the mSOOF, ISOOF, and DMCF (Figure 3). The injection is performed slowly and at a low pressure, inserting the needle bevel-down with a 90° angle to the skin surface until touching the bone. Broadly speaking, injection volumes as low as 0.2 mL per fat pad may suffice to provide a visual improvement, but cases of severe volume deficit will likely require 0.3 mL or more per compartment. This may significantly vary depending on patient assessment and product choice. Of note, injecting higher amounts in the mSOOF than in the ISOOF will enhance anterior projection,

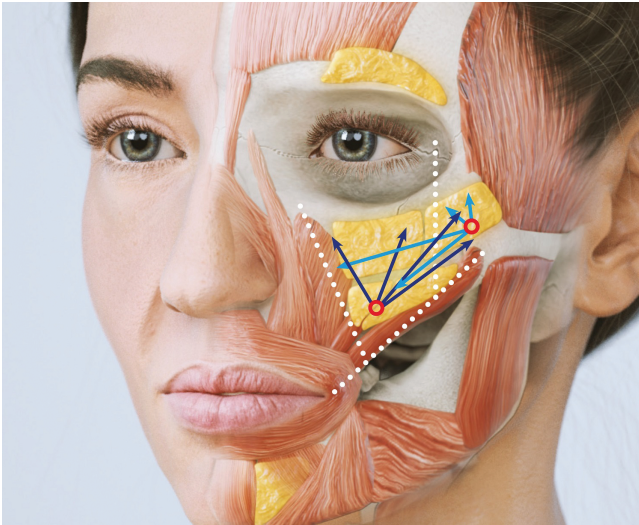

Figure 4. Deep fat injection technique: fanning. Blue arrows represent cannula tracks from a lateral entry point (light blue) or a medial entry point (dark blue).

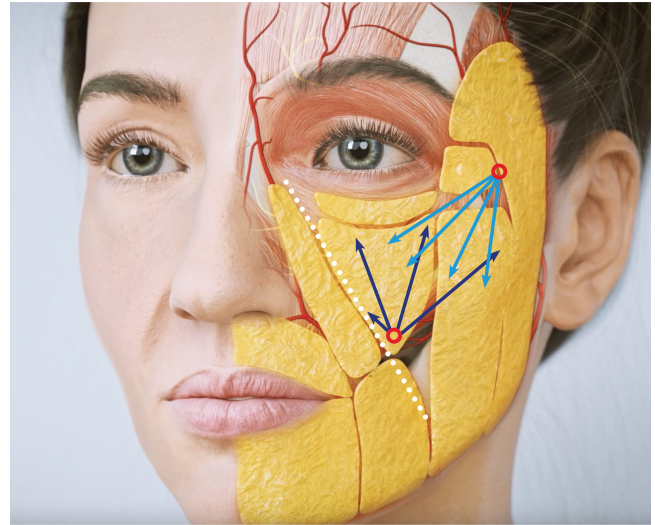


Figure 5. Superficial fat injection technique: fanning. Blue arrows represent the fanning technique employing a needle or cannula from a lateral entry point (light blue) or a medial entry point (dark blue).

and even greater volume in the DMCF will create a fuller mid-cheek, thus allowing to customize each treatment to individual patient needs. Afterward, gentle digital massage helps smooth the product into place and reduce visible irregularities, particularly in thin-skinned patients.²⁹

Alternatively, Shamban et al. described a close technique employing 2 three-point rows, found within a treatment area delineated by 2 lines running from the oral commissure to the ear groove and from the lateral canthus to the hairline.¹⁸ Six supra-periosteal depot injections of 0.1 to 0.2 mL were thus administered in a lateral-to-medial direction, starting with the superior row.¹⁸

Multiple Bolus Technique With a Cannula

The deep bolus injection technique can also be performed with a 25G cannula from an entry point located laterally to the ISOOF (Figure 3) or medially at the bottom of the DMCF. The lateral entry point is positioned 1 to 2 cm below the lateral canthus on a straight line from the lateral orbit, that is, in a relatively safe and poorly vascularized area.⁵¹ When entering from the medial point, the injector should always stay above the mid-cheek safety line to avoid encountering the FV and potentially the infraorbital trunk of the FA.⁴⁷

The pre-hole needle is pressed as deeply as possible into the entry point with an angle of 90°. Soft tissues are then lifted with the non-dominant hand to insert the cannula into the deep fat layer with an angle of approximately 60°. A reliable indication is that the cannula's movement should not be visible on the skin surface when moving into the deep layer. The cannula is advanced along the bone until it reaches the mSOOF, where the first bolus is deposited, then slightly retracted until the ISOOF to inject a second bolus. To administer the final bolus into the DMCF,

the cannula is entirely withdrawn and reinserted in the desired direction. Failure to insert the cannula into the deep plane will result in inadvertent placement into the more superficial mobile layers. This can result in an unnatural look on animation if using a poorly stretchable HA product.

Fanning Technique With a Cannula

The last option for injecting the deep fat layer of the midface is to perform a horizontal fanning technique with a cannula, accessing the area from similar entry points as for the deep bolus technique (Figure 4). Following cannula insertion, gentle retrograde or anterograde injection of the filler is performed employing a low pressure, with constant motion, evenly delivering 0.1 to 0.3 mL along each cannula track. The cannula is retracted and readvanced in several directions targeting the different fat compartments without completely withdrawing it from the skin.

Again, the cannula must not be advanced medial to the mid-cheek safety line when injecting into the DMCF and progressing medially. This should minimize risks of encountering the FV or branches of the infraorbital artery on the one hand and of overfilling the NLF region on the other hand.

Superficial Fat Injection Technique With a Needle or Cannula

In older patients, injecting into the mobile fat pads aims to create a roof above the structural support provided by deep injections. Fanning is the gold standard technique and may be performed with either a needle or a cannula.

Entry point(s) are the same as previously described for deep cannula injections (Figure 5), but needle or cannula insertion is performed at a more acute angle (30°),

Table 1. Comparison of the Rheological Characteristics of Several Hyaluronic Acid Fillers Indicated for Midface Augmentation^a

Manufacturer	Product	HA concentration (mg/mL)	Strength (10^4 Pa^2)	Stretch (10^{-6} s^{-1})
Teoxane (Geneva, Switzerland)	TEOSYAL RHA 3 (RHA3)	23	28 ± 4	98 ± 13
	TEOSYAL RHA 4 (RHA4)	23	80 ± 1	51 ± 5
	TEOSYAL PureSense Ultra Deep (HA _{UD})	25	83 ± 5	28 ± 7
Allergan plc (Irvine, CA)	Juvederm Voluma (VYC-20L)	20	33 ± 1	20 ± 3
Galderma Laboratories (Lausanne, Switzerland)	Restylane Lyft (RES _{LYFT})	20	35 ± 2	9 ± 2

^aBased on instructions for utilization in force in Europe at the date of article writing. ^bStrength and stretch scores were obtained according to mechanical and rheological testing protocols previously described by Faivre et al.¹⁵

stretching the skin with the fingers of the non-dominant hand to ensure the needle or cannula slides within the superficial fatty layer. The filler is delivered through several gentle retrograde or anterograde injections, redirecting the needle or cannula several times without completely withdrawing it and placing 0.1 to 0.3 mL along each track. The medial and middle-fat pads are the main targeted compartments and can be accessed from both entry points. Of note, employing a lateral entry provides access to the lateral infraorbital fat in case it needs to be filled.

As described in the Anatomy section, several important arteries running in the subcutaneous tissue of the midface must be borne in mind: the FA—which can be avoided by refraining from crossing the mid-cheek safety line—the ZFA in the upper lateral IOF, and the superior emerging branch of the TFA in the lower MiCF.

PRODUCTS

The last key aspect of our midface treatment algorithm resides in the product choice. Midface fillers should be carefully selected to ensure optimal and durable treatment outcomes as well as a natural look both in static and dynamic expressions (eg, on smiling). Although several publications on randomized controlled trials support the utilization of HA products for midface augmentation,^{64,65} none has precisely described a systematic and adapted multilayering approach targeting the deep and superficial planes with products of adapted rheological properties.

Depending on its composition (HA molecular weight, HA concentration, and crosslinking degree), every HA filler has unique viscoelastic properties that are commonly characterized employing rheological parameters such as the elastic modulus (G'). To alleviate shortcomings of the G' , which is measured in nearly static conditions, a recent study introduced the new concepts of strength and stretch. The strength, specifically, reflects the ability of a gel to retain its characteristics when subjected to a wide

range of mechanical stresses, and the stretch measures its propensity to deform under facial movement.⁶⁶

A comparison of the rheological characteristics of several fillers approved for midface augmentation in the European Union and/or in the United States is provided in Table 1. Presented rheological scores were obtained according to a previously described protocol.¹⁵

Generally speaking, “firm” HA fillers, characterized by a high G' and a high strength, are ideal candidates for injections into the deep static fat pads to provide strong, persistent structural support and malar projection. Therefore, TEOSYAL Ultra Deep (HA_{UD}) and RHA 4 (RHA4) (Teoxane, Geneva, Switzerland), which exhibited the highest strength scores among commercially available midface fillers, are the logical choice. To avoid surface irregularities in thin-skinned individuals, these may be replaced by softer and more malleable products characterized by slightly lower strength but superior stretch scores (eg, RHA3 [Teoxane]).

Although deep fat compartments are anatomically separated by septa and retaining ligaments, superficial fat pads are less divided and allow for distribution of the filler from one compartment to the other. In the dynamic superficial fat pads, the product should thus be relatively stretchable to accompany facial movements without producing a “bumped” cheek that would look unnatural.⁶⁷ Fillers of the RHA line, specifically RHA3 and RHA4 manufactured with the Preserved Network technology, are therefore suitable candidates because they provide a balance between high stretch and sufficient dynamic strength scores (Table 1).

Two different filler types can thus be combined within a multilayering approach, always considering patient morphology and skin type. Indeed, very stiff fillers that could effectively restore malar projection when placed supraperiosteally could create an unnatural look when injected in the mobile subcutaneous plane, where only malleable products are recommended.

Alternatively, if only 1 product is to be injected within both planes, dynamic fillers must be favored, seeking the

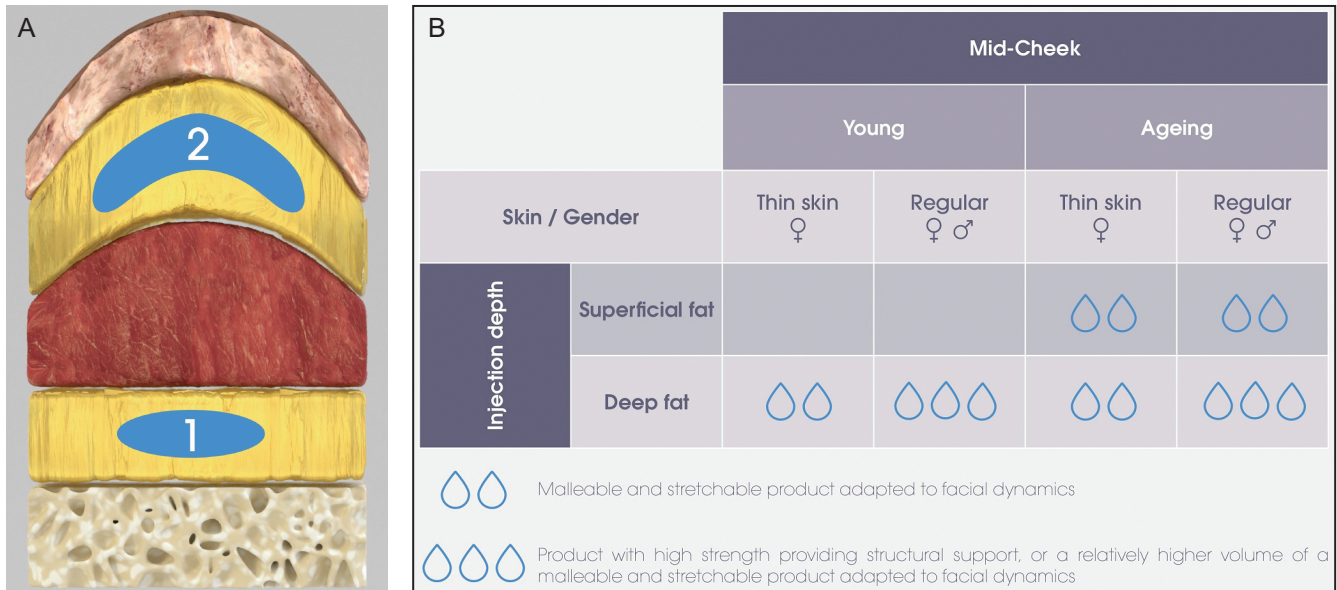


Figure 6. Multilayer treatment algorithm for filling deep (1) and superficial (2) fat layers of the mid-cheek (A) with hyaluronic acid fillers adapted to specific patient needs depending on age, gender, and skin type (B).

best possible compromise between projection capacity and adaptability to facial movement. In that case, relatively higher volumes in the deeper places may be required to provide adequate support to the upper cheeks.

Considering all 3 aspects presented in this review (anatomy, techniques, and products), we therefore propose a midface treatment algorithm in Figure 6, adapting product type, injection volume and/or injection plane depending on patient’s age, gender, and skin type.

DISCUSSION

In this article, we present relevant age-related changes affecting the 5-layered arrangement of the midface and summarize the course of essential vascular structures circulating nearby the area. To restore a youthful appearance involving malar projection and fuller cheeks, we delineate a relatively avascular HA filler treatment zone, bounded by a “mid-cheek safety line” and a “lateral safety line.”

In our view, the deep static fat compartments of the midface—the mSOOF, ISOOF, and DMCF—can be safely injected with either a bolus or a fan-like technique. Positioned deep onto the periosteum, filler depots will remain unaffected by muscle movements and hence provide structural support and malar projection and act as deep pillars elevating the cheek. In cases of severe volume deficit, additional fanning is advised in the dynamic superficial fat pads to finetune and optimize the desired correction.

When adopting a multilayering technique, the choice of filler may not be obvious because specific patient characteristics (including bone structure, skin thickness, and

degree of midface volume deficit) on the one hand and facial dynamism on the other hand must be considered. A filler’s strength is the primary concern when targeting the deep static fat, but stretch is equally important when filling the mobile subcutaneous fat to ensure natural-looking results.⁶⁶ Meeting these requirements may be achieved employing either 1 or 2 different products, depending on the injector’s preference and patient needs.

By limiting the injections within the delineated area, the risk of encountering essential arteries and veins should be minimal. Nonetheless, despite all safety precautions, vascular compromise remains a well-known and documented complication of HA filler injections. Therefore, any injector should be able to recognize the signs (eg, skin blanching, mottled discoloration, and/or pain) and to promptly manage cases of vascular occlusion. Immediate and repeated hyaluronidase injection at the treatment site and in the ischemic region must be performed until capillary refill is restored.⁶⁸⁻⁷¹

Our multilayer algorithm may overcome shortcomings of previously described “single-plane” injection techniques, which may not address all aspects of the midface aging process.^{2,18} It should also minimize the risks of creating an unnatural look by choosing specifically designed products adapted to the different mechanical constraints of each soft tissue layer.⁶⁶

In our clinical practice, the multilayering approach provided visible aesthetic improvements of the midface area while preserving the natural-looking appearance of patients of different age, gender, and skin type by adapting injection volumes and targeted fat pads to their individual needs. Clinical cases are presented in Figures 7 to 9.

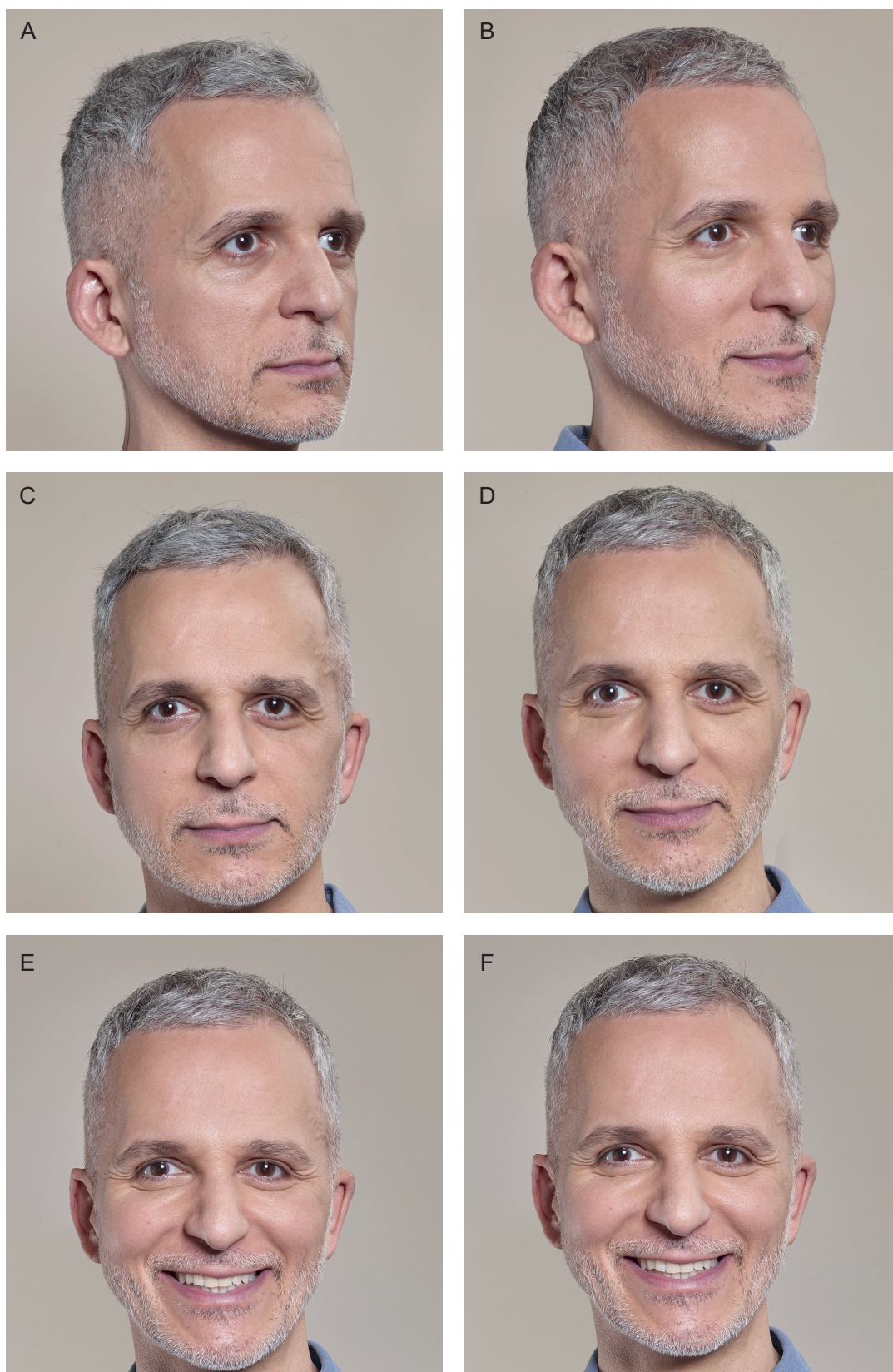

Figure 7. Before and after photographs of this 45-year-old male patient are shown from (A, B) a three-quarter view and from a frontal view, (C, D) in a neutral expression, and (E, F) during smiling. He received 1.2 mL of TEOSYAL Ultra Deep in the deep fat and 2.4 mL of RHA 4 (both Teoxane, Geneva, Switzerland) in the superficial fat of the midface (total volumes for both sides). A 25G, 38-mm cannula was utilized to perform both deep and superficial injections.

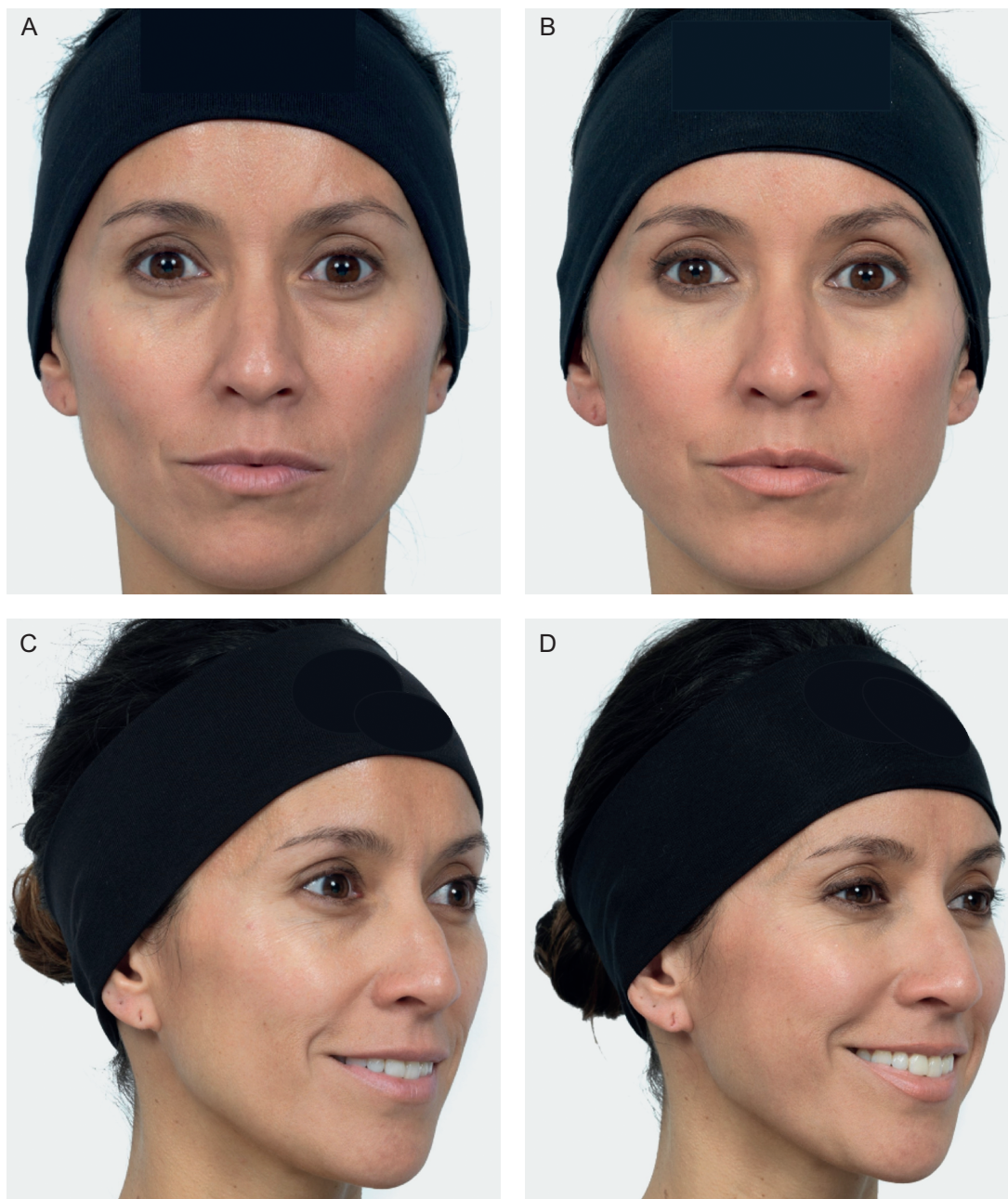

Figure 8. Before and after photographs of this 40-year-old female patient are shown from a frontal view in a (A, B) neutral expression and from a (C, D) three-quarter view during smiling. She received 0.7 mL of TEOSYAL Ultra Deep in the deep fat and 3 mL of RHA 4 (both Teoxane, Geneva, Switzerland) in the superficial fat of the midface (total volumes for both sides). A 27G, 13-mm needle and a 25G, 50-mm cannula were utilized to perform deep and superficial injections, respectively.

Because it is built on literature data and on the authors' own experience and anatomical studies, this guidance article has inherent limitations and proposed concepts need to be validated through clinical investigations. However, its content reflects the opinion of 4 experts in the fields of aesthetic surgery or dermatology with several years of experience in midface augmentation with fillers.

Previously published clinical studies support the overall safety of HA injection into the midface.^{64,65} Nonetheless, stronger clinical evidence is needed to further support the added value of the multilayering technique, for example, through randomized controlled trials comparing this approach with "deep-only" injections and evaluate differences in injection volumes and aesthetic outcomes.

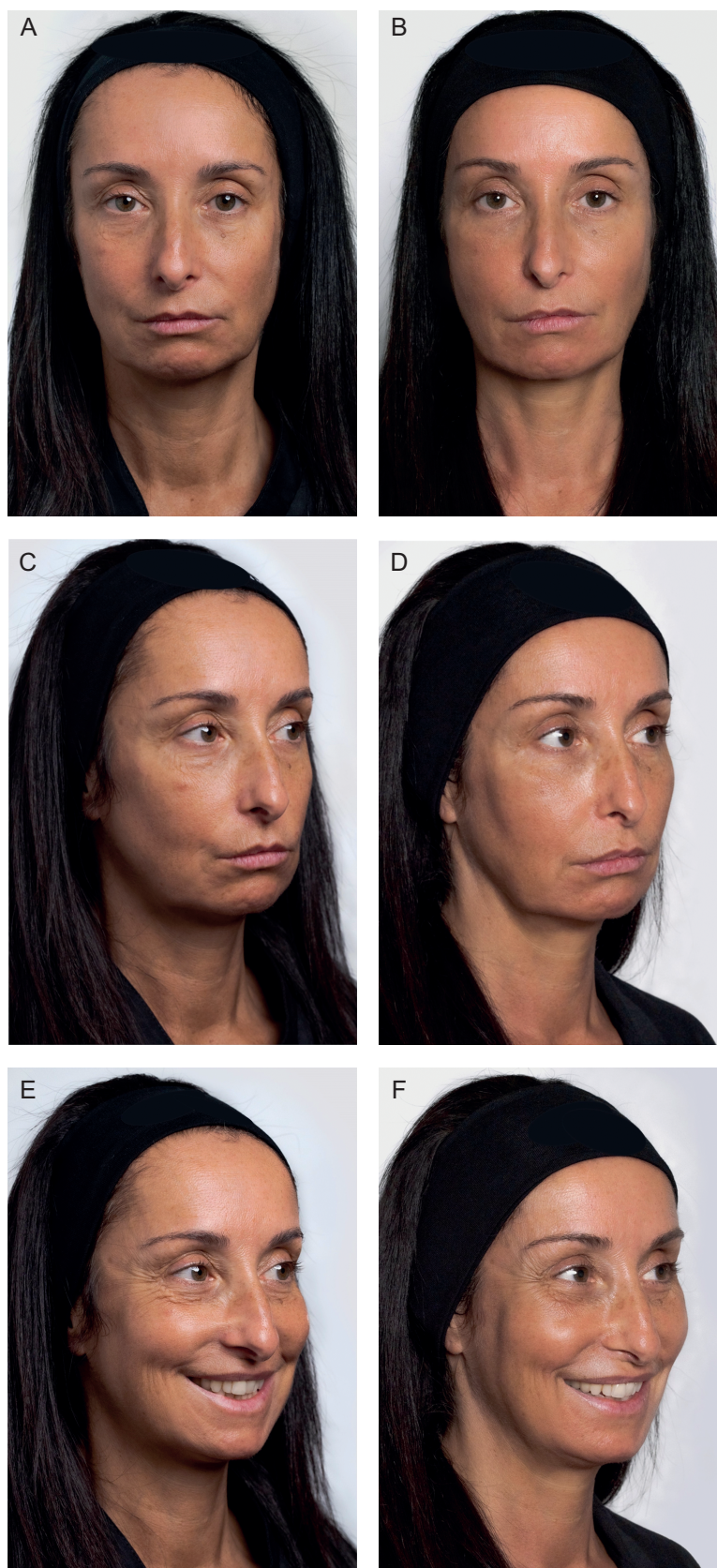

Figure 9. Before and after photographs of this 50-year-old female patient are shown from a (A, B) frontal view and from a 3-quarter view in a (C, D) neutral expression and (E, F) during smiling. She received 1.2 mL of TEOSYAL Ultra Deep in the deep fat and 1.2 mL of RHA 4 (both Teoxane, Geneva, Switzerland) in the superficial fat of the midface (total volumes for both sides). A 25G, 38-mm cannula was utilized to perform both deep and superficial injections.

CONCLUSIONS

Safe, effective, and natural-looking midface rejuvenation can be obtained with HA fillers when combining 3 essential criteria: extensive anatomy knowledge, appropriate injection techniques, and adequate product choices providing structural support and accompanying dynamic facial expression. The multilayering technique is the logical treatment approach to address volume deficit and age-related changes affecting all layers of the midface. Targeting multiple planes for midface augmentation offers the possibility to adapt a filler's rheology to the functional and mechanical specificities of each layer, favoring stronger products with high projection capacity in the deep static fat and stretchable fillers respecting facial dynamism in the superficial fat. Finally, employing the algorithm proposed in this article, the treatment can be fine-tuned to respect each patient's anatomy and aging process by adapting product choice and injection volumes in each fat compartment.

Supplemental Material

This article contains supplemental material located online at www.aestheticsurgeryjournal.com.

Disclosures

Drs Trévidic, Kaufman-Janette, Weinkle, Wu, and Dhillon have financial relationships with Teoxane SA (Geneva, Switzerland) as consultants, trainers, or clinical investigators. Drs Antunes and Macé and Mrs Maffert are employees of Teoxane SA.

Funding

The authors received no financial support for the research, authorship, and publication of this article.

REFERENCES

- Fitzgerald R, Carqueville J, Yang PT. An approach to structural facial rejuvenation with fillers in women. *Int J Womens Dermatol*. 2019;5(1):52-67.
- de Maio M, DeBouille K, Braz A, Rohrich RJ. Facial assessment and injection guide for botulinum toxin and injectable hyaluronic acid fillers: focus on the midface. *Plast Reconstr Surg*. 2017;140(4):540e-550e.
- Monheit GD. Nonsurgical facial rejuvenation. *Facial Plast Surg*. 2014;30(4):462-467.
- Pontius AT, Chaiet SR, Williams EF 3rd. Midface injectable fillers: have they replaced midface surgery? *Facial Plast Surg Clin North Am*. 2013;21(2):229-239.
- National Plastic Surgery Statistics 2020*. American Society of Plastic Surgeons. Accessed September 3, 2021. <https://www.plasticsurgery.org/documents/News/Statistics/2020/plastic-surgery-statistics-full-report-2020.pdf>
- DeLorenzi C. Complications of injectable fillers, part I. *Aesthet Surg J*. 2013;33(4):561-575.
- Signorini M, Liew S, Sundaram H, et al. Global aesthetics consensus: avoidance and management of complications from hyaluronic acid fillers-evidence- and opinion-based review and consensus recommendations. *Plast Reconstr Surg*. 2016;137(6):961e-971e.
- Kablik J, Monheit GD, Yu L, Chang G, Gershkovich J. Comparative physical properties of hyaluronic acid dermal fillers. *Dermatol Surg*. 2009;35(Suppl 1):302-312.
- Stocks D, Sundaram H, Michaels J, Durrani MJ, Wortzman MS, Nelson DB. Rheological evaluation of the physical properties of hyaluronic acid dermal fillers. *J Drugs Dermatol*. 2011;10(9):974-980.
- Tezel A, Fredrickson GH. The science of hyaluronic acid dermal fillers. *J Cosmet Laser Ther*. 2008;10(1):35-42.
- da Costa A, Biccigo DGZ, de Souza Weimann ET, et al. Durability of three different types of hyaluronic acid fillers in skin: are there differences among biphasic, monophasic monodensified, and monophasic polydensified products? *Aesthet Surg J*. 2017;37(5):573-581.
- Flynn TC, Sarazin D, Bezzola A, Terrani C, Micheels P. Comparative histology of intradermal implantation of mono and biphasic hyaluronic acid fillers. *Dermatol Surg*. 2011;37(5):637-643.
- Raspaldo H. Volumizing effect of a new hyaluronic acid sub-dermal facial filler: a retrospective analysis based on 102 cases. *J Cosmet Laser Ther*. 2008;10(3):134-142.
- Goodman GJ, Bekhor P, Rich M, Rosen RH, Halstead MB, Rogers JD. A comparison of the efficacy, safety, and longevity of two different hyaluronic acid dermal fillers in the treatment of severe nasolabial folds: a multicenter, prospective, randomized, controlled, single-blind, within-subject study. *Clin Cosmet Investig Dermatol*. 2011;4:197-205.
- Faivre J, Gallet M, Tremblais E, Trévidic P, Bourdon F. Advanced concepts in rheology for the evaluation of hyaluronic acid-based soft tissue fillers. *Dermatol Surg*. 2021;47(5):e159-e167.
- Wilson AJ, Taglienti AJ, Chang CS, Low DW, Percec I. Current applications of facial volumization with fillers. *Plast Reconstr Surg*. 2016;137(5):872e-889e.
- Cattin TA. A single injection technique for midface rejuvenation. *J Cosmet Dermatol*. 2010;9(3):256-259.
- Shamban A, Clague MD, von Grote E, Nogueira A. A novel and more aesthetic injection pattern for malar cheek volume restoration. *Aesthetic Plast Surg*. 2018;42(1):197-200.
- Winslow C. Filling the midface: injectables. *Facial Plast Surg*. 2016;32(5):473-479.
- Shamban A. Customized approach to facial enhancement. *Facial Plast Surg Clin North Am*. 2015;23(4):471-477.
- Cotofana S, Lachman N. Anatomy of the facial fat compartments and their relevance in aesthetic surgery. *J Dtsch Dermatol Ges*. 2019;17(4):399-413.
- Accioli de Vasconcellos JJ, Britto JA, Henin D, Vacher C. The fascial planes of the temple and face: an en-bloc anatomical study and a plea for consistency. *Br J Plast Surg*. 2003;56(7):623-629.
- Rohrich RJ, Pessa JE, Ristow B. The youthful cheek and the deep medial fat compartment. *Plast Reconstr Surg*. 2008;121(6):2107-2112.
- Rohrich RJ, Pessa JE. The fat compartments of the face: anatomy and clinical implications for cosmetic surgery. *Plast Reconstr Surg*. 2007;119(7):2219-2227.

25. Gierloff M, Stöhring C, Buder T, Gassling V, Açil Y, Wiltfang J. Aging changes of the midfacial fat compartments: a computed tomographic study. *Plast Reconstr Surg.* 2012;129(1):263-273.
26. Rohrich RJ, Pessa JE. The retaining system of the face: histologic evaluation of the septal boundaries of the subcutaneous fat compartments. *Plast Reconstr Surg.* 2008;121(5):1804-1809.
27. Lee JH, Hong G. Definitions of groove and hollowness of the infraorbital region and clinical treatment using soft-tissue filler. *Arch Plast Surg.* 2018;45(3):214-221.
28. Cevik Cenkeri H, Sarigul Guduk S, Derin Cicek E. Aging changes of the superficial fat compartments of the midface over time: a magnetic resonance imaging study. *Dermatol Surg.* 2020;46(12):1600-1605.
29. Ingallina F. *Facial Anatomy and Volumizing Injections 2017 (Superior and Middle Third).* 2017.
30. Gierloff M, Stöhring C, Buder T, Wiltfang J. The subcutaneous fat compartments in relation to aesthetically important facial folds and rhytides. *J Plast Reconstr Aesthet Surg.* 2012;65(10):1292-1297.
31. Pirayesh A, Bertossi D, Heydenrych I. *Aesthetic Facial Anatomy Essentials for Injections.* CRC Press; 2020.
32. Pils U, Anderhuber F, Rzany B. Anatomy of the cheek: implications for soft tissue augmentation. *Dermatol Surg.* 2012;38(7 Pt 2):1254-1262.
33. Lambros V. Observations on periorbital and midface aging. *Plast Reconstr Surg.* 2007;120(5):1367-1376.
34. Cotofana S, Gotkin RH, Frank K, et al. The functional anatomy of the deep facial fat compartments: a detailed imaging-based investigation. *Plast Reconstr Surg.* 2019;143(1):53-63.
35. Alghoul MS, Vaca EE, Bricker JT, Mioton LM. Enhancing the lateral orbital "C-Angle" with calcium hydroxylapatite: an anatomic and clinical study. *Aesthet Surg J.* 2021;41(8):952-966.
36. Cotofana S, Schenck TL, Trévidic P, et al. Midface: clinical anatomy and regional approaches with injectable fillers. *Plast Reconstr Surg.* 2015;136(5 Suppl):219s-234s.
37. Lamb JP, Chase Surek C. Chapter 1: The midface. In: Thieme, ed. *Facial Volumization.* Georg Thieme Verlag; 2018.
38. Stuzin JM, Baker TJ, Gordon HL. The relationship of the superficial and deep facial fascias: relevance to rhytidectomy and aging. *Plast Reconstr Surg.* 1992;89(3):441-449.
39. Moss CJ, Mendelson BC, Taylor GI. Surgical anatomy of the ligamentous attachments in the temple and periorbital regions. *Plast Reconstr Surg.* 2000;105(4):1475-1490.
40. Alghoul M, Codner MA. Retaining ligaments of the face: review of anatomy and clinical applications. *Aesthet Surg J.* 2013;33(6):769-782.
41. Wong CH, Hsieh MKH, Mendelson B. The tear trough ligament: anatomical basis for the tear trough deformity. *Plast Reconstr Surg.* 2012;129(6):1392-1402.
42. Mendelson BC, Jacobson SR. Surgical anatomy of the midcheek: facial layers, spaces, and the midcheek segments. *Clin Plast Surg.* 2008;35(3):395-404; discussion 393.
43. Mendelson B, Wong CH. Changes in the facial skeleton with aging: implications and clinical applications in facial rejuvenation. *Aesthetic Plast Surg.* 2012;36(4):753-760.
44. Toledo Avelar LE, Cardoso MA, Santos Bordonni L, de Miranda Avelar L, de Miranda Avelar JV. Aging and sexual differences of the human skull. *Plast Reconstr Surg Glob Open.* 2017;5(4):e1297.
45. Hong SJ, Park SE, Jo JW, et al. Variant facial artery anatomy revisited: conventional angiography performed in 284 cases. *Medicine (Baltim).* 2020;99(28):e21048-e21048.
46. Lee HJ, Won SY, Jehoon O, et al. The facial artery: a comprehensive anatomical review. *Clin Anat.* 2018;31(1):99-108.
47. Lee JG, Yang HM, Choi YJ, et al. Facial arterial depth and relationship with the facial musculature layer. *Plast Reconstr Surg.* 2015;135(2):437-444.
48. Scheuer JF 3rd, Sieber DA, Pezeshk RA, Campbell CF, Gassman AA, Rohrich RJ. Anatomy of the facial danger zones: maximizing safety during soft-tissue filler injections. *Plast Reconstr Surg.* 2017;139(1):50e-58e.
49. Lee J-G, Yang H-M, Hu K-S, et al. Frontal branch of the superficial temporal artery: anatomical study and clinical implications regarding injectable treatments. *Surg Radiol Anat.* 2015;37(1):61-68.
50. Kim HS, Lee KL, Gil YC, Hu KS, Tansatit T, Kim HJ. Topographic anatomy of the infraorbital artery and its clinical implications for nasolabial fold augmentation. *Plast Reconstr Surg.* 2018;142(3):273e-280e.
51. Galadari H. Middle third. In: Galadari H, ed. *Soft Tissue Augmentation: Principles and Practice.* Berlin, Germany: Springer Berlin Heidelberg; 2018:39-65.
52. von Arx T, Tamura K, Yukiya O, Lozanoff S. The face – a vascular perspective. A literature review. *Swiss Dent J.* 2018;128(5):382-392.
53. Yang H-J, Gil Y-C, Lee H-Y. Topographical anatomy of the transverse facial artery. *Clin Anat.* 2010;23(2):168-178.
54. DeLorenzi C, Karpova E, Rzany B, Trévidic P, Lamilla GC. *Anatomy and Filler Complications.* E2e Medical Publishing; 2017.
55. Beheiry EE, Abdel-Hamid FAM. An anatomical study of the temporal fascia and related temporal pads of fat. *Plast Reconstr Surg.* 2007;119(1):136-144.
56. Bozиков K, Shaw-Dunn J, Soutar DS, Arnez ZM. Arterial anatomy of the lateral orbital and cheek region and arterial supply to the "peri-zygomatic perforator arteries" flap. *Surg Radiol Anat.* 2008;30(1):17-22.
57. Nakajima H, Imanishi N, Minabe T. The arterial anatomy of the temporal region and the vascular basis of various temporal flaps. *Br J Plast Surg.* 1995;48(7):439-450.
58. Mowlds DS, Lambros V. Cheek volumization and the nasolabial fold. *Plast Reconstr Surg.* 2018;141(5):1124-1129.
59. Wysong A, Kim D, Joseph T, MacFarlane DF, Tang JY, Gladstone HB. Quantifying soft tissue loss in the aging male face using magnetic resonance imaging. *Dermatol Surg.* 2014;40(7):786-793.
60. Wang JV, Valiga A, Albornoz CA, Geronemus RG. Comparison of injectable filler locations in men and

- women: an age-matched case analysis. *J Cosmet Dermatol*. 2021;20(8):2469-2471.
61. Li D, Wang X, Wu Y, et al. A randomized, controlled, multicenter study of Juvéderm Voluma for enhancement of malar volume in Chinese subjects. *Plast Reconstr Surg*. 2017;139(6):1250e-1259e.
 62. Hong G, Oh S, Kim B, Lee Y. Filler procedures based on the facial area. In: Hong G, Oh S, Kim B, Lee Y, eds. *The Art and Science of Filler Injection: Based on Clinical Anatomy and the Pinch Technique*. Springer Singapore; 2020:103-175.
 63. Carey W, Inventor. *Treatment With Hyaluronic Acid* - Patent US 7.491,709 B2 2009.
 64. Jones D, Murphy DK. Volumizing hyaluronic acid filler for midface volume deficit: 2-year results from a pivotal single-blind randomized controlled study. *Dermatol Surg*. 2013;39(11):1602-1612.
 65. Weiss RA, Moradi A, Bank D, et al. Effectiveness and safety of large gel particle hyaluronic acid with lidocaine for correction of midface volume deficit or contour deficiency. *Dermatol Surg*. 2016;42(6):699-709.
 66. Faivre J, Gallet M, Tremblais E, Trévidic P, Bourdon F. Advanced concepts in rheology for the evaluation of hyaluronic acid-based soft tissue fillers. *Dermatol Surg*. 2021;47(5):e159-e167.
 67. Galadari H. Chapter 5: Middle Third. *Soft Tissue Augmentation*. Springer; 2018.
 68. Abduljabbar MH, Basendwh MA. Complications of hyaluronic acid fillers and their managements. *J Dermatol Dermatol Surg*. 2016;20(2):100-106.
 69. Cohen JL, Biesman BS, Dayan SH, et al. Treatment of hyaluronic acid filler-induced impending necrosis with hyaluronidase: consensus recommendations. *Aesthet Surg J*. 2015;35(7):844-849.
 70. De Boule K, Heydenrych I. Patient factors influencing dermal filler complications: prevention, assessment, and treatment. *Clin Cosmet Investig Dermatol*. 2015;8:205-214.
 71. Snozzi P, Van loghem J. Complication management following rejuvenation procedures with hyaluronic acid fillers—an algorithm-based approach. *Plast Reconstr Surg*. 2018;6(12):e2061.

The Importance of Functional Quality in Patient Satisfaction: Cosmetic Injectable Patient Experience Exploratory Study (CIPEES) – Part Two

Look for more Visual Abstracts like this one on social media, in print, and online.

Objectives

Determine the relative importance of functional quality (FQ) factors in the care of cosmetic injectable patients and return patronage.



Methods

Via online survey, authors assessed reasons for return patronage to a specific cosmetic injector and the correlation between satisfaction with cosmetic results.



Conclusions

To maximize patient satisfaction and return patronage, health care practitioners should focus on improving FQ care and value it at least as high as technical quality.



The Importance of Functional Quality in Patient Satisfaction: Cosmetic Injectable Patient Experience Exploratory Study (CIPEES) – Part Two

McDonald CB, Heydenrych I

Aesthet Surg J Open Forum. 2022;4. doi:10.1093/asj/of/ocac044

AESTHETIC SURGERY JOURNAL
OPEN FORUM