


## CASE REPORT

# Masquerading bundle branch block obscuring the diagnosis of Brugada syndrome: an electrocardiographic and vectorcardiographic study

Isabel V. Konopka<sup>1</sup>, Hugo A. Garro<sup>1</sup>, Rita B. Tepper<sup>1</sup>, Norma Pizzarelli<sup>1</sup>, Mario D. Gonzalez<sup>2</sup>  & Rafael S. Acunzo<sup>1</sup>

<sup>1</sup>Division of Cardiology, Ramos Mejía Hospital, Buenos Aires, Argentina

<sup>2</sup>Clinical Electrophysiology, Hershey Medical Center, Pennsylvania State University, Hershey, Pennsylvania

### Correspondence

Rafael S. Acunzo, Division of Cardiology, Ramos Mejía Hospital, Urquiza 609, Buenos Aires C1221ADC, Argentina.  
Tel: 54114127-0246;  
E-mail: rsaacunzo@fibertel.com

### Funding Information

No sources of funding were declared for this study.

Received: 23 April 2017; Accepted: 27 May 2017

*Clinical Case Reports* 2017; 5(8): 1362–1368

doi: 10.1002/ccr3.1059

## Background

Brugada syndrome is associated with an increased risk of sudden cardiac death due to the development of malignant ventricular arrhythmias [1]. The characteristic electrocardiogram abnormality that facilitates the diagnosis is the coved ST elevation in V1–V3 and defined as type 1 Brugada pattern. However, this pattern is not present in all patients due to varying phenotypical presentation, but it can be uncovered following the administration of sodium channel blocking drugs.

Recently, it has been shown that the concomitant occurrence of a high-degree right bundle branch block can mask the ECG manifestations of the Brugada pattern [2, 3]. This is important because the administration of sodium channel blockers can not only elicit the coved ST elevation characteristic of type 1 Brugada but also induce right bundle branch block that can preclude the ECG manifestations of Brugada syndrome.

In this study, we describe the development of masquerading bundle branch block following the administration of

## Key Clinical Message

We describe the induction of a masquerading bundle branch block in two patients with Brugada syndrome following the administration of Ajmaline. The development of this conduction disturbance prevented the correct electrocardiographic diagnosis. However, the simultaneously obtained vectocardiogram identified both the Brugada pattern and the masquerading bundle branch block.

## Keywords

Ajmaline, Brugada syndrome, masquerading bundle branch block.

ajmaline, a conduction disorder not previously reported in Brugada syndrome. In addition, we show that similar to right bundle branch block, masquerading bundle branch block can obscure the typical ECG changes associated with Brugada syndrome.

## Methods

### Patients

Between 2005 and 2015, 129 patients (mean age  $31 \pm 11$ ; 79 males) with recurrent syncope, no evidence of structural heart disease, and type 2 Brugada pattern were referred to the Center of Cardiac Arrhythmias of the Autonomous City of Buenos Aires (Division of Cardiology, *Hospital General de Agudos J. M. Ramos Mejía*) for an ajmaline challenge test. In addition, 34 of these 129 patients had a family history of sudden death.

All the patients were evaluated with echocardiography and exercise stress test. When clinically required, the

patients also underwent myocardial perfusion scintigraphy (SPECT) or cardiac magnetic resonance imaging (CMRI).

### Provocative test

A 12-lead electrocardiogram (ECG) was performed at rest and after the administration of intravenous ajmaline at a dose of 1 mg/kg up to a maximum of 70 mg over 5 min, using the Cardio Scan Resting 12-Lead ECG, Beijing, China. The QRS complexes, T waves, intervals, segments, and axes were measured automatically. These recordings were then stored, reproduced, and printed with different amplitudes (2.5, 5, 10, and 20 mm/mV) and speeds (25 and 50 mm/sec). Vectorcardiograms (VCGs) were simultaneously recorded by the same program, using the Frank modified system. VCG loops on a beat-to-beat basis were also obtained.

### Definitions of high-degree right bundle branch block, masquerading bundle branch block, and Brugada pattern types 1 and 2

The diagnosis of *high-degree right bundle branch block* was made when the following three criteria were met [4]:

- (1) wide QRS complex ( $\geq 120$  msec);
- (2) rsR' pattern in lead V1 and qRS pattern in lead V6; and
- (3) wide and slurred S wave in lead I and terminal R wave in lead aVR.

When a single dominant R wave with or without a notch was present in V1, a normal R peak time in leads V5 and V6 but  $>50$  msec in lead V1 was required to make the diagnosis of high-degree right bundle branch block.

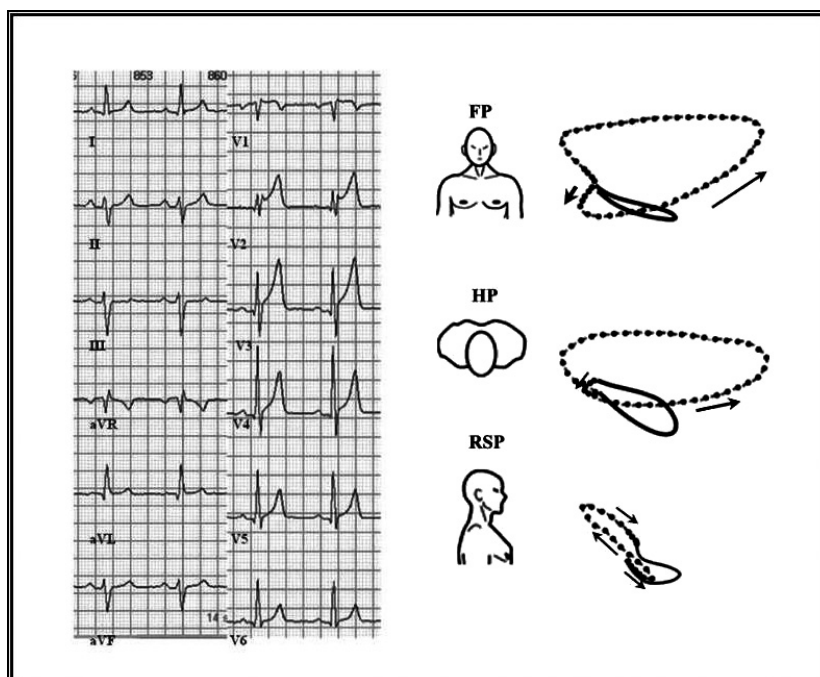
*Masquerading bundle branch block* was defined as a QRS resembling a left bundle branch block in the frontal plane and a right bundle branch block in the precordial plane [5].

Type 1 Brugada pattern: Coved pattern: initial ST elevation  $\geq 2$  mm, slowly descending and concave or rectilinear with respect to the isoelectric baseline, with negative symmetric T wave [6].

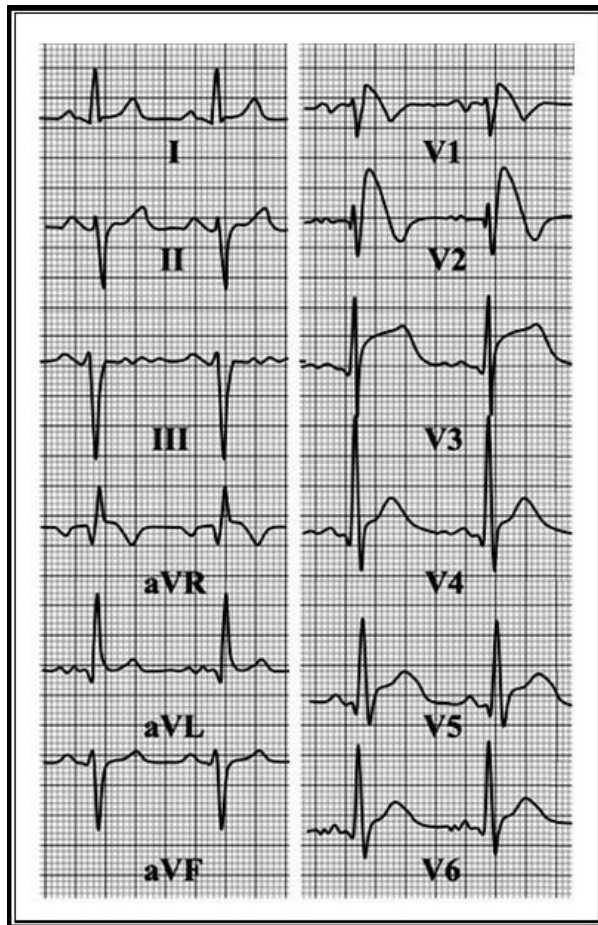
Type 2 Brugada saddle-back pattern: The high takeoff ( $r'$ ) is  $\geq 2$  mm with respect to the isoelectric line and is followed by ST elevation; convex with respect to the isoelectric baseline with elevation  $\geq 0.05$  mV with positive/flat T wave in V2 and T-wave variable in V1. If there is some doubt (i.e.,  $r' < 2$  mm), it is necessary to record the ECG in 2nd and 3rd intercostal spaces [6].

### Results

Following the administration of ajmaline, 66 of these 129 patients (51%) developed the characteristic ECG type 1 Brugada pattern. Twenty-nine of these 66 patients (44%) also developed intraventricular conduction disorders: right bundle branch block (RBBB), in 27 patients (isolated or associated with left anterior fascicular block), and



**Figure 1.** Recordings of a 45-year-old male patient without structural heart disease and a history of recurrent syncope. The ECG and the VCG show type 2 Brugada pattern associated with LAFB.



**Figure 2.** ECG and VCG recordings within the first minutes of ajmaline infusion showing the typical type 1 Brugada pattern.

masquerading BBB in two patients at peak ajmaline effect. We shall now describe these two patients in detail.

The first patient was a 45-year-old man with recurrent syncope. His baseline ECG and VCG (Fig. 1) showed type 2 Brugada pattern associated with low-degree LAFB. Within 2–3 min following the administration of ajmaline, type 1 Brugada pattern developed along with a more pronounced LAFB uncovered by this drug (Fig. 2). However, at peak ajmaline effect (Fig. 3), the ECG and VCG showed a clear masquerading BBB with QRS duration of 190 msec, J-point and ST-segment elevation followed by a negative T wave. The PR interval was prolonged (210 msec). Lead I showed absence of q wave and a QRS consistent with a left bundle branch block (LBBB). In contrast, leads V1, V2, and V3 showed right BBB pattern with an initial q wave. This narrow q wave mimicking septal necrosis was not present in the baseline ECG and indicates lack of septal activation by the left midseptal fascicle [7]. The VCG showed that the first vector was oriented downwards, slightly leftwards, and backwards. In the frontal plane, the QRS loop was clearly

shifted to the left. The amplitude of the spatial vector at 46 msec was lower compared with its baseline voltage and was oriented leftwards, forwards, and upwards,  $-45^\circ$  in the frontal plane, similar to the image of the isolated LAFB. Unlike the typical RBBB associated with LAFB, the vector at 80 msec had higher amplitude and was oriented upwards, backwards, and to the midpoint, indicating delayed septal depolarization. The final electrical forces were directed forwards and downwards, but not as rightward as in a typical RBBB because they were counterbalanced by the delayed activation of the interventricular septum. Both the ECG and the VCG showed a masquerading BBB with delayed activation of the right bundle, left anterior fascicle, and left midseptal fascicle [7]. The wide QRS in the right precordial leads with slurring of the terminal portion of the QRS made the onset of the T wave difficult to determine. In contrast to the ECG, the VCG clearly demonstrated the magnitude of the vector corresponding to the ST segment with greater amplitude in the horizontal and sagittal planes. The increase of the ST-segment vector after ajmaline administration, directed anteriorly and to the right, facilitated the diagnosis of Brugada syndrome.

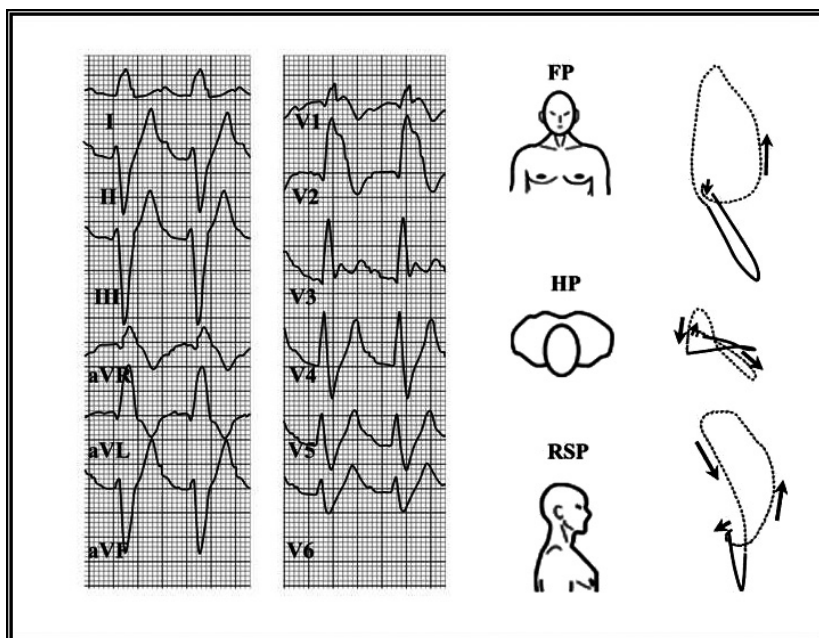
The second patient was a 45-year-old woman with recurrent syncope. Her mother had an episode of sudden death and documented ventricular fibrillation.

In the frontal plane (Fig. 4), the VCG showed the initial QRS loop with clockwise rotation (mimicking inferior necrosis that was ruled out by echocardiography and MRI), followed by counterclockwise rotation, consistent with incomplete LAFB and left midseptal fascicle block. High and low precordial leads show a clear type 2 Brugada pattern. Immediately after the administration of ajmaline, the patient developed an incomplete RBBB, high-degree LAFB, and a type 1 Brugada pattern (Fig. 5, panels A and B) with QT prolongation and T-wave alternans (Fig. 5, panel C). These electrocardiographic features are consistent with marked dispersion of transmural repolarization and increased risk of ventricular fibrillation. Finally, at peak ajmaline effect, both the ECG and VCG showed the development of a masquerading BBB, again obscuring the ECG diagnosis of Brugada (Fig. 6).

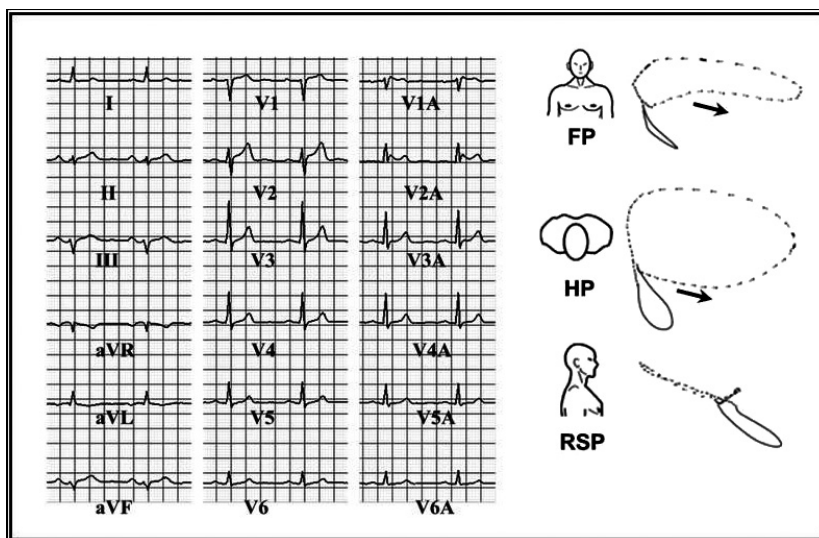
Both patients underwent electrophysiology study, during which they developed polymorphic ventricular tachycardia degenerating into ventricular fibrillation, requiring external defibrillation to restore sinus rhythm.

## Discussion

Masquerading BBB is a frequently unrecognized intraventricular conduction disorder [4]. Although previously considered a conduction disturbance occurring in abnormal hearts, we have recently shown that masquerading BBB can be observed in patients without structural heart



**Figure 3.** ECG and VCG recordings of a masquerading BBB during ajmaline peak effect. The J-point is difficult to determine due to QRS widening observed in the ECG with the masquerading BBB. In contrast, the VCG clearly shows the ST-segment elevation characteristic of type 1 Brugada pattern.



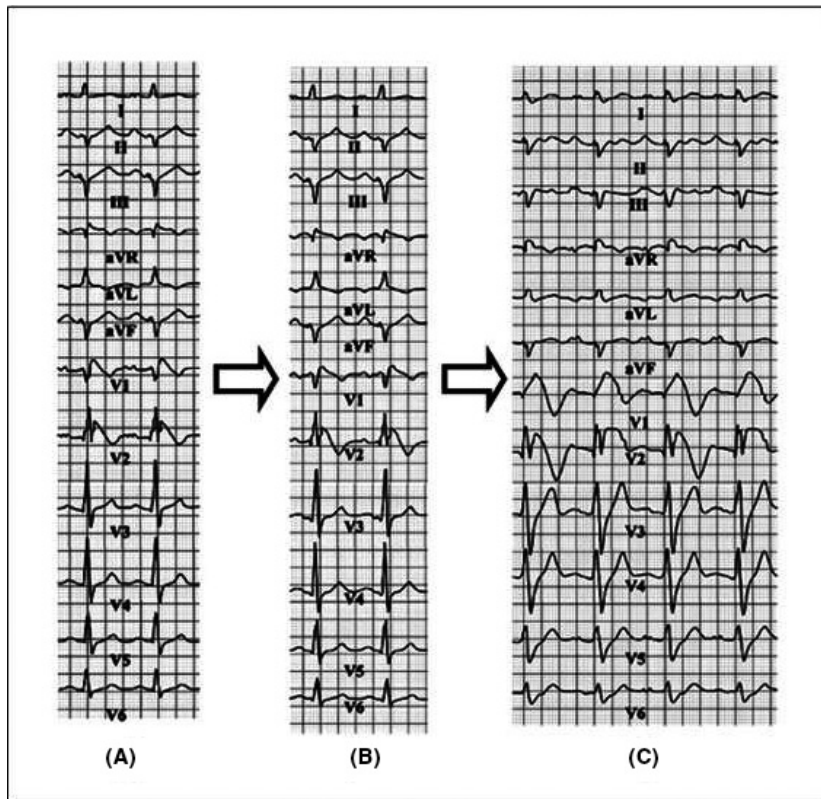
**Figure 4.** ECG with recording of high precordial leads and VCG at baseline of a 45-year-old woman with no evidence of structural heart disease, history of recurrent syncope, and family history of sudden death due to ventricular fibrillation in a first-degree relative (for details see text).

disease during aberrant ventricular conduction elicited by premature atrial beats [7]. We have now shown that this conduction disturbance can also be elicited following ajmaline administration.

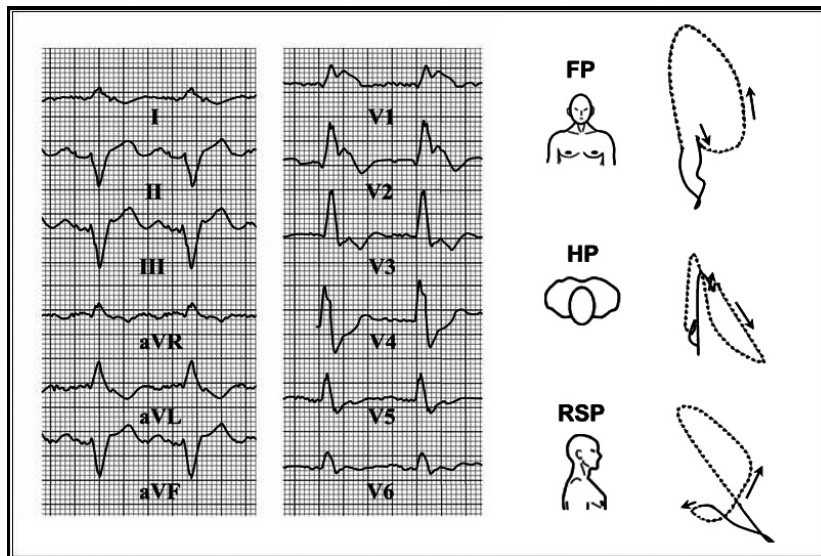
Brugada syndrome is a genetic disease with an autosomal dominant pattern of inheritance and variable penetration and is a common cause of sudden death in young subjects [1].

Type 1 Brugada pattern is present in <0.2% of subjects, but can be found between 3% and 24% of individuals with idiopathic ventricular fibrillation, depending on the diagnostic criteria used [8–14].

The most common mutations involve the sodium channel *SCN5A* gene, which modifies the activation, inactivation, or reactivation of the sodium channel. Carriers of this mutation usually present longer PR and HV



**Figure 5.** Development of type 1 Brugada pattern panels A and B within the first minutes of ajmaline infusion, followed by T-wave alternans (C) (for details see text).



**Figure 6.** A masquerading BBB is induced following the administration of ajmaline.

intervals and wider QRS complexes after the administration of sodium channel blockers [15]. Right BBB is the most common intraventricular conduction disturbance

elicited by ajmaline in patients with Brugada syndrome. However, a masquerading BBB as described in our patients has not been previously reported.

Although the  $\beta$  angle has high positive and negative predictive values in patients with Brugada syndrome, it has also been described in patients with other conduction disorders [16]. This angle is associated with both depolarization and repolarization and is influenced by a wide QRS, conduction disorders, or abnormal ventricular repolarization. It is reasonable to think that as both of our patients had fascicular blocks in their baseline ECGs, the characteristics of this angle may be absent or lost in this type of patients, as the administration of ajmaline induced type 1 Brugada pattern which is pathognomonic of this condition. A consensus statement has reported the criteria to be used to determine whether type 1 Brugada pattern represents a real Brugada syndrome [6]. In our cases, the VCG obtained during masquerading BBB at peak ajmaline effect undoubtedly shows the displacement of the J-point [17]. The J-point is displaced and the ST-segment vector has a greater magnitude and is oriented forwards in the horizontal and sagittal planes; yet, the downwards slope of the ST segment observed in the ECG at 1 and 2 mm is  $\geq 4$  mm and is due to the presence of high-degree BBB [2, 3], developed within the first minutes, which modifies the characteristics of type 1 Brugada pattern as shown in Figures 2 and 5.

The results of our study indicate that the induction of masquerading BBB at peak ajmaline effect can mask the ECG manifestations of Brugada type 1 pattern. The VCG, by clearly defining the J-point and ST elevation, can facilitate the correct diagnosis.

### Study limitations

Genetic testing was not performed in our patients to detect sodium channel mutations. However, only 20–30% of patients with Brugada syndrome have identifiable genetic mutations. Therefore, the diagnosis is based on the clinical and electrocardiographic presentation and a negative genetic testing does not rule out Brugada syndrome.

### Conclusions

In these two cases, the administration of ajmaline initially induced the typical type 1 Brugada pattern followed by a masquerading BBB. Once this conduction disorder occurred, it obscured the typical ECG changes required to diagnose the Brugada type 1 pattern.

On the other hand, the VCG was critical in facilitating the diagnosis of Brugada in the presence of masquerading BBB as it accurately defined the J-point and the ST segment at a time when it remained unclear in the ECG.

### Authorship

IVK: prepared manuscript. HAG: reviewed data. RBT: performed the clinical studies. NP: performed the clinical studies. MDG: guided the authors in writing the manuscript and proof read the final manuscript. RSA: designed the study and wrote the manuscript.

### Conflict of Interest

None declared.

### References

1. Brugada, P., and J. Brugada. 1992. Right bundle branch block, persistent ST segment elevation and sudden cardiac death: a distinct clinical and electrocardiographic syndrome. *J. Am. Coll. Cardiol.* 20:1391–1396.
2. Chiale, P. A., H. A. Garro, P. A. Fernández, and M. V. Elizari. 2012. High-degree right bundle branch block obscuring the diagnosis of Brugada electrocardiographic pattern. *Heart Rhythm* 9:974–976.
3. Wada, T., S. Nagase, H. Morita, et al. 2015. Incidence and Clinical Significance of Brugada Syndrome Masked by Complete Right Bundle-Branch Block. *Circ. J.* 79:2568–2575.
4. Surawicz, B., R. Childers, B. J. Deal, and L. S. Gettes. 2009. AHA/ACCF/HRS recommendations for the standardization and interpretation of the electrocardiogram part III: intraventricular conduction disturbances. *J. Am. Coll. Cardiol.* 53:976–981.
5. Rosenbaum, M. B., M. V. Elizari, and J. O. Lazzari. 1968. *Los hemibloqueos*, 315 pp. Paidós, Buenos Aires.
6. Bayés de Luna, A., J. Brugada, A. Baranchuk, et al. 2012. Current electrocardiographic criteria for diagnosis of Brugada pattern: a consensus report. *J. Electrocardiol.* 45:433–442.
7. Acunzo, R. S., I. V. Konopka, and R. A. Sánchez. 2013. Right bundle branch block and middle septal fiber block with or without left fascicular block manifested as aberrant conduction in apparent healthy individuals: Electrovectorcardiographic characterization. *J. Electrocardiol.* 46:167–172.
8. Priori, S. G., C. Blomström-Lundqvist, A. Mazzanti, et al. 2015. 2015 ESC Guidelines for the management of patients with ventricular arrhythmias and the prevention of sudden death. *Eur. Heart J.* 36:2793–2867.
9. Antzelevitch, C., P. Brugada, and M. Borggrefe. 2005. Brugada syndrome: report of the second consensus conference: endorsed by the Heart Rhythm Society and the European Heart Rhythm Association. *Circulation* 111:659–670.
10. Sieira, J., G. Dendramis, and P. Brugada. 2016. Pathogenesis and management of Brugada syndrome. *Nat. Rev. Cardiol.* 13:1–13.

11. Miyasaka, Y., H. Tsuji, K. Yamada, et al. 2001. Prevalence and mortality of the Brugada-type electrocardiogram in one city in Japan. *J. Am. Coll. Cardiol.* 38:771–774.
12. Matsuo, K., M. Akahoshi, E. Nakashima, et al. 2004. Clinical characteristics of subjects with the Brugada-type electrocardiogram. *J. Cardiovasc. Electrophysiol.* 15:653–657.
13. Atarashi, H., S. Ogawa, K. Harumi, et al. 2001. Three-year follow-up of patients with right bundle branch block and ST segment elevation in the right precordial leads: Japanese registry of Brugada syndrome. Idiopathic ventricular fibrillation investigators. *J. Am. Coll. Cardiol.* 37:1916–1920.
14. Junttila, M. J., M. J. Raatikainen, J. Karjalainen, et al. 2004. Prevalence and prognosis of subjects with Brugada-type ECG pattern in a young and middle-aged Finnish population. *Eur. Heart J.* 25:874–878.
15. Brugada, R., J. Brugada, C. Antzelevitch, G. E. Kirsch, D. Potenza, and P. Brugada. 2000. Sodium channel blockers identify risk for sudden death in patients with ST-segment elevation and right bundle branch block but structurally normal hearts. *Circulation* 101:510–515.
16. Chevallier, S., A. Forclaz, J. Tenkorang, et al. 2011. New electrocardiographic criteria for discriminating between Brugada types 2 and types 3 patterns and incomplete right bundle branch block. *J. Am. Coll. Cardiol.* 58:2290–2298.
17. Mirvis, D. M. 1982. Evaluation of normal variations in S-T segment pattern by body surface mapping: S-T segment elevation in absence of heart disease. *Am. J. Cardiol.* 50:122–128.