

# Rickets in a child with prolonged acquired hypothyroidism secondary to Hashimoto's thyroiditis

Caroline Schulmeister<sup>1,4</sup>, Jason Lee<sup>2,3</sup>, Farzana Perwad<sup>2</sup>, Roger Long<sup>1</sup> and Shylaja Srinivasan<sup>1</sup>

<sup>1</sup>Pediatric Endocrinology, <sup>2</sup>Pediatric Nephrology, University of California at San Francisco, San Francisco, California, USA, <sup>3</sup>Pediatric Nephrology, University of Pennsylvania, Philadelphia, Pennsylvania, USA, and <sup>4</sup>Pediatric Endocrinology, University of California at Davis, Sacramento, California, USA

Correspondence  
should be addressed  
to C Schulmeister  
**Email**  
[cschulmeister@ucdavis.edu](mailto:cschulmeister@ucdavis.edu)

## Summary

Skeletal abnormalities with delayed bone age and decreased linear bone growth are commonly found in children with prolonged juvenile hypothyroidism. However, rachitic bone abnormalities have not been previously reported in children with acquired hypothyroidism. Here, we present a case of newly found rickets in an 8-year-old female with untreated acquired hypothyroidism secondary to Hashimoto's thyroiditis. Laboratory finding for abnormalities in calcium/phosphorus homeostasis and hormones that regulate skeletal health was normal. Her radiographic anomalies resolved with levothyroxine treatment alone, suggesting that hypothyroidism was the etiology of the rickets. To our knowledge, this is the first case report of rickets associated with long-standing severe acquired hypothyroidism that resolved exclusively with thyroid repletion.

## Learning points:

- Thyroid hormone plays an important role in bone mineralization.
- Prolonged hypothyroidism can result in rachitic bone abnormalities noted on radiographs.
- Hypothyroidism should be considered in the evaluation of a child with rickets.

## Background

### What's new?

- Rachitic bone abnormalities have not been previously reported in children with acquired hypothyroidism.
- To our knowledge, this is the first case report of rickets associated with long-standing severe acquired hypothyroidism that resolved exclusively with thyroid repletion.
- Improvement in skeletal abnormalities with thyroid treatment reflects the importance of thyroid hormone in skeletal development in children.

## Case presentation

An 8-year-old African American female presented to pediatric endocrinology for the evaluation of short stature. She had a lack of statural growth and excessive weight gain for 4 years prior to presentation. She was at the 3rd percentile for height, 97th percentile for weight, and her BMI was >99th percentile. Her mid-parental height is 175 cm (97th percentile). The patient reported difficulty in walking and shortness of breath even with minimal physical activity. Her examination was notable for bilateral genu valgum deformity causing significant joint pain which limited her physical activity and participation in



**Table 1** Thyroid function tests.

	Initial	2 months
Thyroid-stimulating hormone 0.5–4.30 mIU/L	>150	5.96
Free thyroxine 0.9–1.4 ng/dL	0.2	0.9
Thyroperoxidase antibody < 9 IU/mL	835	
Thyroglobulin antibody < 1 IU/mL	< 1	

sports. Her mother was unsure when this deformity first presented. She had no loss of deciduous teeth.

## Investigation

As part of her evaluation for short stature, she was found to have severe hypothyroidism with a TSH of >150 mIU/L and free T4 of 0.2 ng/dL with positive thyroid auto-antibodies (Table 1) indicating Hashimoto's thyroiditis. In addition, she had low alkaline phosphatase (alk phos), elevated aspartate transaminase (AST), elevated creatinine (Cr), anemia, low growth factor (IGF-1), and evidence of dyslipidemia (Table 2). She had delayed bone age characteristic of hypothyroidism and also had incidental radiographic findings consistent with rickets with metaphyseal fraying, cupping, and sclerosis of the distal radius and ulna (Fig. 1).

Laboratory testing for the etiology of rickets was unrevealing for known causes of rickets with normal serum levels of calcium, phosphorus, 25 hydroxy vitamin D, 1,25 dihydroxy vitamin D, parathyroid hormone, and urinary calcium excretion (Table 3). She had a low alk phos level which is likely related to severe hypothyroidism but does not support the diagnosis of rickets. She was evaluated in pediatric nephrology in the setting of rickets with abnormal creatinine. Further workup did not reveal underlying kidney disease.

**Table 2** Metabolic Laboratory findings.

	Initial	1 month	4 months	8 months
Insulin-like growth factor 1 80–307 ng/mL	32		137	
Insulin-like growth factor binding protein 3 1.6–6.5 mg/L	2.1		2.9	
Alkaline phosphatase 181–415 U/L	75	334		
Alanine transaminase 20–50 U/L	26	24		
Aspartate transaminase 17–42 U/L	55	34		
Low-density lipoproteins <110 mg/dL	172			83
High-density lipoproteins >45 mg/dL	43			35
Triglycerides <75 mg/dL	146			182 (not fasting)
White blood count 4.5–13.5 Thousand/ $\mu$ L	4.7	4.6		
Hemoglobin 11.5–15.5 g/dL	8.1	9.1		
Hematocrit 35–45 %	23.3	28.6		
Platelet count 140–450 thousand/ $\mu$ L	282	410		

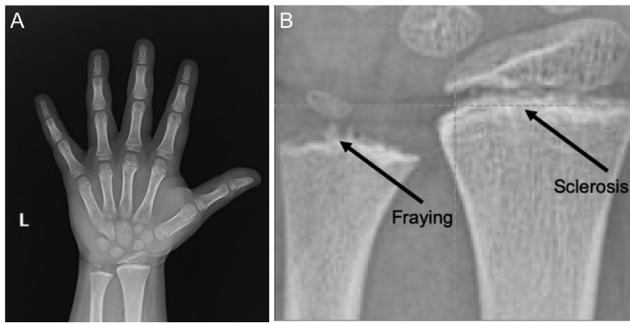
## Treatment

The patient was started on 75  $\mu$ g of oral levothyroxine with subsequent dose titration to reach a dose of 175  $\mu$ g (2.4  $\mu$ g/kg) based on thyroid function tests, targeting a TSH within the normal range. The patient was neither advised to increase calcium nor vitamin D intake as these levels were normal at baseline and she was reported to have at least three servings of calcium-containing foods per day.

The patient was evaluated by an orthopedic surgeon due to her significant genu valgum deformity and recurrent pain-limiting physical activity. She ultimately had bilateral femur and tibia hemiepiphyodesis, also known as guided growth, to help correct the deformity with subsequent improvement in her symptoms. Following surgery, she was eventually able to resume physical activity.

## Outcome and follow-up

Repeat x-rays of her wrist after 4 and 11 months of levothyroxine treatment showed gradual improvement in her rickets and increased mineralization of her bones (Fig. 2). Serum IGF-1 level was normalized and coincided with significant catch-up growth from the 3% tile to the 45% tile in the first year of treatment. This was accompanied by a disproportionate advancement in her bone age as previously described in children treated with levothyroxine after prolonged acquired hypothyroidism (1), resulting in an improvement in her predicted adult height but still below her mid-parental height. Additionally, biochemical abnormalities observed at time of diagnosis including low alk phos, elevated AST, elevated Cr, anemia, and elevated LDL and triglycerides level all improved with levothyroxine treatment (Table 1).



**Figure 1**  
(A) Radiograph of left hand at initial bone age. Bone age was 6 years 10 months at a chronological age of 8 years 7 months ( $-1.8$  s.d.). Predicted height was 156 cm with a mid-parental height of 175 cm. (B) Enlargement of initial bone age. Arrows represent sclerosis and fraying at the epiphyses of the radius and ulna.

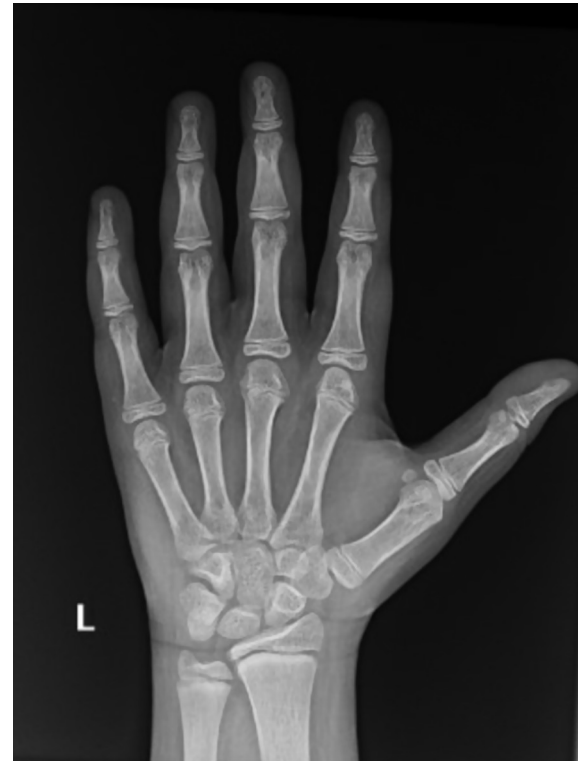## Discussion

Our patient had radiographic findings of rickets marked by metaphyseal fraying, cupping, and sclerosis of the distal radius and ulna in the setting of severe hypothyroidism which was likely long-standing given her 4 years of poor statural growth. In addition, she had the clinical findings of rickets with genu valgum requiring orthopedic intervention. She lacked the laboratory findings classically associated with rickets and had radiographic improvement of rickets following levothyroxine treatment alone. This suggests that hypothyroidism was the sole cause of her rachitic changes.

While the evaluation of a child with rickets does not typically include thyroid studies, thyroid hormone is known to play an important role in bone development as seen by short stature and delayed bone age that is commonly found in a growing child with hypothyroidism (1). Thyroid hormone not only plays an important role in bone growth but is also known to play a critical role in bone mineralization. Cartilage matrix expansion and mineralization occur via proliferating and differentiating

**Table 3** Bone-related laboratory findings.

	Initial	1 month	2 months
Creatinine 0.30–0.60 mg/dL	0.97		0.44
Calcium 8.8–10.3 mg/dL	9.7	9.7	9.4
Phosphorus 2.8–5.7 mg/dL		5.6	5.1
Albumin 8–59 pg/mL		21	
Parathyroid hormone 0.30–0.60 mg/dL		0.45	
Vitamin D 1, 25 31–87 pg/mL	57		
Vitamin D 25 hydroxy 30–100ng/mL	39		
Urine calcium mg/dL		0.9	
Urine creatinine mg/dL		16	



**Figure 2**  
Follow-up bone age with improvement in sclerosis and fraying after levothyroxine treatment.

chondrocytes that secrete matrix proteins and growth factors to regulate cartilage vascular invasion and mineralization by osteoblasts (2). Thyroid hormone receptors are expressed in growth plate chondrocytes, osteoblasts, and osteoclasts (2). Additionally, triiodothyronine (T3) promotes hypertrophic chondrocyte differentiation and cell volume expansion needed for mineralization (3). Poor mineralization has previously been described in individuals with congenital hypothyroidism who are born with low thyroid levels, and prolonged untreated hypothyroidism can lead to irregular epiphyseal appearance known as stippled epiphyseal dysgenesis and is more often to be found in large cartilaginous centers such as the head of the femur or humerus (4, 5, 6). In adults, abnormal thyroid levels are known to cause poor bone mineralization and increased risk of fractures (2). Since rickets is caused by poor mineralization of the endochondral matrix, rickets can theoretically occur in a growing child with prolonged acquired hypothyroidism but is not typically seen in practice.

Our patient's finding of rickets from prolonged acquired hypothyroidism due to Hashimoto's thyroiditis emphasizes the role of thyroid hormone to regulate bone mineralization. Thus hypothyroidism should be considered



when evaluating a child with rickets, particularly when more common causes of rickets have been ruled out.

---

#### Declaration of interest

The authors declare that there is no conflict of interest that could be perceived as prejudicing the impartiality of the research reported.

---

#### Funding

This work was supported by the National Institutes of Health (grant numbers T32-DK007699, T32DK007219, 1K23DK120932 (S S)).

---

#### Patient consent

Written informed consent for the publication of clinical details was obtained from the guardian of the patient.

---

#### Author contribution statement

Dr. Schulmeister drafted the initial manuscript, and reviewed and revised the manuscript. Drs Lee, Perwad, Long, and Srinivasan reviewed and

revised the manuscript. All authors approved the final manuscript as submitted and agree to be accountable for all aspects of the work.

---

#### References

- 1 Rivkees SA, Bode HH & Crawford JD. Long-term growth in juvenile acquired hypothyroidism: the failure to achieve normal adult stature. *New England Journal of Medicine* 1988 **318** 599–602. (<https://doi.org/10.1056/NEJM198803103181003>)
- 2 Duncan Bassett JH & Williams GR. Role of thyroid hormones in skeletal development and bone maintenance. *Endocrine Reviews* 2016 **37** 135–187. (<https://doi.org/10.1210/er.2015-1106>)
- 3 Gogakos AI, Duncan Bassett JH & Williams GR. Thyroid and bone. *Archives of Biochemistry and Biophysics* 2010 **503** 129–136. (<https://doi.org/10.1016/j.abb.2010.06.021>)
- 4 Rastogi MV & LaFranchi SH. Congenital hypothyroidism. *Orphanet Journal of Rare Diseases* 2010 **5** 17. (<https://doi.org/10.1186/1750-1172-5-17>)
- 5 Hüffmeier U, Tietze HU & Rauch A. Severe skeletal dysplasia caused by undiagnosed hypothyroidism. *European Journal of Medical Genetics* 2007 **50** 209–215. (<https://doi.org/10.1016/j.ejmg.2007.02.002>)
- 6 Macmahon P, Blair M & Kovar I. Hypothyroidism and unusual rickets in a very preterm infant. *Postgraduate Medical Journal* 1989 **65** 312–315. (<https://doi.org/10.1136/pgmj.65.763.312>)

---

**Received in final form** 8 July 2022

**Accepted** 13 July 2022