

Post-cataract surgery cluster endophthalmitis due to multidrug-resistant *Pseudomonas aeruginosa*: A retrospective cohort study of six clusters

Swapnil M Parchand, Deepanshu Agrawal¹, Samrat Chatterjee², Anil Gangwe, Mihir Mishra³, Deepshikha Agrawal²

Purpose: To analyze clinical presentations, antibiotic susceptibility, and visual outcomes in six clusters of post cataract surgery endophthalmitis caused due to multidrug-resistant *Pseudomonas aeruginosa* (MDR-PA). This was a hospital-based retrospective cohort study. **Methods:** Our study comprised sixty-two patients from six nonconsecutive clusters of post cataract surgery endophthalmitis caused by MDR-PA referred to our tertiary eye care institute. Demographic details, best-corrected visual acuity (BCVA), clinical features, microbiological findings, and patient management were reviewed. **Results:** The interval between onset of symptoms and presentation ranged from 1 to 7 (mean: 4.61 and median: 5) days. The presenting BCVA was no light perception in 17 (27.4%) eyes, light perception in 35 (56.4%) eyes, and hand movement or better in 10 (16.1%) eyes. All patients had hypopyon and vitreous exudates. Corneal infiltrates were noted in 40 (64.5%) eyes. Panophthalmitis was diagnosed in 20 (32.2%) eyes. The surgical intervention included intraocular antibiotics (IOAB) in 8 (12.9%) eyes, pars plana vitrectomy with IOAB in 26 (41.9%) eyes, and evisceration in 23 (37.09%) eyes. At 6 weeks, BCVA of 20/200 or better was achieved in 9 (14.5%) eyes. *Pseudomonas aeruginosa* was least resistant to colistin (8.3%), piperacillin (31.8%), and imipenem (36.1%). Ceftriaxone and ceftazidime resistance was seen in 80.5% and 70% isolates, respectively. **Conclusion:** Cluster endophthalmitis due to MDR-PA has poor visual outcomes with high rates of evisceration. In the setting of cluster endophthalmitis where MDR-PA is the most common etiology, piperacillin or imipenem can be the first drug of choice for empirical intravitreal injection for gram-negative coverage while awaiting the drug susceptibility report.

Key words: Antibiotics resistance, cataract surgery, cluster endophthalmitis, endophthalmitis, multidrug-resistant pseudomonas aeruginosa, pseudomonas aeruginosa

Cluster endophthalmitis is a devastating complication for patients, surgeons, and clinics. Apart from generating bad publicity for surgeons and clinics, it involves many legal complications that include cancellation of license of the operating surgeon and the clinic. Although optimum precautions are taken while performing cataract surgery, episodes of cluster endophthalmitis are reported in various parts of India.^[1-3] *Pseudomonas aeruginosa* (PA) is the most common gram-negative organism associated with post cataract surgery cluster endophthalmitis.^[4] Since they are not part of the normal conjunctival flora, outbreaks of PA endophthalmitis are most likely to have an exogenous source of infection.^[5] These outbreaks are mainly associated with intrinsic contamination of the ophthalmic solution including the balanced salt solution, the intraocular lens fluid, the hyaluronic acid, trypan blue, contamination of internal fluid pathways of the phacoemulsifier, a contaminated phaco probe, etc.^[6-12]

Cluster endophthalmitis often goes unreported in the medical literature. However, isolated reports of PA cluster

endophthalmitis following cataract surgery have been described in the literature.^[1,3,6,7,9-12] There have been variations in clinical presentations, interventions, outcomes, and antibiotic susceptibility patterns in these reports. Lastly, there have been concerns about the growing resistance of PA to available antibiotics.^[13] Since our institute is the referral institute of Central India, it caters to populations from five adjoining states. Hence, we had the opportunity to manage some instances of cluster endophthalmitis from these regions in the past two decades.^[2] The purpose of this study was to evaluate the clinical presentations, types of surgical interventions, treatment outcomes, and antibiotic susceptibility patterns in six nonconsecutive clusters of post cataract surgery endophthalmitis caused by multidrug-resistant *Pseudomonas aeruginosa* (MDR-PA) over a period of 12 years.

This is an open access journal, and articles are distributed under the terms of the Creative Commons Attribution-NonCommercial-ShareAlike 4.0 License, which allows others to remix, tweak, and build upon the work non-commercially, as long as appropriate credit is given and the new creations are licensed under the identical terms.

For reprints contact: reprints@medknow.com

Cite this article as: Parchand SM, Agrawal D, Chatterjee S, Gangwe A, Mishra M, Agrawal D. Post-cataract surgery cluster endophthalmitis due to multidrug-resistant *Pseudomonas aeruginosa*: A retrospective cohort study of six clusters. Indian J Ophthalmol 2020;68:1424-31.

Access this article online

Website:

www.ijo.in

DOI:

10.4103/ijo.IJO_1612_19

Quick Response Code:



Consultant, Vitreoretina and Uvea Services, ¹DNB Trainee, ²Consultant, Cornea and Anterior Segment Services, ³Consultant, Orbit, Oculoplasty and Ocular Oncology Services, MGM Eye Institute, Raipur, Chhattisgarh, India

Correspondence to: Dr. Swapnil Madhukar Parchand, Vitreoretina and Uvea Services, MGM Eye Institute, Raipur, Chhattisgarh - 493 111, India. E-mail: swapnilp5656@yahoo.co.in

Received: 02-Sep-2019

Revision: 12-Dec-2019

Accepted: 24-Feb-2020

Published: 25-Jun-2020

Methods

The Institutional Ethics Committee approved the study (IEC/MGMEI/1/2018/34) and it was conducted in full accord with the tenets of the Declaration of Helsinki. Since the study involved a retrospective chart review of the concerned patients, the Ethics Committee granted an exemption from obtaining informed consent from patients. The medical records of patients with cluster endophthalmitis referred to our tertiary eye care institute from December 2006 to November 2018 were reviewed. Cluster endophthalmitis was defined as a higher occurrence of endophthalmitis as compared to the local incidence pattern or the occurrence of two or more cases of endophthalmitis on a particular day in a single operating room in one center.^[14] In this study, we included only those clusters that were caused by MDR-PA. MDR-PA was defined as nonsusceptibility (i.e., resistant or intermediate sensitivity) to at least one agent in at least 3 antimicrobial classes of the following 6 classes: 1. ampicillin/sulbactam, 2. cephalosporins (cefepime, ceftazidime), 3. β -lactam/ β -lactamase inhibitor combination (piperacillin, piperacillin/tazobactam), 4. carbapenems (imipenem, meropenem, doripenem), 5. fluoroquinolones (ciprofloxacin or levofloxacin), and 6. aminoglycosides (gentamicin, tobramycin, or amikacin).^[15]

Data collection included assessment of the demographic profile of the patients, type of cataract surgery, evaluation of signs and symptoms, time interval between cataract surgery and onset of symptoms, time interval between onset of symptoms and presentation at our institute, any intervention for endophthalmitis done elsewhere before presentation to us, presenting and final best-corrected visual acuity (BCVA) of the affected eye, microbiological records including analysis of culture reports and antibiotic susceptibility, treatment received, and visual and anatomical outcomes at the final follow-up. Undiluted vitreous samples were obtained and sent for microbiological smear and culture assessment. Smears were examined for Gram's, Giemsa, and 10% potassium hydroxide mount. The remaining sample was inoculated on blood agar (5% sheep blood), chocolate agar, Sabouraud dextrose agar, and brain heart infusion broth and incubated at the appropriate temperature and atmospheric conditions. Antibiotic susceptibility to amikacin, cefazolin, ceftazidime, ceftriaxone, chloramphenicol, ciprofloxacin, colistin, gatifloxacin, gentamicin, imipenem, moxifloxacin, ofloxacin, piperacillin, tobramycin, and vancomycin was tested using the Kirby-Bauer disk diffusion method. Each isolate was labeled either resistant (resistant and intermediate) or susceptible to a particular antibiotic based on the zone of inhibition around the antibiotic-impregnated filter paper disc. The treatment outcome at 6 weeks was defined as favorable or unfavorable. A favorable outcome was defined as a) absence of infection (no corneal infiltrates, absence of cells in the anterior chamber, and a clear vitreous cavity) b) intraocular pressure of >10 mmHg, and c) BCVA $\geq 20/200$. An unfavorable outcome was considered if any one of the following was present: a) an intraocular pressure of <10 mmHg with BCVA $\leq 20/200$, b) presence of phthisis bulbi, or c) an eviscerated eye.

Statistical analysis

Data was entered in a Microsoft Excel spreadsheet and analyzed using SPSS software for Windows (version 16.0, SPSS Inc, Chicago, IL). Quantitative and qualitative variables

were expressed as mean \pm standard deviation and percentages, respectively. The Pearson Chi-square test was used to find out the associations and to carry out univariate analysis. Multiple logistic regression was used for multivariate analysis. A two-tailed *P* value of <0.05 was considered statistically significant.

Results

During the study period, 12 episodes of cluster endophthalmitis were identified. Out of 12 clusters, patients in 6 clusters (62 patients) developed endophthalmitis due to MDR-PA; cluster 1 (December 2006) had 4 patients, cluster 2 (September 2011) 2 patients, cluster 3 (October 2011) 4 patients, cluster 4 (March 2012) 9 patients, cluster 5 (December 2012) 13 patients, and cluster 6 (March 2018) 30 patients. All the patients were operated for cataract elsewhere and referred to our institute for the management of acute postoperative endophthalmitis. The mean age was 62.53 ± 8.91 years (range 30–80 years). There were 25 (40.3%) male and 37 (59.7%) female patients. Five (8.06%) patients had a history of diabetes and 4 (6.4%) patients had a history of hypertension. Small incision cataract surgery (SICS) was performed in 39 (62.9%) eyes, extracapsular cataract surgery (ECCE) in 20 (32.2%) eyes, and phacoemulsification was performed in 3 (4.8%) eyes. All eyes had posterior chamber intraocular lens (PCIOL) implantation during primary surgery [Table 1]. All patients exhibited symptoms related to endophthalmitis, i.e., pain, redness, watering, and decrease in vision on the first postoperative day. The interval between onset of symptoms and presentation at our institute ranged from 1 to 7 (mean: 4.61 and median: 5) days. Twenty-nine (46.7%) eyes of cluster 4 and 6 had surgical interventions for endophthalmitis elsewhere before being referred to our institute. Out of 29 eyes, intraocular antibiotics (IOAB) were administered to 22 (75.9%) eyes and pars plana vitrectomy (PPV) with IOAB was performed in 7 (24.1%) eyes.

The presenting BCVA was no light perception in 17 (27.4%) eyes, light perception in 35 (56.4%) eyes, hand movement in 7 (11.2%) eyes, counting finger close to face to $<20/200$ in 2 (3.2%) eyes, and visual acuity of 20/200 or better in 1 (1.6%) eye. Twelve (19.3%) eyes had restricted extraocular movements. At presentation, corneal infiltrates were noted in 40 (64.5%) eyes, cataract wound gaping in 20 (32.2%) eyes, and wound infiltration in 4 (6.4%) eyes [Fig. 1a and b]. All patients had hypopyon and fibrinous reactions in the anterior chamber [Fig. 1d]. The intraocular lenses were partially extruded in 3 (4.8%) eyes (cluster 5: 2 eyes and cluster 6: 1 eye) [Fig. 1c]. Fundus examination revealed grade-4 media haze in 60 (96.8%) eyes and grade-2 media haze in 2 (3.2%) eyes. Ocular ultrasonography revealed vitreous exudates in all eyes. Retinal detachment was noted in 5 (8.06%) eyes belonging to cluster 6. Choroidal thickness >1.5 mm (maximum threshold for normality is 1.5 mm) was present in 46 (74.2%) eyes and "T" sign was noted in 22 (35.4%) eyes^[16,17] [Table 2]. Panophthalmitis was diagnosed in 20 (32.2%) eyes.

At presentation, patients from all the clusters were started on an intensive topical antibiotic (ciprofloxacin 0.3%, half-hourly), corticosteroids (prednisolone acetate 1%, frequency as deemed appropriate by the treating ophthalmologist), topical cycloplegic (atropine sulphate 1%, 3 times a day),

and intravenous ciprofloxacin (6 mg/kg, 12 hourly). The patients also received oral steroids (prednisolone 1 mg/kg/day as deemed appropriate by the treating ophthalmologist). Topical and systemic antibiotics were further modified according to the drug susceptibility reports of the vitreous sample [Table 3]. Intravenously, cluster 1 received ciprofloxacin 6 mg/kg 12 hourly, cluster 2 tobramycin 1 mg/kg 8 hourly, cluster 3 colistin 1.25 mg/kg 12 hourly, cluster 4 piperacillin 3 g 6 hourly, cluster 5 amikacin 5 mg/kg 8 hourly, and cluster 6 received ceftazidime 1 g 8 hourly. All systemic antibiotics were given for a minimum period of 1 week. Pars plana vitrectomy (PPV) was performed in those eyes in which corneal clarity permitted good visibility for vitrectomy. IOAB were administered in eyes in which vitrectomy was not possible and evisceration was done in eyes with panophthalmitis. Surgical interventions at our institute included IOAB in 8 (12.9%) eyes, PPV along with IOAB in 26 (41.9%) eyes, primary evisceration in 20 (32.2%) eyes, and PPV followed by evisceration in 3 (4.8%) eyes [Table 2]. Five (8%) patients from cluster 6 refused to undergo surgical intervention advised for endophthalmitis, and consented for only medical management. Vancomycin (1 mg/0.1 ml) and ceftazidime (2.25 mg/0.1 ml) were the initial intravitreal antibiotics that were injected either in isolation or in combination with PPV. Antibiotic selected for repeat intravitreal injections depended on the drug susceptibility reports of the vitreous biopsy.

Mean follow-up period was 8.13 ± 2.61 (range 6 to 15) weeks. At 6 weeks, 9 (14.5%) eyes had visual acuity of 20/200 or better, 4 (6.5%) eyes had <20/200 to counting fingers, 15 (24.1%) eyes had light perception, and 34 (54.8%) eyes had no light perception. Thus, a favorable outcome was noted in 9 (14.5%) eyes [Fig. 2], whereas an unfavorable outcome was noted in 53 (85.5%) eyes. Out of 53 eyes, phthisis bulbi was noted in 19 (30.6%) eyes, evisceration was done in 23 (37.09%) eyes, and the globe could be salvaged

but visual acuity was < 20/200 in 11 (17.7%) eyes. Based on univariate analysis, risk factors for unfavorable outcome were time interval between onset and presentation of more than 3 days ($P = 0.006$), presenting visual acuity of hand movement or less ($P < 0.0001$), corneal infiltrates ($P < 0.0001$), "T" sign ($P = 0.016$), and choroidal thickness of more than 1.5 mm on ocular ultrasonography ($P < 0.0001$) [Table 4]. Pars plana vitrectomy ($P < 0.001$) was associated with a favorable outcome but there is a likelihood of selection bias as only cases with clear corneas underwent PPV. Multivariate analysis failed to identify any independent risk factor(s).

Antibiotic susceptibility (vitreous samples)

Antibiotic susceptibility was done for antibiotics commonly used in ophthalmic practice. Susceptibility test to imipenem, piperacillin, and colistin was not done in our Institute before 2010. Table 3 shows the resistance pattern of PA from various clusters. PA from each cluster showed resistance to at least three classes of antibiotics [Fig. 3]. Overall PA was least resistant to colistin (8.3%), piperacillin (31.8%), and imipenem (36.1%). The highest resistance noted was to moxifloxacin (100%) followed by gentamicin (97.1%), gatifloxacin (92.5%), tobramycin (92.5%), ofloxacin (91.4%), and ciprofloxacin (89.4%). Ceftriaxone and ceftazidime resistance was seen in 80.5% and 70% isolates, respectively [Table 3].

Discussion

The present study reports one of the largest series of cluster endophthalmitis after cataract surgery caused by MDR-PA. The PA isolates from all the clusters were resistant to various antibiotics that are commonly used as first-line therapy in treating acute postoperative endophthalmitis. The treatment of all these patients required antibiotics that are not routinely used. Due to the severity of clinical symptoms, virulence of the organism, delay in presentation, time taken for obtaining

Table 1: Demographic and operative details prior to presentation of different clusters

Cluster number (month, year)	Number of patients	Mean age in years (range)	Sex	Systemic status (Comorbidities)	Type of cataract surgery n (%)	Interval between cataract surgery and onset of symptoms (days)	Interval between onset of symptoms and presentation (days)	Previous intervention
1 (December, 2006)	4	60.25 (45-76)	Male: 1 Female: 3	HTN-1	ECCE + PCIOL - 4 (100%)	1	3	None
2 (September, 2011)	2	61.5 (55-68)	Male: 1 Female: 1	None	Phaco + PCIOL - 2 (100%)	1	1	None
3 (October, 2011)	4	59.5 (50-70)	Male: 2 Female: 2	None	ECCE + PCIOL - 4 (100%)	1	7	None
4 (March, 2012)	9	58.4 (30-75)	Male: 3 Female: 6	DM-4 HTN-1	SICS + PCIOL - 9 (100%)	1	7 patients presented of day 3 2 patient presented on day 4	IOAB: 5
5 (December, 2012)	13	61.5 (50-75)	Male: 6 Female: 7	None	ECCE + PCIOL - 12 (92.3%) Phaco + PCIOL - 1 (7.7%)	1	5	None
6 (March, 2018)	30	64.9 (50-75)	Male: 12 Female: 18	DM-1 HTN-2	SICS + PCIOL - 30 (100%)	1	5	IOAB: 17 PPV + IOAB: 7

DM: Diabetes mellitus; HTN: Hypertension; ECCE: Extracapsular cataract extraction; Phaco: Phacoemulsification; SICS: Small incision cataract surgery; PCIOL: Posterior chamber intraocular lens; IOAB: Intraocular antibiotics; PPV: Pars plana vitrectomy

Table 2: Clinical features, surgical treatment, and outcome in various clusters

Cluster number	Corneal infiltrates	Cataract wound status	Fundus view (Grade)	B-scan (choroidal thickness/T sign)	Intervention	Visual acuity		Outcome	
						Initial	Final	Favorable	Unfavorable [#]
1 (n=4)	2 (50%)	Gaping: 0 Infiltration: 2 (50%)	Grade 4-4 (100%)	0	IOAB - 0 PPV + IOAB - 3 (75%) PPV + IOAB followed by Evisceration - 1 (25%)	NO PL PL+ HMCf CF - <20/200 ≥20/200	0 NO PL 3 PL+ 1 HM - CF 0 CF - <20/200 0 ≥20/200	1 2 0 0 1	1 II III I 2
2 (n=2)	0	Gaping: 0 Infiltration: 0	Grade 4-2 (100%)	0	IOAB - 0 PPV + IOAB - 2 (100%) Evisceration - 0	NO PL PL+ HMCf CF - <20/200 ≥20/200	0 NO PL 1 PL+ 1 HM - CF 0 CF - <20/200 0 ≥20/200	1 0 0 0 1	1 II III I 0
3 (n=4)	1 (25%)	Gaping: 0 Infiltration: 0	Grade 4-4 (100%)	0	IOAB - 0 PPV + IOAB - 3 (75%) Evisceration - 1 (25%)	NO PL PL+ HMCf CF - <20/200 ≥20/200	1 NO PL 1 PL+ 2 HM - CF 0 CF - <20/200 0 ≥20/200	1 1 1 0 1	1 II III I 2
4 (n=9)	4 (44.4%)	Gaping: 8 (88.9%) Infiltration: 0	Grade 4-9 (100%)	CT - 7 (77.8%) T sign- 1 (11.1%)	IOAB - 0 PPV + IOAB - 9 (100%) Evisceration - 0	NO PL PL+ HMCf CF - <20/200 ≥20/200	0 NO PL 8 PL+ 0 HM - CF 1 CF - <20/200 0 ≥20/200	3 2 1 0 3	I II III I 3
5 (n=13)	13 (100%)	Gaping: 2 (15.3%) Infiltration: 0 IOL partially extruded: 2 (15.3%)	Grade 4-13 (100%)	CT - 13 (100%) T sign - 12 (92.3%)	IOAB - 0 PPV + IOAB - 1 (7.6%) Evisceration 10 (76.9%) PPV + IOAB followed by Evisceration - 2 (15.4%) No intervention - 1 (7.6%)	NO PL PL+ HMCf CF - <20/200 ≥20/200	8 NO PL 4 PL+ 1 HM - CF 0 CF - <20/200 0 ≥20/200	12 0 1 0 3	I II III I 0
6 (n=30)	20 (66.6%)	Gaping: 10 (33.3%) Infiltration: 2 (6.6%) IOL partially extruded: 1 (3.3%)	Grade 2-2 (6.6%) Grade 4-28 (93.3%)	CT - 26 (86.6%) T sign- 9 (30%)	IOAB - 8 (26.6%) PPV + IOAB - 8 (26.6%) Evisceration - 9 (30%) No intervention - 5 (16.6%)	NO PL PL+ HMCf CF - <20/200 ≥20/200	8 NO PL 18 PL+ 2 HM - CF 1 CF - <20/200 1 ≥20/200	17 9 1 0 3	I II III I 3

CT: Choroidal thickness; IOAB: Intraocular antibiotics; PPV: Pars plana vitrectomy; PL: Perception of light; HM: Hand movements close to face; CF: Counting fingers close to face. [#]Unfavorable outcome: I - intraocular pressure of <10 mm Hg with visual acuity ≤20/200; II - Phthisis bulbi and III - Eye eviscerated

Table 3: Antibiotics resistance report

Cluster	No. of patients	No. of samples tested	AK	GEN	TOB	CIP	GAT	OF	MO	C	CAZ	CTR	IPM	MRP	PI	CL
1 (Dec 2006)	4	4	2 (50)	3 (75)	4 (100)	0	1 (25)	1 (25)	NT	4 (100)	3 (75)	NT	NT	NT	NT	NT
2 (Sep 2011)	2	2	2 (100)	NT	0	NT	NT	NT	2 (100)	2 (100)	2 (100)	2 (100)	0	NT	NT	2 (100)
3 (Oct 2011)	4	3	3 (100)	NT	2 (66.6)	3 (100)	3 (100)	NT	NT	3 (100)	3 (100)	3 (100)	2 (66.6)	NT	NT	0
4 (Mar 2012)	9	9	9 (100)	9 (100)	9 (100)	9 (100)	9 (100)	9 (100)	9 (100)	9 (100)	9 (100)	9 (100)	0	NT	NT	0
5 (Dec 2012)	13	11	0	11 (100)	11 (100)	11 (100)	11 (100)	11 (100)	11 (100)	1 (9.09)	11 (100)	11 (100)	0	NT	5 (45.4)	0
6 (Mar 2018)	30	11	11 (100)	11 (100)	11 (100)	11 (100)	11 (100)	11 (100)	11 (100)	11 (100)	0	4 (36.3)	11 (100)	9 (81.8)	2 (18.1)	1 (9.09)
Overall			27 (67.5)	34 (97.1)	37 (92.5)	34 (89.4)	37 (92.5)	32 (91.4)	33 (100)	30 (75)	28 (70)	29 (80.5)	13 (36.1)	9 (81.8)	7 (31.8)	3 (8.3)

Resistance
 AK=Amikacin, GEN=Gentamicin, TOB=Tobramycin, CIP=Ciprofloxacin, GAT=Gatifloxacin, OF=Ofloxacin, MO=Moxifloxacin, C=Chloramphenicol, CAZ=Ceftazidime, CTR=Ceftriaxone, IPM=Imipenem, MRP=Meropenem, PI=Piperacillin, COL=Colistin, NT=Not tested. Numbers in bracket indicates percentage

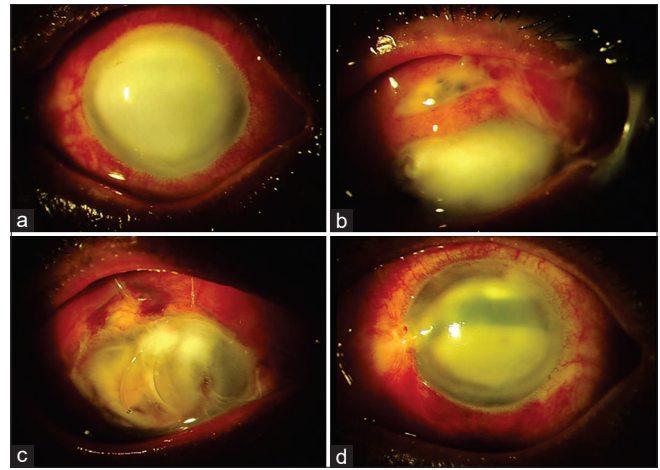


Figure 1: (a-d) Slit-lamp images of various patients from cluster 6 at presentation showing (a) total corneal infiltrates; (b) wound gaping, wound infiltrates, and uveal tissue prolapse with corneal infiltrates; (c) partially extruded optic and haptic of posterior chamber intraocular lens with total corneal melt and uveal tissue prolapse; (d) superior corneal infiltrates and half chamber hypopyon

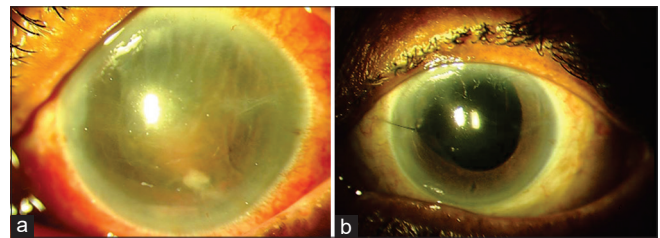


Figure 2: (a and b) Anterior segment image of a patient of cluster 6 (a) at presentation showing corneal edema, Descemet's membrane folds, fibrinous reaction, and hypopyon in anterior chamber (b) at 3 months following pars plana vitrectomy and intraocular antibiotics showing clear cornea, quiet anterior chamber, and PCIOL in place

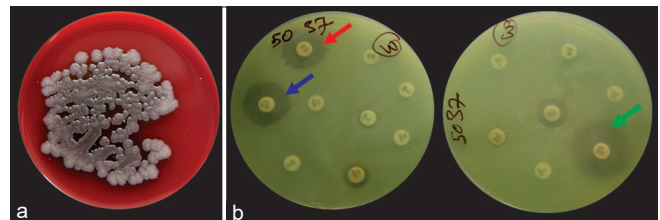


Figure 3: (a and b) (a) Blood agar plate showing confluent, moist, greyish colonies of *Pseudomonas aeruginosa*. (b) Nonnutrient agar plate with various antibiotic discs (Kirby-Bauer disk diffusion method) demonstrating antibiotic susceptibility of piperacillin (red arrow), ceftriaxone (blue arrow), and ceftazidime (green arrow)

antibiotic susceptibility results, and instituting treatment with appropriate antibiotics, the outcome in a majority of the patients was poor.

In our study, the overall outcome was poor (85.5%). About 37% of patients required evisceration while 30.6% of the eyes progressed to phthisis bulbi. Only 14.5% of eyes had BCVA better than 20/200. In some clusters like cluster 5, 12 of 13 eyes required evisceration due to the severity of clinical presentation. Other studies have reported similar or slightly higher rates of evisceration when cluster endophthalmitis was

Table 4: Odds ratio of various variables on outcome by univariate analysis

Factors	Favorable Outcome	Unfavorable Outcome	Odds ratio	95% CI for odds ratio	P
Age >60 years	5	25	1.400	0.338-5.798	0.642
Male	3	22	0.705	0.159-3.125	0.644
Presence of Diabetes	1	4	1.531	0.151-15.508	0.717
Time interval between onset and presentation of >3 days	4	45	0.142	0.031-0.647	0.006
Presenting Visual acuity less than hand movements	3	49	0.041	0.007-0.228	<0.0001
Presence of corneal infiltrates	1	39	0.045	0.005-0.392	<0.0001
Cataract wound gaping	3	17	1.059	0.236-4.751	0.941
Presence of "T" sign on Ocular ultrasonography	0	22	1.710	1.363-2.145	0.016
Presence of choroidal thickness	2	44	0.058	0.010-0.329	<0.0001
Pars plana vitrectomy	9	20	1.450	1.136-1.851	<0.001
Previous Intervention	5	24	1.510	0.364-6.259	0.568

caused by PA.^[3,18-20] In a majority of eyes that were spared of evisceration/enucleation, the visual acuity remained <20/200. This is primarily due to virulence of the bacteria, which is multifactorial.^[21,22] PA produce several toxins and proteases causing rapid host cell destruction, thereby secondarily increasing the invasiveness of the organism. They also possess glycocalyx that protect the PA against antibiotic penetration. Lastly, they produce beta-lactamase, which renders many commonly used antibiotics ineffective against the organism.^[21-23] Outbreaks of PA endophthalmitis have been linked to contaminated ophthalmic solutions such as trypan blue, lens solution, and phacoemulsifier internal fluid reflecting its tendency to survive over a long period in aqueous environments.^[6-12]

The selection of antibiotics to treat PA infection is challenging for the treating ophthalmologist due to the increasing antibiotic-resistant isolates. In one of the earliest published reports, all the isolates of PA from contact lens associated corneal ulcers were resistant to ampicillin, cefamandole, cephalothin, neomycin, and tetracycline and were susceptible only to tobramycin.^[23] There were a number of isolates resistant to gentamicin, amikacin, and triple sulfa. In the 90s, there were reports of resistance to fluoroquinolones, particularly ciprofloxacin that had replaced aminoglycosides as first-line treatment against PA infections.^[24-26] Due to its overuse, the percentage of PA isolates showing resistance to ciprofloxacin have increased from less than 1% in 1991-94 to 4% in 1995-98 and to 29% in 2002-03.^[19,25,26] In the last decade, multidrug-resistant isolates were commonly reported in ocular infections including the newer class of antibiotics like piperacillin/tazobactam.^[27,28] In our study, the highest rate of resistance was noted with aminoglycosides and fluoroquinolones drugs. *Pseudomonas aeruginosa* isolated from cluster 1 were sensitive to fluoroquinolones; remaining clusters were resistant to this class of drugs. This highlights the growing pattern of resistance to fluoroquinolones in our region. A varying degree of susceptibility with cephalosporins has been documented. While PA isolates from the initial 5 clusters were resistant to ceftriaxone and ceftazidime, isolates from the most recent cluster were sensitive to them. Endophthalmitis vitrectomy study reported 11% gram-negative bacteria resistant to ceftazidime.^[29] While a study from USA reported 100% sensitivity to ceftazidime, Indian studies report resistance as high as 63%.^[13,27,30-32]

Considering all 6 clusters, we found the lowest resistance rate with colistin (8.3%) and imipenem (36.1%). Piperacillin was tested in only 2 clusters, where 31.8% tested isolates were resistant to it. Similar to our observation, various studies still report colistin and carbapenems as the most effective drugs against PA with the least resistance rate.^[13,27,32,33] Imipenem is a beta-lactam antibiotic belonging to the subgroup of carbapenems.^[34] It has a broad spectrum of activity against aerobic and anaerobic gram-positive as well as gram-negative bacteria. When administered intravitreally during the early course of endophthalmitis, it may limit intraocular inflammation and retinal tissue damage. The current standard empirical intravitreal antibiotics used for the treatment of endophthalmitis include vancomycin (1 mg/0.1 ml) for the gram-positive organism and ceftazidime (2.25 mg/0.1 ml) or amikacin (0.4 mg/0.1 ml) for the gram-negative organism. As mentioned earlier, ceftazidime resistance is an emerging problem in the management of gram-negative bacterial endophthalmitis.^[13,32] In the present study, we found 70% and 67.5% PA isolates resistant to ceftazidime and amikacin, respectively. In our study, the time interval between cataract surgery and the onset of symptoms was very short. At presentation, in most of the clusters, the infection was so fulminant that vitreous surgery could be performed in only a few cases. In these eyes, vitrectomy was not possible as the presence of corneal infiltrates impeded proper visualization. The time duration from sample collection to the antibiotic susceptibility report at the very least is 72 hours. Hence, while we wait for the antibiotic susceptibility report, managing cluster endophthalmitis (MDR-PA being the most common etiology) using ceftazidime or amikacin as intravitreal antibiotics empirically could be detrimental, considering the rapid progression of infection. Therefore, when faced with cluster endophthalmitis, we propose that ceftazidime can be replaced with either piperacillin or imipenem as the first drug of choice for empirical intravitreal injection for gram-negative coverage.

Dave *et al.* reported presenting vision of <20/200 and the presence of corneal infiltrates as poor prognostic factors for ceftazidime resistant gram-negative endophthalmitis.^[32] Factors responsible for poor anatomical and functional outcomes in our study were a time interval between onset and presentation of more than 3 days, presenting visual acuity of hand movements or worse, presence of corneal infiltrates, presence of "T"

sign, and choroidal thickness more than 1.5 mm on ocular ultrasonography at presentation. We could not identify any single independent risk factor on multivariate analysis. As it has been reported by many studies, *Pseudomonas aeruginosa* infection itself is an important factor for poor outcome.^[3,19,20] Due to delayed referral and the virulent nature of the organism, presenting visual acuity of hand movements or less was noted in 95.1% of the eyes, involvement of the cornea was present in 64.5% of the eyes, and choroidal thickness of more than 1.5 mm in 74.2% of the eyes.

The magnitude of cataract-related blindness is expected to increase by millions in India.^[35] To address this issue, high volume cataract surgical camps are regularly held. The occurrence of cluster endophthalmitis with multidrug-resistant microorganisms may cause a serious setback to this program from the adverse outcome of such infections and the negative publicity that such incidents generate. Various published reports of cluster endophthalmitis had identified phaco-probe and internal tubings of phaco-machine, solutions of hydrophilic acrylic intraocular lenses, trypan blue, reconstituted cefuroxime, water for scrubbing, contaminated OT trolleys, and local anesthetic drops as the source of infection.^[6-12] Therefore, the operating team in India should follow stringent guidelines related to patient selection and pre, intra, and postoperative sterilization protocols laid down by the National Program for Control of Blindness and Visual Impairment, India, the nodal governmental department.^[36] We would suggest that when high volume surgeries are planned, it is important not to compromise on the quality of consumables and procure only certified drugs and intraocular lenses. Second, if any surgeon encounters such an event of endophthalmitis, rather than administering an intravitreal antibiotic injection and keeping the patient under observation, urgent referral to an experienced vitreoretinal surgeon should be done. In the present study, we observed a delayed referral to our hospital in most of the clusters.

Our study has some limitations inherent to the study design. Most of the patients had short follow-up duration. We were not part of any investigation process for the source and mode of infection. The information collected from such investigations would have helped in preventing future outbreaks. We used only the disc diffusion method for assessing antibiotic susceptibility and thus were unable to ascertain the minimum inhibitory concentration values of various antibiotics. Lastly, it was not possible to follow a strict protocol for surgical intervention due to the varying severity of presentation in different clusters.

Conclusion

In conclusion, cluster endophthalmitis by multidrug-resistant *Pseudomonas aeruginosa* (MDR-PA) has very poor visual and anatomical outcomes. The choice of antibiotic therapy for cluster presentation needs to be reviewed. Given increasing resistance to aminoglycosides and cephalosporins by gram-negative bacteria, an alternative class of drugs like piperacillin, colistin, and carbapenems may be considered.

Financial support and sponsorship

Nil.

Conflicts of interest

There are no conflicts of interest.

References

- Ramappa M, Majji AB, Murthy SI, Balne PK, Nalamada S, Garudadri C, *et al.* An outbreak of acute post-cataract surgery *Pseudomonas* sp. Endophthalmitis caused by contaminated hydrophilic intraocular lens solution. *Ophthalmology* 2012;119:564-70.
- Malhotra S, Mandal P, Patanker G, Agrawal D. Clinical profile and visual outcome in cluster endophthalmitis following cataract surgery in Central India. *Indian J Ophthalmol* 2008;56:157-8.
- Pinna A, Usai D, Sechi LA, Zanetti S, Jesudasan NC, Thomas PA, *et al.* An outbreak of post-cataract surgery endophthalmitis caused by *Pseudomonas aeruginosa*. *Ophthalmology* 2009;116:2321-6.
- Pathengay A, Flynn H Jr, Isom R, Miller D. Endophthalmitis outbreaks following cataract surgery: Causative organisms, etiologies and visual acuity outcomes. *J Cataract Refract Surg* 2012;38:1278-82.
- Kresloff MS, Castellarin AA, Zarbin MA. Endophthalmitis. *Surv Ophthalmol* 1998;43:193-224.
- Swaddiwudhipong W, Tangkitchot T, Silarug N. An outbreak of *Pseudomonas aeruginosa* postoperative endophthalmitis caused by contaminated intraocular irrigating solution. *Trans R Soc Trop Med Hyg* 1995;89:288.
- Centers for Disease Control and Prevention (CDC). Outbreaks of postoperative bacterial endophthalmitis caused by intrinsically contaminated ophthalmic solutions--Thailand, 1992, and Canada, 1993. *MMWR Morb Mortal Wkly Rep* 1996;45:491-4.
- Arsan AK, Adışen A, Duman S, Aslan B, Koçak I. Acute endophthalmitis outbreak after cataract surgery. *J Cataract Refract Surg* 1996;22:1116-20.
- Zaluski S, Clayman HM, Karsenti G, Bourzeix S, Tournemire A, Faliu B, *et al.* *Pseudomonas aeruginosa* endophthalmitis caused by contamination of the internal fluid pathways of a phacoemulsifier. *J Cataract Refract Surg* 1999;25:540-5.
- Cruciani M, Malena M, Amalfitano G, Monti P, Bonomi L. Molecular epidemiology in a cluster of cases of postoperative *Pseudomonas aeruginosa* endophthalmitis. *Clin Infect Dis* 1998;26:330-3.
- Hoffmann KK, Weber DJ, Gergen MF, Rutala WA, Tate G. *Pseudomonas aeruginosa*-related postoperative endophthalmitis linked to a contaminated phacoemulsifier. *Arch Ophthalmol* 2002;120:90-3.
- Kenchappa P, Sangwan VS, Ahmed N, Rao KR, Pathengay A, Mathai A, *et al.* High-resolution genotyping of *Pseudomonas aeruginosa* strains linked to acute post cataract surgery endophthalmitis outbreaks in India. *Ann Clin Microbiol Antimicrob* 2005;4:19.
- Jindal A, Pathengay A, Khera M, Jalali S, Mathai A, Pappuru RR, *et al.* Combined ceftazidime and amikacin resistance among Gram-negative isolates in acute-onset postoperative endophthalmitis: Prevalence, antimicrobial susceptibilities, and visual acuity outcome. *J Ophthalmic Inflamm Infect* 2013;3:62.
- Anderson OA, Lee V, Shafi S, Keegan D, Vafidis G. A model for the management of an atypical endophthalmitis outbreak. *Eye (Lond)* 2005;19:972-80.
- Sievert DM, Ricks P, Edwards JR, Schneider A, Patel J, Srinivasan A, *et al.* National Healthcare Safety Network (NHSN) Team and Participating NHSN Facilities. Antimicrobial-resistant pathogens associated with healthcare-associated infections: Summary of data reported to the National Healthcare Safety Network at the Centers for Disease Control and Prevention, 2009-2010. *Infect Control Hosp Epidemiol* 2013;34:1-14.
- Cennamo G, Rosa N, Iaccarino G, La Rana A, Pasquariello A. Macula study with standardized echography. *Acta Ophthalmol Scand* 1996;74:178-81.

17. Atta HR, Byrne SF: The findings of standardized echography for choroidal folds. *Arch Ophthalmol* 1988;106:1234-41.
18. Eifrig CW, Scott IU, Flynn HW, Miller D. Endophthalmitis caused by *Pseudomonas aeruginosa*. *Ophthalmology* 2003;110:1714-7.
19. Irvine WD, Flynn HW Jr, Miller D, Pflugfelder SC. Endophthalmitis caused by gram-negative organisms. *Arch Ophthalmol* 1992;110:1450-4.
20. Guerra RL, Freitas Bde P, Parcero CM, Maia Ode O Jr, Marback RL. An outbreak of forty five cases of *Pseudomonas aeruginosa* acute endophthalmitis after phacoemulsification. *Arq Bras Oftalmol* 2012;75:344-7.
21. Pollack M. The virulence of *Pseudomonas aeruginosa*. *Rev Infect Dis* 1984;6:617-26.
22. Kreger AS, Griffin OK. Physicochemical fractionation of extracellular cornea-damaging proteases of *Pseudomonas aeruginosa*. *Can J Microbiol* 1985;31:387-92.
23. Mayo MS, Cook WL, Schlitzer RL, Ward MA, Wilson LA, Ahearn DG. Antibigrams, serotypes and plasmid profiles of *Pseudomonas aeruginosa* associated with corneal ulcers and contact lens wear. *J Clin Microbiol* 1986;24:372-6.
24. Garg P, Sharma S, Rao G. Ciprofloxacin resistant *Pseudomonas keratitis*. *Ophthalmology* 1999;106:1319-23.
25. Chaudhry NA, Flynn HW Jr, Murray TG, Tabarideh H, Mello MO Jr, Miller D. Emerging ciprofloxacin-resistant *Pseudomonas aeruginosa*. *Am J Ophthalmol* 1999;128:509-10.
26. Alexandrakis G, Alfonso EC, Miller D. Shifting trends in bacterial keratitis in South Florida and emerging resistance to fluoroquinolones. *Ophthalmology* 2000;107:1497-502.
27. Vazirani J, Wurity S, Ali MH. Multi-drug Resistant *Pseudomonas aeruginosa* Keratitis: Risk factors, clinical characteristics and outcome. *Ophthalmology* 2015;122:2110-4.
28. Maltezou HC, Pappa O, Nikolopoulos G, Ftika L, Maragos A, Kaitsa H, *et al.* Post-cataract surgery endophthalmitis outbreak caused by multidrug-resistant *Pseudomonas aeruginosa*. *Am J Infect Control* 2012;40:75-7.
29. Han DP, Wisniewski SR, Wilson LA, Barza M, Vine AK, Doft BH, *et al.* Spectrum and susceptibilities of microbiologic isolates in the Endophthalmitis Vitrectomy Study. *Am J Ophthalmol* 1996;122:1-17.
30. Anand AR, Therese KL, Madhavan HN. Spectrum of aetiological agents of postoperative endophthalmitis and antibiotic susceptibility of bacterial isolates. *Indian J Ophthalmol* 2000;48:123-8.
31. Recchia FM, Busbee BG, Pearlman RB, Carvalho-Recchia CA, Ho AC. Changing trends in the microbiologic aspects of postcataract endophthalmitis. *Arch Ophthalmol* 2005;123:341-6.
32. Dave VP, Pathengay A, Nishant K, Pappuru RR, Sharma S, Sharma P, *et al.* Clinical presentations, risk factors and outcomes of ceftazidime-resistant Gram-negative endophthalmitis. *Clin Exp Ophthalmol* 2017;45:254-60.
33. Zavascki AP, Goldani LZ, Li J, Nation RL. Polymyxin B for the treatment of multidrug-resistant pathogens: A critical review. *J Antimicrob Chemother* 2007;60:1206-15.
34. Alfaro DV 3rd, Hudson SJ, Kasowski EJ, Barton CP, Brucker AJ, Lopez JD, *et al.* Experimental pseudomonal posttraumatic endophthalmitis in a swine model. Treatment with ceftazidime, amikacin, and imipenem. *Retina* 1997;17:139-45.
35. Murthy G, Gupta SK, John N, Vashist P. Current status of cataract blindness and Vision 2020: The right to sight initiative in India. *Indian J Ophthalmol* 2008;56:489-94.
36. National Program for Control of Blindness and Visual Impairment (NPCBVI). Director General of Health Services, Ministry of Health and Family Welfare, Government of India. Guidelines for preoperative, operative and postoperative precautions for intraocular eye surgery. Available from: <http://npcb.nic.in/writereaddata/mainlinkfile/File325>. 2019. [Last accessed on 2019 Jul 31].