

[CASE REPORT]

Switching Therapy from Intravenous Landiolol to Transdermal Bisoprolol in a Patient with Thyroid Storm Complicated by Decompensated Heart Failure and Gastrointestinal Dysfunction

Shigeo Godo^{1,2}, Yu Kawazoe², Hiroshi Ozaki³, Motoo Fujita², Daisuke Kudo^{2,4},
Ryosuke Nomura², Hiroaki Shimokawa¹ and Shigeki Kushimoto^{2,4}

Abstract:

Thyroid storm is a life-threatening disorder that remains a therapeutic challenge. Although β -blockers are the mainstay for treatment, their use can be challenging in cases complicated by rapid atrial fibrillation and decompensated heart failure. We present a case of thyroid storm-associated atrial fibrillation and decompensated heart failure complicated by gastrointestinal dysfunction secondary to diffuse peritonitis that was successfully managed by a switching therapy, in which the continuous intravenous administration of landiolol was changed to bisoprolol via transdermal patch, in the acute phase treatment. This switching therapy may offer a promising therapeutic option for this potentially lethal disorder.

Key words: acute heart failure, atrial fibrillation, bisoprolol transdermal patch, critical care, landiolol, thyroid storm

(Intern Med 56: 2603-2609, 2017)

(DOI: 10.2169/internalmedicine.8846-17)

Introduction

Thyroid storm is a potentially lethal disease characterized by multiple organ dysfunction secondary to thyrotoxicosis in which rapid atrial fibrillation and acute heart failure are frequent complications (1, 2). β -blockers are a drug of choice for the treatment of the cardiovascular symptoms induced by the increased β -adrenergic tone in hyperthyroidism (1, 3, 4). Although the immediate administration of relatively high doses of β -blockers is required to achieve adequate control of profound tachycardia in the setting of thyroid storm, their use can be challenging especially in cases of thyroid storm complicated by decompensated heart failure, and in cases involving patients who cannot tolerate oral medications due to gastrointestinal dysfunction, which is a common manifestation of thyroid storm (4). This is due to the potential for conventional intravenous β -blockers (e.g. propranolol) to

further exacerbate the heart failure or to induce the circulatory collapse of a failing heart (5). Moreover, no specific treatment of acute congestive heart failure in patients with thyroid storm is available, even in the latest guidelines for the management of thyroid storm (4, 6). Recently, novel forms of cardio-selective β 1-blockers have become available in Japan, including the world's first transdermal patch of the selective β 1 blocker bisoprolol (Bisono[®] Tape, Toa Eiyo, Tokyo, Japan) and an ultra-short-acting selective β 1 blocker landiolol (Onoact[®] for Intravenous Infusion, Ono Pharmaceutical, Osaka, Japan), which is used for the treatment of tachyarrhythmia (atrial fibrillation and atrial flutter) in patients with left ventricular dysfunction (7). However, the usefulness of these new drugs in the treatment of thyroid storm remains largely unknown because only a few case reports are available (8, 9).

We herein present the case of a patient with thyroid storm-associated atrial fibrillation and decompensated heart

¹Department of Cardiovascular Medicine, Tohoku University Graduate School of Medicine, Japan, ²Department of Emergency and Critical Care Medicine, Tohoku University Hospital, Japan, ³Division of Nephrology, Endocrinology and Vascular Medicine, Tohoku University Graduate School of Medicine, Japan and ⁴Division of Emergency and Critical Care Medicine, Tohoku University Graduate School of Medicine, Japan
Received: January 10, 2017; Accepted: February 20, 2017; Advance Publication by J-STAGE: September 6, 2017

Correspondence to Dr. Shigeo Godo, s-godo@cardio.med.tohoku.ac.jp

failure complicated by gastrointestinal dysfunction due to duodenal ulcer perforation that was successfully managed by a switching therapy from intravenous landiolol to transdermal bisoprolol.

Case Report

A 30-year-old woman who had no past medical history was referred to our department for the treatment of thyroid storm with concomitant multiple organ failure and a perforated duodenal ulcer. One month prior to her presentation, she exhibited weight loss (from 70 to 60 kg) despite an excessive appetite. One week before her presentation, she complained of dyspnea and palpitation on effort and generalized edema. Twelve hours before her presentation, she experienced a sudden onset of severe upper abdominal pain and the worsening of dyspnea and palpitation. This led her to be transferred to another hospital during the night, where she arrived with modest delirium, jaundice, anasarca, orthopnea, severe hypotension and atrial fibrillation with a rapid ventricular response (systolic blood pressure, 70 mmHg; pulse 200 beats/min) (Fig. 1A). A chest X-ray showed marked cardiomegaly with bilateral pleural effusions that were larger on the right side (Fig. 2A). Contrast-enhanced computed tomography showed large amounts of free air in front of the edematous duodenal wall and ascites around the liver (Fig. 2B). She was diagnosed with diffuse peritonitis secondary to duodenal perforation and underwent an emergency operation. On the second morning (12 hours after her arrival), the laboratory data revealed hyperthyroidism associated with multiple organ dysfunction including cardiac dysfunction, hepatic failure with jaundice, and acute kidney injury (Table). The Burch and Wartofsky diagnostic score reached 95 points, leading to the diagnosis of thyroid storm (4, 10). On presentation to our institution, she showed modest delirium, jaundice, diffuse goiter, obvious anasarca with moist and warm skin, with the following findings: blood pressure, 71/53 mmHg; pulse, 113 beats/min (atrial fibrillation); body temperature, 37.5°C and oxygen saturation 96% under mechanical ventilation with an inspired oxygen fraction of 0.4 and a positive end expiratory pressure of 5 cmH₂O. Her height, weight and body mass index were 157 cm, 75.1 kg, and 30.5 kg/m², respectively. Echocardiography revealed mild systolic dysfunction with a left ventricular ejection fraction of 40-45%. Acute coronary syndrome and myocarditis were ruled out based on the negative findings of emergency coronary angiography and an endomyocardial biopsy. The patient's hemodynamic parameters were as follows: mean pulmonary capillary wedge pressure, 18 mmHg; pulmonary artery pressure, 42/26 mmHg (mean, 31 mmHg); mean right atrial pressure, 24 mmHg; cardiac index, 3.9 L/min/m²; systemic vascular resistance index, 208 dyn-sec/cm⁵/m²; and pulmonary vascular resistance index, 93 dyn-sec/cm⁵/m², which were compatible with high output cardiac failure with extremely low systemic vascular resistance in thyroid storm (11). Based on these clinical data, our initial

therapy included antithyroid therapy with intravenous thiamazole (40 mg/day) and hydrocortisone (200 mg/day), continuous renal replacement therapy for the continuous progression of metabolic acidosis, dobutamine (3 µg/kg/min), noradrenaline (0.4 µg/kg/min), vasopressin (3 units/h) and an intra-aortic balloon pump in order to maintain a mean arterial pressure of at least 65 mmHg (Fig. 3). Although she presented with decompensated heart failure and hemodynamic instability, her rapid atrial fibrillation was refractory to rhythm control treatment using direct current; her atrial fibrillation recurred promptly after a temporal termination by direct current. We therefore adopted a rate control strategy in which landiolol was administered under the close monitoring of the patient's hemodynamic status at an initial dose of 1 µg/kg/min. The dose was then up-titrated by 1 µg/kg/min every hour to a maximum dose of 17 µg/kg/min in order to achieve a target heart rate of <130 beats/min (4, 7, 12) (Fig. 1B and C, 3). As expected, the control of tachycardia led to a significant improvement in the cardiac function and hemodynamics (Fig. 3). On day 3, after her hemodynamic status had improved, we administered a bisoprolol transdermal patch (initial dose: 4 mg/day). The dose was subsequently increased to 8 mg/day while landiolol was successfully tapered off by day 6 (Fig. 3). This switching therapy was well-tolerated without an exacerbation of the patient's heart failure. On day 8, she underwent an emergency re-operation due to suture failure at the site of the perforated duodenal ulcer. However, she was able to continue the steady β-blocker treatment and did not suffer from a relapse of thyroid storm due to this invasive procedure. Because mild hypotension that was dependent on a low dose of noradrenaline persisted, we added a non-selective β-blocker, propranolol, in order to reverse the reduced systemic vascular resistance, which was possibly due to thyroid hormone-induced β₂ receptor upregulation in the vascular periphery (13). The additional propranolol allowed for noradrenaline to be tapered off within two weeks. On day 19, she had a spontaneous return to sinus rhythm and her cardiac functions normalized; she was therefore discharged from the intensive care unit (Fig. 2C, Table). On day 99, she was discharged from the hospital after long-term rehabilitation for generalized muscle weakness due to thyroid myopathy.

Discussion

The present case highlighted two important clinical implications. First, switching therapy from intravenous landiolol to transdermal bisoprolol is feasible and effective in the management of thyroid storm-associated atrial fibrillation and decompensated heart failure, even when such cases are complicated by gastrointestinal dysfunction. Second, the tolerability of the initial treatment with landiolol helps to predict a durable dosage in the subsequent treatment with conventional β-blockers, the induction of which otherwise has the potential to further exacerbate heart failure. To the best

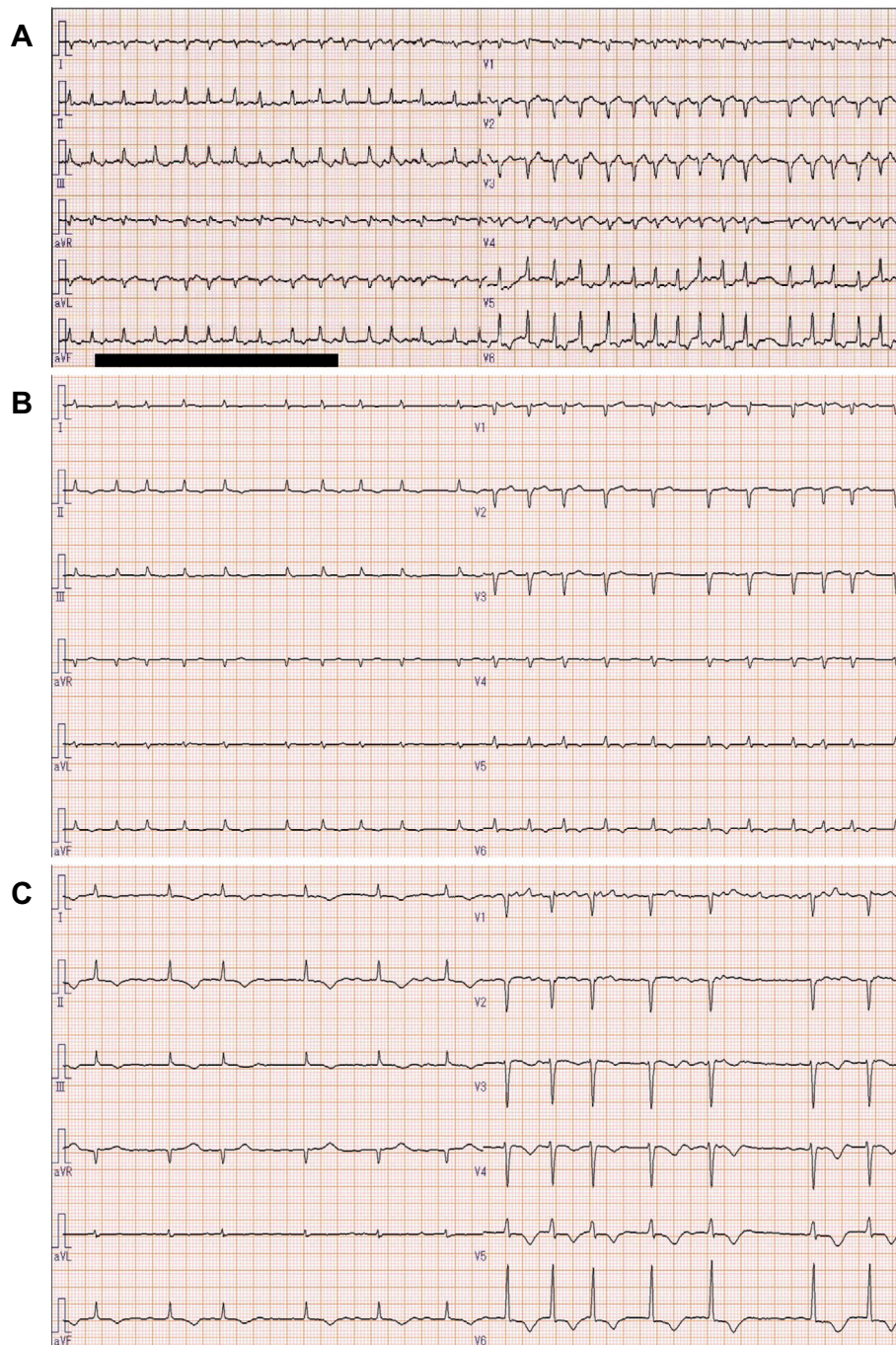


Figure 1. Electrocardiography. (A) The electrocardiogram on the initial presentation to the previous hospital before the administration of landiolol showed excessively rapid atrial fibrillation (180-200 beats/min). (B) The electrocardiogram on her presentation to our department under the intravenous administration of landiolol (5 µg/kg/min) showed a rapid atrial fibrillation (130-160 beats/min). (C) The electrocardiogram under the intravenous administration of landiolol at a maximum dose of 17 µg/kg/min showed the successful control of atrial fibrillation (90-110 beats/min).

of our knowledge, this is the first case report to demonstrate a successful switching therapy from intravenous landiolol to transdermal bisoprolol in a patient with thyroid storm-associated decompensated heart failure complicated by gastrointestinal dysfunction.

First, the switching therapy from intravenous landiolol to transdermal bisoprolol offers a safe and effective strategy for managing thyroid storm-associated atrial fibrillation with

acute heart failure, even when the gastrointestinal function is compromised. β -blockers are the mainstay treatment for managing rapid thyroid storm-associated atrial fibrillation (1, 3, 4). Although the bisoprolol transdermal patch had yet to be approved for the treatment of tachyarrhythmia (such as rapid atrial fibrillation) we used the transdermal patch, instead of oral bisoprolol due to concerns regarding the possibility of poor intestinal absorption in the acute set-

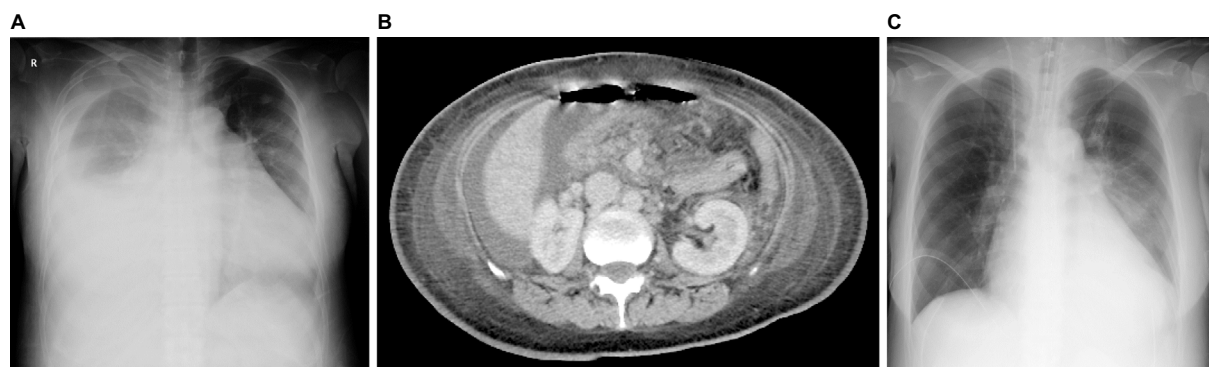

Figure 2. Chest X-rays films and contrast-enhanced computed tomography. (A) The chest X-ray on presentation to previous hospital showed marked cardiomegaly with bilateral pleural effusions that were larger on the right side. (B) Contrast-enhanced computed tomography on presentation to the previous hospital (before surgery) revealed free air in the peritoneal cavity with edematous duodenum and ascites. (C) The chest X-ray on discharge from the intensive care unit showed a marked improvement of heart failure.

Table. Laboratory Data.

	Reference range	On admission	On discharge from ICU
Thyroid function tests			
TSH (μ IU/mL)	0.35-4.94	<0.01	<0.01
fT3 (pg/mL)	1.71-3.71	6.16	1.15
fT4 (ng/dL)	0.70-1.48	2.98	0.43
Tg (ng/mL)	0-33.7	348	NA
TSAb (%)	0-120	842	NA
TgAb (IU/mL)	0-28.0	98.6	NA
TPOAb (IU/mL)	0-16.0	201	NA
Others			
WBC (μ L)	3,500-9,100	17,600	15,200
T-bil (mg/dL)	0.3-1.2	13.4	6.5
D-bil (mg/dL)	0-0.4	10.3	3.9
AST (IU/L)	10-40	46	24
ALT (IU/L)	5-40	54	42
BUN (mg/dL)	8.0-22.0	17.0	10.0
Cre (mg/dL)	0.47-0.79	0.30	0.19
BNP (pg/mL)	<18.4	986	493
CRP (mg/dL)	<0.30	3.6	0.9
Alb (mg/dL)	3.8-5.2	2.3	1.3
T-chol (mg/dL)	150-219	<39	66
Lactate (mmol/L)	0.37-1.65	3.3	1.2

Alb: albumin, ALT: alanine-aminotransferase, AST: aspartate-aminotransferase, BNP: brain natriuretic peptide, BUN: blood urea nitrogen, Cre: creatinine, CRP: C-reactive protein, D-bil: direct bilirubin, fT3: free triiodothyronine, fT4: free thyroxine, ICU: intensive care unit, NA: not available, T-bil: total bilirubin, T-chol: total cholesterol, Tg: thyroglobulin, TgAb: thyroglobulin antibody, TPOAb: thyroid peroxidase antibody, TSAb: thyroid stimulating antibody, TSH: thyroid-stimulating hormone, WBC: white blood cell

ting of heart failure complicated by gastrointestinal dysfunction due to diffuse peritonitis secondary to duodenal ulcer perforation. In critically ill patients, enteral administration can be hampered by concurrent gastrointestinal dysfunction, including vomiting, diarrhea, gastroparesis, and ileus, leading to poor tolerance of enteral feeding. This is also the case in patients with thyroid storm, where gastrointestinal dys-

function is such a common manifestation that it is included in the diagnostic criteria for thyroid storm (10). In comparison to a 5 mg oral bisoprolol formulation, an 8 mg bisoprolol transdermal patch results in lower peak and higher trough concentrations of bisoprolol while exerting similar blood pressure and heart rate lowering effects. The transdermal patch provides a stable treatment with bisoprolol via

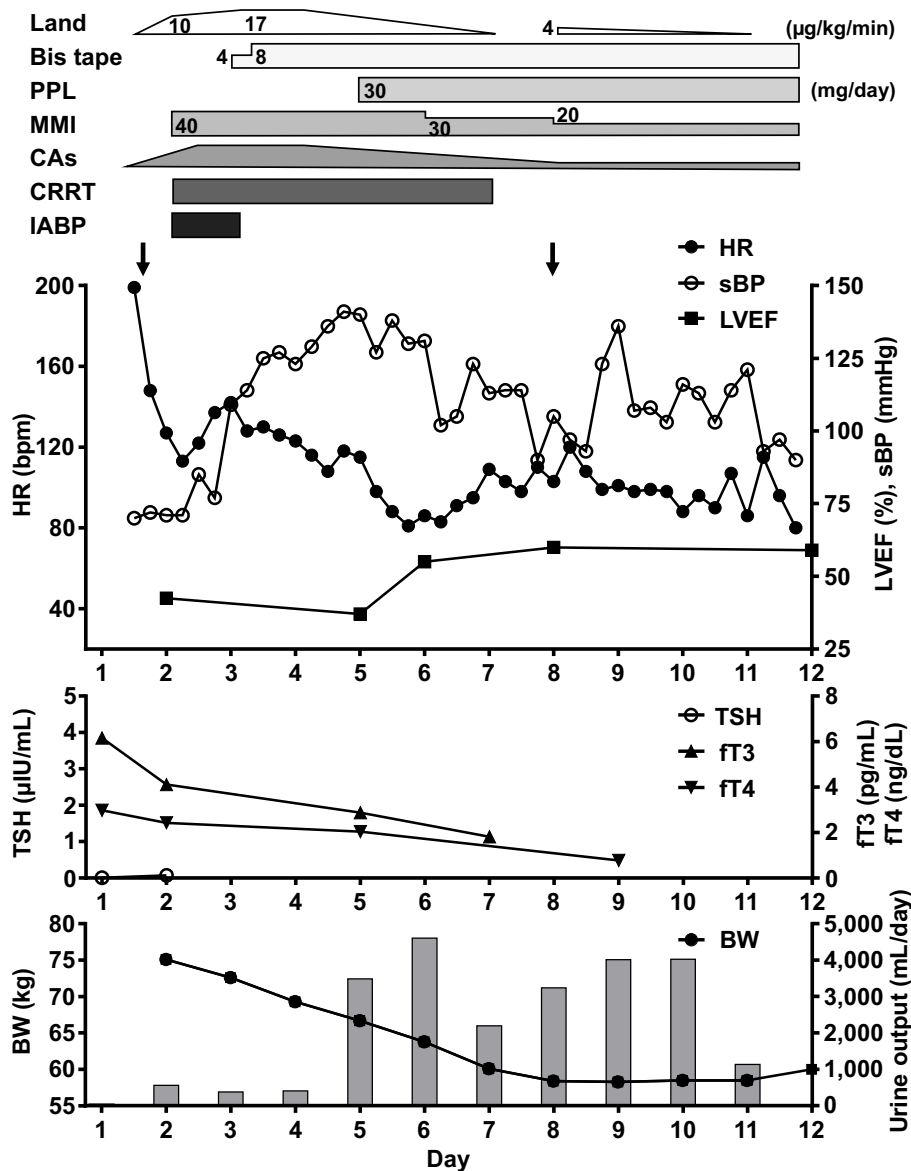


Figure 3. The clinical course of the hemodynamic status, circulatory management, and thyroid hormone levels. Each arrow indicates an emergency operation. Bis tape: bisoprolol transdermal patch, BW: body weight, CAs: catecholamines, CRRT: continuous renal replacement therapy, FT3: free triiodothyronine, FT4: free thyroxine, HR: heart rate, IABP: intra-aortic balloon pump, Land: landiolol, LVEF: left ventricular ejection fraction, MMI: thiamazole, PPL: propranolol, sBP: systolic blood pressure, TSH: thyroid-stimulating hormone

percutaneous absorption, irrespective of gastrointestinal dysfunction (14). Indeed, the novel transdermal patch of bisoprolol has gained increasing attention due to its emerging usefulness in the treatment of critically ill patients. For example, a retrospective study of 16 critically ill patients with rapid atrial fibrillation showed that switching therapy from landiolol to transdermal bisoprolol was successful and cost-effective without significant adverse events (15), while a case report on acute type B aortic dissection showed that a control of the heart rate and blood pressure was swiftly achieved in a stable manner using a transdermal patch of bisoprolol (16). Taken together, switching therapy from landiolol to transdermal bisoprolol after the improvement of the systemic hemodynamic condition may offer a promising

therapeutic option for the treatment of critically ill patients, including those with thyroid storm.

Second, the initial management of thyroid storm associated with atrial fibrillation and decompensated heart failure using landiolol can minimize the risk of a further exacerbation of heart failure, which can be induced by the acute induction of treatment with conventional β -blockers. β -blockers should be initiated with extreme care, especially for patients with decompensated heart failure and for those with left ventricular systolic dysfunction (5, 9). In the current guidelines, digitalis and amiodarone are recommended for acute rate control in patients with atrial fibrillation and left ventricular dysfunction (17-19). However, in the present patient, digoxin and amiodarone were not only ineffective in

controlling the patient's excessive tachycardia due to atrial fibrillation, they were also unsuitable for continuous use due to a concurrent acute kidney injury and the potential for thyrotoxicosis, respectively (2, 20). Furthermore, other heart rate lowering drugs, including verapamil and diltiazem are contraindicated for patients with decompensated heart failure or cardiogenic shock. Although propranolol is commonly used in the treatment of an increased heart rate in patients with thyrotoxicosis, the rapid administration of propranolol is challenging in patients with thyroid storm associated with decompensated heart failure due to the risk of cardiovascular collapse (21). In contrast, landiolol is a novel ultra-short-acting β -blocker with the unique properties of a short half-life (4 minutes), easy titratability independent of renal and hepatic clearance, a quick onset and offset of action and high β_1 receptor selectivity ($\beta_1/\beta_2=255$) (22). These advantages of landiolol may allow for much safer dose adjustment in the rate control of tachyarrhythmia in critically ill patients in comparison to conventional drugs such as digoxin, verapamil, diltiazem, and other β -blockers. Indeed, landiolol can be titrated with the close monitoring of the hemodynamic status in patients with atrial fibrillation and acute heart failure (7, 23). The J-Land study is a landmark trial demonstrating the safety and efficacy of landiolol for patients with atrial fibrillation and heart failure who show a reduced left ventricular ejection fraction (7). In the J-Land study, 50% of the total patients underwent switching therapy from landiolol (mean \pm standard deviation: 6.3 ± 3.5 $\mu\text{g}/\text{kg}/\text{min}$) to an oral bisoprolol formulation (1.8 ± 1.3 mg) (7). Based on the conversion dose in the J-Land study, the therapy in the present case could be switched from landiolol (17 $\mu\text{g}/\text{kg}/\text{min}$, intravenously) to bisoprolol (8 mg/day, via transdermal patch) without the exacerbation of the patient's heart failure. This dose corresponded to an oral bisoprolol dose of 5 mg. Further observation and prospective trials are needed to elucidate whether switching therapy can be safely conducted in patients with more severe left ventricular systolic dysfunction (e.g. left ventricular ejection fraction $<30\%$).

Thyroid storm remains a life-threatening disorder that can make treatment more challenging if it is complicated by rapid atrial fibrillation, decompensated heart failure and gastrointestinal dysfunction. The course of our patient provided two important clinical issues: switching therapy from landiolol to transdermal bisoprolol provides a feasible management for thyroid storm-associated atrial fibrillation with acute heart failure, even when the gastrointestinal function is compromised, and the initial treatment of this disorder using landiolol can minimize the risk of a further exacerbation of heart failure which can be induced by the acute induction of conventional β -blockers. In conclusion, the switching therapy of these drugs may be a promising therapeutic option for patients with thyroid storm.

The authors state that they have no Conflict of Interest (COI).

References

1. Chiha M, Samarasinghe S, Kabaker AS. Thyroid storm: an updated review. *J Intensive Care Med* **30**: 131-140, 2015.
2. De Leo S, Lee SY, Braverman LE. Hyperthyroidism. *Lancet* **388**: 906-918, 2016.
3. Tagami T, Yambe Y, Tanaka, et al. Short-term effects of beta-adrenergic antagonists and methimazole in new-onset thyrotoxicosis caused by Graves' disease. *Intern Med* **51**: 2285-2290, 2012.
4. Satoh T, Isozaki O, Suzuki A, et al. 2016 Guidelines for the management of thyroid storm from The Japan Thyroid Association and Japan Endocrine Society (first edition). *Endocr J* **63**: 1025-1064, 2016.
5. Lee HY, Baek SH. Optimal use of beta-blockers for congestive heart failure. *Circ J* **80**: 565-571, 2016.
6. Ross DS, Burch HB, Cooper DS, et al. 2016 American Thyroid Association guidelines for diagnosis and management of hyperthyroidism and other causes of thyrotoxicosis. *Thyroid* **26**: 1343-1421, 2016.
7. Nagai R, Kinugawa K, Inoue H, et al. Urgent management of rapid heart rate in patients with atrial fibrillation/flutter and left ventricular dysfunction: comparison of the ultra-short-acting beta1-selective blocker landiolol with digoxin (J-Land Study). *Circ J* **77**: 908-916, 2013.
8. Ogiso S, Inamoto S, Hata H, Yamaguchi T, Otani T, Koizumi K. Successful treatment of gastric perforation with thyrotoxic crisis. *Am J Emerg Med* **26**: 1065 e3-1065 e4, 2008.
9. Yamashita Y, Iguchi M, Nakatani R, et al. Thyroid storm with heart failure treated with a short-acting beta-adrenoreceptor blocker, landiolol hydrochloride. *Intern Med* **54**: 1633-1637, 2015.
10. Burch HB, Wartofsky L. Life-threatening thyrotoxicosis. Thyroid storm. *Endocrinol Metab Clin North Am* **22**: 263-277, 1993.
11. Woebler KA. Thyrotoxicosis and the heart. *N Engl J Med* **327**: 94-98, 1992.
12. Rawles JM. What is meant by a "controlled" ventricular rate in atrial fibrillation? *Br Heart J* **63**: 157-161, 1990.
13. Bilezikian JP, Loeb JN. The influence of hyperthyroidism and hypothyroidism on alpha- and beta-adrenergic receptor systems and adrenergic responsiveness. *Endocr Rev* **4**: 378-388, 1983.
14. Matsuoka H, Kuwajima I, Shimada K, Mitamura H, Saruta T. Comparison of efficacy and safety between bisoprolol transdermal patch (TY-0201) and bisoprolol fumarate oral formulation in Japanese patients with grade I or II essential hypertension: randomized, double-blind, placebo-controlled study. *J Clin Hypertens* **15**: 806-814, 2013.
15. Nakamura K, Inokuchi R, Hiruma T, Tokunaga K, Doi K, Nakajima S. Switching therapy from intravenous beta blocker to bisoprolol transdermal patch for atrial fibrillation tachycardia. *J Anesth* **30**: 891-894, 2016.
16. Hara T, Yagi S, Akaike M, Sata M. Transdermal patch of bisoprolol for the treatment of hypertension complicated with aortic dissection. *Int J Cardiol* **198**: 220-221, 2015.
17. Wann LS, Curtis AB, Ellenbogen KA, et al. 2011 ACCF/AHA/HRS focused update on the management of patients with atrial fibrillation (update on Dabigatran): a report of the American College of Cardiology Foundation/American Heart Association Task Force on practice guidelines. *Circulation* **123**: 1144-1150, 2011.
18. JCS Joint Working Group. Guidelines for pharmacotherapy of atrial fibrillation (JCS 2013). *Circ J* **78**: 1997-2021, 2014.
19. Kirchhof P, Benussi S, Kotecha D, et al. 2016 ESC Guidelines for the management of atrial fibrillation developed in collaboration with EACTS. *Eur Heart J* **37**: 2893-2962, 2016.
20. David D, Segni ED, Klein HO, Kaplinsky E. Inefficacy of digitalis in the control of heart rate in patients with chronic atrial fibrillation: beneficial effect of an added beta adrenergic blocking agent. *Am J Cardiol* **44**: 1378-1382, 1979.

21. Dalan R, Leow MK. Cardiovascular collapse associated with beta blockade in thyroid storm. *Exp Clin Endocrinol Diabetes* **115**: 392-396, 2007.
22. Iguchi S, Iwamura H, Nishizaki M, et al. Development of a highly cardioselective ultra short-acting beta-blocker, ONO-1101. *Chem Pharm Bull* **40**: 1462-1469, 1992.
23. Kobayashi S, Murakami W, Myoren T, et al. A low-dose beta1-blocker effectively and safely slows the heart rate in patients with acute decompensated heart failure and rapid atrial fibrillation. *Cardiology* **127**: 105-113, 2014.

The Internal Medicine is an Open Access article distributed under the Creative Commons Attribution-NonCommercial-NoDerivatives 4.0 International License. To view the details of this license, please visit (<https://creativecommons.org/licenses/by-nc-nd/4.0/>).

© 2017 The Japanese Society of Internal Medicine
Intern Med 56: 2603-2609, 2017