

Effectiveness of Dupilumab for an Elderly Patient with Prurigo Nodularis Who Was Refractory and Contradicted to Traditional Therapy

This article was published in the following Dove Press journal:
Journal of Asthma and Allergy

Taoming Liu
Juan Bai
Su Wang
Shuni Ying
Sheng Li 
Jianjun Qiao 
Hong Fang

Department of Dermatology, The First Affiliated Hospital, Zhejiang University School of Medicine, Hangzhou, People's Republic of China

Abstract: Prurigo nodularis (PN) is an intense pruritic skin condition. Treatment of PN is challenging. We described an elderly patient with PN who had contradictions of cyclosporine or methotrexate and achieved significant improvement after treatment with dupilumab. We also reviewed published cases of elderly patients with PN who were refractory to traditional therapy.

Keywords: prurigo nodularis, dupilumab, elderly patient, targeted therapy

Introduction

Prurigo nodularis (PN) is a chronic inflammatory skin disease, which is characterized by intractable pruritus and hyperkeratotic nodules. Effective treating options for PN are limited. Systemic therapies (methotrexate, cyclosporine, and thalidomide) are burdened by a high incidence of serious adverse effects, especially in elderly patients.¹ Dupilumab is a fully humanized interleukin (IL)-4R α antibody. It has been demonstrated to be effective and safe for treating patients with PN with or without atopic history.² Herein we reported a case of elderly patient with refractory PN, and effectively treated with dupilumab.

Case Presentation

An 85-year-old man presented with a 16-year history of PN. He had a history of interstitial lung disease and denied to have atopic background. Physical examination revealed widespread erythematous nodules, plaques, papules, and excoriations on the scalp, extremities, and trunk (**Figure 1**). Blood tests showed an eosinophil count $0.53 \times 10^9/L$ (normal range $0.02-0.50 \times 10^9/L$), total IgE level 242 KU/L (normal range <100.0 KU/L), and a glomerular filtration rate 37 mL/min. This study procedure was given ethical approved by the ethics committees of The First Affiliated Hospital, Zhejiang University School of Medicine (Approved number: IIT20210020A). The patient has given the written informed consent to this case report with all details displayed and the corresponding images.

In the past one month, he had been administrated with gabapentin 300mg twice daily, thalidomide 50mg daily, ketotifen 1 mg per night, NB-UVB twice weekly, and topically halomethane cream as needed. However, these treatments failed to relieve his pruritus. Therefore, the patient was transferred from a local hospital to our department. Due to the low glomerular filtration rate (37 mL/min) and interstitial lung disease

Correspondence: Jianjun Qiao; Hong Fang
Department of Dermatology, The First Affiliated Hospital, Zhejiang University School of Medicine, No. 79 Qingchun Road, Hangzhou, People's Republic of China
Tel/Fax +86-571-87236706
Email qiaojianjun@zju.edu.cn; fanghongzy@zju.edu.cn

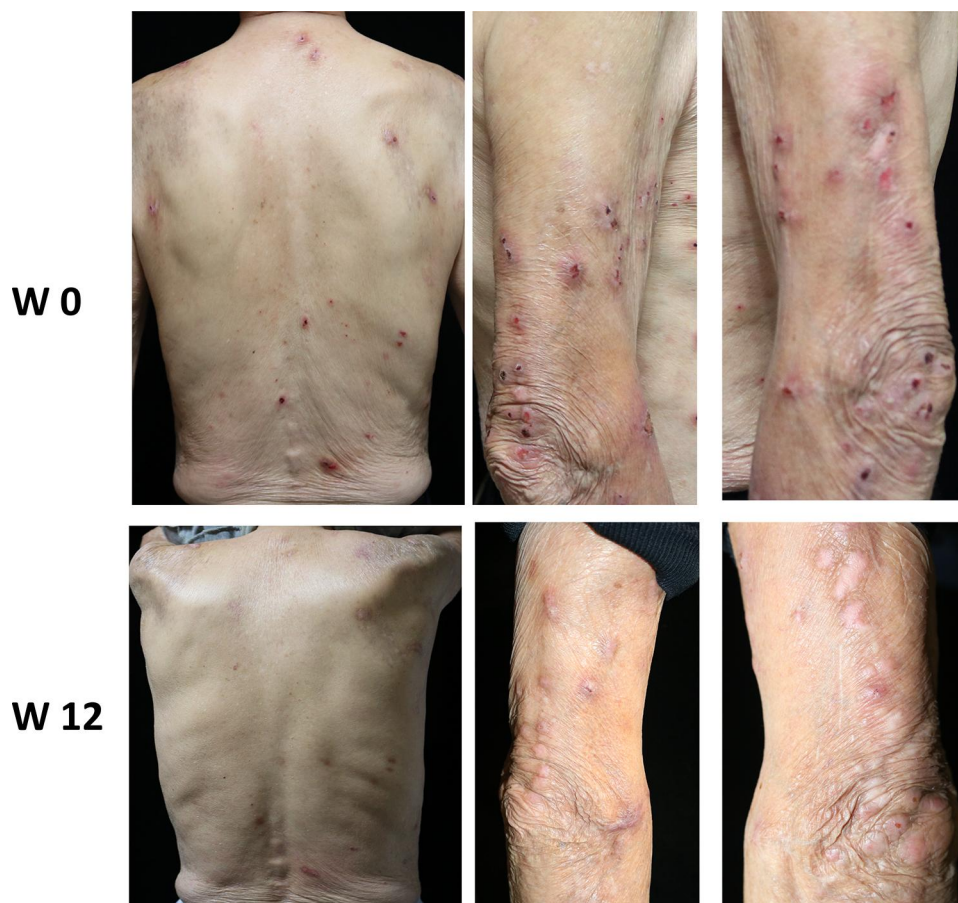


Figure 1 Clinical presentation of an elderly patient with prurigo nodularis. Prurigo nodularis lesions involving the upper limbs and the trunk at baseline (W0). They were improved after dupilumab therapy at week 12 (W12).

history, cyclosporine and methotrexate were not recommended to the elderly patient. As suffering from intensive pruritus and low quality of life, this patient was treated with dupilumab with standard doses of 600 mg subcutaneously at week 0 and then 300 mg every other week. During the first 8-week treatment, the patient was continuing to receive cetirizine 10 mg per day, ketotifen 1 mg per night, and topically halomethane cream as needed. Within 12 weeks, the patient

gradually achieved improvement of itch intensity measured by visual analogue scale. In order to evaluate the change of cutaneous lesions, we used the tools of investigator's global assessment and prurigo activity score. The later one represents the patient's overall disease severity measured by counted number of nodules at the same represented location.³ During the 12-week therapy with dupilumab, reductions were observed in disease severity as assessed on

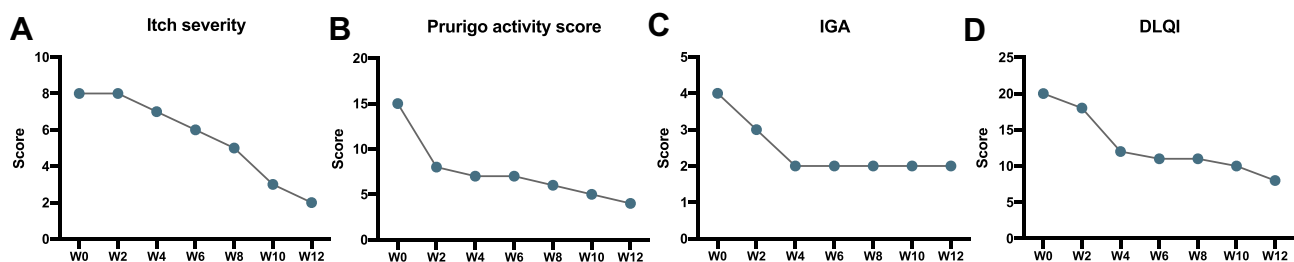


Figure 2 Clinical scores of an elderly patient with prurigo nodularis during dupilumab therapy. (A) The changes of itch severity were measured by visual analogue scale. The changes of cutaneous lesions were assessed by (B) the counted number of nodules in dorsal side of the trunk and (C) IGA. (D) The quality of life was tested by DLQI. **Abbreviations:** IGA, investigator's global assessment; DLQI, Dermatology Life Quality Index.

the itch score, prurigo activity score (location: the dorsal site of the trunk), investigator's global assessment, and Dermatology Life of Quality of Index (Figure 2). No adverse effects were reported during the therapy.

Discussion

It has been identified that the levels of IL-4, IL-13, and IL-31 are increased in lesions of patients with PN.^{4,5} Dupilumab inhibits T helper 2 immune response by blocking IL-4 and IL-13 pathway.⁶ Dupilumab is likely to break the itch-scratch cycle of PN through inhibiting these cytokines.

Case series and case reports recently have showed the satisfied efficacy and safety of dupilumab for the treatment of elderly patients with PN (Table 1),⁷⁻¹¹ particularly those failed to traditional therapy. Our case report contributes to the increasing evidence that dupilumab is a therapeutic choice for elderly patients with PN contradicted to traditional therapy.

Conclusion

In summary, our case report further suggests that dupilumab could be considered as a potential and well-tolerated

Table 1 Review of Cases of Elderly Patients with Prurigo Nodularis Treated by Dupilumab

| References | Age | Gender | History of Atopic Diseases | Blood Tests | Treatment Failures Before Dupilumab Therapy | Effectuated Evaluation of Dupilumab Therapy | Adverse Events |
|----------------------------|-----|--------|-----------------------------|---|--|--|----------------|
| Beck et al ⁷ | 70s | Male | NA | NA | Corticosteroids, hydroxyzine hydrochloride, doxepin, dronabinol, gabapentin, phototherapy, cryotherapy, | Pruritus and skin lesions improved with in 8 weeks | No |
| Giura et al ⁸ | 85 | Female | NA | Total IgE 168 KU/L, LDH 555 UI/L, eosinophil count $0.98 \times 10^9/L$ | Topical and systemic corticosteroids | Pruritus and skin lesions approximately disappeared | No |
| Kovács et al ⁹ | 80 | Female | Atopic dermatitis | High total IgE | Topical corticosteroids, topical calcineurin inhibitors, antihistamines, antidepressants, gabapentin, cyclosporine, methotrexate, naloxone, UVB irradiation, | Pruritus improved with in 10 weeks | NA |
| Criado et al ¹⁰ | 87 | Male | Atopic dermatitis, rhinitis | Elevated eosinophil and IgE | Topical, intralesional, and systemic corticosteroids, mirtazapine, pregabalin, hydroxyzine, methotrexate, cyclosporine. | Pruritus improved with in 4 weeks. Pruritus and skin lesions approximately disappeared within 16 weeks | No |
| Wieser et al ¹¹ | 66 | Female | No | NA | Topical corticosteroids, antihistamines, prednisone, methotrexate | Pruritus improved with in 20 weeks, skin lesions improved with in 16 weeks | No |
| Wieser et al ¹¹ | 65 | Male | No | NA | Thalidomide, intralesional triamcinolone, gabapentin, phototherapy | Pruritus and skin lesions improved with in 4 weeks | No |
| Wieser et al ¹¹ | 65 | Female | No | NA | Topical corticosteroids, tacrolimus 0.1% ointment, antihistamines, gabapentin, hydroxyzine | Pruritus and skin lesions improved with in 28 weeks | No |

treatment option for elderly patients with PN, especially in who were refractory or contradicted to conventional therapy.

Acknowledgments

This work was supported by the National Natural Science Foundation of China (81972931 to HF), and the Medical and Health Science and Technology Project of Health Commission of Zhejiang Province (2020KY558 to JQ).

Disclosure

The authors declare no conflicts of interest related to this work.

References

- Huang AH, Canner JK, Kang S, Kwatra SG. Analysis of real-world treatment patterns in patients with prurigo nodularis. *J Am Acad Dermatol.* 2020;82(1):34–36. doi:10.1016/j.jaad.2019.09.007
- Williams KA, Huang AH, Belzberg M, Kwatra SG. Prurigo nodularis: pathogenesis and management. *J Am Acad Dermatol.* 2020;83(6):1567–1575. doi:10.1016/j.jaad.2020.04.182
- Ständer S, Yosipovitch G, Legat FJ, et al. Trial of nemolizumab in moderate-to-severe prurigo nodularis. *N Engl J Med.* 2020;382(8):706–716. doi:10.1056/NEJMoa1908316
- Park K, Mori T, Nakamura M, Tokura Y. Increased expression of mRNAs for IL-4, IL-17, IL-22 and IL-31 in skin lesions of subacute and chronic forms of prurigo. *Eur J Dermatol.* 2011;21(1):135–136. doi:10.1684/ejd.2010.1196
- Zhong W, Wu X, Zhang W, et al. Aberrant expression of histamine-independent pruritogenic mediators in keratinocytes may be involved in the pathogenesis of prurigo nodularis. *Acta Derm Venereol.* 2019;99(6):579–586. doi:10.2340/00015555-3150
- Beck LA, Thaçi D, Hamilton JD, et al. Dupilumab treatment in adults with moderate-to-severe atopic dermatitis. *N Engl J Med.* 2014;371(2):130–139. doi:10.1056/NEJMoa1314768
- Beck KM, Yang EJ, Sekhon S, Bhutani T, Liao W. Dupilumab treatment for generalized prurigo nodularis. *JAMA Dermatol.* 2019;155(1):118–120. doi:10.1001/jamadermatol.2018.3912
- Giura MT, Viola R, Fierro MT, Ribero S, Ortoncelli M. Efficacy of dupilumab in prurigo nodularis in elderly patient. *Dermatol Ther.* 2020;33(1):e13201. doi:10.1111/dth.13201
- Kovács B, Rose E, Kuznik N, et al. Dupilumab for treatment-refractory prurigo nodularis. *J Dtsch Dermatol Ges.* 2020;18(6):618–624. doi:10.1111/ddg.14107
- Criado PR, Pincelli TP, Criado RFJ. Dupilumab as a useful treatment option for prurigo nodularis in an elderly patient with atopic diathesis. *Int J Dermatol.* 2020;59(10):e358–e361. doi:10.1111/ijd.14994
- Wieser JK, Mercurio MG, Somers K. Resolution of treatment-refractory prurigo nodularis with dupilumab: a case series. *Cureus.* 2020;12(6):e8737. doi:10.7759/cureus.8737

Journal of Asthma and Allergy

Dovepress

Publish your work in this journal

The Journal of Asthma and Allergy is an international, peer-reviewed open-access journal publishing original research, reports, editorials and commentaries on the following topics: Asthma; Pulmonary physiology; Asthma related clinical health; Clinical immunology and the immunological basis of disease; Pharmacological interventions and

new therapies. The manuscript management system is completely online and includes a very quick and fair peer-review system, which is all easy to use. Visit <http://www.dovepress.com/testimonials.php> to read real quotes from published authors.

Submit your manuscript here: <https://www.dovepress.com/journal-of-asthma-and-allergy-journal>