



Case Report

Excellent recovery after nonmissile penetrating traumatic brain injury in a child: A case report

Reber S. Yousif¹, Alend M. Omar¹, Mustafa Ismail², Wael O. Hamouda^{3,4}, Aktham O. Alkhafaji², Samer S. Hoz⁵ 

¹Department of Neurosurgery, Emergency Teaching Hospital, Duhok, ²College of Medicine, University of Baghdad, Baghdad, Iraq, ³Department of Neurosurgery, Kasr Alainy School of Medicine, Research and Teaching Hospitals, Cairo University, Cairo, Egypt, ⁴Department of Neurological and Spinal Surgery Service, Security Forces Hospital, Dammam, Saudi Arabia, ⁵Department of Neurosurgery, University of Cincinnati, Cincinnati, Ohio, United States.

E-mail: Reber S. Yousif - reber.mohammed@uoz.edu.krd; Alend M. Omar - alendneuro88@gmail.com; Mustafa Ismail - mustafalorance2233@gmail.com; *Wael O. Hamouda - wohamouda@outlook.com; Aktham O. Alkhafaji - akthamalkhafaji@gmail.com; Samer S. Hoz - hozsamer2055@gmail.com



*Corresponding author:

Wael O. Hamouda,
Professor Assistant, Department of Neurosurgery, Kasr Alainy School of Medicine, Research, and Teaching Hospitals, Cairo University, Cairo, Egypt.
Senior Consultant, Neurological and Spinal Surgery Service, Security Forces Hospital, Dammam, Saudi Arabia.

wohamouda@outlook.com

Received : 13 April 2022
Accepted : 09 August 2022
Published : 26 August 2022

DOI
10.25259/SNI_350_2022

Quick Response Code:



ABSTRACT

Background: Nonmissile penetrating traumatic brain injuries (pTBIs) are low-velocity injuries which can be caused by a variety of inflicting tools and represent a rare entity in children. Poor outcome has been attributed with an initial admission Glasgow Coma Scale (GCS) of <5, asymmetrical pupil size, and specific initial computed tomography scan findings including brainstem injury.

Case Description: We report a case of an 11-year-old boy who presented to our ER with a GCS of 6 after being assaulted on his head by a 30 cm length metallic tent hook penetrating his forehead reaching down to the central skull base zone.

Conclusion: We demonstrated that following standard recommendations in the management of pTBI which include applying the advanced trauma life support protocol in ER, acquiring the needed preoperative neuroimaging studies, avoiding moving the penetrating object till patient shifted to OR, and finally performing a planned stepwise surgical intervention through craniotomy may yield an excellent functional recovery, especially in children despite an otherwise grave initial presentation and apparently profound brain injury.

Keywords: Nonmissile, Pediatric, Penetrating traumatic brain injury, Recovery

INTRODUCTION

Nonmissile penetrating traumatic brain injuries (pTBIs) are rare entity in children with different reported mechanisms of occurrence.^[12,14] The most common reported sites of object penetration to the intracranial cavity are the orbit, temporal squama, and the skull base foramina.^[2,8] Nonmissile pTBI is a low-velocity injury which can be caused by a variety of inflicting tools including iron rods and wood.^[6] The management options for nonmissile pTBI include surgery as the mainstay which usually yield better outcomes than those experienced after missile pTBI.^[13] Here, we report a case of nonmissile pTBI caused by a tent hook in a child along with his unexpected recovery.

CASE PRESENTATION

An otherwise healthy 11-year-old boy presented by his family to the ER department suffering from disturbance in the level of consciousness with Glasgow Coma Scale (GCS) of 6/15 (E2,

This is an open-access article distributed under the terms of the Creative Commons Attribution-Non Commercial-Share Alike 4.0 License, which allows others to remix, transform, and build upon the work non-commercially, as long as the author is credited and the new creations are licensed under the identical terms.

©2022 Published by Scientific Scholar on behalf of Surgical Neurology International

V2, M2). There has been no history suggestive of seizures. On examination, a 10 cm open wound in the left side of his forehead was evident with a skull bone defect seen beneath it through which brain tissue can be visualized. A sort of a medium-sized metallic hook used to fix tents to the ground was penetrating and anchored to the wound and the skull defect [Figure 1]. Both pupils were equal, medium sized, and reactive to light. No asymmetry in his limbs movements could be detected. The head injury was a result of an assault. After stabilization in the emergency department, a plain skull radiograph was performed and showed the metallic hook penetrating the frontal bone and extending to the central skull base zone [Figure 2]. Computed tomography (CT) scan illustrated hematoma along the injury tract with no associated intraventricular hemorrhage or remote intracerebral hemorrhage considering the limitations exerted by the metal artifact. The midline frontal bone was broken and depressed reaching the left orbital roof [Figure 3].

The decision was to intervene surgically aiming for (1) evacuation of the injury tract hematoma with achieving hemostasis, (2) elevation of the depressed frontal bone fracture with removal of any scattered accessible bony spicules, (3) cleaning and debridement of the soft tissue wound, and (4) closure in layers with the best achievable cosmetic outcome. Therefore, intraoperatively, the scalp wound was extended to perform a craniotomy centered around the hook entry site, exposing the underlying dura which was lacerated at the site of hook penetration, this was followed by cautious retrieval of the hook from within the brain under direct vision where it has been found to have a trajectory from the paramedian right frontal lobe to the contralateral posterior basal left frontal lobe sliding over the medial part of the sphenoid ridge for few millimeters into the anterior left temporal lobe [Figure 4]. Generous wound debridement and excision of the devitalized brain tissue where appropriate was carried out followed by irrigation with antibiotic-mixed saline and meticulous hemostasis. Dura defect closure was done using a periosteal graft. The skin loss was not extensive and closure in layers was readily achievable. Postoperatively, the patient was shifted to the ICU, with gradual daily improvement of his conscious level. Six days after surgery, he has regained his conscious completely to a GCS of 15/15 without any motor or cranial nerve deficits apart from a slight complaint of blurring vision in the left eye [Figure 5]. He was shifted to the inpatient ward for observation then discharged home after 4 days. During the whole length of his hospital stay, he was kept on broad-spectrum antibiotics as well as antiepileptic medications. There have been neither signs of meningitis or surgical site infection during his admission period nor did he develop any seizures. At his last follow-up visit 6 months after the surgery, he was clinically intact regarding gross motor and cranial nerves' function. He has been referred to a

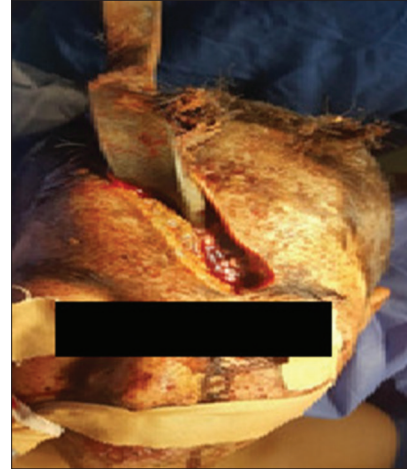

Figure 1: Preoperative picture showing the large metallic hook penetrating the patient's forehead.

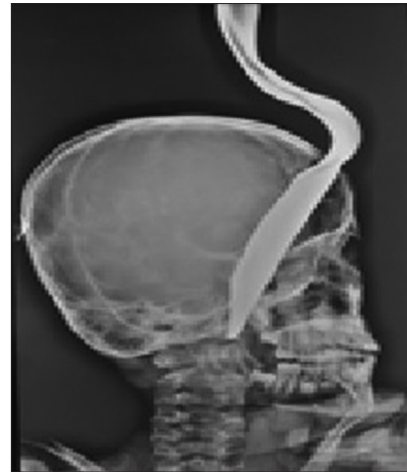

Figure 2: Oblique plain skull radiograph showing the extension of the metallic object penetration.

specialized pediatric hospital for further ophthalmology and neurocognitive assessment.

DISCUSSION

Nonmissile pTBI is rare and constitutes only 0.4% of all brain injuries, but carries the risk of a worse prognosis than closed brain injuries,^[10,13] with a fatality rate approaching 40%.^[1] The pTBI main classification as missile and nonmissile depends on the penetrating object velocity, with the nonmissile pTBI object velocity of <100 meters per second.^[1] The penetration in nonmissile pTBI depends on the energy, material, shape, angle, and site of entry.^[7] The most common entry site is the orbital roof due to its thin wall followed by the temporal squama.^[6,18] There are 57 reported pediatric nonmissile pTBI

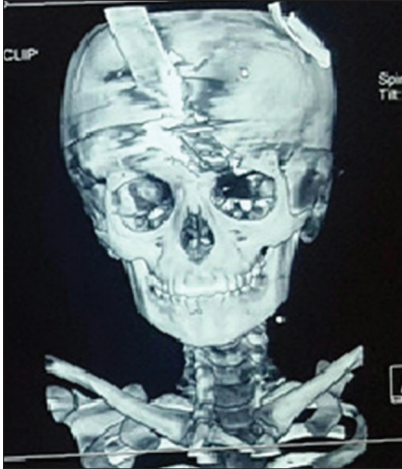


Figure 3: 3D reconstructed CT scan of the skull showing the midline frontal bone depressed fracture reaching the left orbital roof.

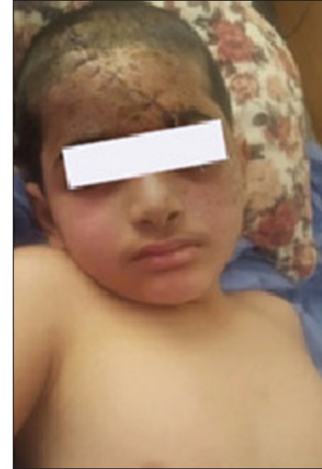

Figure 5: Postoperative photo for the patient almost 10 days after surgery while the patient is conscious and oriented.

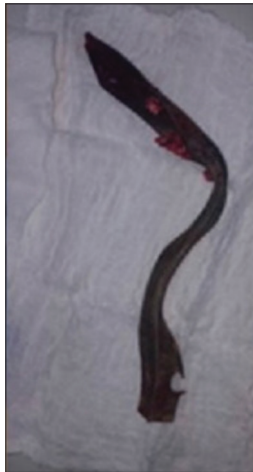


Figure 4: The metallic tent hook after its removal. It measures about 30 cm in length.

caused by offending objects such as iron rod, wood, bamboo, stone, scissors, arrow, chopsticks, pen, nail, and harpoon.^[18] In our case, the entrance site was through the left midline of the frontal bone, which is a less common site, and the material was a metallic tent hook.

The initial management for nonmissile pTBI depends on the (1) advanced trauma life support (ATLS) protocol activation, (2) availability of diagnostic tools such as CT scan and angiography, and (3) the presence of experienced medical personnel as primary responders^[6,16] In the ATLS protocol, focusing on the airway, breathing, and circulation to resuscitate life-threatening injuries are crucial for the survival of the patient and the success of the any later surgical

intervention.^[15] In the current case, the hook was maintained in its anchoring position within the skull all through the emergency department (ER) proceedings because any unplanned removal in the ER might result in uncontrollable and fatal secondary bleeding.^[13]

Regarding neuroimaging, a plain skull radiograph presents valuable information regarding the shape of the penetrating object and the existence of skull fractures^[9] and has the advantage of being free of metallic artifacts. Nevertheless, a CT scan is the most useful imaging modality for preoperative planning in nonmissile pTBI (especially not metallic ones) due to the accurate delineation of associated skull fractures, providing valuable information about the relation of the object to surrounding anatomical structures, and CT also rules out any associated remote brain injuries.^[9,13] In addition, 3D constructed CT scan can provide further valuable info about the object's size, length, direction, and position at various angles.^[11] In the present study, due to the limitation of resources in the hospital, other imaging tools such as digital subtraction angiography to evaluate the nearby vascular structures have not been performed.^[11]

Although, there is no standardized approach for object removal in nonmissile pTBI because it is determined by many factors, including the object site, object trajectory, patient characteristics, and brain injury mechanism,^[13] the surgical management for nonmissile pTBI is generally done through a craniotomy. Craniotomy has the advantages of early visualization and protection of neurovascular structures, controlled object removal, accessible debridement of the devitalized brain tissue, associated hematoma evacuation, and adequate dural repair.^[4] These steps were contemplated in our case to ensure safe and complete object removal.

In cases where mass effect is present, decompressive craniectomy is usually performed to relieve the associated intracranial hypertension.^[5] In our case, the surgeon did not perform decompressive craniectomy because there was no evidence of mass effect neither preoperatively nor intraoperatively.

The complications of nonmissile pTBI are limited to the penetration trajectory pathway, unlike missile injuries which usually involve cavitation and thermal effects.^[3,10] There are known early and late complications associated with nonmissile pTBI.^[6] Early complications include parenchymal contusions, tract hematoma, dural tears associated with cerebrospinal fluid leak, infection, and direct blood vessels injury.^[3,18] Late complications include development of pseudo-aneurysms, foreign body migration, arteriovenous fistula, and seizures.^[17] In our case, the patient developed transient blurry vision in the left eye, which might or might not be attributed to the surgery because preoperatively detailed history and clinical examination were unfeasible. Otherwise, the patient did not develop any other early or late complications.

The outcome of the patients after nonmissile pTBI is mainly dependent on initial admission GCS, pupil size, and the initial CT scan findings.^[10] Initial GCS <5 is usually associated with marked neurological function compromise and poor prognosis. Brain stem involvement on the initial CT scan also has poor prognosis and is mostly fatal.^[6,13] In the present study, the patient's initial GCS was six, which is above the severity's cutoff point, and the initial CT scan has not shown any brainstem involvement.

CONCLUSION

Following standard recommendations in the management of pTBI which includes applying the ATLS protocol in ER, acquiring the needed preoperative neuroimaging studies, avoiding moving the penetrating object till patient shifted to OR, and finally performing a planned stepwise surgical intervention through craniotomy may yield an excellent functional recovery, especially in children despite an otherwise grave initial presentation and apparently profound brain injury.

Declaration of patient consent

Patient's consent not required as patient's identity is not disclosed or compromised.

Financial support and sponsorship

Nil.

Conflicts of interest

There are no conflicts of interest.

REFERENCES

- Alafaci C, Caruso G, Caffo M, Adorno AA, Cafarella D, Salpietro FM, *et al.* Penetrating head injury by a stone: Case report and review of the literature. *Clin Neurol Neurosurg* 2010;112:813-6.
- Borkar SA, Garg K, Garg M, Sharma BS. Trans orbital penetrating cerebral injury caused by a wooden stick. Surgical nuances for removal of a foreign body lodged in cavernous sinus. *Childs Nerv Syst* 2014;30:1441-4.
- Chen L, Bao Y, Liang Y, Wang Y, Jiang J. Surgical management and outcomes of non-missile open head injury: Report of 44 cases from a single trauma centre. *Brain Inj* 2016;30:318-23.
- de Holanda LF, Pereira BJ, Holanda RR, Neto JT, de Holanda CV, Filho MG, *et al.* Neurosurgical Management of Nonmissile Penetrating Cranial Lesions. *World Neurosurg* 2016;90:420-9.
- Dore-Duffy P, Wang S, Mehedi A, Katyshev V, Cleary K, Tapper A, *et al.* Pericyte-mediated vasoconstriction underlies TBI-induced hypoperfusion. *Neurol Res* 2011;33:176-86.
- Drosos E, Giakoumettis D, Blionas A, Mitsios A, Sfakianos G, Themistocleous M. Pediatric nonmissile penetrating head injury: Case series and literature review. *World Neurosurg* 2018;110:193-205.
- Esposito DP, Walker JP. Contemporary management of penetrating brain injury. *Neurosurg Q* 2009;19:249-54.
- Gökçek C, Erdem Y, Köktekir E, Karatay M, Bayar MA, Edebalı N, *et al.* Intracranial foreign body. *Turk Neurosurg* 2007;17:121-4.
- González AL, Marín AG, Garijo JA, Mengual MV. Penetrating head injury in a paediatric patient caused by an electrical plug. *Childs Nerv Syst* 2006;22:197-200.
- Kazim SF, Shamim MS, Tahir MZ, Enam SA, Waheed S. Management of penetrating brain injury. *J Emerg Trauma Shock* 2011;4:395-402.
- Kobayashi M, Seto A, Nomura T, Yoshida T, Yamamoto M. 3D-CT highly useful in diagnosing foreign bodies in the paraesophageal orifice. *Nihon Jibiinkoka Gakkai Kaiho* 2004;107:800-3.
- Koné N, Souleymane I, Koné B, Sissoko D, Tokpa V, Kleib A, *et al.* About an observation of a child penetrating brain injury by knife. *Open J Mod Neurosurg* 2021;11:267-71.
- Li XS, Yan J, Lui C, Luo Y, Liao XS, Yu L, *et al.* Nonmissile penetrating head injuries: Surgical management and review of the literature. *World Neurosurg* 2017;98:873.e9-25.
- Mackerle Z, Gal P. Unusual penetrating head injury in children: Personal experience and review of the literature. *Childs Nerv Syst* 2009;25:909-13.
- Mandavia DP, Qualls S, Rokos I. Emergency airway management in penetrating neck injury. *Ann Emerg Med* 2000;35:221-5.
- Schreckinger M, Orringer D, Thompson BG, La Marca F, Sagher O. Transorbital penetrating injury: Case series, review

of the literature, and proposed management algorithm. *J Neurosurg* 2011;114:53-61.

17. Vakil MT, Singh AK. A review of penetrating brain trauma: Epidemiology, pathophysiology, imaging assessment, complications, and treatment. *Emerg Radiol* 2017;24:301-9.
18. Zyck S, Toshkezi G, Krishnamurthy S, Carter DA, Siddiqui A, Hazama A, *et al.* Treatment of penetrating nonmissile

traumatic brain injury. case series and review of the literature. *World Neurosurg* 2016;91:297-307.

How to cite this article: Yousif RS, Omar AM, Ismail M, Hamouda WO, Alkhafaji AO, Hoz SS. Excellent recovery after nonmissile penetrating traumatic brain injury in a child: A case report. *Surg Neurol Int* 2022;13:388.